ORIGINAL ARTICLE

Contribution of Alcohol Abuse to Cerebellar Volume Deficits in Men With Schizophrenia

Edith V. Sullivan, PhD; Anjali Deshmukh, MD; John E. Desmond, PhD; Daniel H. Mathalon, PhD, MD; Margaret J. Rosenbloom, MA; Kelvin O. Lim, MD; Adolf Pfefferbaum, MD

Background: It is controversial whether cerebellar tissue volume deficits occur in schizophrenia and, if so, what regions and tissue types are affected. Complicating such investigations is the high incidence of alcoholism comorbidity in patients with schizophrenia that itself can contribute to cerebellar abnormalities.

Method: We studied 61 healthy men (control subjects), 25 men with alcoholism, 27 men with schizophrenia, and 19 men comorbid for schizophrenia and alcoholism with the use of magnetic resonance imaging. Cerebellar structures were outlined manually, tissue classification was determined statistically, and regional volumes were corrected for normal variation in head size and age.

Results: Patients with schizophrenia alone had enlarged fourth ventricles (1.5 SD relative to controls) but showed no cerebellar tissue volume deficits. The alcoholic group had gray and white matter vermian deficits (–0.5 SD), most prominent in anterior superior lobules, and gray matter hemisphere deficits (–0.8 SD), but not fourth ventricle enlargement. The comorbid group had cerebellar hemisphere (–1.3 SD) and vermian gray matter volume deficits (–0.7 SD) and fourth ventricular enlargement (1.6 SD); these abnormalities were greater than in either single-diagnosis group, despite significantly lower levels of alcohol consumption compared with the alcoholic group. Gray matter volume in the anterior superior vermis correlated with lifetime alcohol consumption in the schizophrenic and comorbid groups when combined.

Conclusions: Cerebellar tissue volume deficits were detected in schizophrenia only when accompanied by alcoholism. By contrast, fourth ventricular enlargement occurred in schizophrenia even without alcoholism, although it was exacerbated by alcoholism. These findings support a model of cerebellar supersensitivity to alcohol-related tissue volume deficits in schizophrenia.

Arch Gen Psychiatry. 2000;57:894-902

From the Departments of Psychiatry and Behavioral Sciences (Dr Sullivan and Ms Rosenbloom), Psychology (Dr Desmond), and Radiology (Dr Desmond), Stanford University School of Medicine, Stanford, Calif; the Neuropsychiatry Program, SRI International, Menlo Park, Calif (Drs Deshmukh, Mathalon, and Pfefferbaum); and the Nathan Kline Psychiatric Research Institute, Orangeburg, NY (Dr Lim).

THERE HAS BEEN growing interest in the role that cerebellar abnormalities may play in the pathophysiology and manifestations of schizophrenia.[1-3] It has been speculated that limb movement abnormalities, lack of coordination,[4-6] impaired smooth eye pursuit,[7] and the classic "cerebellar signs"[8,9] indicate cerebellar abnormality. The observation of localized vermian hypoplasia in patients with autism,[10,11] a developmental disorder, suggests that cerebellar abnormality in patients with schizophrenia could reflect a neurodevelopmental cause of this disease. Psychotic symptoms have been attributed to cerebellar degeneration in patients with this primary neurological diagnosis.[3,9] A recent magnetic resonance (MR) imaging study reported an association between enlarged vermian white matter volume and positive symptoms in patients with schizophrenia.[12] A longitudinal MR imaging study of first-episode schizophrenia reported volume reduction of the right cerebellar hemisphere.[13]

Although reasons to expect abnormalities in the structure of the cerebellum in schizophrenia abound, efforts to document such abnormalities using neuropathological[14] or neuroimaging approaches (computed tomography[2,15,16] and MR imaging[17,18]) have not revealed a consistent pattern of results. Some postmortem studies report evidence of reduced cell counts or volume reduction,[18-21] whereas others do not.[9,15,22-24] Several critical factors complicate the in vivo establishment of whether cerebellar abnormalities constitute a reliable feature of schizophrenia.[25-27] Conventional MR imaging sequences, using slices oriented to cerebral landmarks, are not necessarily orthogonal to the plane of cerebellar structures and consequently can provide inappropriate alignment landmarks for the cerebellum.[28]

©2000 American Medical Association. All rights reserved.
Downloaded From: http://archpsyc.jamanetwork.com/ on 08/29/2016

SUBJECTS AND METHODS

SUBJECTS

All subjects (**Table 1**) were men and gave written consent for study. Data from the control and alcoholic-only groups were reported previously[41] and are included for comparison with the schizophrenic groups.

Patients With Schizophrenia Alone

The schizophrenic-only group (n=27) consisted of patients who met *DSM-III-R*[46] criteria for schizophrenia but not for current or lifetime alcohol abuse or dependence or other Axis I diagnoses. Patients without a history of significant illness or head injury (loss of consciousness >30 minutes) admitted to the unlocked voluntary ward of the Mental Health Clinical Research Center at the Veterans Affairs Palo Alto Health Care System, Palo Alto, Calif, were considered for study participation. Patients underwent screening with a medical evaluation (review of systems, routine radiography, and laboratory tests) and psychiatric diagnostic assessment. Diagnosis was based on a consensus between a research psychiatrist or psychologist using a semistructured interview and a trained and calibrated research assistant using the Structured Clinical Interview for *DSM-III-R* (SCID).[47] Subjects who met criteria for *DSM-III-R* lifetime drug dependence or drug abuse within the 3 months before undergoing MR imaging were excluded. Current symptom severity was evaluated with the 18-item Brief Psychiatric Rating Scale (BPRS)[48] (Table 1) administered by 2 raters with established reliability.

Patients With Schizophrenia and Alcoholism Comorbidity

The comorbid group (n=19) consisted of patients who met *DSM-III-R* criteria for schizophrenia and *DSM-III-R* criteria for alcohol abuse (n=3) or dependence (n=16) or Research Diagnostic Criteria (RDC) (determined from the Schedule for Affective Disorders and Schizophrenia [SADS][49]) for alcoholism. Subjects were not excluded for non–alcoholic substance abuse (n=7) but were excluded for dependence. The schizophrenia diagnosis preceded the alcoholism diagnosis in 9 patients. Median time between last drink and MR imaging was 601 days (SD, 893; range, 1-3656 days), and mean (± SD) time since last met alcohol dependence diagnosis was 8.5±7.9 years (range, 0.3-22 years). All patients with schizophrenia (with and without alcoholism comorbidity) had been treated with antipsychotic medications.

Patients With Alcoholism Only

Alcohol-dependent patients (n=25) were drawn from patients meeting RDC for alcoholism who had participated in brain imaging studies during treatment in the Alcohol Rehabilitation Program at the Veterans Affairs Palo Alto Health Care System.[50] Screening for that study excluded patients with hospitalization for *DSM-III-R* or *DSM-IV* [51] diagnosis of schizophrenia, major affective disorders, or medical or neurological conditions affecting the central nervous system; seizure disorder unrelated to alcohol withdrawal; or use of phenytoin sodium or corticosteroids in the past month and patients meeting criteria for substance abuse other than alcohol within the past year. Subjects underwent MR scanning as part of ongoing studies.[52,53] Median time between last drink and MR imaging was 204 days (SD, 648; range, 1-1994 days).

Healthy Controls

Volunteers (n=61) underwent initial screening by telephone and further evaluation using psychiatric interview with the SCID or SADS, physical examination, complete blood cell count, and chemistry panel. Subjects were excluded for Axis I psychopathological disease, substance abuse in the year before study entry, or ever having consumed more than 54 g per day of ethanol (equivalent of 4 drinks containing an average of 13.6 g of ethanol) for a period exceeding 1 month as assessed through a semistructured interview to obtain alcoholic consumption history.[54,55] Medical data were reviewed for evidence of liver, heart, or pulmonary disease; thyroid dysfunction; diabetes; head injury resulting in loss of consciousness for longer than 30 minutes; or other diseases that could affect the variables being measured. Control subjects aged 50 years and older were given the Mini-Mental State Examination[56] to screen for dementia and were excluded for having a score of 24 or less.

Assessment of Alcohol Consumption

To quantify exposure to alcohol in all subjects, we used a semistructured interview based on one developed by Skinner[54,57] and previously used by our research group[50,58] to derive estimates of total lifetime ethanol consumption. Not all patients were administered the structured alcohol history questionnaire, which yields quantitative alcohol consumption data, because early in our studies of schizophrenia these questionnaires were not part of our clinical protocol.

Demographic Variables

Kruskal-Wallis tests of demographic variables (Table 1) across the 4 groups yielded significant differences in education ($P<.001$), IQ estimated using the National Adult Reading Test[59] ($P<.002$), handedness measured using a quantitative test[60] ($P<.02$), and total lifetime consumption of alcohol ($P<.001$) but not age ($P=.09$). Follow-up Mann-Whitney tests revealed that the alcoholic group consumed more alcohol than any group, and that the schizophrenic group consumed the least alcohol and had the lowest handedness scores, indicating extreme right-handedness. The 3 patient groups had equivalent years of education and National Adult Reading Test IQs. The comorbid group did not differ significantly from the schizophrenic group in total or subscale[61] BPRS scores but tended to have higher scores on the withdrawal/retardation subscale ($P=.05$).

Continued on next page

©2000 American Medical Association. All rights reserved.
Downloaded From: http://archpsyc.jamanetwork.com/ on 08/29/2016

MR IMAGING PROTOCOLS AND QUANTIFICATION

Acquisition

Subjects underwent scanning on a 1.5-T MR imaging scanner (Signa; General Electric, Milwaukee, Wis) with a 3-dimensional–spoiled gradient recalled acquisition sequence to collect images of the entire cerebrum and cerebellum in a single volumetric data set acquired in the sagittal plane (repetition time, 24 milliseconds; echo time, 5 milliseconds; flip angle, 40°; 124 slices; 24-cm field of view; 256 × 196 matrix; acquired resolution, 0.9 × 1.2 × 1.5 mm; reconstructed resolution, 0.9 × 0.9 × 1.5 mm).

Processing

Image analysis tools were developed within the laboratory using Interactive Data Language (Research Systems, Inc, Boulder, Colo) and x-lisp software. Analysis first included a series of transformations[62] for aligning the 3-dimensional data set into desired orientations, relating them to standardized coordinates,[63] and then slicing 2-dimensional images in that orientation for delineation and measurement of specific regions. Once the images had been realigned and resliced, manual point placement and semiautomated edge detection were used for defining regions, followed by automated tissue-cerebrospinal fluid (CSF) segmentation. Volumes were determined by summation of each region on all slices measured.

Reslicing

A graphical prescription tool resliced the cerebellar structures along intracerebellar landmarks. For the hemispheres and fourth ventricle, the slices ran parallel to the brainstem on a midline sagittal section; the resulting slices were contiguous and 2.5 mm thick. For the vermian regions, the midsagittal plane was determined from axial slices taken through the vermis at the following 3 levels[28,45]: superior, where the cerebral aqueduct becomes continuous with the fourth ventricle; middle, where the vermis first protrudes into the fourth ventricle; and inferior, where the foramen of Luschka becomes confluent with CSF space. At each level, a midline plane was prescribed graphically so that the section passed through the anterior and posterior convexities of the vermis. The average of these 3 prescriptions was calculated and used to reslice the vermis into a midsagittal and 4 parasagittal slices with an interval of 1.5 mm.

Anatomical Definitions of Regions

The vermis was divided into 4 regions, designated V1, V2, V3, and V4 (**Figure 1**), and measured on the prescribed sagittal slices. Region V1 (anterior superior vermis) included lobules I through V (lingula, centralis, and culmen), bound by the superior medullary velum and the primary fissure; V2, lobules VI and VII (declive, folium, and tuber), bounded by the primary and the prepyramidal fissures; V3, lobule VIII (pyramis), demarcated by the prepyramidal and secondary fissures; and V4, lobules IX and X (uvula and nodulus), which lay between the secondary fissure and the inferior medullary velum. We measured V1 and V2 on 5 slices; V3 and V4, on the 3 middle slices (the midsagittal and 2 parasagittal slices). The junction of all vermian regions formed the apex of the fourth ventricle, which was measured on 2 to 4 slices.

Borders for each region were based on anatomical landmarks and manually outlined by separate raters with generally good to excellent reliability (intraclass correlations: hemisphere gray matter and white matter, 0.97 and 0.84; gray matter and white matter V1, 0.96 and 0.89; V2, 0.84 and 0.97; V3, 0.79 and 0.85; and V4, 0.82 and 0.73).[45] Each cerebellar hemisphere was outlined separately (Figure 1). The most anterior slice measured was at the first appearance of the floor of the fourth ventricle; the most posterior slice measured was the last on which the hemispheres were bilaterally visible. Other anatomical guides included the tentorium cerebelli as it stretched over the hemispheres superiorly and the posterior, inferior, and lateral surfaces of the meninges overlying the occipital bone.

STATISTICAL ANALYSIS

Initial analyses were performed on regional volumes expressed as standardized z scores, adjusted with regression analysis for variation in head size and age observed in the control group. A previous study of our controls[63] demonstrated significant negative correlations between regional cerebellar gray matter volumes and age and positive correlations between fourth ventricular volumes and intracranial volume. Further, the 4 subject groups in our study differed in intracranial volume ($F_{3,131}=7.90$; $P<.001$): the schizophrenic and comorbid groups had significantly smaller volumes than the alcoholic or control groups, which did not differ from each other. Regression analysis was used to adjust statistically for these differences.

The z scores were calculated with a 2-step regression analysis based on the control data. Each region of interest was regressed against an estimate of intracranial volume (ie, head size) based on a 3-dimensional volume of the cerebrum. The resulting regression coefficients were used to calculate head size–residualized scores based on the regression analysis. To correct for normal age effects, the head size–residualized scores from the control group were regressed on age, using a constrained quadratic function.[50,64] The potential increase in intersubject variability with normal age was accounted for by using a weighted least squares regression model. For each region, the standard error of the regression (SD with age effects removed) for the control data was calculated. Once all regression parameters were estimated, regional volumes from all subjects were converted to z scores as the final unit of analysis. The expected mean of the controls was $z=0\pm1$ SD. Analyses using standardized z scores permitted (1) assessment of disease effects, having removed the effects of head size and normal aging variation; (2) direct comparison of patient groups regardless of age differences; and (3) direct comparison across brain regions of fundamentally different sizes. Lower z scores for tissue and higher scores for CSF volumes were in the direction of greater abnormality.

Group comparisons for these volume measures were based on repeated-measures analysis of variance (ANOVA; $\alpha=.05$, 2 tailed), with Greenhouse-Geisser correction for P values associated with 3-way interactions, and 1-way ANOVAs and follow-up Scheffé paired comparisons ($\alpha=.05$, 2-tailed). Relationships between brain and clinical variables were examined with parametric (Pearson product moment) correlations.

©2000 American Medical Association. All rights reserved.
Downloaded From: http://archpsyc.jamanetwork.com/ on 08/29/2016

Table 1. Description of Subject Groups

	Subject Group				
	Control (n = 61)	Alcoholic (n = 25)	Schizophrenic Only (n = 27)	Comorbid (n = 19)	Significant Differences, Kruskal-Wallis Tests*
Age, mean (SD), y	46.8 (14.0)	49.6 (11.0)	44.7 (8.6)	40.9 (7.5)	NS
Education					
Mean (SD), y	16.4 (2.3)	13.9 (3.4)	14.0 (2.4)	13.6 (1.6)	C>A = S = CM
No. of subjects	61	25	27	19	
National Adult Reading Test IQ					
Mean (SD)	112.8 (6.6)	106.7 (8.3)	108.6 (7.8)	106.4 (6.6)	C>A = S = CM
No. of subjects	49	25	18	14	
Handedness score†					
Mean (SD)	23.7 (13.8)	24.6 (14.9)	19.3 (12.3)	24.6 (14.9)	C = A = CM>S
No. of subjects	58	25	22	17	
Age at onset, y‡					
Mean (SD)	. . .	27.8 (12.9)	23.3 (4.6)	22.8 (3.3)	NS
No. of subjects	. . .	25	27	19	
Lifetime alcohol consumption, kg					
Mean (SD)	61.7 (78.7)	1263.6 (790.1)	22.4 (25.4)	229.7 (219.1)	A>CM>C>S
No. of subjects	60	25	19	13	
BPRS Score					
Thinking disturbance§					
Mean (SD)	. . .	. . .	8.4 (3.3)	7.7 (2.9)	NS
No. of subjects	. . .	. . .	27	19	
Withdrawal/retardation‖					
Mean (SD)	. . .	. . .	6.8 (3.0)	8.2 (2.6)	NS
No. of subjects	. . .	. . .	27	19	
Total					
Mean (SD)	. . .	. . .	41.9 (9.1)	42.8 (8.4)	NS
No. of subjects	. . .	. . .	27	19	

*NS indicates not significant; C, controls; A, alcoholic group; S, schizophrenic group; CM, comorbid group; and ellipses, not applicable. α = .05, 2 tailed.
†Right-handed score, 14 to 32.
‡Age of alcohol onset for the alcoholic group and age of schizophrenia onset for the schizophrenic and comorbid groups.
§Thinking disturbance score consisted of hallucinatory behavior, unusual thought content, and conceptual disorganization items.
‖Withdrawal/retardation score consisted of blunted affect, emotional withdrawal, and motor retardation items.

Cerebellar structures subserve a wide range of cognitive[29] and motor[30,31] functions and have extensive connections to cortical and subcortical sites. As with the cerebrum,[23,32-35] cerebellar abnormalities associated with schizophrenia may affect cerebellar structures and tissue types differentially. Consequently, examination of gross volumetric abnormalities requires regional and tissue-type analyses.

In contrast to the equivocal role cerebellar deficits play in the pathophysiology of schizophrenia, the contribution of structural cerebellar deficits to behavioral deficits in patients with chronic alcoholism[36] is less controversial. Pathological studies of chronically alcoholic patients and patients with alcoholic Korsakoff syndrome have shown the anterior superior vermis specifically to be affected.[37] Even among moderate alcohol drinkers, the level of consumption in the year before death has been linked to degree of vermian Purkinje cell loss.[38] In vivo MR imaging studies report volume loss in cerebellar hemispheres and vermis of chronically alcoholic patients without grossly detectable cerebellar signs,[39,40] with quantitative regional assessments indicating specific loss to the anterior superior vermis.[41] Thus, there is clear evidence of alcoholism-related damage to the cerebellum, especially vermian lobules I to V and IX and to X.[42]

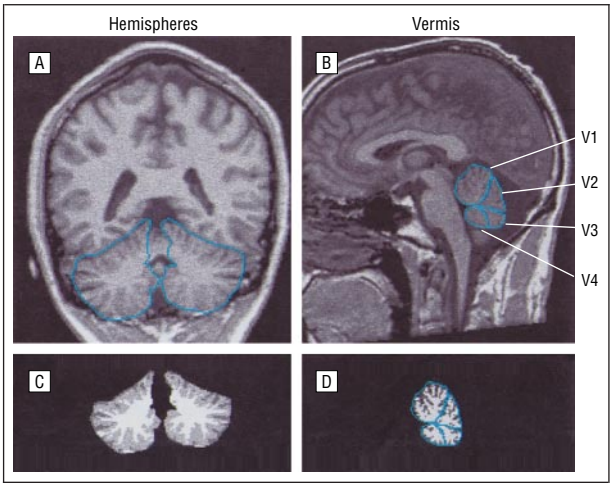

Figure 1. *Examples of hemisphere (A) and vermian (B) regions, which were traced manually. C and D, Examples of gray and white matter segmentation. The 4 regions of the vermis (V1-V4) are described in the "Anatomical Definitions of Regions" subsection of the "Subjects and Methods" section.*

Many patients with schizophrenia abuse or are dependent on alcohol. A survey of studies of comorbidity of schizophrenia with alcohol abuse found prevalence rates to range from about 10% to 50%,[43] with prevalence in-

©2000 American Medical Association. All rights reserved.
Downloaded From: http://archpsyc.jamanetwork.com/ on 08/29/2016

Table 2. ANOVA Results Based on z Scores*

Group	Cerebellar Hemispheres: Group	Group × Hemisphere	Group × Tissue Type	Group × Hemisphere × Tissue Type†
C vs S vs A				
$F_{(df)}$	$3.44_{(2,110)}$	$1.95_{(2,110)}$	$1.64_{(2,110)}$	$1.65_{(2,110)}$
P	**.04**	.15	.20	.20
C vs S				
$F_{(df)}$	$1.46_{(1,86)}$	$0.11_{(1,86)}$	$0.88_{(1,86)}$	$0.01_{(1,86)}$
P	.23	.74	.35	.91
C vs A				
$F_{(df)}$	$6.48_{(1,84)}$	$3.47_{(,184)}$	$4.44_{(1,84)}$	$3.03_{(1,84)}$
P	**.02**	.07	**.04**	.09
S vs A				
$F_{(df)}$	$1.44_{(1,50)}$	$1.26_{(1,50)}$	$0.34_{(1,50)}$	$2.92_{(1,50)}$
P	.24	.27	.56	.10
S vs A vs CM				
$F_{(df)}$	$0.68_{(2,68)}$	$0.77_{(2,68)}$	$3.16_{(2,68)}$	$1.38_{(2,68)}$
P	.52	.47	**.05**	.26

	Vermian Regions: Group	Group × Region	Group × Tissue Type	Group × Region × Tissue Type
C vs S vs A				
$F_{(df)}$	$4.06_{(2,110)}$	$1.99_{(6,330)}$	$0.23_{(2,110)}$	$2.98_{(6,330)}$
P	**.02**	.07	.80	**.008**
C vs S				
$F_{(df)}$	$0.01_{(1,86)}$	$1.45_{(3,258)}$	$0.31_{(1,86)}$	$4.04_{(3,258)}$
P	.93	.23	.58	**.009**
C vs A				
$F_{(df)}$	$7.35_{(1,84)}$	$1.85_{(3,252)}$	$0.04_{(1,84)}$	$0.75_{(3,252)}$
P	**.009**	.14	.84	.52
S vs A				
$F_{(df)}$	$5.75_{(1,50)}$	$3.13_{(3,150)}$	$0.34_{(1,50)}$	$4.28_{(3,150)}$
P	**.02**	**.03**	.56	**.01**
S vs A vs CM				
$F_{(df)}$	$3.01_{(2,68)}$	$1.62_{(6,204)}$	$4.10_{(2,68)}$	$3.11_{(6,204)}$
P	.053	.12	**.02**	**.01**

**ANOVA indicates analysis of variance; C, controls (n = 61); S, schizophrenic group (n = 27); A, alcoholic group (n = 25); and CM, comorbid group (n = 19). Significant* P *values are in boldface type.*

†Greenhouse-Geisser correction applied to 3-way interactions.

creasing in more recent decades. The Epidemiologic Catchment Area Study[44] estimated that 24% of individuals with a lifetime diagnosis of schizophrenia or schizophreniform disorder met lifetime criteria for alcohol dependence and an additional 9.7% met criteria for alcohol abuse.

Using quantitative MR image acquisition and scoring procedures designed for cerebellar measurement,[45] we examined patients with schizophrenia, some with and others without documented alcoholism comorbidity, and compared them with patients with chronic alcoholism and with healthy control subjects.[41] We hypothesized that patients comorbid for alcohol dependence and schizophrenia would manifest cerebellar deficits unique to each disease but compounded in severity.

RESULTS

Two sets of data analyses were performed. First, the schizophrenic, alcoholic, and control groups were compared, and then the schizophrenic, alcoholic, and comorbid groups were compared.

SCHIZOPHRENIC VS ALCOHOLIC VS CONTROL GROUPS

Included in these analyses were the 61 control subjects, 25 patients with alcoholism, and 27 patients with schizophrenia without alcoholism comorbidity. These analyses addressed whether patients with schizophrenia had cerebellar volume abnormalities and, if so, were they as severe as those observable in patients with alcoholism. The primary effects of interest from the repeated-measures ANOVAs (**Table 2**) involved the group factor.

A 3-way ANOVA (3 groups × 2 hemispheres × 2 tissue types) tested for differences in cerebellar hemisphere volumes and yielded a significant group effect. Follow-up ANOVAs were performed for each group pair and yielded no significant group effects or interactions for the comparisons between the control and schizophrenic groups or between the alcoholic and schizophrenic groups. The ANOVA examining differences between the control and the alcoholic groups identified gray but not white matter volume deficits in the alcoholic group (**Figure 2**, top).

©2000 American Medical Association. All rights reserved.
Downloaded From: http://archpsyc.jamanetwork.com/ on 08/29/2016

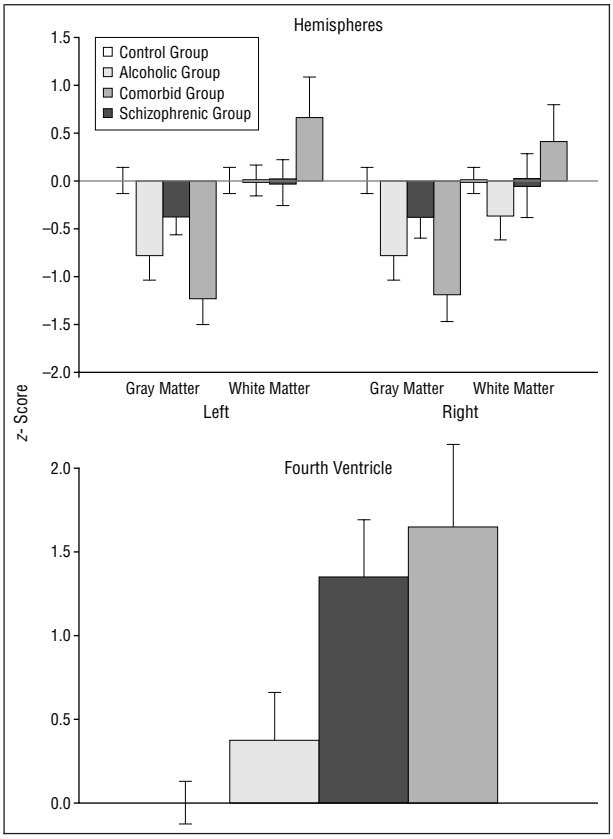

Figure 2. *Means and standard error bars for each magnetic resonance imaging regional volume for controls (n=61), patients with alcoholism (alcoholic group; n=25), patients with schizophrenia without alcoholism comorbidity (schizophrenic group; n=27), and patients with schizophrenia with alcoholism comorbidity (comorbid group; n=19).*

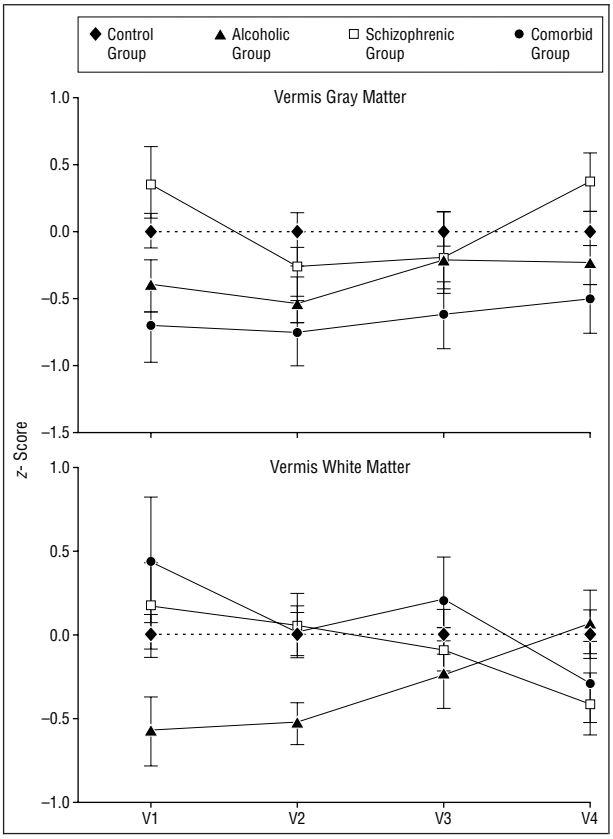

Figure 3. *Means and standard error bars for each magnetic resonance imaging regional volume for controls (n=61), patients with alcoholism (alcoholic group; n=25), patients with schizophrenia without alcoholism comorbidity (schizophrenic group; n=27), and patients with schizophrenia with alcoholism comorbidity (comorbid group; n=19). The 4 regions of the vermis (V1-V4) are described in the "Anatomical Definitions of Regions" subsection of the "Subjects and Methods" section.*

A 1-way ANOVA with follow-up Scheffé tests disclosed that the fourth ventricle was significantly larger in the schizophrenic than in the alcoholic group, which did not differ in volume from the control group ($F_{2,112}=9.47$; $P<.001$) (Figure 2, bottom).

Analysis of vermian volumes proceeded with a 3 groups × 4 regions × 2 tissue types ANOVA. The main effect of group and the 3-way interaction were significant. Follow-up ANOVAs involving group pairs showed that the alcoholic group had significantly smaller volumes in V1 gray and white matter than the control or the schizophrenic group and smaller V2 gray and white matter volume than the control group (**Figure 3**).

SCHIZOPHRENIC VS ALCOHOLIC VS COMORBID GROUPS

Included in these analyses were the 25 patients with alcoholism, 27 patients with schizophrenia without alcoholism comorbidity, and 19 patients with schizophrenia and alcoholism comorbidity. These analyses addressed whether the comorbid group had cerebellar volume differences relative to patients with uncomplicated schizophrenia (who were found not to have tissue volume deficits), and further, whether they demonstrated the same pattern and extent of deficits as the alcoholic group.

For the hemispheres, the 3 group × 2 hemisphere × 2 tissue type ANOVA yielded a significant group × tissue interaction (**Table 3**), indicating that the comorbid group had significantly smaller gray matter volumes than the schizophrenic group without alcoholism, and that the comorbid group had smaller hemisphere gray matter volume but more white matter volume (compare with Levitt et al[12]) than the alcoholic group (Figure 2, top). In contrast to the hemisphere pattern of group differences, the fourth ventricle was enlarged in the schizophrenic and the comorbid groups relative to the alcoholic group ($F_{2,70}=3.16$; $P<.05$) (Figure 2, bottom).

For the vermis, a 3 group × 4 region × 2 tissue type ANOVA yielded a significant 3-way interaction (Figure 3). To examine whether these group differences in regional vermian volumes were selectively related to differences in alcohol consumption, the 19 patients with schizophrenia and 13 patients in the comorbidity group who had given quantitative alcohol histories were compared using analysis of covariance, covarying the amount of lifetime alcohol consumed; in all cases, the group differences were no longer detectable, indicating a direct relationship between vermian volume decline and quantity of alcohol consumption among those in the schizophrenic group.

The estimate of total lifetime alcohol consumption did not correlate significantly with any cerebellar volume measure in the alcoholic group. However, among

©2000 American Medical Association. All rights reserved.
Downloaded From: http://archpsyc.jamanetwork.com/ on 08/29/2016

Table 3. Volumes of Cerebellar Regions of Interest*

	Subject Group, Mean (SD)			
	Control (n = 61)	Alcoholic (n = 25)	Schizophrenic Only (n = 27)	Comorbid (n = 19)
Hemispheres				
Left gray matter	26.07 (3.0)	24.03 (3.2)	24.88 (3.0)	22.51 (3.6)
Right gray matter	26.12 (3.0)	24.02 (3.8)	24.98 (3.2)	22.82 (3.8)
Left white matter	20.35 (2.7)	20.34 (2.3)	19.40 (3.7)	20.90 (4.9)
Right white matter	20.36 (2.6)	19.50 (3.3)	19.37 (4.1)	20.25 (4.2)
Fourth ventricle	1.32 (0.5)	1.44 (0.7)	1.83 (0.7)	1.99 (1.0)
Vermian measures				
V1 gray matter	1.89 (0.3)	1.74 (0.3)	2.03 (0.3)	1.79 (0.3)
V2 gray matter	1.22 (0.3)	1.08 (0.2)	1.20 (0.3)	1.10 (0.3)
V3 gray matter	0.37 (0.1)	0.35 (0.1)	0.38 (0.1)	0.34 (0.1)
V4 gray matter	0.47 (0.1)	0.44 (0.1)	0.51 (0.1)	0.41 (0.1)
V1 white matter	2.49 (0.4)	2.30 (0.4)	2.58 (0.4)	2.66 (0.5)
V2 white matter	1.66 (0.4)	1.44 (0.3)	1.71 (0.4)	1.69 (0.3)
V3 white matter	0.57 (0.1)	0.54 (0.1)	0.53 (0.1)	0.56 (0.1)
V4 white matter	0.65 (0.2)	0.65 (0.2)	0.56 (0.2)	0.58 (0.2)

*Vermian regions are described in the "Anatomical Definitions of Regions" of the "Subjects and Methods" section.

all patients with schizophrenia (ie, with and without alcoholism) for whom a quantitative alcohol history was obtained (n=32), greater lifetime alcohol consumption was negatively correlated with V1 gray matter volumes (r=–0.45; P=.009).

ANALYSIS OF RAW VOLUMES

To investigate the impact of the regression analysis approach on the group differences of primary interest, we examined these comparisons using raw volumes (instead of age- and head size–corrected z scores; Table 3) in 1-way ANOVAs with follow-up paired comparisons (α=.05). As observed with z scores, the group difference for the fourth ventricle was significant ($F_{3,131}$=7.14; P<.001); the schizophrenic and comorbid groups had significantly larger volumes than the control or alcoholic groups. Examination of gray matter revealed significant group effects for the combined left and right cerebellar hemispheres ($F_{3,131}$=6.64; P<.001) and the total of the 4 vermian regions ($F_{3,131}$=4.53; P=.005). In both cases, the comorbid and alcoholic groups had smaller volumes than the control group and the comorbid group had smaller volumes than the schizophrenic group. Regional analysis of the vermis disclosed that the schizophrenic and control groups did not differ on any gray matter measure, and, in fact, that the schizophrenic group had larger volumes in 3 of the 4 vermian regions. By contrast, the alcoholic and the comorbid groups had smaller gray matter volumes than the control group across all 4 vermian regions, although most differences failed to reach statistical significance. As with z score analysis, which removed variance attributable to head size and aging, the differences between alcoholic and control groups and between comorbid and control groups were statistically significant, whereas the schizophrenic group was still not different from the control group.

COMMENT

This controlled MR imaging study demonstrated regional cerebellar volume deficits in patients with schizophrenia who were comorbid for alcohol abuse. The cerebellar deficit pattern was similar (albeit not identical) to that observed in alcoholic patients without schizophrenia and involved gray matter of both cerebellar hemispheres and vermis. The vermian volume deficits of the alcoholic group extended to white matter and were maximal in the anterior superior lobules (compare Sullivan et al[41]). In contrast to both patient groups with alcohol abuse histories, the pure schizophrenic group exhibited no cerebellar tissue volume deficits and only fourth ventricular enlargement.

Postmortem measurements reveal that the volume of the adult human cerebellum is 140 to 150 mL.[65] The total cerebellar volume for controls in our study was slightly more than 100 mL (92 mL for the hemispheres and 9.2 mL for the vermis), indicating that we sampled about 70% of the volume estimated in postmortem studies.

Estimates of lifetime alcohol consumption for all groups provided additional corroborating evidence of the validity of the diagnostic group differences and also highlighted the fact that the patients comorbid for schizophrenia and alcoholism, although drinking more alcohol than the patients with schizophrenia alone, had substantially lower lifetime alcohol use than the patients recruited from the alcoholic treatment program. In many cases it had been many years since these comorbid patients last met diagnostic criteria for an alcohol disorder (Table 2). Despite the lower exposure to alcohol and more remote histories of alcohol consumption in the comorbid group, they manifested the regional deficits typical of alcoholism and, in certain instances, with greater severity than those seen in patients with alcoholism alone.

Fourth ventricular enlargement was present in patients with schizophrenia but not in those with alcohol dependence alone. Conversely, volume deficits of the cerebellar hemispheres and vermis were found in patients with alcohol dependence but not in those with schizophrenia without alcoholism. Patients comorbid for both disorders manifested more severe fourth ventricular enlargement than that seen in patients with schizophrenia alone and more severe cerebellar and vermian gray matter volume deficits than those observed in patients with alcoholism alone. These volume abnormalities occurred in patients comorbid for both disorders despite substantially lower levels of lifetime alcohol consumption than in patients with alcoholism alone. Although the levels of deficit present in the patients with schizophrenia alone were not severe enough to reach statistical significance in this sample, the severe deficits seen in comorbid patients may be evidence that the preexisting neuropathological features of schizophrenia renders these brain structures especially vulnerable to the toxic effects of excessive alcohol exposure. This model of su-

©2000 American Medical Association. All rights reserved.
Downloaded From: http://archpsyc.jamanetwork.com/ on 08/29/2016

persensitivity is further supported by the observation that among the combined group of patients with schizophrenia, with and without a diagnosis of alcoholism, lifetime alcohol consumption was significantly related to gray matter volume in the anterior superior vermis (V1) and that amount of alcohol consumption accounted for the observed group differences in vermian volumes. These results also argue against the contention that these vermian volume deficits predated the onset of alcoholism.

A model of "cognitive dysmetria" has been proposed by Andreasen and colleagues[66] to explain the overarching deficit of schizophrenia, which includes impairment in the coordination, ordering, monitoring, and prioritizing of incoming and outgoing information. The neural substrate is hypothesized to involve prefrontal, thalamic, and cerebellar circuitry. An MR imaging study from that research group reported absence of cerebellar hemisphere volume deficits but presence of anterior superior vermian area deficits in patients with schizophrenia irrespective of history of alcoholism.[67] Our finding of absence of cerebellar volume deficits in schizophrenia uncomplicated by alcoholism does not necessarily disprove the cognitive dysmetria hypothesis, because the circuitry could be disrupted without macrostructural volume deficits. However, an MR spectroscopy study, although showing *N*-acetylaspartate–creatine ratio abnormalities in the pons, failed to show them in the cerebellum in patients with schizophrenia.[68]

The similarity of the intracranial volume deficits of the schizophrenic and comorbid groups provides converging evidence of the diagnosis of schizophrenia in the patients with alcoholism comorbidity. Abnormal size of intracranial volumes as well as that of midline structures, such as the fourth ventricle, is supportive of neurodevelopmental pathogenesis of schizophrenia.[14,69-72] This finding is consistent with that of Jacobsen and colleagues[18] who reported fourth ventricle size abnormalities in adolescent patients with early-onset schizophrenia and who also noted that the lack of consensus regarding this finding may be attributable to difficulties in measurement of this deeply enfolded fluid-filled space.

CONCLUSIONS

The data presented herein suggest that fourth ventricular enlargement is a feature of schizophrenia, whereas cerebellar tissue volume deficits, if seen in patients with schizophrenia, may be attributable to exposure to alcohol. Whether fourth ventricular enlargement reflects a neurodevelopmental process that also can be exacerbated by exposure to alcohol cannot be determined from the current data. However, these data support the contention that excessive alcohol consumption can be a major factor underlying cerebellar volume deficits observed in schizophrenia and emphasize the importance of documenting history of alcohol use in patients with schizophrenia. Our findings and interpretations are limited to men with adult onset of the disease and do not preclude the possibility that some aspect of schizophrenia pathophysiology arises from disruption of neural circuits involving the cerebellum (compare with previous studies[1-3,66] on the cerebellum and schizophrenia). Further limitations include lack of knowledge about the functional significance of the observed cerebellar volume deficits in the comorbid group, lack of information about nutritional status that can underlie brain abnormalities acquired during bouts of alcohol abuse,[36,73] and whether recuperation of volume or function can occur with prolonged sobriety (compare with previous studies[51,53,74] on brain volume in alcoholic patients). Nonetheless, the results of our study suggest a supersensitivity of the cerebellum in schizophrenia to the detrimental effects of alcoholism comorbidity, exposing patients to risks for motor and cognitive dysfunction common to both diseases.[75]

Accepted for publication April 11, 2000.

Supported by grants AA10723, AA05965, MH58007, and MH30854 from the National Institutes of Health, Bethesda, Md, and Department of Veterans Affairs, Washington, DC.

We thank the staff of the Mental Health Clinical Research Center, Palo Alto, Calif, in particular, Sarah Rawson, and Christopher Galloway for their undaunted care and vigilant attention to data collection, and management. We also thank Barton F. Lane, Catherine Ju, Kenneth Chow, MA, and Brian Matsumto, MA, for their contributions to image scoring, image processing, and data analysis.

Reprints: Edith V. Sullivan, PhD, Department of Psychiatry and Behavioral Sciences (5717), Stanford University School of Medicine, 401 Quarry Rd, Stanford, CA 94305-5717 (e-mail: edie@stanford.edu).

REFERENCES

1. Taylor MA. The role of the cerebellum in the pathogenesis of schizophrenia. *Neuropsychiatry Neuropsychol Behav Neurol.* 1991;4:251-280.
2. Martin P, Albers M. Cerebellum and schizophrenia: a selective review. *Schizophr Bull.* 1995;21:241-250.
3. Katsetos CD, Hyde TM, Herman MM. Neuropathology of the cerebellum in schizophrenia: an update: 1996 and future directions. *Biol Psychiatry.* 1997;42:213-224.
4. Schröder J, Niethammer R, Geider F-J, Reitz C, Blinkert M, Jauss M, Sauer H. Neurological soft signs in schizophrenia. *Schizophr Res.* 1992;6:25-30.
5. Sanders RD, Keshavan MS, Schooler NR. Neurological examination abnormalities in neuroleptic-naive patients with first-break schizophrenia: preliminary results. *Am J Psychiatry.* 1994;151:1231-1233.
6. Rossi A, Decataldo S, Di Michele V, Manna V, Ceccoli S, Stratta P, Casacchia M. Neurological soft signs in schizophrenia. *Br J Psychiatry.* 1990;157:735-739.
7. Levy DL, Holzman PS, Matthysse S, Mendell NR. Eye tracking dysfunction and schizophrenia: a critical perspective. *Schizophr Bull.* 1993;19:461-536.
8. Kinney DK, Yurgelun-Todd DA, Woods BT. Neurologic signs of cerebellar and cortical sensory dysfunction in schizophrenics and their relatives. *Schizphr Res.* 1999;35:99-104.
9. Lohr JB, Jeste DV. Cerebellar pathology in schizophrenia? a neurometric study. *Biol Psychiatry.* 1986;21:865-875.
10. Courchesne E, Saitoh O, Yeung-Courchesne R, Press GA, Lincoln AJ, Haas RH, Schreibman L. Abnormality of cerebellar vermian lobules VI and VII in patients with infantile autism: identification of hypoplastic and hyperplastic subgroups with MR imaging. *Am J Radiol.* 1993;162:123-130.
11. Courchesne E, Yeung-Courchesne R, Press GA, Hesselink JR, Jernigan TL. Hypoplasia of cerebellar vermal lobules VI and VII in autism. *N Engl J Med.* 1988;318:1349-1354.
12. Levitt J, McCarley R, Nestor P, Petrescu C, Donnino R, Hirayasu Y, Kikinis R, Jolesz F, Shenton M. Quantitative volumetric MRI study of the cerebellum and vermis in schizophrenia: clinical and cognitive correlates. *Am J Psychiatry.* 1999;156:1105-1107.
13. DeLisi LE, Sakuma M, Tew W, Kushner M, Hoff AL, Grimson R. Schizophrenia as a chronic active brain process: a study of progressive brain structural change subsequent to the onset of schizophrenia. *Psychiatry Res.* 1997;74:129-140.
14. Shapiro RM. Regional neuropathology in schizophrenia: where are we? where are we going? *Schizophr Res.* 1993;10:187-239.
15. Aylward EH, Reiss A, Barta PE, Tien A, Han W, Lee J, Pearlson GD. Magnetic resonance imaging measurement of posterior fossa structures in schizophrenia. *Am J Psychiatry.* 1994;151:1448-1452.

©2000 American Medical Association. All rights reserved.
Downloaded From: http://archpsyc.jamanetwork.com/ on 08/29/2016

16. Weinberger DR, Wagner RL, Wyatt RJ. Neuropathological studies of schizophrenia: a selective review. *Schizophr Bull.* 1983;9:193-212.
17. Shenton M, Wible CG, McCarley RW. A review of magnetic resonance imaging studies of brain abnormalities in schizophrenia. In: Krishnan KRR, Doraiswamy PM, eds. *Brain Imaging in Clinical Psychiatry.* New York, NY: Marcel Dekker Inc; 1997:297-380.
18. Jacobsen L, Giedd J, Berquin P, Krain A, Hamburger S, Kumra S, Rapoport J. Quantitative morphology of the cerebellum and 4th ventricle in childhood-onset schizophrenia. *Am J Psychiatry.* 1997;154:1663-1669.
19. Nasrallah HA, Schwarzkopf SB, Olson SC, Coffman JA. Perinatal brain injury and cerebellar vermal lobules-I-X in schizophrenia. *Biol Psychiatry.* 1991;29:567-574.
20. Weinberger DR, Kleinman JE, Luchins DJ, Bigelow LB, Wyatt RJ. Cerebellar pathology in schizophrenia, a controlled postmortem study. *Am J Psychiatry.* 1980; 137:359-361.
21. Stevens JR. Neuropathology of schizophrenia. *Arch Gen Psychiatry.* 1982;39: 1131-1139.
22. Uematsu M, Kaiya H. Midsagittal cortical pathomorphology of schizophrenia: a magnetic resonance imaging study. *Psychiatry Res Imaging.* 1989;30:11-20.
23. Andreasen NC, Flashman L, Flaum M, Arndt S, Swayze V, O'Leary DS, Ehrhardt JC, Yuh WTC. Regional brain abnormalities in schizophrenia measured with magnetic resonance imaging. *JAMA.* 1994;272:1763-1769.
24. Helmkamp CE, Bigelow LB, Paltan-Ortiz JD, Torrey EF, Kleinman JE, Herman MM. Evaluation of superior vermal Purkinje cell placement in mental illness. *Biol Psychiatry.* 1999;45:1370-1375.
25. Press GA, Murakami JW, Courchesne E, Grafe M, Hesselink JR. The cerebellum, III: anatomic-MR correlation in the coronal plane. *AJR Am J Roentgenol.* 1990;154:593-602.
26. Courchesne E, Press GA, Murakami J, Berthoty D, Grafe M, Wiley CA, Hesselink JR. The cerebellum in sagittal plane–anatomic-MR correlation, I: the vermis. *AJNR Am J Neuroradiol.* 1989;10:659-665.
27. Snyder PJ, Bilder RM, Wu H, Bogerts B, Lieberman JA. Cerebellar volume asymmetries are related to handedness: a quantitative MRI study. *Neuropsychologia.* 1995;33:407-419.
28. Courchesne E, Yeung-Courchesne R, Egaas B. Methodology in neuroanatomic measurement. *Neurology.* 1994;44:203-208.
29. Schmahmann JD, ed. *The Cerebellum and Cognition.* San Diego, Calif: Academic Press; 1997.
30. Gilman S. Cerebellar control of movement. *Ann Neurol.* 1994;35:3-4.
31. Ghez C. The cerebellum. In: Kandel ER, Schwartz JH, Jessell TM, eds. *Principles of Neural Science.* 3rd ed. New York, NY: Elsevier Science Inc; 1991:626-646.
32. Gur RE. MRI and cognitive behavioral function in schizophrenia. *J Neural Transm.* 1992;36(suppl):13-22.
33. Schlaepfer TE, Harris GJ, Tien AY, Peng LW, Lee S, Federman EB, Chase GA, Barta PE, Pearlson GD. Decreased regional cortical gray matter volume in schizophrenia. *Am J Psychiatry.* 1994;151:842-848.
34. Sullivan E, Lim K, Mathalon D, Marsh L, Beal D, Harris D, Hoff A, Faustman W, Pfefferbaum A. A profile of cortical gray matter volume deficits characteristic of schizophrenia. *Cereb Cortex.* 1998;8:117-124.
35. Wible CG, Shenton ME, Fischer IA, Allard JE, Kikinis R, Jolesz FA, Iosifescu DV, McCarley RW. Parcellation of the human prefrontal cortex using MRI. *Psychiatry Res Neuroimaging.* 1997;76:29-40.
36. Victor M, Adams RD, Collins GH. *The Wernicke-Korsakoff Syndrome and Related Neurologic Disorders Due to Alcoholism and Malnutrition.* 2nd ed. Philadelphia, Pa: FA Davis Co Publishers; 1989.
37. Phillips SC, Harper CG, Kril J. A quantitative histological study of the cerebellar vermis in alcoholic patients. *Brain.* 1987;110:301-314.
38. Karhunen PJ, Erkinjuntti T, Laippala P. Moderate alcohol consumption and loss of cerebellar Purkinje cells. *BMJ.* 1994;308:1663-1667.
39. Davila MD, Shear PK, Lane B, Sullivan EV, Pfefferbaum A. Mammillary body and cerebellar shrinkage in chronic alcoholics: an MRI and neuropsychological study. *Neuropsychology.* 1994;8:433-444.
40. Shear PK, Sullivan EV, Lane B, Pfefferbaum A. Mammillary body and cerebellar shrinkage in chronic alcoholics with and without amnesia. *Alcohol Clin Exp Res.* 1996;20:1489-1495.
41. Sullivan EV, Deshmukh A, Desmond JE, Lim KO, Pfefferbaum A. Cerebellar volume decline in normal aging, uncomplicated alcoholism, and Korsakoff's syndrome: relation to ataxia. *Neuropsychology.* 2000;14:341-352.
42. Cavanagh J, Holton JL, Nolan CC. Selective damage to the cerebellar vermis in chronic alcoholism: a contribution from neurotoxicology to an old problem of selective vulnerability. *Neuropathol Appl Neurobiol.* 1997;23:355-363.
43. Cuffel BJ. Prevalence estimates of substance abuse in schizophrenia and their correlates. *J Nerv Ment Dis.* 1992;180:589-592.
44. Regier DA, Farmer ME, Rae DS, Locke BZ, Keith SJ, Judd LL, Goodwin FK. Comorbidity of mental disorders with alcohol and other drug abuse: results from the Epidemiologic Catchment Area (ECA) Study. *JAMA.* 1990;264:2511-2518.
45. Deshmukh A, Desmond JE, Sullivan EV, Lane BF, Lane B, Matsumoto B, Marsh L, Lim K, Pfefferbaum A. Quantification of cerebellar structures with MRI. *Psychiatry Res Neuroimaging.* 1997;75:159-172.
46. American Psychiatric Association. *Diagnostic and Statistical Manual of Mental Disorders, Revised Third Edition.* Washington, DC: American Psychiatric Association; 1987.
47. Spitzer RL, Gibbon M, Skodol AE, Williams JBW, First MB. DSM-III-R *Casebook.* Washington, DC: American Psychiatric Press; 1989.
48. Overall JE, Gorham DR. The Brief Psychiatric Rating Scale (BPRS): recent developments in ascertainment and scaling. *Psychopharmacol Bull.* 1988;24:97-99.
49. Spitzer RL, Endicott J, Robins E. *Research Diagnostic Criteria (RDC).* New York: Biometrics Research, New York State Psychiatric Institute; 1975.
50. Pfefferbaum A, Lim KO, Zipursky RB, Mathalon DH, Lane B, Ha CN, Rosenbloom MJ, Sullivan EV. Brain gray and white matter volume loss accelerates with aging in chronic alcoholics: a quantitative MRI study. *Alcohol Clin Exp Res.* 1992; 16:1078-1089.
51. American Psychiatric Association. *Diagnostic and Statistical Manual of Mental Disorders, Fourth Edition.* Washington, DC: American Psychiatric Association; 1994.
52. Pfefferbaum A, Sullivan EV, Mathalon DH, Shear PK, Rosenbloom MJ, Lim KO. Longitudinal changes in magnetic resonance imaging brain volumes in abstinent and relapsed alcoholics. *Alcohol Clin Exp Res.* 1995;19:1177-1191.
53. Pfefferbaum A, Sullivan E, Rosenbloom MJ, Mathalon DH, Lim KO. A controlled study of cortical gray matter and ventricular changes in alcoholic men over a 5-year interval. *Arch Gen Psychiatry.* 1998;55:905-912.
54. Skinner HA. *Development and Validation of a Lifetime Alcohol Consumption Assessment Procedure.* Toronto, Ontario: Addiction Research Foundation; 1982.
55. Skinner HA, Allen BA. Alcohol Dependence Syndrome: measurement and validation. *J Abnorm Psychol.* 1982;91:199-209.
56. Folstein MF, Folstein SE, McHugh PR. Mini-Mental State: a practical method for grading the cognitive state of patients for the clinician. *J Psychiatr Res.* 1975; 12:189-198.
57. Skinner HA, Sheu WJ. Reliability of alcohol use indices: the lifetime drinking history and the MAST. *J Stud Alcohol.* 1982;43:1157-1170.
58. Pfefferbaum A, Rosenbloom MJ, Crusan K, Jernigan TL. Brain CT changes in alcoholics: the effects of age and alcohol consumption. *Alcohol Clin Exp Res.* 1988;12:81-87.
59. Nelson HE. *The National Adult Reading Test (NART).* Windsor, Ontario: Nelson Publishing Co; 1982.
60. Crovitz HF, Zener KA. Group test for assessing hand and eye dominance. *Am J Psychol.* 1962;75:271-276.
61. Faustman WO. The Brief Psychiatric Rating Scale. In: Maruish M, ed. *The Use of Psychological Testing For Treatment, Planning and Outcome Assessment.* Hillsdale, NJ: Lawrence A Erlbaum Associates; 1994:371-401.
62. Desmond J, Lim KO. On- and off-line Talairach registration for structural and functional MRI studies. *Hum Brain Mapp.* 1997;5:58-73.
63. Talairach J, Szikla G. *Atlas of Stereotaxic Anatomy of the Telencephalon: Anatomo-Radiological Studies.* New York, NY: Masson Publishing; 1967.
64. Pfefferbaum A, Mathalon DH, Sullivan EV, Rawles JM, Zipursky RB, Lim KO. A quantitative magnetic resonance imaging study of changes in brain morphology from infancy to late adulthood. *Arch Neurol.* 1994;51:874-887.
65. Ellis RS. Norms for some structural changes in the human cerebellum from birth to old age. *J Comp Neurol.* 1920;32:1-33.
66. Andreasen NC, Paradiso S, O'Leary DS. "Cognitive dysmetria" as an integrative theory of schizophrenia: a dysfunction in cortical-subcortical-cerebellar circuitry? *Schizophr Bull.* 1998;24:203-218.
67. Nopoulos P, Ceilley J, Gailis E, Andreasen N. An MRI study of cerebellar vermis morphology in patients with schizophrenia. *Biol Psychiatry.* 1999;46:703-711.
68. Eluri R, Paul C, Roemer R, Boyko O. Single-voxel proton magnetic resonance spectroscopy of the pons and cerebellum in patients with schizophrenia: a preliminary study. *Psychiatry Res.* 1998;84:17-26.
69. Feinberg I. Schizophrenia caused by a fault in programmed synaptic elimination during adolescence? *J Psychiatr Res.* 1983;17:319-334.
70. Mednick SA, Machon RA, Huttunen MD, Bonett D. Adult schizophrenia following prenatal exposure to an influenza epidemic. *Arch Gen Psychiatry.* 1988;45: 189-192.
71. Weinberger DR. Implications of normal brain development for the pathogenesis of schizophrenia. *Arch Gen Psychiatry.* 1987;44:660-669.
72. Lyon M, Barr CE. Possible interactions of obstetrical complications and abnormal fetal brain development in schizophrenia. In: Mednick SA, Cannon TD, Barr CE, Lyon M, eds. *Fetal Neural Development and Adult Schizophrenia.* New York, NY: Cambridge University Press; 1991:134-150.
73. Charness ME. Brain lesions in alcoholics. *Alcohol Clin Exp Res.* 1993;17:2-11.
74. Sullivan EV, Rosenbloom MJ, Lim KO, Pfefferbaum A. Longitudinal changes in cognition, gait, and balance in abstinent and relapsed alcoholic men: relationships to changes in brain structure. *Neuropsychology.* 2000;14:178-188.
75. Nixon SJ, Hallford HG, Tivis RD. Neurocognitive function in alcoholic, schizophrenic, and dually diagnosed patients. *Psychiatry Res.* 1996;64:35-45.

©2000 American Medical Association. All rights reserved.
Downloaded From: http://archpsyc.jamanetwork.com/ on 08/29/2016