

# Sensory Information Processing in Neuroleptic-Naive First-Episode Schizophrenic Patients

## A Functional Magnetic Resonance Imaging Study

Dieter F. Braus, MD; Wolfgang Weber-Fahr, PhD; Heike Tost, MSc; Matthias Ruf, MSc; Fritz A. Henn, PhD, MD

**Background:** Schizophrenic disorders are thought to involve widespread abnormalities in information processing. The present study used functional magnetic resonance imaging and a simple and robust paradigm that involved auditory and visual activation to examine basic sensory input circuits. Our aim was to determine which stages of the input processing network are disturbed in first-episode schizophrenic patients.

**Methods:** Twelve neuroleptic-naive inpatients (paranoid subtype) were compared with 11 healthy subjects by means of echo-planar functional magnetic resonance imaging. In a block design, the paradigm included the simultaneous presentation of a moving 6-Hz checkerboard and auditory stimuli in the form of drumbeats. The subjects were asked to simply look and listen.

**Results:** In comparison with control subjects, patients showed reduced activation in the right thalamus, the right

prefrontal cortex, and the parietal lobe (restricted to the dorsal visual pathway) bilaterally. There were no notable differences in the primary visual cortex or the object-specific occipitotemporal pathway. In addition, patients presented with a reduced signal change to auditory stimulation in the left acoustic cortex.

**Conclusions:** The present study supports the concept of widespread cortical and subcortical deficits in schizophrenia. Our findings suggest abnormal functioning early in the information processing and in high-order association cortices already at illness onset, before the administration of medication or the most confounding effects of illness duration. The main regions have been implicated in visual motion perception and discrimination as well as in attention to sensorial events and perceptual synthesis.

*Arch Gen Psychiatry.* 2002;59:696-701

**T**HE SCHIZOPHRENIA spectrum is widely recognized as a heterogeneous disorder. Investigators have consistently tried to identify the neurobiological substrate of information processing deficits that are characteristic of most schizophrenic patients.<sup>1-3</sup> It has been hypothesized that there are widespread abnormalities in the early stages of information processing leading to a cascade of “downstream” effects on higher cortical functions, such as sustained attention, working memory, concept formation, or social functioning.<sup>4</sup>

The goal of the present study was to use functional magnetic resonance (fMR) imaging<sup>5</sup> to demonstrate abnormality in information processing circuits in first-episode, neuroleptic-naive schizophrenic patients. In general, functional imaging findings in acutely ill schizophrenic patients have been criticized, as patients might be unable to understand and perform complicated cognitive tasks. Keeping this in mind,

the present study was designed with the use of a simple and robust input paradigm requiring little cognitive effort, which would allow an evaluation of elementary information processing. The paradigm chosen included the simultaneous presentation of 2 sensory stimuli without information content, (1) an alternating visual checkerboard (6 Hz) as well as (2) an acoustic stimulus consisting of drumbeats. The use of 2 different modalities should involve both the information flow through the thalamus to the low- and high-order sensory cortices (V1-V5 and A1, A2) in the temporal and occipital lobes and processing in the frontoparietal cortices. Two inputs were chosen to stimulate perceptual synthesis and to maximize activation of the heteromodal association cortices. Thus far, the functional interaction of the information processing stream via visual and acoustic input channels has not been directly studied in schizophrenia. Therefore, this study may serve as a starting point for further research aimed at identifying functional dif-

From the Central Institute of Mental Health (ZI), NMR-Research, Mannheim, Germany.

## SUBJECTS AND METHODS

### SUBJECTS

Twelve inpatients (6 men and 6 women; average [ $\pm$ SD] age,  $25.1 \pm 4.8$  years; school education,  $10.6 \pm 1.8$  years) living in the community of Mannheim, Germany, and satisfying *DSM-IV* as well as *International Classification of Diseases, 10th Revision (ICD-10)* criteria for schizophrenia along with 11 healthy control subjects (6 men and 5 women; average age,  $29.4 \pm 6.2$  years; school education,  $12.0 \pm 1.4$  years) participated in this study. Control subjects were recruited through advertisements; all patients entered the study after first psychiatric hospitalization. All were right-handed according to the Edinburgh Handedness Inventory.<sup>6</sup> All inpatients were neuroleptic-naive, having their first schizophrenic episode with the predominance of delusions, hallucinations, and distrust. Particular care was taken to exclude patients with a history of neurologic disorders or substance abuse. All patients had undergone thorough neurologic examination, showing no abnormalities. Urine screening for drug usage was negative. All stabilized patients were rediagnosed 6 months after the initial examination, and the diagnosis was stable in all cases.

The healthy volunteers were given a structured screening interview. Exclusion criteria included a history of significant medical, neurologic, or psychiatric illnesses as well as substance abuse. Written informed consent was obtained after the purpose of the study and the procedures

had been explained to all participants. The study was approved by the local university ethics committee.

### PROCEDURE

The fMR imaging paradigm included the simultaneous presentation of a flickering 6-Hz checkerboard and auditory stimuli in the form of drumbeats, with the specific instruction just to look and listen. Visual stimuli were generated by a computer (Apple PowerBook; Apple Computer Corp, Cupertino, Calif; MacStim; David Darby, PhD, FRACP, West Melbourne, Australia) and displayed on a back projection plane at the foot end of the scanner via a liquid crystal display projector (Sharp Electronics Corporation, Mahway, NJ). Subjects were in a supine position and viewed the screen through an adjustable mirror fixed to the head coil. Acoustic stimuli were presented through customized magnetic resonance headphones. The 2 experimental conditions (stimulation and fixation) were recorded in 5 sequences of 10 measurements in alternating order.

### IMAGE ACQUISITION

Images were acquired on a standard clinical 1.5-T MR imager (Siemens AG, Munich, Germany). For fMR imaging, a standard echo planar imaging sequence (repetition time, 1.8 milliseconds; echo time, 66 milliseconds;  $\alpha=90^\circ$ ; T2\* contrast) with an in-plane resolution of  $64 \times 64$  pixels (19 slices;

Continued on next page

ferences in the various levels of information processing deficits. We hypothesized that even minimal cognitive effort might disclose dysfunction in different levels of the information processing network, particularly in the thalamus and frontoparietal association areas.

## RESULTS

The study groups did not differ significantly with respect to age, sex, or educational achievement. On average, patients were investigated 6.5 months after inception of prodromal signs. Patients presented with moderate psychotic symptoms as indicated by the Brief Psychiatric Rating Scale (mean  $\pm$ SD score,  $49.9 \pm 5.7$ ). None of the participants had ever received neuroleptic medication before being enrolled in the study. Overall head motions were evaluated with SPM99 software. Two patients and 1 control subject had to be excluded because of motion artifacts exceeding 1.5 mm in the x, y, or z direction. Structural MR images and showed no abnormalities in any of the participants.

### GROUP ANALYSIS OF HEALTHY SUBJECTS

Comparing visual and acoustic stimulation and fixation, the group analysis showed a significant ( $P < .05$ ) activation of the primary visual cortex (V1) and extrastriate areas (V2-V5) as well as the superior temporal auditory cortices A1 and A2 (**Table 1**). A stimulation-induced enhancement of local blood oxygen level-dependent MR signals could also be traced subcortically bilaterally in

dorsolateral thalamic areas corresponding to the lateral and medial geniculate nuclei. Increased activation was also seen in the dorsolateral prefrontal cortex, where a pronounced right-sided activation in the inferior portion was detected. **Figure 1** shows the localization of the activation overlaid onto a glass brain.

### GROUP ANALYSIS OF FIRST-EPIISODE SCHIZOPHRENIC PATIENTS

The group analysis of the different perceptual conditions in the neuroleptic-naive first-episode patient group showed a significant activation in the primary visual (V1), extrastriate (V2-V5), and auditory cortices (A1, A2) of the brain. Thalamic activation patterns were more pronounced in the lateral and medial geniculate nuclei of the left hemisphere. A significant blood oxygen level-dependent response of prefrontal areas was totally missing in our patient group. Table 1 shows the amount and the localization of stimulus-induced activations.

### INTERACTION ANALYSIS

The application of a rigorous interaction analysis allows the selective detection of cerebral areas that are less active in the schizophrenic sample and enhanced in healthy control subjects. The schizophrenic patients showed a markedly reduced response of the right posterior thalamic relay nuclei, which are concerned with subcortical processing of sensory information (lateral and medial geniculate nuclei).

3-mm thickness; gap factor, 0.3; field of view, 220 × 220 mm) was used. For anatomic reference, a 3-dimensional magnetization prepared rapid gradient echo image data set was acquired. The fMR imaging slices were oriented axially parallel to the anterior commissure–posterior commissure line according to Talairach and Tournoux.<sup>7</sup> Each functional T2\* slice was imaged 100 times in a total period of 310 seconds. A vacuum pad was used to improve head fixation and to minimize involuntary head movement.

#### DATA ANALYSIS

For data analysis we used a general linear model as employed by SPM99 software (Wellcome Department of Cognitive Neurology, University College, London, London, England).<sup>8</sup> Our inferences were based on *P* values adjusted for the volume of interest by means of random field theory. We used a 2-stage analysis procedure where the contrasts reflecting activations in each subject were entered into a second-level analysis to emulate a random-effect analysis. This allows us to generalize our inferences to the populations from which our control subjects and patients were drawn. We first looked at the main effects of visual and auditory stimulation in both groups and then analyzed the interaction or differences in activation.

The first 5 volumes of each functional time series were discarded because of T1 effects. All volumes were realigned to the remaining first volume as correction for interscan movements by means of a rigid body transformation with 6 parameters (3 rotations and 3 translations). A T1-weighted

3-dimensional magnetization prepared rapid gradient echo (1.05 × 1.05 × 1-mm voxel size) was coregistered to the first T2\* image. This procedure ensures that the functional (fMR) and structural data are part of the same coordinate system. The structural image was spatially normalized to a standard template by means of a 12-parameter affine transformation with additional nonlinear components,<sup>9,10</sup> where the deformations were modeled with smooth (spatial) basis functions (ie, 3-dimensional discrete cosine basis function set). The nonlinear transformation was subsequently applied to the T2\* data. The data were smoothed with a 12-mm full width at half maximum isotropic gaussian kernel for individual analysis and for group analysis. Data were analyzed by modeling the different conditions (stimulation and fixation) as boxcar functions convoluted with the hemodynamic response function (individual threshold *P* < .001) in the context of a general linear model.

Specific effects were tested by applying appropriate linear contrasts to the parameter estimates for each condition, resulting in a *T*-statistic for each individual voxel. The statistical parametric map constitutes the *T*-values. The contrast used was +1 for visual and auditory stimulation and –1 for the fixation condition. Data were analyzed by including the contrast images of all subjects of each group (first-episode patients and control subjects) into a second-level group analysis with a threshold of *P* < .05 corrected for the entire volume or the volume of interest.<sup>11,12</sup> One-sample *t* tests were performed to test for in-group correspondences and 2-sample *t* tests to identify areas that are less active in schizophrenic patients compared with control subjects.

**Table 1. SPM Group Analysis\***

Area	Location	Side	Talairach Coordinates†			No. of Voxels	T-Value
			x	y	z		
<b>Healthy Control Subjects</b>							
Frontal lobe (FEF/BA46)	Intermediate frontal gyrus	R	42	16	21	97	2.74‡
		L	No significant activation				
Temporal lobe (A1, A2)	Superior temporal gyrus	R	59	–17	1	846	12.95§
		L	–53	–23	4	875	9.48‡
Occipital lobe (V1-V5)	Medial and posterior occipital lobe	R	21	–94	–8	1867	10.96§
		L	–36	–85	–8	1683	15.87§
Thalamus (LGN/MGN)	Lateral/medial geniculate nucleus	R	18	–24	–4	172	7.82‡
		L	–18	–24	–4	156	9.16‡
<b>First-Episode Patients</b>							
Temporal lobe (A1, A2)	Superior temporal gyrus	R	53	–6	–2	732	8.76§
		L	–53	–3	–2	765	12.06§
Occipital lobe (V1-V5)	Medial and posterior occipital lobe	R	30	–85	–13	1522	11.96§
		L	–15	–99	–3	1544	13.79§
Thalamus (LGN/MGN)	Lateral/medial geniculate nucleus	R	18	–24	–6	62	4.71‡
		L	–18	–24	–6	160	5.90‡

\*SPM indicates statistical parametric map; FEF, frontal eye field; BA, Brodmann area; LGN, lateral geniculate nucleus; MGN, medial geniculate nucleus; R, right; and L, left.

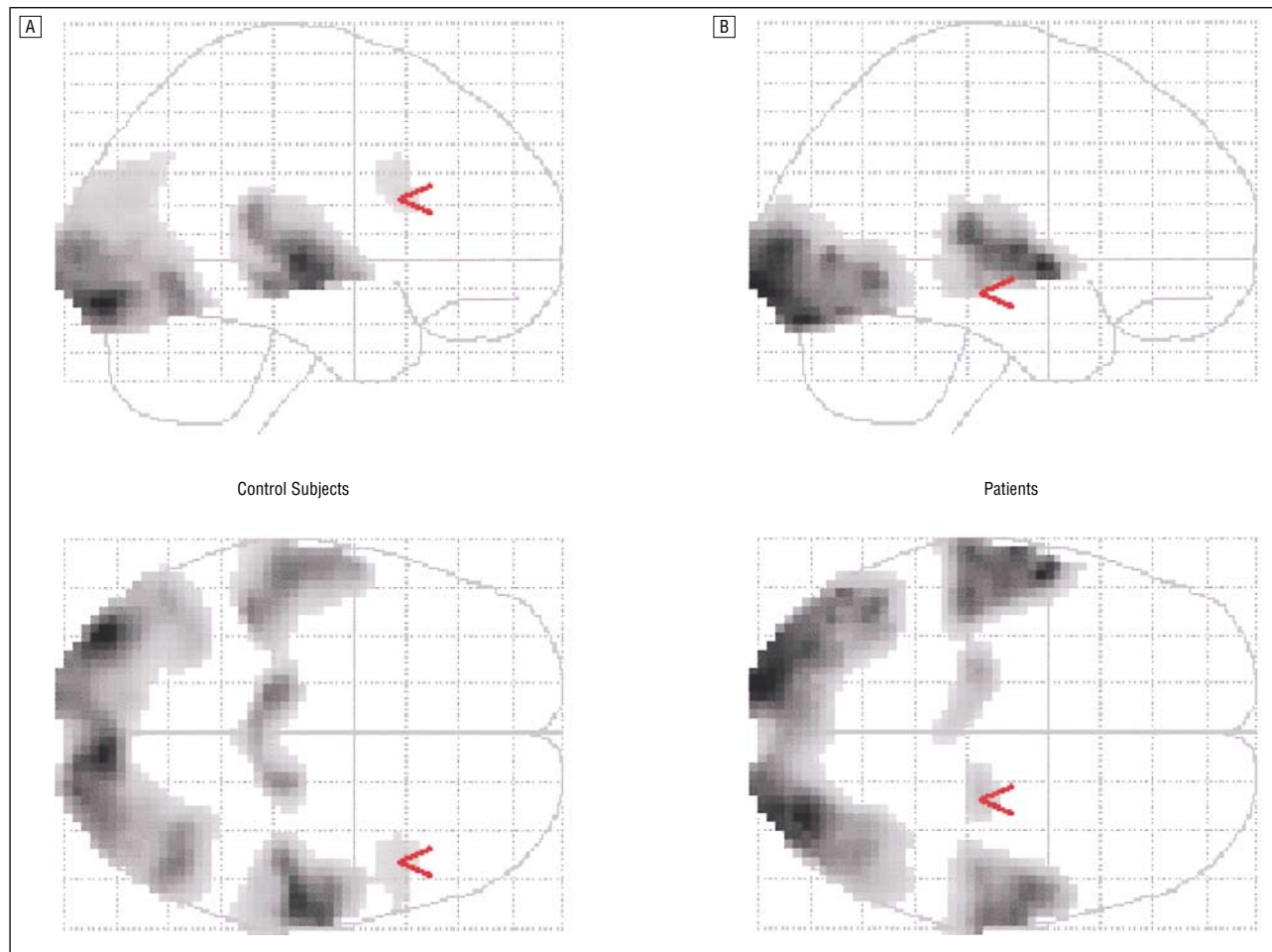
†Local maximum.

‡*P*<sub>1,9</sub> < .05, corrected for volume of interest.

§*P*<sub>1,9</sub> < .05, corrected for entire volume.

Higher-order extrastriate cortices of the middle occipital and inferior parietal lobes corresponding to the dorsal visual processing pathway were found to be hypoactive in the patients bilaterally. Furthermore, a reduced prefrontal activation level of the right frontal eye field and the in-

termediate frontal gyrus corresponding to Brodmann area 46 was detected along with a reduced blood oxygen level–dependent–response in the left acoustic cortices of the superior temporal lobe (**Table 2**). Figure 1 and **Figure 2** outline the “hypoactive” cortical regions of the first-



**Figure 1.** Anatomic correlates of the stimulus-induced activation patterns in 10 healthy control subjects (A) and 10 first-episode schizophrenic patients (B). The patient group shows a reduced right thalamic blood oxygen level–dependent response (B, red arrow) in addition to a lack of prefrontal activation seen in control subjects (A, red arrow) (SPM99 software; Wellcome Department of Cognitive Neurology, University College, London, London, England, group analysis,  $P < .05$ , corrected for volume of interest).

**Table 2. SPM Interaction Analysis (Activation Control Subjects > First-Episode Patients)\***

Area	Location	Side	Talairach Coordinates†			No. of Voxels	T-Value‡
			x	y	z		
Frontal lobe							
FEF	Superior precentral sulcus	R	42	5	33	114	3.16
BA46	Intermediate frontal gyrus	R	42	21	21	29	2.12
Parietal lobe (IPL)	Inferior parietal lobe	R	30	-74	34	177	3.07
		L	-21	-63	31	209	2.61
Temporal lobe (A1, A2)	Transverse temporal gyrus	L	-36	-29	10	138	3.14
Occipital lobe (V3a/V5)	Middle occipital gyrus	L	-48	-75	7	75	2.89
Thalamus (LGN/MGN)	Lateral/medial geniculate nucleus	R	15	-26	-4	176	3.36

\*See the first footnote to Table 1 for explanation of abbreviations. IPL indicates inferior parietal lobe.

†Local maximum.

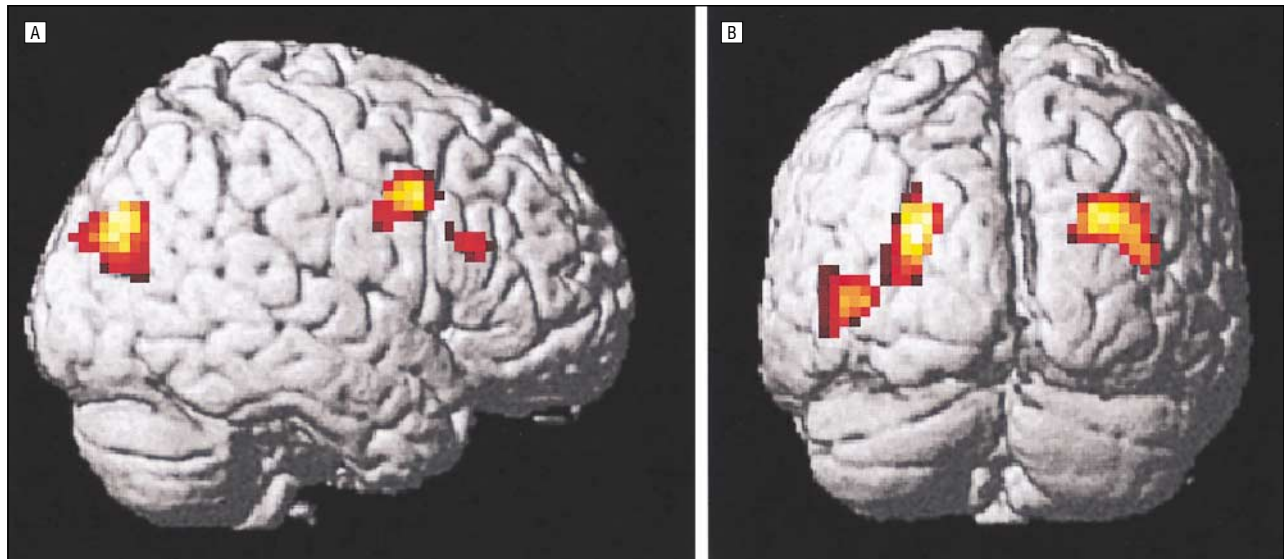
‡For all values,  $P_{1,18} < .05$ , corrected for volume of interest.

episode schizophrenic patients from a lateral and posterior angle on a normalized brain.

#### COMMENT

Using a very simple perceptual fMR imaging paradigm that minimized the effect of cognitive effort and motivation, we examined the circuitry involved in the fun-

damental processing of simultaneous visual and auditory information in neuroleptic-naive first-episode schizophrenic patients compared with control subjects. We were able to demonstrate functional deficits in the first relay station of the right thalamus as a sign of abnormalities in early stages of information processing. This observation is consistent with positron emission tomographic studies,<sup>13,14</sup> lending further support to the



**Figure 2.** Visualization of the interaction analysis results (SPM99 software; Wellcome Department of Cognitive Neurology, University College, London, London, England,  $P < .05$ , corrected for volume of interest). Compared with schizophrenic patients ( $n=10$ ), the spatial extent of activation patterns in healthy subjects ( $n=10$ ) is significantly increased in the highlighted anatomic areas of the prefrontal areas (frontal eye field, Brodmann area 46) (A) and the dorsal visual processing pathway (B).

concept indicating both deficits in sensory gating in schizophrenia<sup>15</sup> and a dysfunction in cortical-thalamic-cerebellar circuitry as proposed by Andreasen et al.<sup>16</sup> In addition, cortical response to auditory stimulation in the left superior temporal gyrus was reduced in our acutely ill patients, with at least 9 of them experiencing auditory hallucinations. This latter result is in full agreement with fMR imaging data from David et al<sup>17</sup> showing that response of the temporal cortex to exogenous auditory stimulation was markedly reduced in patients experiencing auditory hallucinations, regardless of medication. The major new finding of the present study is that, after simultaneous visuoauditory stimulation, schizophrenic patients activate to a lesser extent than do normal subjects bilaterally in the inferoposterior parietal cortex and regions of the right prefrontal cortex. In contrast to this specific hypofunction of the dorsal visual pathway, we did not find any differences in the primary visual cortex or the object-specific occipitotemporal stream.

One emerging architectural principle of functional brain organization in information processing is that neuronal responses expressed at any level in a perceptual hierarchy reflect an interaction between “bottom-up”-driven afferents from lower subcortical and cortical areas and backward “modulatory” inputs from higher cortical regions that mediate top-down contextual effects.<sup>18-20</sup> A compelling example is attentional modulation of responses in functionally specialized areas. Vision is an especially fruitful domain for studying distributed neural systems in the human brain. Major functions are comparable with those in nonhuman primates, with the neuroanatomy and neurophysiology of the monkey visual system being well known.<sup>21</sup>

The differential visual impairments produced by focal lesions in clinical cases suggest that the human visual cortex, like that of the monkey, may be similarly organized into 2 anatomically distinct and functionally specialized ventral and dorsal processing pathways. Occipitotemporal lesions include visual object agnosia, while those

produced by occipitoparietal lesions include disorders in velocity detection and discrimination as well as attention deficits, visuospatial neglect, and dysfunction of spatial working memory.<sup>22,23</sup> Both processing streams have reciprocal connections with regions beyond the modality-specific visual system.<sup>24</sup> Anatomic studies have shown that projections from areas in the dorsal stream terminate around the frontal eye field and the principal sulcus of the dorso-lateral prefrontal cortex (Brodmann area 46) reciprocated by a top-down feedback projection via the prefrontal cortex.<sup>25</sup> On the other hand, there is evidence that thalamocortical and corticocortical loops play a causal role in cooperative and competitive neural interactions<sup>26</sup> and that frontoparietal connections are mediating spatial working memory<sup>27</sup> as well as visual awareness and the organization of voluntary behavior contingent on sensory cues.<sup>28,29</sup>

It has been suggested that, in addition to thalamic gating, the maintenance of context and spatial working memory may underlie various deficits in information processing and attention observed in schizophrenic patients.<sup>30-32</sup> This in turn would imply disturbances in the above-mentioned neural network in schizophrenic patients.<sup>33</sup>

This study showed a very specific profile of abnormal activation in the posterior parietal cortex and regions of the right prefrontal cortex (the right frontal eye field and Brodmann area 46) in schizophrenic patients. This points to a limited dysfunction in the dorsal visual processing stream, as opposed to the object-specific ventral visual pathway. The parietal and frontal regions implicated in our study are very similar to those activated during attention to visual motion in normal subjects<sup>18</sup> as well as smooth-pursuit eye movements.<sup>34</sup> Furthermore, these areas have been shown to be specifically involved in the formation of perceptual states and the awareness of sensory stimuli.<sup>29</sup> Attentional deficits<sup>35,36</sup> and impairments in the visual perception of motion signals<sup>37</sup> as well as in smooth-pursuit eye movements<sup>38,39</sup> are well documented in schizophrenia. The homology between our functional results and those behavioral markers may represent

their underlying neurobiology. The noted abnormal frontoparietal activations could also reflect a functional interaction between visual and auditory cortical processing and a disturbed modulatory cognitive set in schizophrenia. This would mean that the site of abnormal activation must not necessarily be identical with the site of pathophysiology.

Our findings are clearly preliminary because of the small number of unmedicated first-episode patients available for this study and acquired in a naturalistic design. Because of the fMR imaging method, subtracting the fixation baseline from the stimulation condition, we cannot exclude that patients showed more baseline activation during the fixation period in the frontoparietal areas than the control subjects, but equal activation during stimulation, appearing as a hypoactive response to stimulation. A further drawback of this study lies in the fact that these acutely ill patients were not examined for oculomotor and motion-perception deficits or spatial and nonspatial working memory, partly because of technical limitations and their limited compliance for extensive technical procedures. Clearly, one future goal should be more comprehensive studies using large numbers of well-characterized subjects (clinically and neuropsychologically), with a direct correlation of oculomotor performance and specific dorsal pathway activation tasks (eg, sinusoidal grating or random dot paradigms) performed inside the magnet.<sup>40</sup>

Despite its constraints, this study confirms the concept of widespread cortical and subcortical deficits in schizophrenia. The regions implicated in our study suggest an abnormal functioning of the thalamus as well as high-order frontoparietal cortical areas that are restricted to the dorsal visual processing stream and have been implicated in attention to sensorial events and conscious perceptual synthesis. With respect to the syndromic nature of schizophrenia, we suggest that functional alterations within this information processing network represent a common pathophysiology rather than a common etiology. Our simple and robust fMR imaging paradigm may be useful for screening at-risk populations and for observing patients during the introduction of medication and throughout the longitudinal course of the illness.

Submitted for publication March 26, 2001; final revision received August 16, 2001; accepted October 15, 2001.

This work was supported by grant DFG: BR 1112/5-1 from the Deutsche Forschungsgemeinschaft, Bonn, Germany.

We thank Traute Demirakca, MSc, for valuable comments on the manuscript and Gunilla Oberthür, MTRA, for her help in performing the studies.

Corresponding author and reprints: Dieter F. Braus, MD, Central Institute of Mental Health (ZI), PO Box 122 120, D-68072 Mannheim, Germany (e-mail: djbraus@zi-mannheim.de).

## REFERENCES

1. Braff DL, Saccuzzo DP. Information processing dysfunction in paranoid schizophrenia: a two-factor deficit. *Am J Psychiatry*. 1981;138:1051-1056.
2. Holzman PS, Proctor LR, Levy DL, Yasillo NJ, Meltzer HY, Hurt SW. Eye-tracking dysfunctions in schizophrenic patients and their relatives. *Arch Gen Psychiatry*. 1974;31:143-151.
3. Nuechterlein KH, Dawson ME, Green MF. Information-processing abnormalities as neuropsychological vulnerability indicators for schizophrenia. *Acta Psychiatr Scand Suppl*. 1994;90:71-79.
4. Saccuzzo DP, Braff DL. Early information processing deficit in schizophrenia. *Arch Gen Psychiatry*. 1981;38:175-179.
5. Ogawa S, Lee TM. Magnetic resonance imaging of blood vessels at high fields. *Magn Reson Med*. 1990;16:9-18.
6. Oldfield RC. The assessment and analysis of handedness: the Edinburgh inventory. *Neuropsychologia*. 1971;9:97-113.
7. Talairach J, Tournoux P. *Co-planar Stereotaxic Atlas of the Human Brain*. Stuttgart, Germany: Georg Thieme Verlag; 1988.
8. Friston KJ, Holmes AP, Poline JB, Grasby PJ, Williams SC, Frackowiak RS, Turner R. Analysis of fMRI time-series revisited. *Neuroimage*. 1995;2:45-53.
9. Ashburner J, Hutton C, Frackowiak R, Johnsrude I, Price C, Friston K. Identifying global anatomical differences. *Hum Brain Mapp*. 1998;6:348-357.
10. Ashburner J, Friston KJ. Nonlinear spatial normalization using basis functions. *Hum Brain Mapp*. 1999;7:254-266.
11. Worsley KJ, Friston KJ. Analysis of fMRI time-series revisited—again. *Neuroimage*. 1995;2:173-181.
12. Strange BA, Fletcher PC, Henson RN, Friston KJ, Dolan RJ. Segregating the functions of human hippocampus. *Proc Natl Acad Sci U S A*. 1999;96:4034-4039.
13. Buchsbaum MS, Someya T, Teng CY, Abel L, Chin S, Najafi A, Haier RJ, Wu J, Bunney WE Jr. PET and MRI of the thalamus in never-medicated patients with schizophrenia. *Am J Psychiatry*. 1996;153:191-199.
14. Heckers S, Curran T, Goff D, Rauch SL, Fischman AJ, Alpert NM, Schacter DL. Abnormalities in the thalamus and prefrontal cortex during episodic object recognition in schizophrenia. *Biol Psychiatry*. 2000;48:651-657.
15. Judd LL, McAdams L, Budnick B, Braff DL. Sensory gating deficits in schizophrenia: new results. *Am J Psychiatry*. 1992;149:488-493.
16. Andreasen NC, Paradiso S, O'Leary DS. "Cognitive dysmetria" as an integrative theory of schizophrenia. *Schizophr Bull*. 1998;24:203-218.
17. David AS, Woodruff PW, Howard R, Mellers JD, Brammer M, Bullmore E, Wright I, Andrew C, Williams SC. Auditory hallucinations inhibit exogenous activation of auditory association cortex. *Neuroreport*. 1996;7:932-936.
18. Friston KJ, Buchel C. Attentional modulation of effective connectivity from V2 to V5/MT in humans. *Proc Natl Acad Sci U S A*. 2000;97:7591-7596.
19. Posner MI, Petersen SE, Fox PT, Raichle ME. Localization of cognitive operations in the human brain. *Science*. 1988;240:1627-1631.
20. Haxby JV, Grady CL, Ungerleider LG, Horwitz B. Mapping the functional neuroanatomy of the intact human brain with brain work imaging. *Neuropsychologia*. 1991;29:539-555.
21. Zeki S, Watson JD, Lueck CJ, Friston KJ, Kennard C, Frackowiak RS. A direct demonstration of functional specialization in human visual cortex. *J Neurosci*. 1991;11:641-649.
22. Park S, Puschel J, Sauter BH, Rentsch M, Hell D. Spatial working memory deficits and clinical symptoms in schizophrenia. *Biol Psychiatry*. 1999;46:392-400.
23. Petrides M. Visuo-motor conditional associative learning after frontal and temporal lesions in the human brain. *Neuropsychologia*. 1997;35:989-997.
24. Desimone R, Schein SJ, Moran J, Ungerleider LG. Contour, color and shape analysis beyond the striate cortex. *Vision Res*. 1985;25:441-452.
25. Ungerleider LG, Courtney SM, Haxby JV. A neural system for human visual working memory. *Proc Natl Acad Sci U S A*. 1998;95:883-890.
26. Lumer ED, Edelman GM, Tononi G. Neural dynamics in a model of the thalamo-cortical system. II. *Cereb Cortex*. 1997;7:228-236.
27. Friedman HR, Goldman-Rakic PS. Coactivation of prefrontal cortex and inferior parietal cortex in working memory tasks revealed by 2D functional mapping in the rhesus monkey. *J Neurosci*. 1994;14:2775-2788.
28. Lumer ED, Friston KJ, Rees G. Neural correlates of perceptual rivalry in the human brain. *Science*. 1998;280:1930-1934.
29. Lumer ED, Rees G. Covariation of activity in visual and prefrontal cortex associated with subjective visual perception. *Proc Natl Acad Sci U S A*. 1999;96:1669-1673.
30. Wexler BE, Stevens AA, Bowers AA, Sernyak MJ, Goldman-Rakic PS. Word and tone working memory deficits in schizophrenia. *Arch Gen Psychiatry*. 1998;55:1093-1096.
31. Carter CS, Perlstein W, Ganguli R, Brar J, Mintun M, Cohen JD. Functional hypofrontality and working memory dysfunction in schizophrenia. *Am J Psychiatry*. 1998;155:1285-1287.
32. Javitt DC, Shelley AM, Silipo G, Lieberman JA. Deficits in auditory and visual context-dependent processing in schizophrenia. *Arch Gen Psychiatry*. 2000;57:1131-1137.
33. Braff DL, Swerdlow NR. Neuroanatomy of schizophrenia. *Schizophr Bull*. 1997;23:509-512.
34. Berman RA, Colby CL, Genovese CR, Voyvodic JT, Luna B, Thulborn KR, Sweeney JA. Cortical networks subserving pursuit and saccadic eye movements in humans: an fMRI study. *Hum Brain Mapp*. 1999;8:209-225.
35. Bustillo JR, Thaker G, Buchanan RW, Moran M, Kirkpatrick B, Carpenter WT Jr. Visual information-processing impairments in deficit and nondeficit schizophrenia. *Am J Psychiatry*. 1997;154:647-654.
36. Cornblatt BA, Keip JG. Impaired attention, genetics, and the pathophysiology of schizophrenia. *Schizophr Bull*. 1994;20:31-46.
37. Chen Y, Palafox GP, Nakayama K, Levy DL, Matthysse S, Holzman PS. Motion perception in schizophrenia. *Arch Gen Psychiatry*. 1999;56:149-154.
38. Iacono WG, Lykken DT. Eye tracking and psychopathology. *Arch Gen Psychiatry*. 1979;36:1361-1369.
39. Holzman PS. Recent studies of psychophysiology in schizophrenia. *Schizophr Bull*. 1987;13:49-75.
40. Rudolph K, Pasternak T. Transient and permanent deficits in motion perception after lesions of cortical areas MT and MST in the macaque monkey. *Cereb Cortex*. 1999;9:90-100.