ORIGINAL ARTICLE

Fusiform Gyrus Volume Reduction in First-Episode Schizophrenia

A Magnetic Resonance Imaging Study

Chang Uk Lee, MD, PhD; Martha E. Shenton, PhD; Dean F. Salisbury, PhD; Kiyoto Kasai, MD; Toshiaki Onitsuka, MD, PhD; Chandlee C. Dickey, MD; Deborah Yurgelun-Todd, PhD; Ron Kikinis, MD; Ferenc A. Jolesz, MD; Robert W. McCarley, MD

Background: The fusiform gyrus (occipitotemporal gyrus) is thought to be critical for face recognition and may possibly be associated with impaired facial recognition and interpretation of facial expression in schizophrenia. Results of postmortem studies have suggested that fusiform gyrus volume is reduced in schizophrenia, but there have been no in vivo structural studies of the fusiform gyrus in schizophrenia using magnetic resonance imaging.

Methods: High–spatial resolution magnetic resonance images were used to measure the gray matter volume of the fusiform gyrus in 22 patients with first-episode schizophrenia (first hospitalization), 20 with first-episode affective psychosis (mainly manic), and 24 control subjects.

Results: Patients with first-episode schizophrenia had overall smaller relative volumes (absolute volume/intracranial contents) of fusiform gyrus gray matter compared with controls (9%) and patients with affective psychosis (7%). For the left fusiform gyrus, patients with schizophrenia showed an 11% reduction compared with controls and patients with affective psychosis. Right fusiform gyrus volume differed in patients with schizophrenia only compared with controls (8%).

Conclusion: Schizophrenia is associated with a bilateral reduction in fusiform gyrus gray matter volume that is evident at the time of first hospitalization and is different from the presentation of affective psychosis.

Arch Gen Psychiatry. 2002;59:775-781

From the Clinical Neuroscience Division, Laboratory of Neuroscience, Department of Psychiatry, VA Boston Healthcare System, Brockton Division, and Harvard Medical School, Brockton, Mass (Drs Lee, Shenton, Salisbury, Kasai, Onitsuka, Dickey, and McCarley); the Cognitive Neuroscience Laboratory (Dr Salisbury) and the Brain Imaging Center (Dr Yurgelun-Todd), McLean Hospital, Belmont, Mass; and the Surgical Planning Laboratory, MRI Division, Brigham and Women's Hospital, Department of Radiology, Harvard Medical School, Boston, Mass (Drs Shenton, Kikinis, and Jolesz). Dr Lee is now with the Department of Psychiatry, College of Medicine, The Catholic University of Korea, Seoul.

THE FUSIFORM GYRUS (FG), or occipitotemporal gyrus, is located on the ventromedial surface of the temporal and occipital lobes. Recently, this gyrus received attention because of its critical role in face recognition.[1-3] Evidence from functional neuroimaging and neuropsychological studies[4,5] suggests that there are specific mechanisms for face perception in the FG in humans that are distinct from the mechanisms for perception of other objects. Using functional magnetic resonance imaging (fMRI), Kanwisher et al[6] found that the FG was selectively involved in the perception of faces. These findings excluded alternative accounts of the function of the FG in face perception, such as visual attention or general processing of any animate or human forms. Moreover, the necessary role of the FG in face recognition has been supported by findings from neuropsychological and anatomical studies[7,8] of patients who have selectively lost the ability to recognize faces (prosopagnosia).

There is also accumulating evidence[9-11] to suggest that patients with schizophrenia may have a deficit in face processing. Impaired processing of faces in patients with schizophrenia may also underlie some aspects of their disturbance in social skills, as interpersonal interactions largely depend on facial recognition[12] and interpretation of facial expressions.[13,14]

Yet another line of evidence for impaired facial recognition in schizophrenia is that abnormal facial perception may be related to symptoms of delusional misinterpretation, a disturbance sometimes observed in patients with schizophrenia.[15,16] For example, Hudson and Grace[17] reported that a case of misidentification syndrome was associated with a region anterior to the typical face area, in the mid FG. These findings, taken together, suggest that the FG might be one of the brain areas underlying some of the pathophysiology of schizophrenia.

Despite evidence for FG abnormalities in schizophrenia, we know of only one research group[18,19] that has measured FG volume in a postmortem study of schizophrenia. These investigators reported reduced left FG volume and a reversal of the

©2002 American Medical Association. All rights reserved.
Downloaded From: http://archpsyc.jamanetwork.com/ on 06/01/2016

normal left>right volume asymmetry in patients with schizophrenia. However, to our knowledge, there have been no structural MRI studies examining FG volume change in schizophrenia. In part, this may be due to difficulties in accurately identifying FG boundaries because of neuroanatomical variations. The FG is bordered medially by the collateral sulcus and laterally by the occipitotemporal sulcus, both of which are frequently interrupted, with bifurcations particularly in the anterior and posterior part of the FG.[20,21] Another potential impediment to defining FG boundaries is MRI susceptibility artifact at the interface between the brain and petrous bones, often encountered in the ventral area of the temporal lobe.[22] These neuroanatomical ambiguities and artifacts make it difficult to identify FG landmarks using MRI slices in a single plane.

Thus, in the present study, we use 3-dimensional information to provide reliable measures of FG gray matter volume in patients with first-episode schizophrenia, patients with first-episode affective psychosis, and control subjects. Although structural MRI data demonstrate abnormal brain structures in schizophrenia,[23-25] it is important to evaluate patients at the first episode as the effects of chronicity of illness and long-term treatment may confound structural MRI findings in patients with chronic schizophrenia. Examining patients with first-episode schizophrenia and patients with first-episode affective psychosis is also important to investigating whether changes in brain structure are specific to schizophrenia or are part of a more general pathological process of psychosis. In addition, addressing this issue is important because it will help answer the question of whether the psychosis associated with affective disorder and that associated with schizophrenia represent different disorders or variants of a single disorder of psychosis that has somewhat different expressions.[26] Hirayasu et al[27,28] previously reported that patients with first-episode schizophrenia were different from patients with first-episode affective psychosis in evincing smaller gray matter volume in the posterior superior temporal gyrus, planum temporale, and Heschl's gyrus.

PARTICIPANTS AND METHODS

PARTICIPANTS

Twenty-four controls (21 men and 3 women), 22 patients with first-episode schizophrenia (17 men and 5 women), and 20 patients with first-episode affective psychosis (15 men and 5 women) participated in this study. Patients were recruited from inpatients at McLean Hospital, a psychiatric hospital affiliated with Harvard Medical School. Control subjects were recruited through newspaper advertisements. After a complete description of the study, written informed consent was obtained from all participants.

Patients and control subjects met inclusion criteria for age (18-55 years); IQ greater than 75; right-handedness[29]; and a negative history of seizures, head trauma with loss of consciousness, or neurologic disorder and no lifetime history of alcohol or other drug dependence. Control subjects also had no Axis I psychiatric disorders or a first-degree relative with Axis I psychiatric disorders (determined by Structured Clinical Interview for *DSM-III-R,* Non-Patient-Edition,[30] and Structured Clinical Interview for *DSM-III-R,* Personality Disorder[31]). Demographic data for each group are presented in **Table 1**.

Patients were diagnosed based on the Structured Clinical Interview for *DSM-III-R*[32] and by a review of hospital course and medical records. The affective psychosis group included 16 patients with bipolar (manic) disorder and 4 with major depressive (unipolar) disorder. The statistically significant results reported in the "Results" section remained the same with exclusion of the 4 major depressive patients. All patients manifested psychosis. Diagnoses were confirmed at a 1-year follow-up interview. First episode was operationally defined as the first psychiatric hospitalization, as in previous studies.[27,28] Age at time of first medication (Table 1) provided both a measure of duration of medication administration and a relatively objective estimate of symptom onset (most dates were from hospital records). Current chlorpromazine-equivalent medication dosage and duration of administration before MRI were based primarily on hospital records, with patient information also used; the median duration of psychotropic medication administration before MRI was short (Table 1). Participants in this study included 15 new individuals and 51 common to an earlier study of the planum temporale and Heschl's gyrus.[28]

CLINICAL EVALUATIONS

The Brief Psychiatric Rating Scale[33] was administered to all patients. General level of functioning was evaluated using the Global Assessment Scale.[34] The Mini-Mental State Examination[35] was used to rule out dementia or delirium. In addition, the information subscale of the *Wechsler Adult Intelligence Scale–Revised*[36] was used to estimate general fund of information, and the digits-forward and digits-backward subscales of the *Wechsler Adult Intelligence Scale–Revised* were used to evaluate immediate and short-term memory, attention, and concentration. Socioeconomic status (SES) and parental SES were assessed using the Hollingshead 2-factor scale.[37] All of these assessments were conducted by one of two psychologists (M.E.S. and D.F.S.).

MRI ACQUISITION AND PROCESSING

Magnetic resonance images were acquired with a 1.5-T scanner (GE Medical Systems, Milwaukee, Wis). The scanning and image methods are described in detail elsewhere.[38-40] Briefly, the acquisition protocol included 2 MRI pulse sequences. The first sequence was a coronal series of contiguous spoiled gradient-recalled acquisition (SPGR) images (repetition time, 35 milliseconds; echo time, 5 milliseconds; 1 repetition; 45° mutation angle; 24-cm field of view; number of excitations, 1.0; and matrix, 256×256 [192 phase-encoding steps]$\times 124$). Voxel (volume of pixel) dimensions were $0.9375 \times 0.9375 \times 1.5$ mm. Data were formatted in the coronal plane and analyzed as 124 coronal, 1.5-mm-thick slices. This protocol was used for measuring the FG because the coronal plane offers excellent visualization of the FG. The second acquisition sequence resulted in an axial series of contiguous double-echo (proton-density and T2-weighted) images (repetition time, 3000 milliseconds; echo time, 30 and 80 milliseconds; 24-cm field of view; and interleaved acquisition with 3-mm slice thickness). Voxel dimensions were $0.9375 \times 0.9375 \times 3.0$ mm. The latter pulse sequence was used to evaluate total intracranial content (ICC). An anisotropic diffusion filter ($k=13$ for SPGR and 90 for proton-density and T2-weighted images; iteration, 3)[38] was applied to the images to reduce noise before processing each set of scans. The intensity information from the SPGR and T2-weighted images was then used in a fully automated segmentation program to classify tissue into gray matter, white matter, and cerebrospinal fluid. An iterative expectation maximization algorithm was used initially to estimate image intensity inhomogeneities, apply intensity corrections based on these estimates, and then classify tissue based on the same set of signal intensity parameters for all participants

©2002 American Medical Association. All rights reserved.
Downloaded From: http://archpsyc.jamanetwork.com/ on 06/01/2016

Table 1. Demographic and Clinical Characteristics of the 3 Study Groups*

	Patients With Schizophrenia (n = 22)	Patients With Affective Psychosis (n = 20)	Control Subjects (n = 24)	F or *t*	df	*P* Value
Age (range), y	26.0 ± 6.9 (18-41)	22.6 ± 5.5 (18-41)	24.0 ± 4.1 (18-35)	1.99	2,63	.15
Sex, M/F, No.	17/5	15/5	21/3	. . .	. . .	. . .
Handedness	0.8 ± 0.2	0.8 ± 0.2	0.8 ± 0.2	1.08	2,63	.90
SES†	3.4 ± 1.3‡	2.8 ± 1.2	2.0 ± 0.8	9.00	2,63	<.001
Parental SES†	2.0 ± 1.0‡	1.6 ± 0.8	1.4 ± 0.8	0.39	2,63	.04
MMSE score	28.1 ± 2.6	28.8 ± 1.5	29.0 ± 1.3	1.21	2,63	.30
WAIS-R score						
Information	19.7 ± 6.0	20.6 ± 4.8	22.7 ± 3.6	1.88	2,63	.16
Digits-forward	8.5 ± 2.2	8.1 ± 2.3	9.9 ± 2.5	3.04	2,63	.06
Digits-backward	6.8 ± 2.7	7.0 ± 2.3	8.3 ± 2.9	1.70	2,63	.19
Age first medicated, y	24.5 ± 7.9	22.7 ± 5.7		0.82	41	.42
Duration of medication use, median (range), mo	1.7 (0-18.8)	0 (0-12.8)				
Medication dose (CPZ equivalent)§	286.0 ± 231.2	203.3 ± 177.1		1.05	41	.30
BPRS total score	38.2 ± 11.2	37.7 ± 11.9		0.14	41	.89
GAS score	35.0 ± 9.1	35.3 ± 13.0		0.75	41	.94

*Data are given as mean ± SD except where indicated otherwise. SES indicates socioeconomic status; MMSE, Mini-Mental State Examination; *WAIS-R, Wechsler Adult Intelligence Scale–Revised*; CPZ, chlorpromazine; BPRS, Brief Psychiatric Rating Scale; and GAS, Global Assessment Scale.

†Higher scores indicate lower SES.

‡Results of post-hoc tests indicated that the schizophrenia group was significantly different from the control group (Tukey Honestly Significant Difference, $P<.05$).

§Patients were administered the following medications during the hospital admission within which the magnetic resonance image scan was acquired: schizophrenia group—n = 1 olanzapine; n = 1 olanzapine and benztropine mesylate; n = 1 olanzapine and divalproex sodium; n = 1 risperidone and benztropine mesylate; n = 4 risperidone, haloperidol, divalproex sodium, and benztropine mesylate; n = 1 risperidone, divalproex sodium, and benztropine mesylate; n = 1 quetiapine fumarate and lithium; n = 1 clozapine, trifluoperazine hydrochloride, and lithium; n = 1 perphenazine; n = 1 perphenazine and benztropine mesylate; n = 1 perphenazine and trazodone hydrochloride; n = 2 perphenazine, divalproex sodium, and benztropine mesylate; n = 2 perphenazine, clozapine, divalproex sodium, and benztropine mesylate; n = 1 haloperidol and benztropine mesylate; n = 1 fluphenazine hydrochloride and benztropine mesylate; n = 1 clonazepam and fluoxetine hydrochloride; and n = 1 (blind to agent because of study) olanzapine or haloperidol; affective psychosis group—n = 1 perphenazine; n = 2 perphenazine and benztropine mesylate; n = 2 perphenazine, divalproex sodium, and benztropine mesylate; n = 2 perphenazine, lithium, and clonazepam; n = 1 perphenazine, clonazepam, and divalproex sodium; n = 1 perphenazine, clonazepam, divalproex sodium, and benztropine mesylate; n = 1 thioridazine hydrochloride and fluoxetine hydrochloride; n = 1 haloperidol, lithium, and benztropine mesylate; n = 1 haloperidol, lithium, and divalproex sodium; n = 1 risperidone, bupropion hydrochloride, and benztropine mesylate; n = 1 risperidone, fluoxetine hydrochloride, and benztropine mesylate; n = 1 olanzapine, thiothixene, and divalproex sodium; n = 1 olanzapine and divalproex sodium; n = 2 quetiapine fumarate, paroxetine hydrochloride, and divalproex sodium; and n = 2 unmedicated.

(ie, one segmentation map was used for all cases).[40] As in previous studies,[28] images were aligned using the line between the anterior and posterior commissures and the sagittal sulcus to correct head tilt, and they were also resampled to make voxels isotropic (sides measured 0.9375 mm). Segmented voxels were used to assist in the manual definition of the regions of interest (ROIs).

DEFINITION OF THE FG

The FG is a spindle-shaped structure that is coextensive with the length of the temporal lobe at a distance lateral to the parahippocampal gyrus.[41] Anatomically, the collateral sulcus forms the medial border of the FG along its entire length. The occipitotemporal sulcus forms the lateral border of the FG along its entire length. In some anatomical definitions, the anterior and posterior transverse collateral sulci are used to define the anterior and posterior FG boundaries.[20,21] However, the anterior and posterior borders are often hard to identify reliably on MRIs, and, consequently, different landmarks have to be used for the segmentation of this structure.

In the present study, we used criteria similar to that of Kim et al,[42] who provided detailed guidelines for FG measurement in the parcellation of the temporal lobe. Drawing for the FG was performed on the coronal plane. It was essential to refer to axial and sagittal orientations for cases in which the borders were ambiguous on coronal slices. The anterior landmark was reliably defined by one slice posterior to the appearance of the mamillary body. The posterior landmark was determined by the anterior tip of the parieto-occipital sulcus in the midsagittal plane. These landmarks were chosen because they were the most reliable for delineating the FG, although small amounts of the anterior and posterior parts of the FG were excluded. This approach prevented erroneous inclusion of parts of another structure in FG measurement. The collateral and occipitotemporal sulci were used to determine the medial and lateral FG borders, respectively. In some cases, these sulci were interrupted or duplicated, particularly in the posterior part near the preoccipital incisura. In these sections, the more laterally located sulcus was used as the border. **Figure 1** shows the FG ROI on a 3-dimensional reconstruction of the ventral surface of the brain and on a coronal slice.

Interrater reliability was computed for the ROIs by 3 independent raters (C.U.L., K.K., and T.O.), who were blind to group membership. Ten cases were selected randomly for interrater reliability. An intraclass correlation coefficient was used to compute interrater reliability for the 3 raters: 0.979 for the left FG and 0.985 for the right FG.

STATISTICAL ANALYSES

We used 1-way analysis of variance to test for group differences in age, SES, parental SES, and basic neuropsychological performance. In addition, *t* tests were used to assess patient group differences in clinical measures, age first medicated, and medication dosage and duration of use. Tests for group differences in ICC were conducted using a 1-way analysis of covariance (ANCOVA), with age and parental SES as covariates.

For ROI analysis, a mixed-model ANCOVA was performed with group (schizophrenia, affective psychosis, or control) as a between-subjects factor and hemisphere (left or right) as a within-subjects factor. Age and parental SES were used as covariates for

©2002 American Medical Association. All rights reserved.
Downloaded From: http://archpsyc.jamanetwork.com/ on 06/01/2016

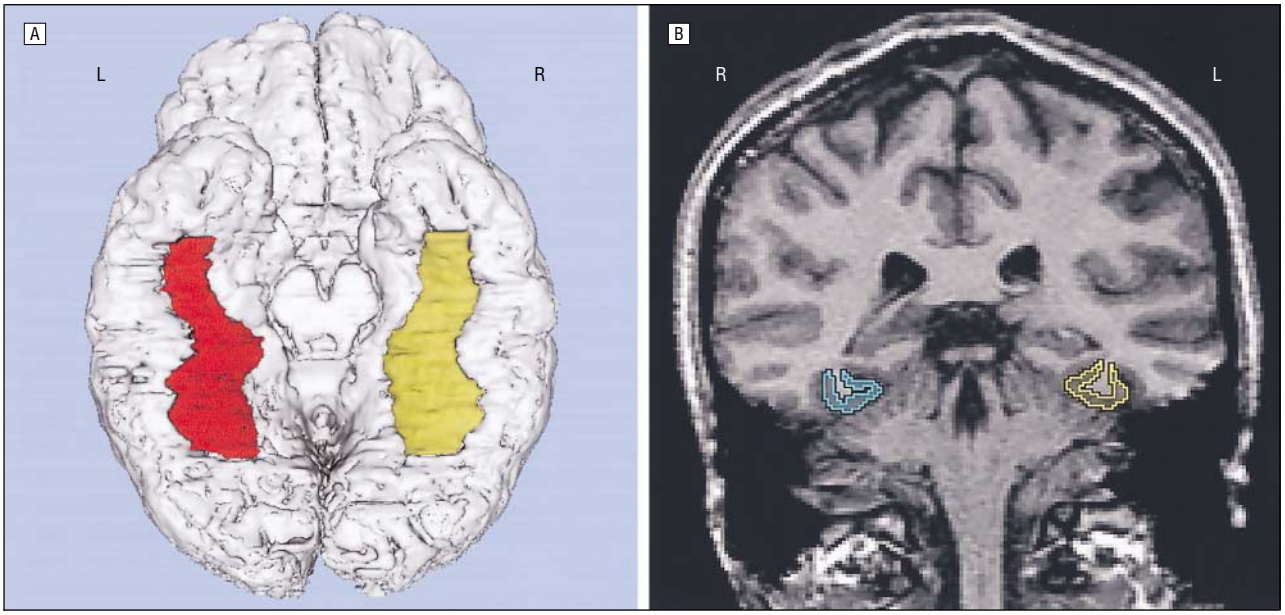

Figure 1. The fusiform gyrus region of interest on a 3-dimensional reconstruction of the ventral surface of the brain (A) and on a coronal slice (B). L indicates left; R, right.

Table 2. Gray Matter Volume of the Fusiform Gyrus in the 3 Study Groups*

	Patients With Schizophrenia (n = 22)	Patients With Affective Psychosis (n = 20)	Control Subjects (n = 24)	F	df	*P* Value
Total ICC	1499.2 ± 120.2	1434.7 ± 149.7†	1555.2 ± 149.9	3.92	2,61	.03
Fusiform gyrus						
Left						
Absolute volume, mL	5.09 ± 0.45	5.44 ± 0.82	5.89 ± 0.73			
Relative volume, %	0.340 ± 0.029‡	0.380 ± 0.034	0.380 ± 0.037	6.63	2,61	.002
Right						
Absolute volume, mL	5.83 ± 0.69	5.88 ± 0.94	6.56 ± 0.91			
Relative volume, %	0.390 ± 0.040	0.409 ± 0.041	0.422 ± 0.044	2.37	2,61	.10

*Data are given as mean ± SD. Statistical significance levels are based on 1-factor analysis of covariance. ICC indicates intracranial contents.

†Results of post-hoc tests indicated that the affective psychosis group was significantly different from the control group (Tukey Honestly Significant Difference, $P<.05$).

‡Results of post-hoc tests indicated that the schizophrenia group was significantly different from the affective psychosis and control groups (Tukey Honestly Significant Difference, $P<.05$).

all ANCOVAs. Follow-up analyses included 2-factor ANCOVA for comparing 2 groups, 1-way ANCOVA for each side, and post hoc Tukey Honestly Significant Difference tests. To correct for potential differences in brain size, we used relative FG volumes, computed as [(absolute FG volume)/(ICC)] × 100. Testing absolute volumes with ICC as a covariate did not change the results reported in the following section. In addition, we reanalyzed the data by excluding all women (leaving 21 controls, 17 patients with first-episode schizophrenia, and 15 with first-episode affective psychosis) and found no meaningful changes in the results. Accordingly, we present findings based on all participants.

Exploratory analyses of the relationship between absolute volumes of the FG and the psychopathologic scales were evaluated using the Spearman ρ to diminish the effect of any outliers. Herein, we conservatively used $P \leq .001$ as the cutoff value for statistical significance, considering the presence of multiple comparisons.

RESULTS

There were no significant group differences in age (Table 1). Patients with first-episode schizophrenia had a significantly lower SES than control subjects, consistent with reduced functioning secondary to their illness. Parental SES was upper middle class or above for all groups, but patients with schizophrenia had a lower parental SES than control subjects. There were no significant differences between patients with schizophrenia and patients with affective psychosis on any of the clinical scales, age first medicated, or medication dosage or duration of use. The age, SES, parental SES, age first medicated, duration of medication use, and dosage (chlorpromazine equivalent) of medication did not correlate with FG volume in the patients. There was a significant difference in ICC volume among the groups (ANCOVA, $F_{2,61}=3.92$; $P=.03$). The ICC volume was smaller in patients with affective psychosis than in the control group (Tukey Honestly Significant Difference, $P<.05$), but there were no significant differences between patients with schizophrenia and the control group or between patients with schizophrenia and those with affective psychosis (**Table 2**).

©2002 American Medical Association. All rights reserved.
Downloaded From: http://archpsyc.jamanetwork.com/ on 06/01/2016

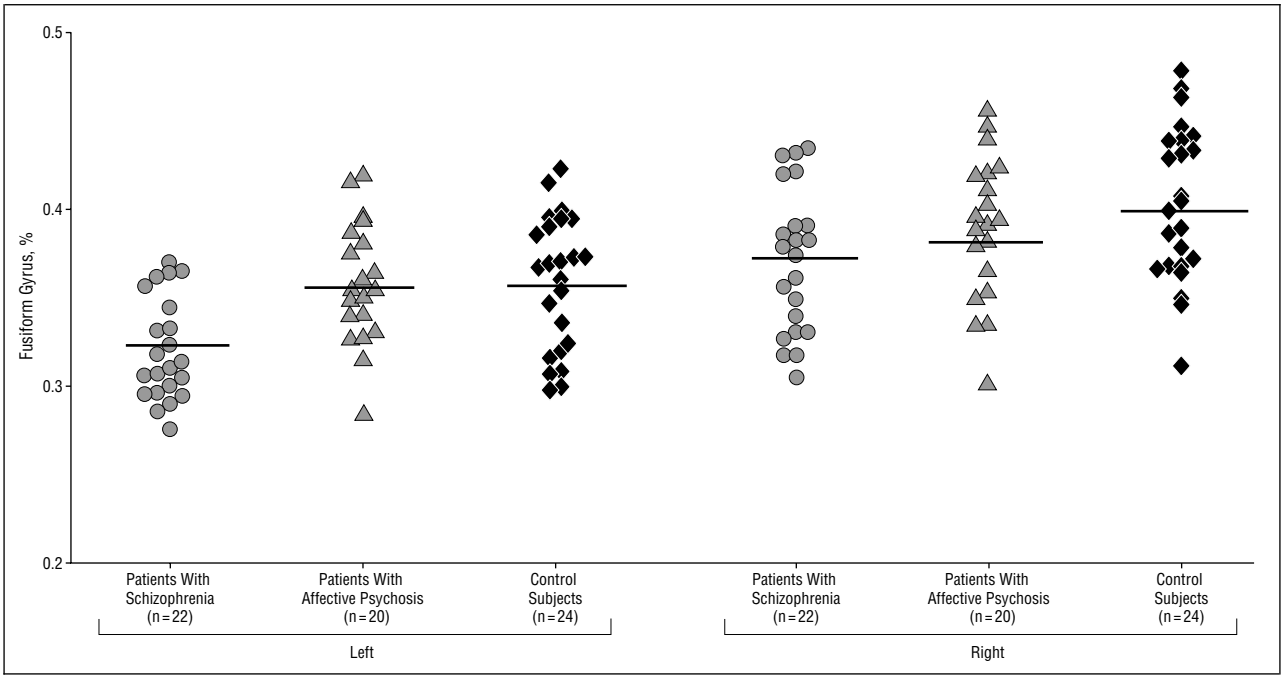

Figure 2. Fusiform gyrus relative volumes for each individual in the 3 study groups. Horizontal bars are means. L indicates left; R, right.

VOLUME OF THE FG

The 2-factor (3 groups × 2 sides) ANCOVA indicated a significant main effect of group ($F_{2,61}$=4.23; P=.02) and a significant main effect of side ($F_{1,61}$=4.82; P=.03) and no group-by-side interaction ($F_{2,61}$=2.42; P=.10). Because we found a significant main effect of group, we performed follow-up ANCOVAs (2 groups × 2 sides) comparing each pair of groups separately. The results revealed that overall FG gray matter volume was significantly smaller in patients with schizophrenia than in those with affective psychosis ($F_{1,38}$=5.16; P=.03) and control subjects ($F_{1,42}$=5.90; P=.02), whereas there were no significant differences between patients with affective psychosis and the control group ($F_{1,40}$=0.80; P=.38). Thus, there was a statistically significant reduced overall FG volume in schizophrenia. The schizophrenia group showed reduced total FG (left+right) volumes of 9% (effect size, 0.93) relative to the control group and 7% (effect size, 0.82) relative to the affective psychosis group (**Figure 2**).

The significant main effect for side by ANCOVA indicates that the right FG was larger than the left FG in all groups. Although there was no group-by-side interaction, we performed follow-up 1-way ANCOVAs in the left and right FGs, separately. The result revealed that the left FG differed among groups ($F_{2,61}$=6.63; P=.002), with the schizophrenia group having significantly smaller volume than the control and affective psychosis groups (Tukey Honestly Significant Difference, P<.05). The schizophrenia group showed gray matter volume reduction of 11% in the left FG compared with the control group (effect size, 1.06) and the same 11% reduction compared with the affective psychosis group (effect size, 1.13). On the other hand, in the right FG, there was no significant difference among groups ($F_{2,61}$=2.37; P=.10). The schizophrenia group showed an 8% smaller gray matter volume difference in the right FG (effect size, 0.74) compared with the control group (Table 2 and Figure 2).

CORRELATION BETWEEN FG VOLUME AND PSYCHOPATHOLOGIC MEASURES

In an exploratory analysis of correlations between FG gray matter volume and psychopathologic measures, we found no statistically significant correlations between FG gray matter volume reduction and factors or items of the Brief Psychiatric Rating Scale in first-episode schizophrenia or in first-episode affective disorder. There also were no statistically significant correlations between FG gray matter volume reduction and Global Assessment Scale scores. In addition, none of the cognitive tests were statistically significantly correlated with FG gray matter volume in this study.

COMMENT

To our knowledge, this is the first MRI study of FG gray matter volume in schizophrenia or affective psychosis and the first to report reduced FG gray matter volume in patients with first-episode schizophrenia. Using high–spatial resolution MRI with 3-dimensional information, we reported bilateral FG gray matter volume reduction in schizophrenia that was statistically significantly smaller than that in patients with affective psychosis and in control subjects. Our results suggest that FG gray matter volume reduction is specific to schizophrenia, as contrasted with affective psychosis. The presence of FG gray matter volume reduction in the course of first-episode schizophrenia suggests that this abnormality is related to schizophrenia and is not a product of the potentially confounding factors of long-term treatment or chronic illness.

The present data are consistent with findings of previous postmortem studies[18,19] in terms of FG abnormali-

©2002 American Medical Association. All rights reserved.
Downloaded From: http://archpsyc.jamanetwork.com/ on 06/01/2016

ties in schizophrenia, although there is some difference in laterality. McDonald et al[19] reported a 13.2% smaller left FG gray matter volume in 31 patients with schizophrenia, whereas there was no volume decrease on the right FG. In addition, these investigators reported a reversal of the normal left>right volume asymmetry in patients with schizophrenia. In the present study, all 3 samples showed larger FG gray matter volumes on the right, suggesting that there is a normal right>left FG asymmetry in all 3 groups. Other structural MRI studies[42,43] in healthy populations also support the right>left FG volume asymmetry, although the postmortem studies did not confirm this finding. Kim and colleagues,[42] in a study that used similar FG measurement methods as our study, reported that the FG is larger in the right hemisphere than in the left in healthy individuals. This discrepancy between postmortem and MRI studies stems in part from different anatomical boundaries and measurements.

Theoretically, it seems plausible that the right>left asymmetry of the FG in right-handed control subjects may be due to the right hemisphere predominance in visuospatial function, including facial recognition processes. But this is conjecture because there is no clear-cut evidence that the larger side need also be the dominant side.[44] Possible FG asymmetry in controls requires further investigation.

With respect to participants in the present study, those with first-episode schizophrenia demonstrated 9% bilateral FG (left, 11%; right, 8%) gray matter volume reduction compared with controls. The percentage reduction on the left was slightly greater than that on the right, a result that is visually evident in Figure 2 as the lower values of the first-episode schizophrenia mean vs the other groups on the left. These data suggest that there may be a slight trend for the schizophrenia group to show a left>right FG gray matter volume reduction, although the absence of a group-by-side interaction in the statistical ANCOVA makes this interpretation a tentative one.

The bilateral FG gray matter volume reduction in the present study is similar to the finding in a previous study[28] of a bilateral Heschl's gyrus gray matter volume reduction in first-episode schizophrenia compared with controls and patients with first-episode affective psychosis. On the other hand, previous studies[28] of first-episode schizophrenia compared with first-episode affective psychosis and control subjects have found left-lateralized volume reduction in schizophrenia of the posterior superior temporal gyrus[27] and planum temporale. These data, and the findings of the present study, suggest that areas not particularly specific for language may show bilateral reduction, whereas language-specific areas with left lateralized functional dominance show more preferential left side reduction.

In the present study, we found that FG gray matter volume reduction was specific to schizophrenia. This finding further supports the results of previous first-episode studies[18,19] that indicate volume reduction in temporal lobe regions (ie, in those studies, the left superior temporal gyrus and left planum temporale, Heschl's gyrus) is specific to schizophrenia relative to affective psychosis. Other investigators also suggest the specificity of MRI abnormalities to schizophrenia compared with affective psychosis. For example, Zipursky et al[45] found regional volume reduction in gray matter in patients with schizophrenia but not in those with bipolar disorder and a decrease in global gray matter volume in schizophrenia. Harvey et al[46] similarly reported a decrease in cortical volume in patients with chronic schizophrenia but not in bipolar patients.

The present first-episode study did not find significant correlations between clinical measures and FG volume reduction. This limitation might be due in part to the instability of symptoms in first-episode psychosis.[18,19,47] However, we believe it is more likely that standard clinical scales, such as those used in the present study, are limited in their ability to measure the functional specificity of face processing ascribed to the FG. Future studies should measure face processing and FG volumes, since, as described at the beginning of this article, there is substantial neuropsychological and behavioral evidence that patients with schizophrenia have deficits in face processing.[9-11]

With respect to ROI methods, we used reliable but arbitrary landmarks because current MRI acquisition protocols do not allow for the definition of anterior and posterior FG boundaries completely and accurately using textbook anatomical criteria. We emphasize that because the boundaries were consistent for all the study groups, we think it is highly unlikely that the small amounts of the anterior and posterior parts of the FG that were excluded in the present study were responsible for group differences. Finally, because of the small numbers of patients and controls, the present study was unable to comment on possible differences according to sex or on volume measures in unipolar depression.

In summary, the overall FG gray matter volume reduction in first-episode schizophrenia, but not in first-episode affective psychosis, suggests that structural abnormalities in this region are specific to schizophrenia and are evident at the time of first hospitalization.

Submitted for publication January 31, 2001; final revision received September 17, 2001; accepted October 12, 2001.

This study was supported in part by grants K02 MH 01110 and R01 MH 50747 (Dr Shenton), R01 MH 40799 (Dr McCarley), and R01RR11747 and IP41PR13218 (Dr Kikinis) from the National Institutes of Health, Bethesda, Md; the Department of Veterans Affairs Merit Awards (Drs Shenton and McCarley) and Middleton Award (Dr McCarley) (Washington, DC); the Welfide Medicinal Research Foundation, Japan (Dr Kasai); and the Uehara Memorial Foundation, Japan (Dr Kasai).

Corresponding authors and reprints: Robert W. McCarley, MD, and Martha E. Shenton, PhD, Department of Psychiatry (116A), VA Boston Healthcare System, Brockton Division, Harvard Medical School, 940 Belmont St, Brockton, MA 02301 (e-mail: robert_mccarley@hms.harvard.edu and martha_shenton@hms.harvard.edu).

REFERENCES

1. McCarthy G, Puce A, Gore JC, Allison T. Face specific processing in the human fusiform gyrus. *J Cognit Neurosci.* 1997;9:605-610.
2. Haxy JV, Horwitz B, Ungerleider LG, Maisog JM, Pietrini P, Grady CL. The functional organization of human extrastriate cortex: a PET-rCBF study of selective attention to faces and locations. *J Neurosci.* 1994;14:6336-6353.
3. Allison T, Ginter H, McCarthy G, Nobre AC, Puce A, Belger A. Face recognition in human extrastriate cortex. *J Neurophysiol.* 1994;71:821-825.

©2002 American Medical Association. All rights reserved.
Downloaded From: http://archpsyc.jamanetwork.com/ on 06/01/2016

4. Kanwisher N, Stanley D, Harris A. The fusiform face area is selective for faces not animals. *Neuroreport.* 1999;10:183-187.
5. Allison T, Puce A, Spencer DD, McCarthy G. Electrophysiological studies of human face perception, I: potentials generated in occipitotemporal cortex by face and non-face stimuli. *Cereb Cortex.* 1999;9:415-430.
6. Kanwisher N, McDermott J, Chun MM. The fusiform face area: a module in human extrastriate cortex specialized for face perception. *J Neurosci.* 1997;17: 4302-4311.
7. Damasio A, Damasio H, Van Hoesen GW. Prosopagnosia: anatomic basis and behavioral mechanisms. *Neurology.* 1982;32:331-341.
8. De Renzi E. Prosopagnosia. In: Feinberg TE, Farah MJ, eds. *Behavioral Neurology and Neuropsychology.* New York, NY: McGraw-Hill Co; 1997:245-255.
9. Walker E, McGuire M, Bettes B. Recognition and identification of facial stimuli by schizophrenics and patients with affective disorders. *Br J Clin Psychol.* 1984; 23:37-44.
10. Williams LM, Loughland CM, Gordon E, Davidson D. Visual scan paths in schizophrenia: is there a deficit in face recognition? *Schizophr Res.* 1999;40:189-199.
11. Frith CD, Stevens M, Johnstone EC, Owens DGC, Crow TJ. Integration of schematic faces and other complex objects in schizophrenia. *J Nerv Ment Dis.* 1983; 171:34-39.
12. Phillips ML, David AS. Visual scan paths are abnormal in deluded schizophrenics. *Neuopsychologia.* 1997;35:99-105.
13. Woelwer W, Streit M, Polzer U, Gaebel W. Facial affect recognition in the course of schizophrenia. *Eur Arch Psychiatry Clin Neurosci.* 1996;3:165-170.
14. Streit M, Woelwer W, Gaebel W. Facial-affect recognition and visual scanning behavior in the course of schizophrenia. *Schizophr Res.* 1997;24:311-317.
15. Phillips ML, David AS. Facial processing in schizophrenia and delusional misidentification: cognitive neuropsychiatric approaches. *Schizophr Res.* 1995;17: 109-114.
16. Young AW, Ellis HD, Szulecka TK, De Paul KW. Face processing impairments and delusional misidentification. *Behav Neurol.* 1990;3:153-168.
17. Hudson AJ, Grace GM. Misidentification syndromes related to face-specific area in the fusiform gyrus. *J Neurol Neurosurg Psychiatry.* 2000;69:645-648.
18. Highley JR, McDonald B, Walker MA, Esiri MM, Crow TJ. Schizophrenia and temporal lobe asymmetry: a post-mortem stereological study of tissue volume. *Br J Psychiatry.* 1999;175:127-134.
19. McDonald B, Highley JR, Walker MA, Esiri MM, Crow TJ. Anomalous asymmetry of fusiform and parahippocampal gyrus grey matter in schizophrenia: a post-mortem study. *Am J Psychiatry.* 2000;157:40-47.
20. Ono M, Kubik S, Abernathey CD. *Atlas of the Cerebral Sulci.* New York, NY: Georg Thieme Verlag; 1990.
21. Naidich TP, Daniels DL, Haughton VM, Williams A, Pojunas K, Palacios E. Hippocampal formation and related structures of the limbic lobe: anatomic-MR correlation. *Radiology.* 1987;162:747-754.
22. Xu Y, Jack CR, O'Brien PC, Kokmen E, Smith GE, Ivnik RJ, Boeve BF, Tangalos RG, Petersen RC. Usefulness of MRI measures of entorhinal cortex versus hippocampus in AD. *Neurology.* 2000;54:1760-1767.
23. McCarley RW, Wible CG, Frumin M, Hirayasu Y, Levitt JJ, Fischer IA, Shenton ME. MRI anatomy of schizophrenia. *Biol Psychiatry.* 1999;45:1099-1119.
24. Lawrie SM, Abukmeil SS. Brain abnormality in schizophrenia: a systematic and quantitative review of volumetric magnetic resonance imaging studies. *Br J Psychiatry.* 1998;172:110-120.
25. Shenton ME, Kikinis R, Jolesz FA, Pollak SD, LeMay M, Wible CG, Hokama H, Martin J, Metcalf D, Coleman M, McCarley RW. Abnormalities of the left temporal lobe and thought disorder in schizophrenia: a quantitative magnetic resonance imaging study. *N Engl J Med.* 1992;327:604-612.
26. Crow TJ. The two-syndrome concept: origins and current status. *Schizophr Bull.* 1985;11:471-486.
27. Hirayasu Y, Shenton ME, Salisbury DF, Dickey CC, Fisher IA, Mazzoni P, Kisler T, Aarakaki H, Kwon JS, Anderson JE, Yurgelun-Todd D, Tohen M, McCarley RW. Lower left temporal lobe MR volumes in patients with first-episode schizophrenia compared with psychotic patients with first-episode affective disorder and normal subjects. *Am J Psychiatry.* 1998;155:1384-1391.
28. Hirayasu Y, McCarley RW, Salisbury DF, Tanaka S, Kwon JS, Frumin M, Snyderman D, Yurgelun-Todd D, Kikinis R, Jolesz FA, Shenton ME. Planum temporale and Heschl gyrus volume reduction in schizophrenia. *Arch Gen Psychiatry.* 2000;57:692-699.
29. Oldfield RC. The assessment and analysis of handedness: the Edinburgh inventory. *Neuropsychologia.* 1971;9:97-113.
30. Spitzer RL, Williams JBW, Gibbson M, First M. *The Structured Clinical Interview for DSM-III-R (SCID-NP), Non-Patient Edition.* Washington, DC: American Psychiatric Association; 1990.
31. Spitzer RL, Williams JBW, Gibbson M, First M. *The Structured Clinical Interview for DSM-III-R (SCID-II), Personality Disorder.* Washington, DC: American Psychiatric Association; 1990.
32. Spitzer RL, Williams JBW, Gibbson M, First M. *The Structured Clinical Interview for DSM-III-R (SCID).* Washington, DC: American Psychiatric Association; 1990.
33. Overall JE, Gorham DR. The Brief Psychiatric Rating Scale. *Psychol Rep.* 1962; 10:799- 812.
34. Endicott J, Spitzer RL, Fleiss JL, Cohen J. The Global Asessment Scale: a procedure for measuring overall severity of psychiatric disturbance. *Arch Gen Psychiatry.* 1976;33:766-771.
35. Folstein MF, Folstein SE, McHugh PR. "Mini-Mental State": a practical method for grading the cognitive state of patients for the clinician. *J Psychiatr Res.* 1975; 12:189-198.
36. Wechsler D.*Wechsler Adult Intelligence Scale–Revised.* New York, NY: Harcourt Brace Jovanovich Inc; 1981.
37. Hollingshead AB. *Two Factor Index of Social Position.* New Haven, Conn: Yale University Press; 1965.
38. Shenton ME, Kikinis R, McCarley RW, Metcalf D, Tieman J, Jolesz FA. Application of automated MRI volumetric measurement techniques to the ventricular system in schizophrenics and normal controls. *Schizophr Res.* 1991;5:103-113.
39. Kikinis R, Jolesz FA, Gerig G. 3D morphometric and morphometric information derived from clinical brain MR images. In: Hohne KH, Fuchs H, Pizer SM, eds. *3-D Imaging in Medicine.* Berlin, Germany: Springer-Verlag; 1990:441-454.
40. Wible CG, Shenton ME, Hokama H, Kikinis R, Jolesz FA, Metcalf D, McCarley RW. Prefrontal cortex and schizophrenia: a quantitative magnetic resonance imaging study. *Arch Gen Psychiatry.* 1995;52:279-288.
41. Duvernoy HM, Guyot J, Cabanis EA, Iba-Zizen MT, Tamraz J. *The Human Brain: Surface, Three-dimensional Sectional Anatomy and MRI.* New York: Springer-Verlag NY Inc; 1991.
42. Kim JJ, Crespo-Facorro B, Andreasen NC, O'Leary D, Zhang B, Harris G, Magnotta VA. An MRI-based parcellation method for the temporal lobe. *Neuroimage.* 2000;11:271-288.
43. Kennedy DN, Lange N, Makris N, Bates J, Meyer J, Caviness VS Jr. Gyri of the human neocortex: an MRI-based analysis of volume and variance. *Cereb Cortex.* 1998;8:372-384.
44. Davidson RJ, Hugdahl K. *Brain Asymmetry.* Cambridge, Mass: MIT Press; 1995.
45. Zipursky RB, Seeman MV, Bury A, Langevin R, Wortzman G, Katz R. Deficits in gray matter volume are present in schizophrenia but not bipolar disorder. *Schizophr Res.* 1997;26:85-92.
46. Harvey I, Persaud R, Ron MA, Baker G, Murray RM. Volumetric MRI measurements in bipolars compared with schizophrenics and healthy controls. *Psychol Med.* 1994;24:689-699.
47. Kwon JS, McCarley RW, Hirayasu Y, Anderson JE, Fischer IA, Kikinis R, Jolesz FA, Shenton ME. Left planum temporale volume reduction in schizophrenia. *Arch Gen Psychiatry.* 1999;56:142-148.

©2002 American Medical Association. All rights reserved.
Downloaded From: http://archpsyc.jamanetwork.com/ on 06/01/2016