ORIGINAL ARTICLE

Capsulotomy for Obsessive-Compulsive Disorder

Long-term Follow-up of 25 Patients

Christian Rück, MD, PhD; Andreas Karlsson, MS; J. Douglas Steele, MD, PhD, MRCPsych; Gunnar Edman, PhD; Björn A. Meyerson, MD, PhD; Kaj Ericson, MD, PhD; Håkan Nyman, PhD; Marie Åsberg, MD, PhD; Pär Svanborg, MD, PhD

Context: Capsulotomy is sometimes used as a treatment of last resort in severe and treatment-refractory cases of obsessive-compulsive disorder (OCD).

Objective: To evaluate the long-term efficacy and safety of capsulotomy in OCD.

Design: Noncontrolled, long-term follow-up trial (mean of 10.9 years after surgery).

Setting: University hospital referral center.

Patients: Twenty-five consecutive patients with OCD who underwent capsulotomy from 1988 to 2000.

Intervention: Unilateral or bilateral capsulotomy. Lesions were created by means of radiofrequency heating (thermocapsulotomy) or gamma radiation (radiosurgery, gammacapsulotomy).

Main Outcome Measure: Yale-Brown Obsessive-Compulsive Rating Scale (Y-BOCS) score.

Results: The mean Y-BOCS score was 34 preoperatively and 18 at long-term follow-up ($P<.001$). Response (defined as ≥35% reduction at long-term follow-up compared with baseline) was seen in 12 patients at long-term follow-up. Nine patients were in remission (Y-BOCS score, <16) at long-term follow-up. Only 3 patients were in remission without adverse effects at long-term follow-up. Response rates did not differ significantly between surgical methods. A mean weight gain of 6 kg was reported in the first postoperative year. Ten patients were considered to have significant problems with executive functioning, apathy, or disinhibition. Six of these 10 patients had received high doses of radiation or had undergone multiple surgical procedures. Results of our magnetic resonance imaging analysis in 11 patients suggest that the OCD symptom reduction may be increased by reducing the lateral extension of the lesions, and a reduction in the medial and posterior extension may limit the risk of adverse effects (ie, smaller lesions may produce better results).

Conclusions: Capsulotomy is effective in reducing OCD symptoms. There is a substantial risk of adverse effects, and the risk may vary between surgical methods. Our findings suggest that smaller lesions are safer and that high radiation doses and multiple procedures should be avoided.

Arch Gen Psychiatry. 2008;65(8):914-922

Author Affiliations: Sections of Psychiatry (Drs Rück, Nyman, Åsberg, and Svanborg and Mr Karlsson), Neurosurgery (Dr Meyerson), and Neuroradiology (Dr Ericson), Department of Clinical Neuroscience, Karolinska Institutet, Stockholm, Sweden; Department of Social Sciences, Mid Sweden University, Östersund (Mr Karlsson); Department of Mental Health, University of Aberdeen, Aberdeen, Scotland (Dr Steele); and Department of Psychiatry, Danderyd Hospital, Danderyd, Sweden (Dr Edman).

At least 30% to 40% of patients with obsessive-compulsive disorder (OCD) fail to respond to first-line pharmacological or psychotherapeutic treatments.[1-3] For treatment-refractory OCD (a current definition is found in Husted and Shapira[1]), neurosurgery for mental disorders (NMD), such as capsulotomy and cingulotomy,[4] is sometimes used. In capsulotomy, lesions are placed in the anterior limb of the internal capsules, whereas lesions in cingulotomy are placed bilaterally in the anterior cingulate gyri. The neurophysiological features of OCD have been reported to include hyperactivity in the orbitofrontal cortex, anterior cingulate cortex, and caudate nucleus,[5,6] all part of the corticostriatal circuit, the target of most NMD procedures. The capsulotomy lesions created by the use of radiofrequency heating (thermocapsulotomy) or gamma radiation (gammacapsulotomy) involve fibers connecting the mediodorsal thalamus and the prefrontal cortex,[7] whereas cingulotomy lesions affect the anterior cingulate cortex and fibers of the cingulum. The same target that is ablated in capsulotomy has also been the target of chronic electric stimulation such as deep brain stimulation,[1,8] a reversible technique because the stimulation can be turned off. The efficacy and safety of NMD has been a source of recurring controversy,[9] but OCD has remained an indication. The evidence of the efficacy of capsulotomy in OCD is based on a number of case series[10-13] reporting

©2008 American Medical Association. All rights reserved.
Downloaded From: http://archpsyc.jamanetwork.com/ on 04/01/2015

significant improvement in 53% to 73% of patients.[14,15] It is important to point out that results from a certain NMD procedure (eg, capsulotomy) are not directly applicable to other forms of NMD (eg, cingulotomy).

Few studies have systematically assessed adverse effects after capsulotomy. Of the 18 patients with OCD in a study from 1961 by Herner,[11] 1 patient had severe, 2 had moderate, and 7 had mild adverse effects. The most common adverse effects were emotional blunting, indifference, low initiative, fatigue, and urinary incontinence. Other capsulotomy studies[10,16,17] have reported no or very few adverse effects. For cingulotomy a number of recent studies[4,18,19] have demonstrated the relative safety of the procedure. The short-term outcome of 24 patients undergoing capsulotomy was presented by Mindus.[20] Amelioration was reported in symptom severity and social functioning. However, at the 1-year follow-up, 7 patients reported fatigue, 4 reported poor memory, 2 felt more talkative, and 2 reported carelessness. In a recent study,[13] 1 of 15 patients had a permanent behavior disorder after postoperative brain edema, but the other 14 did not have any permanent adverse effects, and the study therefore indicates that the procedure is relatively safe. Data[21-23] were recently published on the long-term outcome of 26 patients who had an anxiety disorder but not OCD as their primary diagnosis and who had undergone thermocapsulotomy at our center. The results showed good anxiolytic efficacy, but the procedure was accompanied by substantial adverse effects such as apathy and executive dysfunction in 7 patients. That led us to design the present study to address the following questions:

- Is capsulotomy effective in reducing OCD symptoms?
- Is capsulotomy safe in patients with OCD?
- Is the outcome related to lesion characteristics?

METHODS

PATIENTS

All 25 patients with OCD (14 women and 11 men) who underwent capsulotomy from 1988 to 2000 at the Karolinska University Hospital in Stockholm were included in this study. The mean age at first capsulotomy was 41 (SD, 11; range 25-68) years, and the mean duration of illness at the time of surgery was 21 (SD, 8; range, 8-40) years. The mean age at long-term follow-up was 52 (SD, 12; range, 33-83) years. The highest level of preoperative education was elementary school in 5 patients, high school in 14, and university in 6. At the time of surgery, 3 patients were gainfully employed.

The preoperative *DSM-III-R* or *DSM-IV* diagnostic criteria for OCD were systematically assessed on the basis of a semistructured interview (n=16) or the Structured Clinical Interview for *DSM* Axis I Disorders[24] (n=9). Comorbidity at the time of surgery included obsessive-compulsive personality disorder (n=5), avoidant personality disorder (n=1), depressive personality disorder (n=2), depression (n=5), specific phobia (n=3), tic disorder (n=3), panic disorder with agoraphobia (n=3), social phobia (n=2), and generalized anxiety disorder (n=1).

Inclusion criteria for capsulotomy were chronic OCD (duration of ≥5 years) causing substantial suffering and significant reduction in functioning.[25,26] Current psychological and pharmacological treatment options had to have been tried systematically for at least 5 years without substantial effect. We analyzed the inclusion criteria post hoc. Twelve patients had not received preoperative cognitive behavioral therapy. This is largely explained by the limited access to cognitive behavioral therapy in certain areas at the time. Two patients were not considered to have OCD that was pharmacologically treatment refractory because they had received only clomipramine hydrochloride preoperatively.

All patients underwent face-to-face assessment at long-term follow-up, except for 2 who had died. Thus, 23 patients were available for long-term follow-up. Relatives of all but 2 of the patients who were alive at long-term follow-up were also interviewed. A small number of patients in the present study have been included in previous reports of magnetic resonance imaging (MRI),[12] neuropsychology,[27] and personality findings.[28]

The study was approved by the local ethics vetting board at the Karolinska Institutet. After a detailed description of the study was given to the subjects, written informed consent was obtained.

SURGICAL TECHNIQUE

Capsulotomy had been performed by means of radiofrequency thermolesions or radiosurgery, to which the patients had been assigned without any systematic randomization. The target was located 19 to 21 mm anterior to the anterior commissure on the intercommissural line. This approximately corresponded to the middle portion of the capsules at the level of the posterior part of the medial putamen border as visualized on stereotactic MRIs. Thermocapsulotomy is conventional stereotactic surgery where lesions were produced using a monopolar electrode with a diameter of 1.5 mm and a 10-mm bare tip that heats to 60°C. The intended height of the lesions was 12 to 20 mm. Gammacapsulotomy was performed using different models of the Leksell Gamma Knife unit (Elekta Instruments AB, Stockholm). Lesions are produced (without opening the skull) by converging beams of gamma radiation. Round, 4-mm collimators were selected, and doses of 160 to 200 Gy were applied (to convert radiology doses to rads, multiply value in grays by 100). The surgical details are presented in **Table 1**. Twelve patients underwent bilateral thermocapsulotomy and 9 underwent a bilateral gammacapsulotomy (radiosurgery). Four patients had a unilateral right-sided thermocapsulotomy. Five patients received 200 Gy in 3 isocenters bilaterally and were subjected to higher doses of radiation than would be recommended in hindsight.[29,30] One patient had been subjected to a trial of deep brain stimulation before the bilateral thermocapsulotomy, to our knowledge the first patient with OCD to undergo such treatment. In 7 patients with unsatisfactory outcomes, additional operations were performed to enlarge the lesions to include the ventral portion of the capsule in the same anteroposterior plane.

FOLLOW-UP ASSESSMENTS

Short- (1 year after the first surgical procedure) and long-term (mean, 10.9 years after the first surgical procedure [SD, 3.8; SE, 0.8; range, 4-17]) assessments were compared with preoperative data. One of us (C.R.) who had not been involved in patient selection and postoperative care conducted the long-term follow-up interviews from 2002 to 2006.

Primary Efficacy Variable

The Yale-Brown Obsessive-Compulsive Scale (Y-BOCS)[31] was used to rate OCD severity. Response was defined as at least a 35% reduction in Y-BOCS score from baseline, and remission was defined as a Y-BOCS score of no more than 16.[32] In 1 case the preoperative rating was missing, and in 8 patients the preoperative rating was performed retrospectively at the 1-year follow-up using all available sources such as audio recordings of the preoperative interview and medical records.

©2008 American Medical Association. All rights reserved.
Downloaded From: http://archpsyc.jamanetwork.com/ on 04/01/2015

Table 1. Characteristics and Outcome Data of Individual Patients

Patient No.	Age at Surgery, y	Age at LT FU, y	Surgical Capsulotomy Method[a] (Intervention[b])	Reoperation[a]	Y-BOCS Score			EAD Scores			
					Preop	1-y FU	LT FU	E	A	D	Total
4	43	56	Bilateral gamma (200 Gy × 3)	. . .	28	19	24	0	1	0	1
10	43	55	Bilateral gamma (200 Gy × 3)	. . .	36	NA	5	2	2	0	4
17	57	64	Bilateral gamma (180 Gy × 1)	. . .	38	35	28	0	0	0	0
18	68	83	Bilateral gamma (200 Gy × 3)	. . .	35	1	1	0	0	2	2
20	46	61	Bilateral gamma (200 Gy × 3)	. . .	27	9	15	2	2	0	4
23	26	38	Bilateral gamma (200 Gy × 3)	. . .	33	0	1	2	0	3	5
19	45	Died	Bilateral gamma (180 Gy × 1)	Bilateral gamma	39	35	NA	NA	NA	NA	NA
11	34	42	Bilateral gamma (180 Gy × 1)	Bilateral gamma (160 Gy × 1)	30	12	9	1	2	1	4
9	33	44	Bilateral gamma (180 Gy × 1)	Bilateral thermo, unilateral thermo	35	25	31	0	0	0	0
1	36	49	Bilateral thermo (20 mm)	. . .	31	8	18	2	0	1	3
3	46	63	Bilateral thermo (20 mm)	. . .	37	25	18	0	2	1	3
5	37	49	Bilateral thermo (20 mm)	. . .	30	0	0	2	1	3	6
12	26	40	Bilateral thermo (18 mm)	. . .	37	19	25	0	0	1	1
16	53	62	Bilateral thermo (20 mm)	. . .	32	29	29	0	2	0	2
21	49	65	Bilateral thermo (16 mm)	. . .	32	14	6	1	0	2	3
22	28	43	Bilateral thermo (14 mm)	. . .	38	21	25	0	0	0	0
24	35	41	Bilateral thermo (12 mm)	. . .	33	27	24	0	1	0	1
25	53	64	Bilateral thermo (18 mm)	. . .	33	NA	10	0	0	0	0
7	38	50	Bilateral thermo (20 mm)	Bilateral thermo	35	33	31	2	0	2	4
8	49	53	Bilateral thermo (16 mm)	Bilateral thermo	35	14	35	3	3	0	6
2	32	45	Bilateral thermo (18 mm)	Unilateral thermo + cingulotomy	NA	NA	25	0	0	0	0
6	25	33	Unilateral thermo (18 mm)	. . .	30	32	19	0	0	0	0
14	35	39	Unilateral thermo (18 mm)	. . .	38	20	37	1	0	0	1
15	52	56	Unilateral thermo (18 mm)	. . .	35	2	2	0	0	0	0
13	29	Died	Unilateral thermo (15 mm)	Unilateral thermo	38	35	NA	NA	NA	NA	NA

Abbreviations: EAD, Execution, Apathy, and Disinhibition Scale; FU, follow-up; gamma, gammacapsulotomy (radiosurgery); LT FU, long-term FU; NA, not applicable; preop, preoperative; thermo, thermocapsulotomy; Y-BOCS, Yale-Brown Obsessive-Compulsive Scale; ellipses, no reoperation.

SI conversion factor: To convert radiation doses to rads, multiply value in grays by 100.

[a] All unilateral procedures were right sided.

[b] For patients undergoing bilateral gamma, radiation dose is given as the dose times the number of isocenters; for patients undergoing thermo, the intended lesion height is given.

Secondary Efficacy Variables

Anxiety and Depression Ratings. The Montgomery-Åsberg Depression Rating Scale[33] and the Brief Scale for Anxiety[34] are 10-item rating scales (0-6) for measuring depression and anxiety symptoms, respectively.

Measures of Improvement, Impairment, and Global Functioning. Global improvement was measured at long-term follow-up by the investigator-rated Clinical Global Impression–Improvement Scale (CGI-I),[35] where 1 is the best possible outcome (very much improved) and 7 is the worst (very much worse). The Global Assessment of Functioning Scale[36] is a composite measure of current psychological, social, and occupational functioning. Functional impairment was evaluated with the 10-point patient-rated Work, Social Life, and Family Life/Home Responsibilities subscales of the Sheehan Disability Scale[37] (0, none; 1-3, mild; 4-6, moderate; 7-9, marked; and 10, extreme).

Measures of Adverse Effects

In a previous study,[21] we constructed a simple rating scale, the Execution, Apathy, and Disinhibition Scale (EAD Scale) because rating scales such as the Frontal Systems Behavior Scale[38] were not available at that time. The EAD Scale was designed to measure 3 important symptoms that have been postulated to be related to frontal lobe dysfunction, namely, executive dysfunction (E), apathy (A), and disinhibition (D). Severity of symptoms was rated on a 4-point Likert scale (0-3) by 2 of us (C.R. and P.S.) on the basis of all information available, including patient records, videotapes of patient interviews, and interviews with relatives. Consensus was reached for all patients before the scores were entered into the raw data matrix. Patients with a total score of at least 3 were defined as having clinically significant dysfunction. High interrater reliability for the EAD Scale has been shown previously.[21]

Neuropsychology

All patients underwent assessment with a battery of tests sensitive to frontal lobe dysfunction at long-term follow-up. Working memory was assessed with the Wechsler Adult Intelligence Scale–Revised[39] and Wechsler Adult Intelligence Scale–Revised as a Neuropsychological Instrument[40] (Digit Span, Spatial Span, and Letter-Number Sequencing). Executive function was assessed with the Controlled Oral Word Association Test,[41] Wisconsin Card Sorting Test (WCST),[42] and Simplified Six Elements Task.[43] Preoperative and postoperative comparison was possible for 7 patients for whom the WCST and digit span data were available. All neuropsychological results were transformed into T scores.

QUANTITATIVE NEUROIMAGING METHOD

The preoperative computed tomography and MRI findings were unremarkable in all cases. Imaging at long-term follow-up was performed with MRI (1.5-T Signa scanner; GE Healthcare, Wauwatosa, Wisconsin) that included standard imaging se-

©2008 American Medical Association. All rights reserved.
Downloaded From: http://archpsyc.jamanetwork.com/ on 04/01/2015

quences (T1-, proton density–, and T2-weighted images). The section thickness was 5 mm and the intersection gap was 2 mm. Long-term MRI data were available for 11 subjects (5 undergoing bilateral thermocapsulotomy; 4, bilateral gammacapsulotomy; and 2, unilateral right-sided thermocapsulotomy).

The T2-weighted MRIs were converted to Analyze format (available at http://www.mayo.edu/bir/Software/Analyze/AnalyzeTechInfo.html) and spatially normalized[44] to the Montreal Neurological Institute (MNI) Talairach-standardized brain template[45,46] using Statistical Parametric Mapping 2[47] and written using seventh-degree B-spline interpolation to isotropic 1-mm^3 voxel resolution. This automated technique avoided a potential loss in image quality due to spatial normalization. For each subject, we used MRIcro[48] to view the normalized images in transverse section, and the lesion was outlined in each hemisphere, for each 1-mm-thick section and at a 1-mm^2 in-section resolution, forming lesion regions of interest. The rater (J.D.S.) was blinded to clinical outcome. A list of the MNI coordinates of each 1-mm^3 voxel within each 3-dimensional outlined lesion volume was obtained using MRIcro. Specifically, the medial-lateral direction is the x dimension, the anteroposterior direction is the y dimension, and the superior-inferior direction is the z dimension. The origin (0, 0, 0) is the point defined by the intersection of the sagittal plane with the anterior commissure. The average of the coordinates of the voxels making up the lesion is an estimate of the center of mass of the lesion; their total is an estimate of the lesion volume. These measures do not take into account irregularities of shape. One of the simplest ways of doing this is to imagine a roughly ovoid lesion just fitting within a 3-dimensional "bounding box," with parts of the outline of the lesion touching parts of the sides of the box. Therefore, the lesion can be described as extending from the smallest x value (x1L) to the maximum x value (x2L) with an intermediate average x value. The lesion also extends from the smallest y value (y1L) to the maximum y value (y2L) with an intermediate average y value, and similarly for the z dimension, where L refers to a lesion in the left hemisphere. Because the images were spatially normalized, this method automatically corrected each lesion location and volume for between-subject differences in total brain size and orientation.

We tested the following imaging hypotheses. First, that the thermolesion method created different-sized lesions and resulted in different EAD Scale scores compared with the radiolesion method. Second, when pooling all subjects, that (1) the mean (center-of-mass) location of the lesion correlated with the outcome (EAD Scale total score and percentage of Y-BOCS change from baseline to long-term follow-up); (2) the volume of the lesion correlated with the outcome; and (3) the most extreme edge of the lesion correlated with the outcome.

STATISTICAL METHODS

All variables were summarized using standard descriptive statistics (frequency, mean, range, and standard deviation). For approximately normally distributed and continuous variables, statistical analyses were performed using parametric statistics (paired and unpaired, 2-tailed *t* test); otherwise, nonparametric methods (Mann-Whitney test, Wilcoxon rank sum test, and Spearman correlation) were applied. The significance level was 5% (2-tailed).

RESULTS

IS CAPSULOTOMY EFFECTIVE IN REDUCING OCD SYMPTOMS?

Preoperative and postoperative data for the individual patients are presented in Table 1. The main results are displayed for the whole group and separately for different surgical methods and for single vs multiple procedures in **Table 2**. The Y-BOCS, Montgomery-Åsberg Depression Rating Scale, and Brief Scale for Anxiety scores at long-term follow-up were significantly lower than at the 1-year follow-up, indicating stable improvement.

The mean (SD) Global Assessment of Functioning Scale score preoperatively was 42.8 (7.4) (range, 30-55) (n=17) and was nonsignificantly higher (46.8 [9.9]; range, 33-75) (n=23) at long-term follow-up (Table 2). The mean CGI-I score at long-term follow-up was 2.6 (SD, 1.2; range, 1-6) (n=23), indicating minimal to much improvement. The preoperative mean score for the patient-rated Sheehan Disability Scale Work subscale was 8.7 (SD, 2.6; range, 1-10); for the Social Life subscale, 9.5 (SD, 0.9; range; 7-10); and for the Family Life subscale, 8.5 (SD, 2.1; range, 2-10) (n=24). At long-term follow-up, the mean score for the Work subscale had dropped to 7.3 (SD, 3.4; range, 0-10) (n=23) (P=.10); the mean score for the Social Life subscale had dropped significantly to 5.3 (SD, 3.4; range, 0-10) (z=3.7; $P<.001$); and the mean score for the Family Life subscale was significantly lower at 4.7 (SD, 3.3; range, 0-10) (z=3.5; $P<.001$). In sum, patients rated their social and family life functioning as improved but their working life functioning as unchanged. None of the patients were employed at the time of long-term follow-up. All of the patients had received pharmacological treatment postoperatively. Seventeen of the 23 patients were receiving daily OCD medication at long-term follow-up.

IS CAPSULOTOMY SAFE?

Nine patients had made a suicide attempt before surgery. Seven patients had made at least 1 suicide attempt postoperatively, including 1 who completed suicide, but 4 of these made their first suicide attempt after surgery. One patient had died of homicide before the long-term follow-up. Both deceased patients had undergone multiple surgical procedures.

Neurosurgical Complications

One of the 9 patients undergoing radiosurgery (patient 20) developed a right-sided radiation necrosis with subsequent apathy, memory problems, and executive dysfunction. Another (patient 10) developed a brain edema that reached its peak size 1 year after surgery; the patient was hospitalized with symptoms of apathy, incontinence, and seizures. At long-term follow-up, urinary incontinence, apathy, and executive problems persisted. In both cases, complications may have been caused by too high a radiation dose. Another patient who underwent multiple thermocapsulotomies (patient 8) had persistent urinary incontinence at long-term follow-up.

Weight Gain

The mean preoperative weight was 69.8 (SD, 20.5; range, 47-120) kg (n=25). At the 1-year follow-up, the mean weight was 76.0 (SD, 24.4; range, 47-146) kg (n=24), a significant increase from baseline (z=3.4; $P<.001$). Long-term mean weight was 81.0 (SD, 25.0; range, 50-140) kg (n=22).

©2008 American Medical Association. All rights reserved.
Downloaded From: http://archpsyc.jamanetwork.com/ on 04/01/2015

Table 2. Results Grouped After Surgical Method[a]

	All Patients (N=25)	Bilateral Thermo (n=12)	Bilateral Gamma (n=9)	Unilateral Thermo (n=4)	Single Procedure (n=18)	Multiple Procedures (n=7)
Y-BOCS score						
Preop (n=24)	34.0 (3.4) [27-39]	33.9 (2.7) [30-38]	33.4 (4.2) [27-39]	35.2 (3.7) [30-38]	33.5 (3.4) [27-38]	35.3 (3.1) [30-39]
1-y FU (n=22)	18.9 (12.0) [0-35][b]	19.0 (10.2) [0-33][b]	17.0 (13.9) [0-35][c]	22.2 (15.0) [2-35]	16.3 (11.8) [0-35][b]	25.7 (10.5) [12-35][c]
LT FU (n=23)	18.2 (11.8) [0-37][b]	20.5 (10.5) [0-35][b]	14.2 (12.1) [1-31][c]	19.3 (17.5) [2-37]	15.9 (11.4) [0-37][b]	26.2 (10.2) [9-35]
MADRS						
Preop (n=25)	21.3 (7.7) [6-36]	20.9 (8.8) [6-33]	20.1 (5.8) [13-27]	25.0 (8.7) [17-36]	20.1 (7.9) [6-33]	24.3 (6.6) [17-36]
1-y FU (n=25)	12.6 (8.6) [0-31][b]	11.4 (8.1) [0-27][c]	12.4 (8.5) [3-31][c]	16.8 (11.3) [3-26]	10.8 (8.3) [0-31][d]	17.3 (8.1) [6-27]
LT FU (n=23)	9.4 (5.6) [0-18][b]	10.1 (5.4) [0-18][d]	7.2 (6.3) [0-18][c]	12.3 (3.1) [9-15]	8.8 (5.4) [0-18][b]	11.8 (6.2) [5-18][c]
BSA						
Preop (n=24)	18.0 (6.6) [6-29]	15.8 (6.5) [6-29]	21.3 (4.4) [15-28]	17.3 (10.1) [11-29]	16.7 (6.3) [6-28]	21.3 (6.4) [11-29]
1-y FU (n=25)	8.8 (6.0) [0-19][b]	8.9 (6.2) [0-18][d]	8.9 (6.3) [0-19][d]	8.0 (5.9) [0-14]	8.1 (6.1) [0-19][d]	10.4 (5.6) [1-17][c]
LT FU (n=23)	9.7 (5.3) [0-18][b]	10.9 (5.3) [3-17]	7.4 (5.7) [0-18][c]	11.0 (1.7) [9-12]	9.9 (5.6) [0-18][c]	9.0 (3.5) [4-13][c]
GAF						
Preop (n=17)	42.8 (7.4) [30-55]	44.5 (7.1) [35-55]	44.3 (7.6) [31-50]	37.2 (6.1) [30-44]	42.4 (7.6) [30-55]	43.8 (7.5) [35-50]
LT FU (n=23)	46.8 (9.9) [33-75]	47,2 (8.7) [35-60]	47.5 (13.1) [33-75]	41.7 (7.6) [35-50]	46.8 (10.9) [33-75]	46.0 (7.4) [35-55]
Response at LT FU, No. of patients	12/22	5/12	5/9	2/3	11/18	1/5
Remission at LT FU, No. of patients	9/22	3/12	5/9	1/3	7/18	1/5
CGI-I (n=23)	2.6 (1.2) [1-6]	2.8 (1.3) [2-6]	2.4 (1.1) [1-4]	2.7 (0.6) [2-3]	2.5 (1.1) [1-6]	3.0 (1.4) [1-4]
EAD Scale (n=23)	2.2 (2.0) [0-6]	2.4 (2.1) [0-6]	2.5 (2.0) [0-5]	0.3 (0.6) [0-1]	2.0 (1.9) [0-6]	2.8 (2.7) [0-6]
Total EAD Scale score ≥3, No./total No. of patients	10/23	6/12	4/8	0/3	7/18	3/5

Abbreviations: Bilateral Gamma, bilateral gammacapsulotomy (radiosurgery); Bilateral Thermo, bilateral thermocapsulotomy; BSA, Brief Scale of Anxiety; CGI-I, Clinical Global Impression–Improvement Scale; EAD Scale, Execution, Apathy, and Disinhibition Scale; FU, follow-up; GAF, Global Assessment of Functioning Scale; LT FU, long-term FU; MADRS, Montgomery-Åsberg Depression Rating Scale; preop, preoperative; Unilateral Thermo, right-sided unilateral thermocapsulotomy; Y-BOCS, Yale-Brown Obsessive-Compulsive Scale.

[a] Significance test results are all related to baseline (preop) data. Unless otherwise indicated, data are expressed as mean (SD) [range].

[b] $P < .001$.

[c] $P < .05$.

[d] $P < .01$.

Sexual Disinhibition

One man who underwent thermocapsulotomy (patient 5) was severely sexually disinhibited immediately after surgery and was subsequently convicted of rape 5 months postoperatively. The disinhibition partly remitted, but the patient's functioning was still impaired at long-term follow-up, owing to, among other things, substance abuse that developed after surgery. In a woman (patient 23), the disinhibition had resulted in job loss and severely impaired her social functioning. This patient had undergone a radiosurgical procedure with high radiation doses (200 Gy in 3 isocenters). Patients and their relatives were interviewed for signs of disinhibition preoperatively and at long-term follow-up, and there were no such signs before surgery.

EAD Scale

Individual scores are presented in Table 1, whereas data for each surgical method are displayed in Table 2. Ten of 23 patients examined at long-term follow-up had a total EAD score of at least 3 and were consequently rated as having significant clinical symptoms indicating frontal lobe dysfunction. Four of the 8 patients who underwent gammacapsulotomy who were alive at long-term follow-up had an EAD Scale score of at least 3, but all these had had a high radiation dose (200 Gy in 3 isocenters; patients 10, 20, and 23) or multiple radiosurgical procedures (patient 11), suggesting the relative safety of gammacapsulotomy with lower radiation doses. Six of the 12 patients who underwent thermocapsulotomy scored at least 3 on the EAD Scale total score, and 2 of these 6 patients had undergone multiple capsulotomies. None of the 4 unilaterally lesioned patients had an EAD Scale score of at least 3. Three of the 5 patients who were alive at long-term follow-up and who had undergone more than 1 NMD procedure scored at least 3 on the EAD Scale, indicating adverse effects. Only 3 of the 9 patients in remission had an EAD Scale score lower than 3.

NEUROPSYCHOLOGY

A direct comparison of preoperative and postoperative data from the WCST and Digit Span test was possible in 7 subjects (**Table 3**) and indicated possibly a more compromised executive function (WCST) at long-term follow-up for 6 of 7 subjects, with less consistent results for working memory. Changes in the numbers of WCST categories attained were more than 1 SD. The results of the long-term follow-up assessments are displayed in **Table 4**.

QUANTITATIVE NEUROIMAGING RESULTS

Effect of Thermolesioning vs Gammalesioning Technique

The mean (SD) lesion volume after spatial normalization was 758 (427) mm^3 (left hemisphere) and 979 (397) mm^3 (right hemisphere). Relevant data are summarized in **Table 5**, **Figure 1**, and **Figure 2**. Comparing the 5 ther-

©2008 American Medical Association. All rights reserved.
Downloaded From: http://archpsyc.jamanetwork.com/ on 04/01/2015

Table 3. Individual Preoperative and LT FU T Scores for WCST and Digit Span for 7 Patients

Patient No.	Surgical Method[a]	Preoperative Results, T Score		LT FU, T Score	
		WCST	Digit Span	WCST	Digit Span
6	Unilateral thermo	32	33	20	47
8	Bilateral thermo	55	50	38	33
11	Bilateral gamma	38	50	26	40
14	Unilateral thermo	32	47	55	47
15	Unilateral thermo	37	57	20	57
17	Bilateral gamma	55	37	20	30
24	Bilateral thermo	38	53	26	30
Mean (SD) score		41 (9.9)	47 (8.6)	29 (13.9)	41 (10.3)

Abbreviations: gamma, gammacapsulotomy (radiosurgery); LT FU, long-term follow-up; thermo, thermocapsulotomy; WCST, Wisconsin Card Sorting Test.
[a]Unilateral procedures were right sided.

molesion images with 4 gammalesion images, we found no significant difference in average lesion volume or in EAD Scale score ($P=.81$ and $P=.90$, respectively).

Correlations With Adverse Effects and OCD Symptom Reduction

The mean right hemispheric lesion x-coordinate correlated negatively ($P=.04$) with the EAD Scale score. In addition, the minimum x-coordinate in the right hemisphere correlated negatively ($P=.005$) with the EAD Scale score. This suggests that more medial extension of the lesions in the right hemisphere were associated with more adverse outcome, and how far the lesion edge was from the midline was particularly important. Furthermore, the right hemispheric mean y-coordinate correlated negatively ($P=.06$) with the EAD Scale score, and the right hemispheric minimum y-coordinate correlated negatively ($P=.02$) with the EAD Scale score. This indicates that more posterior lesions in the right hemisphere were associated with a worse outcome, and it was particularly important how posterior the edge of the lesion was. Both of these findings for the right hemisphere are linked because more posterior aspects of a lesion were also more medial (Figures 1 and 2). In the left hemisphere, the degree of Y-BOCS score reduction from baseline to long-term follow-up correlated positively with mean x location ($P=.03$), as did the minimum x location ($P=.054$). This indicates that a more lateral placement of lesions in the left hemisphere was associated with less therapeutic benefit.

Table 4. T Score–Transformed Neuropsychological Test Results at Long-term Follow-up

Test	Mean (SD)	Range
FAS (n = 23)	37.4 (9.1)	20-53
Simplified Six Elements Task (n = 22)	43.4 (12.8)	18-56
Letter-Number Sequencing (n = 23)	45.6 (12.2)	20-73
Digit Span (n = 23)	42.0 (8.9)	30-60
Visual Span (n = 23)	50.1 (11.4)	23-70
WCST		
Categories (n = 22)	37.2 (12.2)	20-55
Perseverative responses (n = 22)	37.4 (9.1)	20-59
Perseverative errors (n = 22)	37.1 (8.8)	20-58
Conceptual responses (n = 22)	35.9 (9.4)	20-56

Abbreviations: FAS, Controlled Oral Word Association Test; WCST, Wisconsin Card Sorting Test.

COMMENT

IS CAPSULOTOMY EFFECTIVE IN REDUCING OCD SYMPTOMS?

We report highly significant OCD symptom relief for thermocapsulotomy and gammacapsulotomy in this long-term follow-up of 25 patients with treatment-refractory OCD. Twelve patients were considered to be responders at long-term follow-up. This finding is in line with the results from earlier studies[13,20,49,50] and very satisfactory considering the severity and chronicity of the disorder. Nine patients were considered to be in remission from OCD at long-term follow-up, but 6 of these 9 experienced substantial adverse effects. There were no significant differences from the 1-year to the long-term follow-up ratings, implying that improvement was generally stable. Despite the reduction in ratings of OCD, depression, and anxiety, global function did not increase. Nonetheless, patients' own ratings of their family and social lives showed marked improvement postoperatively.

IS CAPSULOTOMY SAFE?

We report that the same proportion (50%) of patients who underwent gammacapsulotomy (4 of 8 patients) and those who underwent bilateral thermocapsulotomy (6 of 12 patients) displayed signs of primarily apathy and dysexecutive function behavior. However, looking more closely at the radiosurgical cases shows that all of these case patients received very high radiation doses or underwent more than 1 procedure. Therefore, our data do not provide evidence that gammacapsulotomy is unsafe. Moreover, undergoing multiple capsulotomies by any method appeared to be associated with a high risk of adverse effects in our study. Large lesions or multiple procedures cannot fully explain the high incidence of adverse effects in the patients who underwent thermocapsulotomy. Right-sided unilateral thermocapsulotomy had good safety results, but the very small sample precludes any definitive conclusions on its usefulness.

©2008 American Medical Association. All rights reserved.
Downloaded From: http://archpsyc.jamanetwork.com/ on 04/01/2015

Table 5. Talairach Lesion Coordinates and Volumes at Long-term Follow-up in 11 Patients

Patient No.	Surgery[a]	Volume, mm³			x-Coordinates						y-Coordinates			% of Y-BOCS[b]	EAD Total Score
		Mean	Left	Right	xL	x1L	x2L	xR	x1R	x2R	yR	y1R	y2r		
11	Bilateral gamma	501.5	303	700	–16.57	–20	–13	16.01	11	21	8.69	1	15	30.00	4
23	Bilateral gamma	672.5	785	560	–16.97	–22	–12	11.74	7	17	2.32	–2	7	3.03	5
9	Bilateral gamma	931.5	730	1133	–17.15	–21	–13	19.08	15	24	13.38	8	20	88.57	0
18	Bilateral gamma	1584.0	1708	1460	–21.06	–27	–13	19.36	12	26	17.68	10	29	2.86	2
5	Bilateral thermo	1001.5	650	1353	–14.44	–19	–9	14.67	9	19	11.47	4	19	100.00	6
12	Bilateral thermo	606.0	524	688	–15.22	–21	–9	15.01	10	20	10.71	5	17	67.57	1
25	Bilateral thermo	775.5	706	845	–15.86	–20	–12	16.39	13	20	13.81	7	20	30.30	0
16	Bilateral thermo	418.5	339	498	–15.07	–20	–11	11.97	5	17	11.12	4	17	90.63	2
7	Bilateral thermo	1402.0	1082	1722	–16.18	–21	–10	14.00	4	25	11.30	4	23	88.57	4
14	Unilateral thermo	839.0	0	839	NA	NA	NA	17.94	13	25	13.16	9	18	97.37	1
15	Unilateral thermo	1150.0	0	1150	NA	NA	NA	17.02	13	21	14.40	7	21	5.71	0

Abbreviations: EAD Scale, Execution, Apathy, and Disinhibition Scale; gamma, gammacapsulotomy (radiosurgery); NA, not applicable; thermo, thermocapsulotomy; xL, average x-coordinate left hemisphere; x1L minimum x-coordinate left hemisphere; x2L, maximum x-coordinate left hemisphere; xR, average x-coordinate right hemisphere; x1R minimum x-coordinate right hemisphere; x2R, maximum x-coordinate right hemisphere; yR, average y-coordinate right hemisphere; y1R, minimum y-coordinate right hemisphere; y2R, maximum y-coordinate right hemisphere, Y-BOCS, Yale-Brown Obsessive-Compulsive Scale.

[a] Unilateral procedures were right sided.

[b] Indicates percentage of remaining Y-BOCS score at long-term follow-up, calculated as the Y-BOCS score at long-term follow-up/(baseline score × 100).

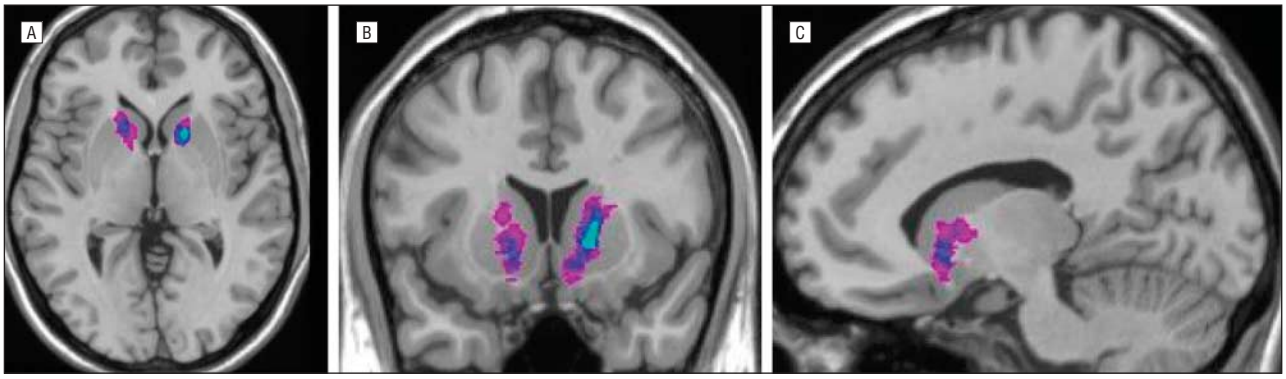

Figure 1. Spatially normalized brain from a healthy subject. Orthogonal sections through the anterior capsule with a thermocapsulotomy lesion overlap in color (light blue, highest overlap; purple, least). Transverse (A), coronal (B), and sagittal (C) views.

The weight gain seen in the first postoperative year was within expectations and is a well-known adverse effect of capsulotomy.[20] The patients' subjective evaluation of their lives in some cases conflicted with the view of others. Some of the patients with the largest change in personality were very satisfied with the outcome. One disinhibited patient concluded that she had "finally found her true personality." This pointed to the fact that interviews with the patients' relatives were indispensable.

In line with previous reports of postoperative neuropsychological performance in capsulotomy,[21,27,51] our data indicate mildly impaired executive functions for the group as a whole. Most studies report that patients with OCD perform at a level comparable to that of controls on the WCST.[52,53] However, tests of set shifting ability[54,55] other than the WCST have been suggested to be more sensitive for orbitofrontal dysfunction and may therefore be valuable to use in future studies. The pattern of results in the present study, with deficits ($T < 40$) on Verbal Fluency and WCST and results within the reference range ($T > 40$) on Working Memory and Attentional Span tasks indicate that results are not merely an effect of slow processing or general cognitive deficits associated with OCD. However, our neuropsychological findings do not prove a causal relationship between surgery and impaired results. The limited group of patients who had preoperative and postoperative neuropsychological evaluations gave an indication of possibly lower results postoperatively for WCST.

An important question is how the patients would have fared without surgery. Studies of the course of OCD suggest that patients generally improve over time.[56,57] However, these observations hardly apply to severely ill patients with long-standing illness and a lack of response to current treatment (ie, the candidates for capsulotomy), where the alternative to surgery often may be lifelong suffering.

COULD THE SURGICAL METHOD, LESION SIZE, OR SITE BE IMPROVED FOR A SAFER OUTCOME?

The results of our MRI lesion analysis in 11 patients suggest that the method of creating lesions had no detectable effect with regard to lesion size and EAD Scale score. In addition, it suggests that reducing the lateral extension of the lesions may increase efficacy, and a reduc-

©2008 American Medical Association. All rights reserved.
Downloaded From: http://archpsyc.jamanetwork.com/ on 04/01/2015

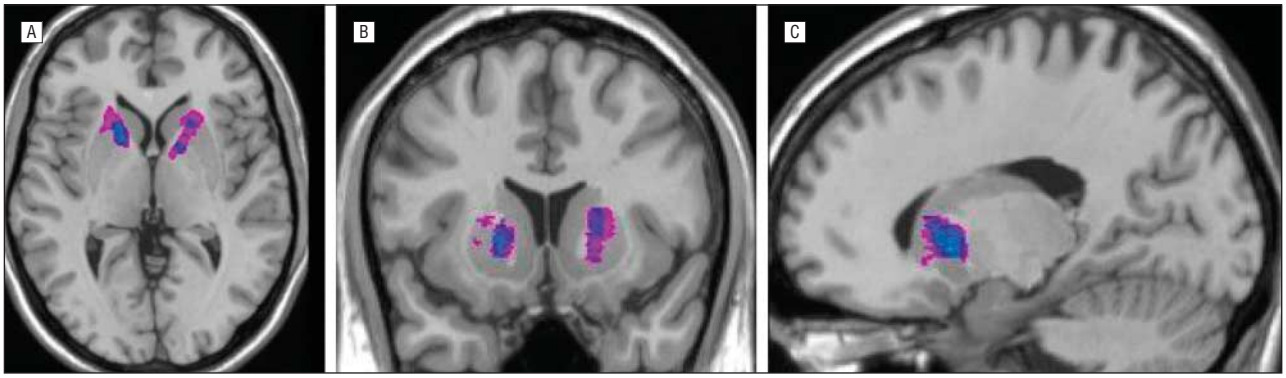

Figure 2. Spatially normalized brain from a healthy subject. Orthogonal sections through the anterior capsule with a gammacapsulotomy (radiosurgery) lesion overlap in color (light blue, highest overlap; purple, least). Transverse (A), coronal (B), and sagittal (C) views.

tion in the medial and posterior extension of the lesions may limit the risk of adverse effects. It is important to note the limitations of the analysis. First, data from few patients were available, implying that a failure to find a difference related to the lesion method may reflect type II error. Second, the reported significant correlations have a significant risk of type I error because a correction for multiple comparisons was not applied. Recognizing these limitations, the results suggest that smaller anterior capsulotomy lesions may produce better results. These suggestions are in line with the clinical results discussed in the preceding sections, suggesting that high radiation doses and multiple procedures should be avoided. The lesions in the gammacapsulotomy cases (Figure 2) were dorsally placed in comparison with current practice, where the focus is on the ventral portion of the capsule, impinging on the adjacent ventral striatum.

Dougherty et al[4] reported that 46% of their patients who underwent cingulotomy were responders (defined as a Y-BOCS decrease of ≥35% *and* a CGI-I score of 1 or 2) or partial responders (defined as a Y-BOCS decrease of ≥35% *or* a CGI-I score of 1-2) at long-term follow-up, compared with 64% in our sample. This finding, together with the fact that few adverse effects were reported, suggests that capsulotomy may be slightly more effective in treating OCD but, at least for thermocapsulotomy, less safe than cingulotomy.

LIMITATIONS

The study lacked a placebo treatment and the sample size was limited, resulting in a low a priori statistical power. Some of the measurements were merely used postoperatively and only a subgroup of patients had undergone preoperative neuropsychological evaluation. The spatial resolution of our MRI method was suboptimal, given the small structures that were studied. Therefore, the results should be interpreted with caution. There are also a number of possible explanations other than capsulotomy for postoperative changes, including comorbid disease, other treatments received postoperatively, substance abuse, and life events. The patients included in the study are not representative of the general OCD population, and there may be differences in neurosurgical methods relevant to the intervention between our center and others. Another limitation is the heterogeneity with regard to preoperative treatment, comorbidity, and the different methods of surgical interventions. These factors clearly may limit this study's generalizability. Furthermore, the results reported herein are not directly applicable to other NMD methods.

CONCLUSIONS

Capsulotomy is effective in treating OCD but carries a substantial risk of adverse effects. This risk is larger than previously assumed but is also influenced by the surgical technique used. There were no clear differences in outcome between patients who underwent gammacapsulotomy or thermocapsulotomy, but the findings regarding radiosurgery were obscured by high radiation doses in some patients that may explain adverse effects. The risk of thermocapsulotomy could be higher than that of a single gammacapsulotomy. Future research should explore reversible interventions and the optimal lesion localization to minimize the risks of NMD.

Submitted for Publication: July 2, 2007; final revision received February 6, 2008; accepted February 14, 2008.
Correspondence: Christian Rück, MD, PhD, Section of Psychiatry M57, Department of Clinical Neuroscience, Karolinska Institutet, Karolinska University Hospital Huddinge, SE-141 86 Stockholm, Sweden (christian.ruck@ki.se).
Financial Disclosure: None reported.
Funding/Support: This study was supported by the Swedish Research Council, Hjärnfonden, The Swedish Lundbeck Foundation, and funds from the Karolinska Institutet.
Previous Presentation: This paper was presented in part at the Annual Meeting of the American Psychiatric Association; May 21, 2007; San Diego, California.

REFERENCES

1. Husted DS, Shapira NA. A review of the treatment for refractory obsessive-compulsive disorder: from medicine to deep brain stimulation. *CNS Spectr.* 2004; 9(11):833-847.
2. van Oppen P, van Balkom AJ, de Haan E, van Dyck R. Cognitive therapy and exposure in vivo alone and in combination with fluvoxamine in obsessive-compulsive disorder: a 5-year follow-up. *J Clin Psychiatry.* 2005;66(11):1415-1422.
3. Mancebo MC, Eisen JL, Pinto A, Greenberg BD, Dyck IR, Rasmussen SA. The Brown Longitudinal Obsessive Compulsive Study: treatments received and patient impressions of improvement. *J Clin Psychiatry.* 2006;67(11):1713-1720.
4. Dougherty DD, Baer L, Cosgrove GR, Cassem EH, Price BH, Nierenberg AA, Jenike

©2008 American Medical Association. All rights reserved.
Downloaded From: http://archpsyc.jamanetwork.com/ on 04/01/2015

MA, Rauch SL. Prospective long-term follow-up of 44 patients who received cingulotomy for treatment-refractory obsessive-compulsive disorder. *Am J Psychiatry*. 2002;159(2):269-275.
5. Rauch SL. Neuroimaging and neurocircuitry models pertaining to the neurosurgical treatment of psychiatric disorders. *Neurosurg Clin N Am*. 2003;14(2):213-223, vii-viii.
6. Whiteside SP, Port JD, Abramowitz JS. A meta-analysis of functional neuroimaging in obsessive-compulsive disorder. *Psychiatry Res*. 2004;132(1):69-79.
7. Axer H, Keyserlingk DG. Mapping of fiber orientation in human internal capsule by means of polarized light and confocal scanning laser microscopy. *J Neurosci Methods*. 2000;94(2):165-175.
8. Greenberg BD, Malone DA, Friehs GM, Rezai AR, Kubu CS, Malloy PF, Salloway SP, Okun MS, Goodman WK, Rasmussen SA. Three-year outcomes in deep brain stimulation for highly resistant obsessive-compulsive disorder. *Neuropsychopharmacology*. 2006;31(11):2384-2393.
9. Bejerot S. Psychosurgery for obsessive-compulsive disorder: concerns remain. *Acta Psychiatr Scand*. 2003;107(4):241-243.
10. Burzaco J. Stereotactic surgery in the treatment of obsessive-compulsive neurosis. In: Perris C, Struwe G, Jansson B, eds. *Biological Psychiatry*. Amsterdam, the Netherlands: Elsevier/North-Holland Biomedical Press; 1981:1103-1109.
11. Herner T. Treatment of mental disorders with frontal stereotaxic thermo-lesions: a follow-up study of 116 cases [thesis]. *Acta Psychiatr Scand*. 1961;36(158)(suppl):39-73. doi:10.1111/j.1600-0447.1961.tb08703.x.
12. Lippitz BE, Mindus P, Meyerson BA, Kihlström L, Lindquist C. Lesion topography and outcome after thermocapsulotomy or gamma knife capsulotomy for obsessive-compulsive disorder: relevance of the right hemisphere. *Neurosurgery*. 1999;44(3):452-460.
13. Oliver B, Gascon J, Aparicio A, Ayats E, Rodriguez R, Maestro De León JL, García-Bach M, Soler PA. Bilateral anterior capsulotomy for refractory obsessive-compulsive disorders. *Stereotact Funct Neurosurg*. 2003;81(1-4):90-95.
14. Matthews K, Eljamel MS. Status of neurosurgery for mental disorder in Scotland: selective literature review and overview of current clinical activity. *Br J Psychiatry*. 2003;182:404-411.
15. Rück C. *Capsulotomy in Anxiety Disorders* [dissertation]. Stockholm, Sweden: Karolinska Institutet; 2006.
16. Rylander G. Stereotactic radiosurgery in anxiety and obsessive-compulsive states: psychiatric aspects. In: Hitchcock ER, Ballantine HTJ, Meyerson BA, eds. *Modern Concepts in Psychiatric Surgery*. Amsterdam, the Netherlands: Elsevier/North Holland Biomedical Press; 1979:235-240.
17. Christensen DD, Laitinen LV, Schmidt LJ, Hariz MI. Anterior capsulotomy for treatment of refractory obsessive-compulsive disorder: results in a young and an old patient. *Stereotact Funct Neurosurg*. 2002;79(3-4):234-244.
18. Jung HH, Kim CH, Chang JH, Park YG, Chung SS, Chang JW. Bilateral anterior cingulotomy for refractory obsessive-compulsive disorder: long-term follow-up results. *Stereotact Funct Neurosurg*. 2006;84(4):184-189.
19. Kim CH, Chang JW, Koo MS, Kim JW, Suh HS, Park IH, Lee HS. Anterior cingulotomy for refractory obsessive-compulsive disorder. *Acta Psychiatr Scand*. 2003;107(4):283-290.
20. Mindus P. *Capsulotomy in Anxiety Disorders: A Multidisciplinary Study* [dissertation]. Stockholm, Sweden: Karolinska Institutet; 1991.
21. Rück C, Andréewitch S, Flyckt K, Edman G, Nyman H, Meyerson BA, Lippitz BE, Hindmarsh T, Svanborg P, Mindus P, Åsberg M. Capsulotomy for refractory anxiety disorders: long-term follow-up of 26 patients. *Am J Psychiatry*. 2003;160(3):513-521.
22. Rück C, Svanborg P, Meyerson BA. Lesion topography in capsulotomy for refractory anxiety: is the right side the right side? *Stereotact Funct Neurosurg*. 2005;83(4):172-179.
23. Rück C, Edman G, Åsberg M, Svanborg P. Long-term changes in self-reported personality following capsulotomy in anxiety patients. *Nord J Psychiatry*. 2006;60(6):486-491.
24. First MB, Spitzer RL, Gibbon M, Williams JBW. *Structured Clinical Interview for* DSM-IV *Axis I Disorders (SCID-I)–Clinician Version*. Washington, DC: American Psychiatric Press; 1997.
25. Mindus P. Present-day indications for capsulotomy. *Acta Neurochir Suppl (Wien)*. 1993;58:29-33.
26. Meyerson BA. Neurosurgical treatment of mental disorders: introduction and indications. In: Gildenberg PL, Tasker RR, eds. *Textbook of Stereotactic and Functional Neurosurgery*. New York, NY: McGraw-Hill Health Professions Division; 1998:1955-1963.
27. Nyman H, Andréewitch S, Lundbäck E, Mindus P. Executive and cognitive functions in patients with extreme obsessive-compulsive disorder treated by capsulotomy. *Appl Neuropsychol*. 2001;8(2):91-98.
28. Mindus P, Edman G, Andréewitch S. A prospective, long-term study of personality traits in patients with intractable obsessional illness treated by capsulotomy. *Acta Psychiatr Scand*. 1999;99(1):40-50.
29. Kihlström L, Guo WY, Lindquist C, Mindus P. Radiobiology of radiosurgery for refractory anxiety disorders. *Neurosurgery*. 1995;36(2):294-302.
30. Kihlström L, Hindmarsh T, Lax I, Lippitz B, Mindus P, Lindquist C. Radiosurgical lesions in the normal human brain 17 years after gamma knife capsulotomy. *Neurosurgery*. 1997;41(2):396-402.
31. Goodman WK, Price LH, Rasmussen SA, Mazure C, Fleischmann RL, Hill CL, Heninger GR, Charney DS. The Yale-Brown Obsessive Compulsive Scale, I: development, use, and reliability. *Arch Gen Psychiatry*. 1989;46(11):1006-1011.
32. Pallanti S, Quercioli L. Treatment-refractory obsessive-compulsive disorder: methodological issues, operational definitions and therapeutic lines. *Prog Neuropsychopharmacol Biol Psychiatry*. 2006;30(3):400-412.
33. Montgomery SA, Åsberg M. A new depression scale designed to be sensitive to change. *Br J Psychiatry*. 1979;134:382-389.
34. Tyrer P, Owen RT, Cicchetti DV. The Brief Scale for Anxiety: a subdivision of the Comprehensive Psychopathological Rating Scale. *J Neurol Neurosurg Psychiatry*. 1984;47(9):970-975.
35. Guy W. Clinical global impressions. In: Guy W, ed. *ECDEU Assessment Manual for Psychopharmacology*. Rev ed. Rockville, MD: Dept of Health, Education and Welfare; 1976:218-222. Publication (ADM) 76-338.
36. American Psychiatric Association. *Diagnostic and Statistical Manual of Mental Disorders*. 4th ed. Washington, DC: American Psychiatric Association; 1994.
37. Sheehan DV, Harnett-Sheehan K, Raj BA. The measurement of disability. *Int Clin Psychopharmacol*. 1996;11(suppl 3):89-95.
38. Grace J, Malloy PF. *Frontal Systems Behavior Scale (FrSBe): Professional Manual*. Lutz, FL: Psychological Assessment Resources; 2001.
39. Wechsler D. *Wechsler Adult Intelligence Scale–Revised*. San Antonio, TX: Psychological Corp; 1981.
40. Kaplan E, Fein D, Morris R, Delis DC. *WAIS-R as a Neuropsychological Instrument (WAIS-R NI)*. San Antonio, TX: Psychological Corp; 1991.
41. Lezak MD. *Neuropsychological Assessment*. 3rd ed. New York, NY: Oxford University Press; 1995.
42. Heaton RK, Chelune GJ, Talley JL, Kay GG, Curtiss G. *Wisconsin Card Sorting Test Manual–Revised and Expanded*. Odessa, FL: Psychological Assessment Resources Inc; 1993.
43. Wilson B. *Behavioural Assessment of Dysexecutive Syndrome*. Bury St Edmunds, England: Thames Valley Test Co; 1995.
44. Frackowiak RSJ. *Human Brain Function*. 2nd ed. Amsterdam, the Netherlands: Elsevier Academic Press; 2004.
45. MRC Cognition and Brain Sciences Unit. The MNI brain and the Talairach atlas. http://imaging.mrc-cbu.cam.ac.uk/imaging/MniTalairach. Accessed January 4, 2007.
46. Talairach J, Tournoux P. *Co-planar Stereotaxic Atlas of the Human Brain: 3-Dimensional Proportional System: An Approach to Cerebral Imaging*. New York, NY: Thieme Medical Publishers; 1988.
47. Members and collaborators of the Wellcome Department of Imaging Neuroscience. SPM2: Statistical Parametric Mapping. http://www.fil.ion.ucl.ac.uk/spm. Accessed January 4, 2007.
48. Rorden C. MRIcro. University of South Carolina. http://www.sph.sc.edu/comd/rorden/mricro.html. Accessed January 4, 2007.
49. Bingley T, Leksell L, Meyerson BA, Rylander G. Long-term results of stereotactic capsulotomy in chronic obsessive-compulsive neurosis. In: Sweet WH, Obrador S, Martín-Rodriguez JG, eds. *Neurosurgical Treatment in Psychiatry, Pain and Epilepsy*. Baltimore, MD: University Park Press; 1977:287-289.
50. Kullberg G. Differences in effect of capsulotomy and cingulotomy. In: Sweet W, Obrador S, Martín-Rodríguez J, eds. *Neurosurgical Treatment in Psychiatry, Pain, and Epilepsy*. Baltimore, MD: University Park Press; 1977:301-308.
51. Nyman H, Mindus P. Neuropsychological correlates of intractable anxiety disorder before and after capsulotomy. *Acta Psychiatr Scand*. 1995;91(1):23-31.
52. Olley A, Malhi G, Sachdev P. Memory and executive functioning in obsessive-compulsive disorder: a selective review. *J Affect Disord*. 2007;104(1-3):15-23.
53. Kuelz AK, Hohagen F, Voderholzer U. Neuropsychological performance in obsessive-compulsive disorder: a critical review. *Biol Psychol*. 2004;65(3):185-236.
54. Freedman M, Oscar-Berman M. Bilateral frontal lobe disease and selective delayed response deficits in humans. *Behav Neurosci*. 1986;100(3):337-342.
55. Freedman M. Object alternation and orbitofrontal system dysfunction in Alzheimer's and Parkinson's disease. *Brain Cogn*. 1990;14(2):134-143.
56. Reddy YC, D'Souza SM, Shetti C, Kandavel T, Deshpande S, Badamath S, Singisetti S. An 11- to 13-year follow-up of 75 subjects with obsessive-compulsive disorder. *J Clin Psychiatry*. 2005;66(6):744-749.
57. Skoog G, Skoog I. A 40-year follow-up of patients with obsessive-compulsive disorder. *Arch Gen Psychiatry*. 1999;56(2):121-127.

©2008 American Medical Association. All rights reserved.
Downloaded From: http://archpsyc.jamanetwork.com/ on 04/01/2015