

Microglial Activation in Young Adults With Autism Spectrum Disorder

Katsuaki Suzuki, MD, PhD; Genichi Sugihara, MD, PhD; Yasuomi Ouchi, MD, PhD; Kazuhiko Nakamura, MD, PhD; Masami Futatsubashi, BS; Kiyokazu Takebayashi, MD, PhD; Yujiro Yoshihara, MD, PhD; Kei Omata, PhD; Kaori Matsumoto, MA; Kenji J. Tsuchiya, MD, PhD; Yasuhide Iwata, MD, PhD; Masatsugu Tsujii, MA; Toshirou Sugiyama, MD, PhD; Norio Mori, MD, PhD

Context: A growing body of evidence suggests that aberrant immunologic systems underlie the pathophysiologic characteristics of autism spectrum disorder (ASD). However, to our knowledge, no information is available on the patterns of distribution of microglial activation in the brain in ASD.

Objectives: To identify brain regions associated with excessively activated microglia in the whole brain, and to examine similarities in the pattern of distribution of activated microglia in subjects with ASD and control subjects.

Design: Case-control study using positron emission tomography and a radiotracer for microglia— $[^{11}\text{C}](\text{R})$ -(1-[2-chlorophenyl]-*N*-methyl-*N*-[1-methylpropyl]-3 isoquinoline carboxamide) ($[^{11}\text{C}](\text{R})$ -PK11195).

Setting: Subjects recruited from the community.

Participants: Twenty men with ASD (age range, 18-31 years; mean [SD] IQ, 95.9 [16.7]) and 20 age- and IQ-matched healthy men as controls. Diagnosis of ASD was made in accordance with the Autism Diagnostic Observation Schedule and the Autism Diagnostic Interview-Revised.

Main Outcome Measures: Regional brain $[^{11}\text{C}](\text{R})$ -PK11195 binding potential as a representative measure of microglial activation.

Results: The $[^{11}\text{C}](\text{R})$ -PK11195 binding potential values were significantly higher in multiple brain regions in young adults with ASD compared with those of controls ($P < .05$, corrected). Brain regions with increased binding potentials included the cerebellum, midbrain, pons, fusiform gyri, and the anterior cingulate and orbitofrontal cortices. The most prominent increase was observed in the cerebellum. The pattern of distribution of $[^{11}\text{C}](\text{R})$ -PK11195 binding potential values in these brain regions of ASD and control subjects was similar, whereas the magnitude of the $[^{11}\text{C}](\text{R})$ -PK11195 binding potential in the ASD group was greater than that of controls in all regions.

Conclusions: Our results indicate excessive microglial activation in multiple brain regions in young adult subjects with ASD. The similar distribution pattern of regional microglial activity in the ASD and control groups may indicate augmented but not altered microglial activation in the brain in the subjects with ASD.

JAMA Psychiatry. 2013;70(1):49-58.

Published online November 26, 2012.

doi:10.1001/jamapsychiatry.2013.272

AUTISM SPECTRUM DISORDER (ASD) is a group of neurodevelopmental disorders characterized by pervasive abnormalities in social interaction and communication and by repetitive and restricted behavioral patterns and interests. Autism spectrum disorders include autistic disorder, Asperger disorder, and pervasive developmental disorder not otherwise specified.¹ Recent population-based surveys^{2,3} showing that ASD is more common than previously believed have aroused serious public concern worldwide. Although the neurobiologic basis for ASD remains poorly understood, a growing body of

research^{4,5} suggests that immune abnormalities are a contributing factor to the development of ASD. Several genetic studies link ASD with genes that are associated with various immune functions,

*For editorial comment
see page 9*

including the HLA antigen⁶ and the major histocompatibility complex class III molecule, such as complement C4B.^{7,8} Systemic abnormalities of the immune system have been one of the most common and long-standing reported findings in subjects with ASD.^{9,10} Notably, increased production of cytokines (eg,

Author Affiliations are listed at the end of this article.

Table 1. Demographic Characteristics of the Subjects^a

Variable	Mean (SD) [Range]	
	Control (n = 20)	ASD (n = 20)
Age, y ^b	22.6 (5.3) [17.8-35.5]	23.3 (4.0) [18.6-31.9]
WAIS-III full IQ ^c	102.8 (12.5) [81.0-131.0]	95.9 (16.7) [81.0-140.0]
ADI-R		
Social	NA	20.6 (5.1) [10.0-29.0]
Communication	NA	15.2 (4.4) [8.0-24.0]
Stereotype	NA	4.3 (2.2) [3.0-10.0]
ADOS		
Social	NA	6.4 (3.0) [4.0-11.0]
Communication	NA	6.2 (2.7) [2.0-13.0]
Stereotype	NA	1.0 (0.9) [0-3.0]
Faux Pas Test	NA	21.2 (8.6) [3.0-34.0]
Y-BOCS	NA	11.0 (6.4) [0-28.0]
DCDQ-J total	NA	60.4 (12.0) [42.0-73.0]

Abbreviations: ADI-R, Autism Diagnostic Interview–Revised; ADOS, Autism Diagnostic Observation Schedule; ASD, autism spectrum disorder; DCDQ-J, Japanese version of the Developmental Coordination Disorder Questionnaire; NA, not applicable; WAIS-III, Wechsler Adult Intelligence Scale, third edition; Y-BOCS, Yale-Brown Obsessive Compulsive Scale.

^aAll subjects were men.

^b*P* = .63.

^c*P* = .15.

interleukin 6 [IL-6], tumor necrosis factor, and macrophage chemoattractant protein-1) has been observed in peripheral samples and the brains of ASD subjects.¹¹⁻¹⁶ In general, plasma cytokine levels in ASD subjects are widely distributed and show substantial overlap with control subjects, implying that there is a subset of ASD subjects with high levels of such cytokines. In addition, several studies¹⁷⁻²⁰ have identified specific antibodies against human brain epitopes in the serum of mothers of children with ASD, as well as in children with ASD, although autoantibodies are found in only 10% to 15% of the children with ASD. These findings argue in favor of the participation of the immune system in the pathogenesis of a subset of ASD subjects.

Microglia are resident brain cells that sense pathologic tissue alterations.^{21,22} The first microglial precursors colonize the brain during the embryonic and fetal phases of development.^{23,24} They develop into brain macrophages and perform immune functions. Upon exposure of the brain to any form of insult, such as infection, trauma, or ischemia, the microglia are rapidly activated. When activated, microglia produce neurotoxic substances, including proinflammatory cytokines (ie, tumor necrosis factor and IL-1 β) and oxygen species (ie, hydrogen peroxide and superoxide). However, under certain conditions, activated microglia can produce anti-inflammatory cytokines such as IL-10 and transforming growth factor- β , which have neuroprotective effects in experimental animal models of traumatic injury and stroke.^{25,26} Furthermore, experimental studies^{27,28} have demonstrated that microglia play a role in the maintenance of synaptic integrity in the uninjured brain.

Recently, Vargas and colleagues¹⁶ determined the magnitude of neuroglial and inflammatory reactions and their cytokine expression profiles in brain tissues from the cerebellum, midfrontal, and cingulate gyrus obtained at au-

topsy from children and adults with ASD. Immunocytochemical examination revealed marked activation of microglia and astroglia. Microglial responses were diffusely distributed in the cortex and subcortical areas, as well as the cerebellum, and were present as microglial nodules or as part of a prominent accumulation of perivascular macrophages. More recently, Morgan and colleagues²⁹ quantitatively assessed activated microglia in the dorsolateral prefrontal cortex of postmortem brains from children and adults with ASD. They found that the microglia were markedly or marginally activated in most cases examined. Transcriptomic analysis of the autistic brain by Voineagu and colleagues³⁰ has shown the presence of 2 modules in the ASD brain: a neuronal module enriched for known autism susceptibility genes, including neuronal-specific factors, such as ataxin 2-binding protein 1, and a module enriched for immune genes and glial markers. The latter immune-glia module has a less pronounced genetic component and thus is most likely either a secondary phenomenon or the result of environmental factors. Despite the striking features of microglial activation in the pathogenesis of ASD, to our knowledge, there is no information on the patterns and characteristics of the distribution of microglial activation in the whole brain in ASD subjects.

To address this issue, we conducted a positron emission tomography (PET) analysis using the radiocarbon (¹¹C)-labeled (R)-(1-[2-chlorophenyl]-N-methyl-N-[1-methylpropyl]-3-isoquinoline carboxamide) (¹¹C)(R)-PK11195, a radiotracer that specifically binds to activated microglia.³¹⁻³³ This procedure permitted us to visualize the activated microglia *in vivo* in the whole brain. In this study, we initially determined the distribution of [¹¹C](R)-PK11195 binding potential (BP) in the whole brain of young adults with ASD and then identified several brain regions associated with the activation of microglia. Subsequently, we compared the levels of [¹¹C](R)-PK11195 BP in the identified brain regions. Because microglia may be prenatal in origin,^{23,24} and because ASD is typically diagnosed by 3 years of age, we hypothesized that the regional variability of the [¹¹C](R)-PK11195 BP in the identified brain regions is similar between ASD and control subjects, whereas the magnitude of [¹¹C](R)-PK11195BP in ASD subjects is greater than that of controls in all the regions. To test this hypothesis, we carefully recruited subjects with no history of epilepsy or medication because epileptic seizures and psychotropic drugs can influence the condition of microglial activation.³⁴⁻³⁷

METHODS

SUBJECTS

The ethics committees of the Hamamatsu University School of Medicine approved this study. Written informed consent was obtained from all subjects and their guardians after they had been provided a detailed explanation of the study procedures. Twenty men with ASD and 20 age- and IQ-matched typically developing male subjects participated in this study (**Table 1**). All subjects were right-handed and had an IQ of greater than 80. None of the subjects were tobacco smokers, and none were

taking any medication, including psychotropic drugs. All of them were physically healthy. At the time of scanning, all the subjects had no symptoms of inflammation and were not under stressful conditions. All the subjects with ASD were diagnosed by 2 trained child psychiatrists (K.N. and T.S.) according to the *DSM-IV-TR*.¹ The ASD diagnosis was confirmed for all cases using the Autism Diagnostic Interview–Revised (ADI-R)³⁸ and the Autism Diagnostic Observation Schedule (ADOS)³⁹ module-4 by trained clinicians (K.J.T. and K.M., respectively). As a result, 15 of 20 ASD subjects were diagnosed as having autistic disorder and the remaining 5 were considered to have pervasive developmental disorder not otherwise specified on the basis of the ADOS scores, although all 20 subjects met the ADI-R criteria for autistic disorder. None of the ASD subjects was classified as having regressive autism, the classification of which was based on clinical characteristics using both parental reporting and answers to questions on the ADI-R regarding language loss (question 11) and social skills (question 25). The ASD subjects did not have any other psychiatric comorbidity disorders, as confirmed by the Structured Clinical Interview for *DSM-IV* Axis I disorders.⁴⁰ In addition, they had no notable dysmorphism, neurocutaneous abnormalities, significant neurologic deficits, history of epileptic seizures, or disorders known to be associated with autism, such as fragile X syndrome, neurofibromatosis, or tuberous sclerosis. Fragile X syndrome was excluded by determining the CGG repeat number in the *FMRI* gene. We measured the markers of inflammation in the blood in the ASD subjects, including the serum C-reactive protein and white blood cell count. Both levels in all the ASD subjects were within normal range. None of the ASD subjects had any history of inflammatory or allergic diseases, except 2 subjects who had had atopic dermatitis in their childhood. One of the ASD subjects had a family history of major depression (his mother). In the remaining 19 subjects, there was no family history of any chronic inflammatory diseases or neuropsychiatric conditions. In the ASD subjects, the social cognitive disability and the degree of repetitive and/or obsessive behavior and interests were evaluated by the Faux Pas Test⁴¹ and Yale-Brown Obsessive Compulsive Scale,^{42,43} respectively. Current motor coordination problems were assessed by the Japanese version of the Developmental Coordination Disorder Questionnaire.⁴⁴ All control subjects were found to be mentally and physically healthy on the basis of comprehensive assessments of their medical histories and neuropsychiatric examinations.

MAGNETIC RESONANCE IMAGING AND PET PROCEDURES

As described previously,^{33,45} we obtained 3-dimensional magnetic resonance images (MRIs) just before PET measurements using a 0.3-T MRI unit (MRP7000AD; Hitachi Medical) and a high-resolution brain PET scanner having an intrinsic resolution of $2.9 \times 2.9 \times 3.4$ mm at full-width at half maximum and a 163-mm axial field of view, and yielding 47 PET images simultaneously (SHR 12000; Hamamatsu Photonics), respectively. All MRI and PET scans were set parallel to the anterior-posterior intercommissural line.⁴⁵ Before dynamic PET scanning, a 20-minute transmission scan was performed for attenuation correction using a ⁶⁸Ge/⁶⁸Ga source. Then, after a bolus intravenous injection of a 350-MBq dose of [¹¹C](R)-PK11195, we performed 32 serial PET scans (time frames: 4×30 second, 20×60 second, and 8×300 second) for 62 minutes. In quantitative PET brain imaging, the motion artifact is the important degrading factor. Therefore, we fixed the head of each subject by using a thermoplastic face mask, observed subjects carefully during each scan, and confirmed that all the subjects had remained immobilized.

IMAGE ANALYSIS AND KINETIC MODELING

The brain, particularly in cortical subregions, is known to be sensitive to a partial volume effect that sometimes occurs during the measurement of small brain structures and that leads to an underestimation of tracer activity. In this study, we used the following previously described procedure to minimize the contribution of the partial volume effect.^{33,45} First, we adjusted the MRI voxel size to the PET voxel size 3-dimensionally using image-processing software (DrView; Asahi Kasei) on a Sun workstation (HyperSPARC ss-20; Sun Microsystems). Then, these reformatted MRIs with 3-dimensional scales and coordinates identical to those of the PET images were used as anatomic landmarks for the regions of interest (ROIs) setting. Subsequently, by referring to areas on the MRIs as anatomical landmarks, the ROIs were carefully drawn to avoid the involvement of either the sulci or ventricles. An investigator masked to the subject's condition placed 3 ROIs over the bilateral cerebellar cortices, midbrain, and bilateral thalami on the MRIs. These ROIs were then transferred onto the corresponding dynamic [¹¹C](R)-PK11195 images.

To assess activated microglial density in the brain, we analyzed the [¹¹C](R)-PK11195 time-activity curves (TACs) on the basis of a simplified reference tissue model^{46,47} because the regional brain [¹¹C](R)-PK11195 BP (a ratio of binding and dissociation rate constants, k_3/k_4) estimated by the simplified reference tissue model is reported to correlate with the magnitude of microglial activity.^{33,48} Because the decrease of TACs was sharpest in the cerebellar ROI among the 3 ROIs examined in the control group, we assumed that the specific binding would be the least in this region. A normalized input curve was first created by averaging the TACs from the ROIs placed over the bilateral cerebellar cortices in the control group. Then, the normalized mean input curve was used as the reference input function of the simplified reference tissue model in the ASD and control subjects because a desirable reference region free from specific binding was not evident in the ASD subjects.

Using biomedical imaging software (PMOD, version 3.0; PMOD Technologies), we constructed whole-brain parametric maps of the [¹¹C](R)-PK11195 BP for the subsequent voxel-based analysis using Statistical Parametric Mapping software (SPM5; <http://www.fil.ion.ucl.ac.uk/spm/>). The [¹¹C](R)-PK11195 BP maps were normalized to the Montreal Neurological Institute space, as defined by the MRI T1 template implemented in SPM5. The extracerebral structures were then masked by demarcating cerebral regions on spatially normalized MRIs. Finally, the normalized and masked BP maps were smoothed with an 8-mm full-width at half maximum gaussian filter.

In addition to the voxel-based analysis, which is suitable for an exploratory examination of altered tracer distribution in the brain, we performed a volume of interest (VOI)-based analysis because it enabled us to generate quantitative differences in [¹¹C](R)-PK11195 BP in specific regions. For this purpose, we placed additional spherical VOIs of 5-mm radius, which centered on the peak voxel derived from the results of the voxel-based analysis, on [¹¹C](R)-PK11195 BP maps for each of the subjects. The VOIs selected were the bilateral cerebellum, brainstem, splenium of the corpus callosum, bilateral fusiform gyri, bilateral superior temporal gyri, and the bilateral anterior cingulate, bilateral orbitofrontal, left midfrontal, and right parietal cortices. Averaged [¹¹C](R)-PK11195 BP values for each VOI were obtained in the ASD and control groups.

VOXEL-BASED MORPHOMETRY

To investigate possible differences in brain structure between the ASD and control groups, we conducted voxel-based morphometry. For this purpose, we used a 3-T MRI scanner (Signa Excite;

General Electric Medical Systems) to obtain T1-weighted volumetric images scanned by the inversion recovery-prepared fast spoiled gradient recalled acquisition protocol as follows: repetition time = 11.0 milliseconds, echo time = 5.0 milliseconds, preparation time = 450 milliseconds, flip angle 20°, number of excitations = 1, field of view = 24.0 cm, matrix = 256 × 256, auto-zero-fill interpolation = 512, location per slab = 160, slice thickness = 1.2 mm, and voxel size = 0.94 × 0.94 × 1.2 mm. The T1-weighted volumetric images were analyzed using the VBM5.1 toolbox (<http://www.fil.ion.ucl.ac.uk/spm/ext/>) implemented in SPM5 with the default parameters. Estimates of the absolute gray matter (GM), white matter (WM), and cerebrospinal fluid (CSF) volumes were obtained after the automatic brain segmentation procedure had been carried out by VBM5.1. The total intracranial volume was calculated as the sum of the volumes of the GM, WM, and CSF.

STATISTICAL ANALYSIS

The demographic and clinical variables of the ASD and control groups were compared by the unpaired *t* test using statistical software (PASW Statistics version 18; SPSS Japan Inc). The level of statistical significance was set at $P < .05$.

The voxel-based analyses of the [¹¹C](R)-PK11195 BP maps were conducted using SPM5. For the SPM5 analysis of the [¹¹C](R)-PK11195 BP maps, between-group comparisons were performed to explore regional differences in the [¹¹C](R)-PK11195 BP using the *t* test for each voxel without a proportional scaling of the [¹¹C](R)-PK11195 BP maps. We also performed exploratory correlation analyses between the regional changes in [¹¹C](R)-PK11195 BP values and the severity of clinical features in ASD subjects using SPM5. The scores on the ADOS, ADI-R, Faux Pas Test, Yale-Brown Obsessive Compulsive Scale, and the Japanese version of the Developmental Coordination Disorder Questionnaire were variables of interest. To test hypotheses about the region-specific effects of these variables, the estimates were compared using 2 linear contrasts (positive or negative correlation). In the SPM5 analyses, values of $P < .05$ were statistically significant after adjustment for the false discovery rate in the whole-brain multiple comparisons.

In the VOI-based analyses, we tested the main effect of the diagnosis of ASD on [¹¹C](R)-PK11195 BP values derived from 13 brain regions using 2-way analysis of variance, in which statistical significance was set at $P < .05$. For comparisons of clinical variables between subgroups of ASD subjects, a Mann-Whitney test was performed.

To assess the differences in segmented brain volumes between groups in the voxel-based morphometry analysis, we conducted a multivariate analysis of covariance using PASW software with group (ASD and control) as a between-subject factor, segmented brain regional absolute volume (GM, WM, and CSF) as a within-subject factor, and intracranial volume as a covariate. The statistical significance level was set at $P < .05$. Second, for the GM analysis, the normalized, modulated, and smoothed GM image segments in each group were entered into a voxel-wise 2-sample *t* test analysis in SPM5. An absolute threshold mask of 0.30 was used to avoid possible edge effects around the border between GM and WM. The statistical threshold was set at $P < .05$ after the false discovery rate correction. Data were presented as mean (SD).

RESULTS

Characteristics of all the subjects are summarized in Table 1. There was no significant difference in age or IQ between the 2 groups.

COMPARISON OF [¹¹C](R)-PK11195 BP BETWEEN ASD SUBJECTS AND CONTROLS

The tissue TACs of [¹¹C](R)-PK11195 are shown in **Figure 1A**. After the administration of [¹¹C](R)-PK11195, the radioactivity in 3 ROIs over the cerebellum, midbrain, and thalamus of a representative control subject decreased with time. The TACs in an ASD subject decreased less sharply than those in the control subject, indicating a time-course accumulation of [¹¹C](R)-PK11195 in the respective brain structures. **Figure 1B** shows MRI-PET fusion parametric images of [¹¹C](R)-PK11195 BP in the representative control and ASD subjects. A marked increase in [¹¹C](R)-PK11195 binding was observed across widespread areas of the brain of the representative ASD subject.

In the voxel-based analysis, we found greater [¹¹C](R)-PK11195 BP in multiple brain regions in the ASD group than in the control group; the brain regions with increased [¹¹C](R)-PK11195 BP included the cerebellum, brainstem (midbrain and pons), subcortical region (corpus callosum), limbic region (anterior cingulate cortex), and the frontal, temporal, and parietal regions (**Table 2** and **Figure 2**). Among the brain regions, the left cerebellum showed the most prominent *z* score. There were no voxels in which controls had a significantly higher [¹¹C](R)-PK11195 BP compared with that of the ASD group. In the ASD group, there was no significant difference in [¹¹C](R)-PK11195 BP between the 2 diagnoses—that is, autistic disorder ($n = 15$) or pervasive developmental disorder not otherwise specified ($n = 5$).

On the basis of the results of the voxel-based analysis, we then conducted VOI-based analysis. We placed 14 spherical VOIs of 5-mm radius, which centered on the peak voxels listed in Table 2. In accordance with the findings derived from the voxel-based analysis, the [¹¹C](R)-PK11195 BP was significantly higher in ASD subjects than in control subjects throughout all VOIs (**Figure 3**; $F_{13,532} = 17.62, P < .001$). As shown in Figure 3, the mean [¹¹C](R)-PK11195 BP was highest in the brainstem, followed by the left cerebellum, right orbitofrontal cortex, right anterior cingulate cortex, and other regions in the control group. The corresponding rank order was essentially the same in the ASD group. Thus, the pattern of distribution of [¹¹C](R)-PK11195 BP values throughout the VOI was quite similar between the 2 groups. **Figure 4** shows a scatterplot of [¹¹C](R)-PK11195 BP from the 4 VOIs (the left cerebellum, midbrain, right orbitofrontal cortex, and right anterior cingulate cortex) in the ASD and control groups. Although the overall average level of [¹¹C](R)-PK11195 BP was higher in the ASD group than in the control group, the BPs of some ASD subjects overlapped those of the controls in the 4 VOIs.

CORRELATION BETWEEN [¹¹C](R)-PK11195 BP AND SYMPTOMS IN ASD

Relationships between the regional changes in [¹¹C](R)-PK11195 BP values and the clinical features of ASD subjects were evaluated by voxel-based exploratory correlation analyses using SPM5. There was no voxel for which significant correlations were observed between [¹¹C](R)-

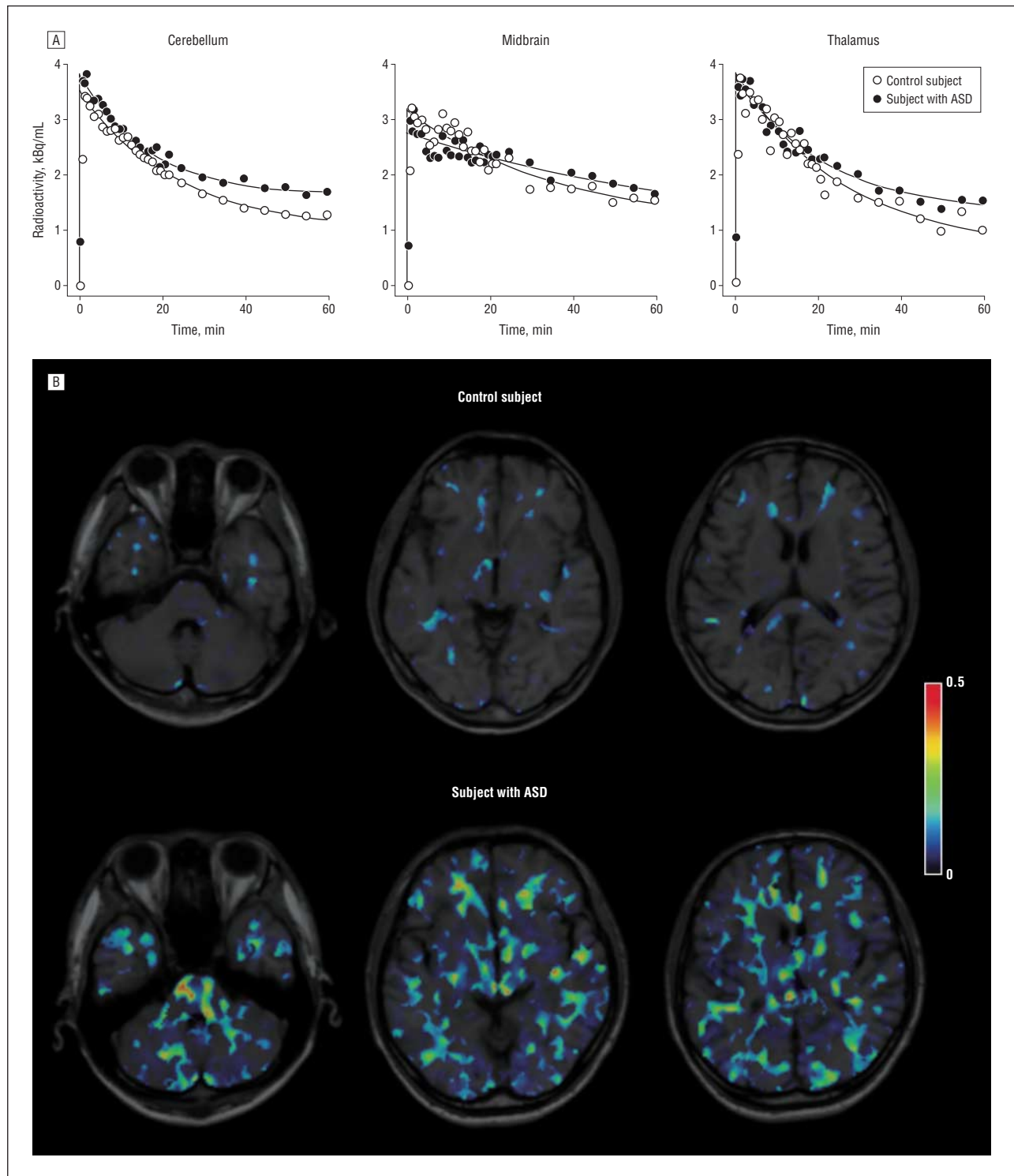


Figure 1. Results of positron emission tomography image analyses in a healthy control subject and a subject with autism. A, Scattergrams showing the time-activity curves of radiocarbon (^{11}C)-labeled (*R*)-(1-[2-chlorophenyl]-*N*-methyl-*N*-[1-methylpropyl]-3-isoquinoline carboxamide) (^{11}C)(*R*)-PK11195 for regions of interest in the cerebellum, midbrain, and thalamus in a subject with autism spectrum disorder (ASD) and a control subject. B, Magnetic resonance imaging–positron emission tomography fusion parametric images of ^{11}C (*R*)-PK11195 binding potential in a subject with ASD and a control subject. The left brain is shown on the right. The color bar indicates a level of binding potential.

PK11195 BP and the scores on the Faux Pas Test, Yale-Brown Obsessive Compulsive Scale, ADI-R, ADOS, or the Japanese version of the Developmental Coordination Disorder Questionnaire after the correction of whole-brain multiple comparisons (data not shown).

In the VOI-based analysis, we also conducted correlation analyses between ^{11}C (*R*)-PK11195 BP in each VOI and clinical variables, and we found no significant correlations. We divided the ASD group into 2 subgroups, a High-BP and Not-High-BP group, on the basis of the

Table 2. Results of the Whole-Brain Voxel-Based Statistical Parametric Mapping Analyses of [¹¹C](R)-PK11195 Binding Potential: Increase in Binding in the Subjects With ASD^a

Brain Regions	Coordinates			Voxel Level	
	x	y	z	Corrected P Value	z Score
Cerebellum					
Left lobuli 7, 8, and 9	-10	-58	-38	.03	4.82
Right lobuli 7 and 8	32	-76	-48	.04	3.77
Brainstem (midbrain and pons)	10	-38	-42	.03	4.56
Frontal region					
Left middle frontal gyrus, BA10, BA46	-44	50	12	.03	3.89
Left orbitofrontal cortex, BA11	-8	48	-4	.03	3.93
Right orbitofrontal cortex, BA47	14	30	-16	.03	4.32
Temporal region					
Left superior temporal gyrus, BA22	-52	-28	4	.03	3.67
Right superior temporal gyrus, BA22	50	-20	-6	.03	4.22
Left fusiform gyrus, BA37	-48	-60	-14	.03	4.16
Right fusiform gyrus, BA37	38	-58	-16	.03	4.30
Parietal region					
Right parietal cortex, BA40	28	-48	54	.03	3.70
Limbic region					
Left anterior cingulate cortex, BA32	-6	38	18	.03	4.12
Right anterior cingulate cortex, BA32	18	10	46	.04	3.47
Subcortical region					
Corpus callosum	-2	-26	16	.03	4.11

Abbreviations: ASD, autism spectrum disorder; BA, Brodmann area; [¹¹C](R)-PK11195, radioactive carbon-labeled (R)-(1-[2-chlorophenyl]-N-methyl-N-[1-methylpropyl]-3-isoquinoline carboxamide).

^aThe significance thresholds at the voxel cluster levels were $P < .05$ after false discovery rate correction for multiple comparisons across the whole brain. Coordinates are given in millimeters based on the Montreal Neurological Institute brain template. Each location is a peak within a cluster (defined as the voxel with highest z score).

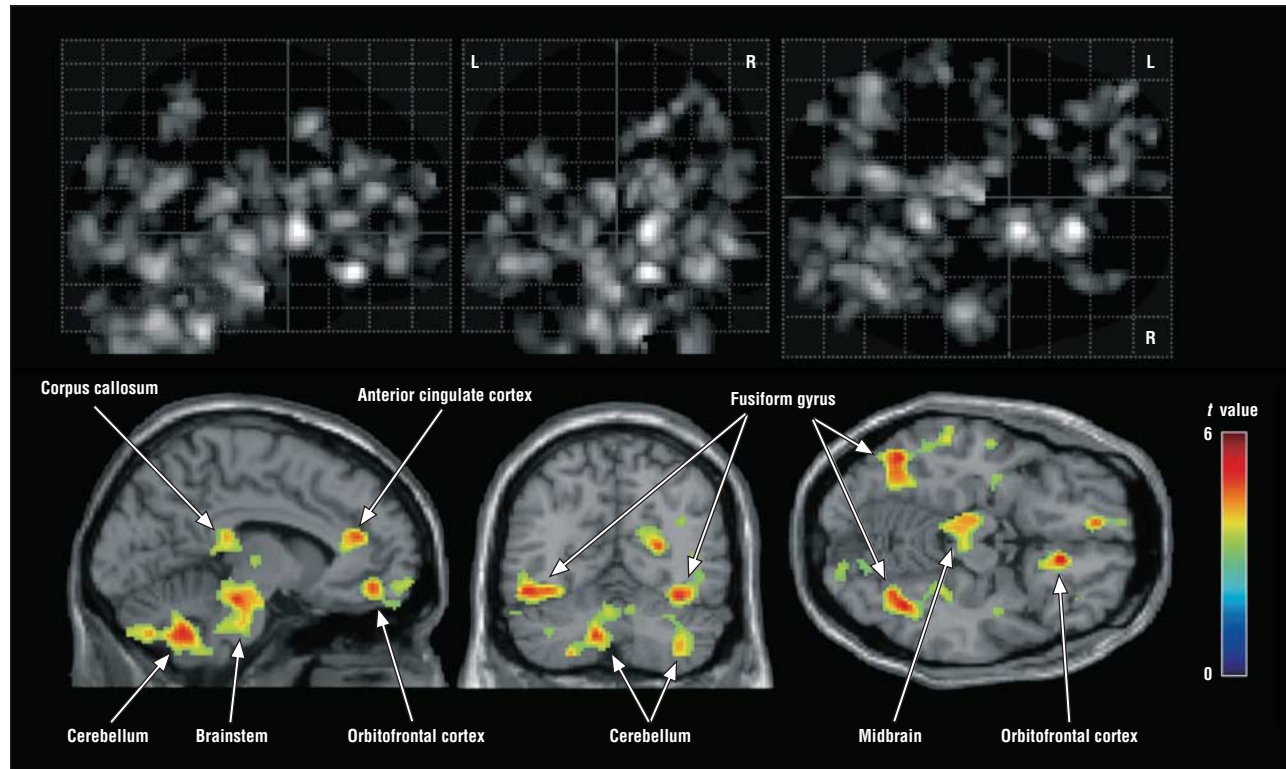


Figure 2. Results of the whole-brain voxel-based statistical parametric mapping analysis of the [¹¹C](R)-PK11195 binding potentials. Locations of clusters with significant increases in the group with autism spectrum disorder compared with the control group ($P < .05$, false discovery rate corrected) are shown on glass brain images and superimposed onto normal-template magnetic resonance images. L indicates left; and R, right.

[¹¹C](R)-PK11195 BPs in 4 VOIs respectively located in the left cerebellum, midbrain, right orbitofrontal cor-

tex, and right anterior cingulate cortex. In the VOI at the left cerebellum, 12 ASD subjects had BPs that were more

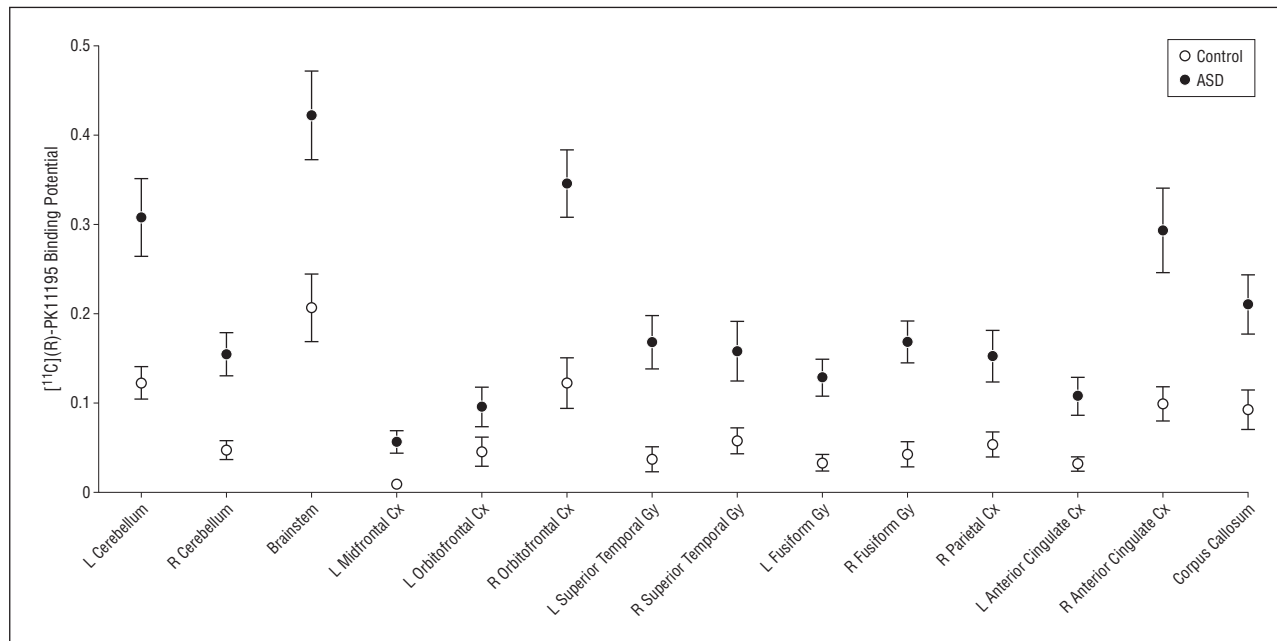


Figure 3. Regional brain [¹¹C](R)-PK11195 binding potential in the autism spectrum disorder (ASD) and control group. Subjects with ASD had significantly higher [¹¹C](R)-PK11195 binding potentials than those of controls ($F_{12,456} = 24.59$, $P < .001$). Error bars represent the SEM. Cx indicates cortex; Gy, gyrus; L, left; and R, right.

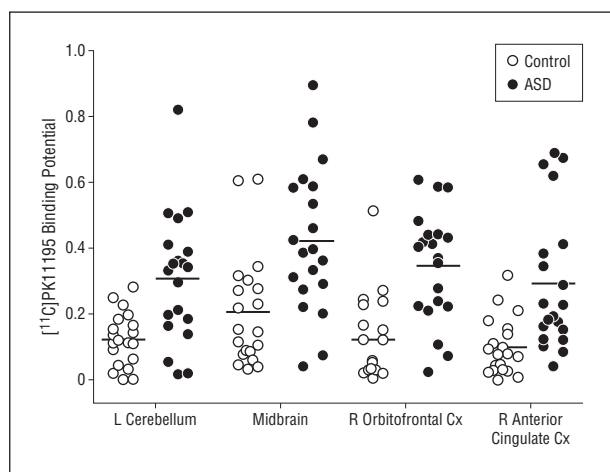


Figure 4. Scatterplot of regional [¹¹C](R)-PK11195 binding potential in the autism spectrum disorder (ASD) and control groups in 4 spherical volumes of interest placed over the left cerebellum, midbrain, right orbitofrontal cortex, and right anterior cingulate cortex.

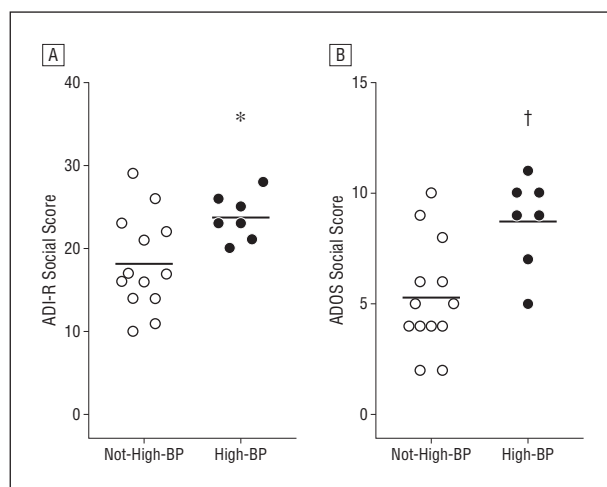


Figure 5. Comparison of social domain scores from Autism Diagnostic Interview-Revised (ADI-R) (A) and Autism Diagnostic Observation Schedule (ADOS) (B) between the High-Binding Potential (BP) and Not-High-BP subgroups in subjects with autism spectrum disorder. * $P = .03$ and † $P = .006$.

than 2 SDs higher than the mean BP of controls. The number of ASD subjects who had BPs that were more than 2 SDs higher than the mean value of the controls was 6 for the VOI in the midbrain, 10 for the VOI in the right orbitofrontal cortex, and 8 for the VOI in the right anterior cingulate cortex. Subjects with ASD who exhibited high BPs in at least 3 of the 4 VOIs were classified into a High-BP group ($n = 7$), and the remaining subjects were classified into a Not-High-BP group ($n = 13$). When clinical variables were compared between the High-BP and Not-High-BP groups, statistically significant differences were observed for the social scores of the ADI-R ($U = 19.0$, $P = .04$) and the ADOS ($U = 13.0$, $P = .01$) (**Figure 5**), suggesting that social disabilities might be more severe in the High-BP group.

COMPARISON OF REGIONAL VOLUME BETWEEN ASD SUBJECTS AND CONTROLS

The absolute volumes of the segmented brain regions were estimated in the control and ASD groups (GM: 676.3 [50.3] vs 705.8 [78.2] [control vs ASD]; WM: 421.7 [42.3] vs 439.7 [48.4]; CSF: 405.1 [47.1] vs 426.0 [50.2]; and intracranial volume: 1503.1 [123.7] vs 1571.5 [161.7]). The multivariate analysis of covariance revealed no significant differences in volume between the 2 groups (GM: $F_{1,37} = 0.006$, $P = .94$; WM: $F_{1,37} = 0.209$, $P = .65$; CSF: $F_{1,37} = 0.036$, $P = .85$). A voxel-wise 2-sample t test analysis of normalized and smoothed

GM images revealed no significant differences in GM volume between the 2 groups (data not shown).

COMMENT

Our PET measurements revealed that young adults with ASD had significantly increased [^{11}C](R)-PK11195 BP, a representative measure of the activation of microglia, in a wide range of brain areas, including the cerebellum, brainstem, anterior cingulate cortex, frontal cortex (orbitofrontal and midfrontal), temporal cortex (superior temporal and fusiform), parietal cortex, and corpus callosum. The microglial activation was greater in the ASD group than in the control group across all regions tested, although the most prominent increase was evident in the cerebellum. To our knowledge, this is the first in vivo evidence of the presence of excessive microglial activation in ASD subjects, and these findings support the contention that microglial activation may play a role in the pathogenesis of ASD.^{16,29}

When we performed a VOI-based analysis on the [^{11}C](R)-PK11195 BPs for different brain regions associated with microglial activation, the pattern of distribution of [^{11}C](R)-PK11195 BP values throughout the VOIs was quite similar between the ASD and control subjects. The similar distribution of regionally activated microglia in the ASD and control groups may indicate the augmented but not altered microglial activation in the brain in the ASD subjects. Resident microglia, which are embryonic and fetal in origin, can be replenished intrinsically and do not require significant turnover from circulating blood progenitors (monocytes)⁴⁹ (see also the review by Chan et al⁵⁰). Under pathologic conditions, however, microglia in neonates and adults are considered to derive from circulating blood monocytes originating primarily within the bone marrow.⁵⁰ In brain tissues from children and adults with ASD, macrophage chemoattractant protein-1, which can facilitate the infiltration and accumulation of blood monocytes in the brain,^{51,52} is greatly increased.¹⁶ It is also possible that microglia might respond to prolonged aberrant neuronal functioning in the ASD adults, providing trophic support to damaged cells or engaging in synaptic stripping to protect against excitotoxicity.²⁵⁻²⁸ Taken together, the excessive activation of microglia in ASD subjects could begin in the prenatal period and last until adulthood. However, we propose that the critical period for the occurrence of excessive activation of microglia as a possible pathogenic factor for ASD may be during prenatal and early postnatal development of the brain because symptoms of ASD are manifested very early in life, typically by 3 years of age. To better understand the detailed mechanism underlying the long-running microglial activation, further studies, including experiments in animal models, may be helpful.

In the present PET assessment, young adults with ASD showed a prominent activation of microglia in the cerebellum. The cerebellum has been one of the foci of postmortem studies of autistic children and adults. Of the 30 postmortem cases of autism in which the cerebellum has been studied, 22 (73%) showed a reduced number of Purkinje cells, particularly in the hemispheres.⁵³⁻⁵⁶ Patho-

logic abnormalities have been observed in both childhood and adult cases, with and without a history of seizures or medication usage. It is not known whether cerebellar lesions might have been present in the high-functioning young adults with ASD recruited for this study. Nonetheless, cerebellar activation of the microglia may reflect an association with cerebellar pathologic abnormalities, because when *N*-acetylaspartate, a putative marker of neuronal loss, was assessed by proton magnetic resonance spectroscopy, levels were significantly decreased in high-functioning adults with ASD.⁵⁷ An in vitro study has demonstrated that microglial activation can promote the death of developing Purkinje cells via reactive oxygen species⁵⁸; however, it remains unclear whether this microglia-mediated mechanism would apply in cases of ASD.

The voxel-based correlation analysis failed to find a cluster in which [^{11}C](R)-PK11195 BP correlated significantly with any of the clinical features evaluated by the Faux Pas Test, Yale-Brown Obsessive Compulsive Scale, ADI-R, and ADOS. However, when ASD subjects were divided into High-BP and Not-High-BP subgroups before being entered into the VOI-based analysis, social disabilities as assessed by ADI-R and ADOS in the High-BP subgroup were significantly more severe than in the Not-High-BP subgroup. The results suggest that ASD subjects carrying more microglial activation may be more impaired in their cognitive skills. In a previous study, immune abnormalities in peripheral blood from severely affected children with ASD, especially the regressive type of autism, appeared to correlate with the disturbance of cognitive skills.^{13,59} Considering the positive observation of the VOI-based analysis and the previous data in the ASD children with regression, the failure of the voxel-based correlation analysis was probably due to the selection of the ASD subjects, all of whom were high-functioning ASD subjects with no regression. Namely, the subject selection may have been inappropriate for comparison with studies of severely affected cases. The small subject population may be another reason for the lack of voxel-based correlation analysis. In this study, there was no correlation in the cerebellum between the [^{11}C](R)-PK11195 BP and motor coordination as assessed by the Developmental Coordination Disorder Questionnaire. Again, the selection of the high-functioning subjects and the small sample size may have contributed to the absence of correlation. Although there was no correlation of microglial activation with any of the clinical features, this could not exclude the recently emerging evidence that microglia play a crucial role in monitoring and maintaining synapses in the uninjured brain.^{27,28} During development, microglia actively engulf synaptic material and play a major role in synaptic pruning.^{60,61} Microglial activation might have led to impairment of synaptic function in the corresponding brain regions being associated with clinical features in ASD.⁶²⁻⁶⁷

Several limitations of our study bear mention. Our study was performed on a population basis and the subject group consisted entirely of high-functioning ASD subjects. That is, this study did not include ASD subtypes in which immunologic abnormality may be more prominent, although greater microglial activations are more

likely to occur in more severe subtypes. Another potential weakness was the nature of the tracer used in this study, which has a significant nonspecific binding. Future studies on a wider range of autistic phenotypes using a new ligand with more specificity would be warranted.

In conclusion, the present PET measurements revealed marked activation of microglia in multiple brain regions of young adults with ASD. The results strongly support the contention that immune abnormalities contribute to the etiology of ASD. The similar patterns of distribution of regionally activated microglia in these ASD and control groups may indicate the augmented but not altered microglial activation in the brain in the ASD subjects.

Submitted for Publication: November 22, 2011; final revision received March 27, 2012; accepted March 30, 2012.

Published Online: November 26, 2012. doi:10.1001/jamapsychiatry.2013.272

Author Affiliations: Research Center for Child Mental Development (Drs Suzuki, Sugihara, Omata, Tsuchiya, and Mori and Ms Matsumoto), United Graduate School of Child Development (Drs Suzuki, Ouchi, and Tsuchiya), Molecular Imaging Frontier Research Center (Dr Ouchi), Departments of Psychiatry and Neurology (Drs Nakamura, Takebayashi, Iwata, and Mori) and Child and Adolescent Psychiatry (Dr Sugiyama), Hamamatsu University School of Medicine, and Positron Medical Center, Hamamatsu Medical Center (Dr Ouchi and Mr Futat-subashi), Hamamatsu; Koujin Hospital, Nagoya (Dr Yoshihara); and Faculty of Sociology, Chukyo University, Toyota (Mr Tsujii), Japan.

Correspondence: Norio Mori, MD, PhD, Department of Psychiatry and Neurology, Hamamatsu University School of Medicine, 1-20-1 Handayama, Higashi-ku, Hamamatsu, Shizuoka 431-3192, Japan (morin@hama-med.ac.jp).

Author Contributions: Drs Suzuki and Sugihara contributed equally to this work.

Conflict of Interest Disclosures: None reported.

Funding/Support: This work was supported by the Strategic Research Program for Brain Sciences ("Integrated research on neuropsychiatric disorders") and a Grant-in-Aid for Scientific Research from the Ministry of Education, Culture, Sports, Science, and Technology, Japan, and by the Research on Brain Science Funds from the Ministry of Health, Labour, and Welfare, Japan.

Role of the Sponsors: These funding sources played no role in the design or conduct of the study; collection, management, analysis, or interpretation of the data; or preparation, review, or approval of the manuscript.

Additional Contributions: We are grateful to Toshihiko Kanno, MS, Etsuji Yoshikawa, MS, Wataru Ishida, MA, Taro Takahashi, PhD, Utako Matsuo, MA, Kaori Inaho, MA, and Manami Ogawa, MA, for their excellent assistance.

REFERENCES

1. American Psychiatric Association. *Diagnostic and Statistical Manual of Mental Disorders*. 4th ed. Text Rev. Washington, DC: American Psychiatric Association; 2000.
2. Baron-Cohen S, Scott FJ, Allison C, Williams J, Bolton P, Matthews FE, Brayne C. Prevalence of autism-spectrum conditions: UK school-based population study. *Br J Psychiatry*. 2009;194(6):500-509.
3. Kim YS, Leventhal BL, Koh YJ, Fombonne E, Laska E, Lim EC, Cheon KA, Kim SJ, Kim YK, Lee H, Song DH, Grinker RR. Prevalence of autism spectrum disorders in a total population sample. *Am J Psychiatry*. 2011;168(9):904-912.
4. Ashwood P, Wills S, Van de Water J. The immune response in autism: a new frontier for autism research. *J Leukoc Biol*. 2006;80(1):1-15.
5. Stigler KA, Sweeten TL, Posey DJ, McDougle CJ. Autism and immune factors: a comprehensive review. *Res Autism Spectr Disord*. 2009;3(4):840-860.
6. Warren RP, Odell JD, Warren WL, Burger RA, Maciulis A, Daniels WW, Torres AR. Strong association of the third hypervariable region of HLA-DR beta 1 with autism. *J Neuroimmunol*. 1996;67(2):97-102.
7. Warren RP, Singh VK, Cole P, Odell JD, Pingree CB, Warren WL, White E. Increased frequency of the null allele at the complement C4b locus in autism. *Clin Exp Immunol*. 1991;83(3):438-440.
8. Odell D, Maciulis A, Cutler A, Warren L, McMahon WM, Coon H, Stubbs G, Henley K, Torres A. Confirmation of the association of the C4B null allele in autism. *Hum Immunol*. 2005;66(2):140-145.
9. Croonenberghs J, Bosmans E, Deboutte D, Kenis G, Maes M. Activation of the inflammatory response system in autism. *Neuropsychobiology*. 2002;45(1):1-6.
10. Croonenberghs J, Wauters A, Devreese K, Verkerk R, Scharpe S, Bosmans E, Egedy B, Deboutte D, Maes M. Increased serum albumin, gamma globulin, immunoglobulin IgG, and IgG2 and IgG4 in autism. *Psychol Med*. 2002;32(8):1457-1463.
11. Corbett BA, Kantor AB, Schulman H, Walker WL, Lit L, Ashwood P, Rocke DM, Sharp FR. A proteomic study of serum from children with autism showing differential expression of apolipoproteins and complement proteins. *Mol Psychiatry*. 2007;12(3):292-306.
12. Schwarz E, Guest PC, Rahmoune H, Wang L, Levin Y, Ingudomnukul E, Ruta L, Kent L, Spain M, Baron-Cohen S, Bahn S. Sex-specific serum biomarker patterns in adults with Asperger's syndrome [published online September 28, 2010]. *Mol Psychiatry*. 2011;16(12):1213-1220. doi:10.1038/mp.2010.102.
13. Ashwood P, Krakowiak P, Hertz-Picciotto I, Hansen R, Pessah I, Van de Water J. Elevated plasma cytokines in autism spectrum disorders provide evidence of immune dysfunction and are associated with impaired behavioral outcome. *Brain Behav Immun*. 2011;25(1):40-45.
14. Suzuki K, Matsuzaki H, Iwata K, Kameno Y, Shimmura C, Kawai S, Yoshihara Y, Wakuda T, Takebayashi K, Takagai S, Matsumoto K, Tsuchiya KJ, Iwata Y, Nakamura K, Tsujii M, Sugiyama T, Mori N. Plasma cytokine profiles in subjects with high-functioning autism spectrum disorders. *PLoS One*. 2011;6(5):e20470. doi:10.1371/journal.pone.0020470.
15. Zimmerman AW, Jyonouchi H, Comi AM, Connors SL, Milstien S, Varsou A, Heyes MP. Cerebrospinal fluid and serum markers of inflammation in autism. *Pediatr Neurol*. 2005;33(3):195-201.
16. Vargias DL, Nascimbene C, Krishnan C, Zimmerman AW, Pardo CA. Neuroglial activation and neuroinflammation in the brain of patients with autism. *Ann Neurol*. 2005;57(1):67-81.
17. Dalton P, Deacon R, Blamire A, Pike M, McKinlay I, Stein J, Styles P, Vincent A. Maternal neuronal antibodies associated with autism and a language disorder. *Ann Neurol*. 2003;53(4):533-537.
18. Singer HS, Morris C, Gause C, Pollard M, Zimmerman AW, Pletnikov M. Prenatal exposure to antibodies from mothers of children with autism produces neurobehavioral alterations: a pregnant dam mouse model. *J Neuroimmunol*. 2009;211(1-2):39-48.
19. Braunschweig D, Ashwood P, Krakowiak P, Hertz-Picciotto I, Hansen R, Croen LA, Pessah IN, Van de Water J. Autism: maternally derived antibodies specific for fetal brain proteins. *Neurotoxicology*. 2008;29(2):226-231.
20. Croen LA, Braunschweig D, Haapanen L, Yoshida CK, Fireman B, Grether JK, Kharrazi M, Hansen RL, Ashwood P, Van de Water J. Maternal mid-pregnancy auto-antibodies to fetal brain protein: the early markers for autism study. *Biol Psychiatry*. 2008;64(7):583-588.
21. Kreutzberg GW. Microglia: a sensor for pathological events in the CNS. *Trends Neurosci*. 1996;19(8):312-318.
22. Hanisch UK, Kettenmann H. Microglia: active sensor and versatile effector cells in the normal and pathologic brain. *Nat Neurosci*. 2007;10(11):1387-1394.
23. Rezaie P, Male D. Colonisation of the developing human brain and spinal cord by microglia: a review. *Microsc Res Tech*. 1999;45(6):359-382.
24. Ginhoux F, Greter M, Leboeuf M, Nandi S, See P, Gokhan S, Mehler MF, Conway SJ, Ng LG, Stanley ER, Samokhvalov IM, Merad M. Fate-mapping analysis reveals that adult microglia derive from primitive macrophages. *Science*. 2010;330(6005):841-845.
25. Streit WJ, Conde JR, Fendrick SE, Flanary BE, Mariani CL. Role of microglia in the central nervous system's immune response. *Neurosci Res*. 2005;27(7):685-691.

26. Neumann H, Kotter MR, Franklin RJ. Debris clearance by microglia: an essential link between degeneration and regeneration. *Brain*. 2009;132(pt 2):288-295.
27. Graeber MB. Changing face of microglia. *Science*. 2010;330(6005):783-788.
28. Wake H, Moorhouse AJ, Jinno S, Kohsaka S, Nabekura J. Resting microglia directly monitor the functional state of synapses in vivo and determine the fate of ischemic terminals. *J Neurosci*. 2009;29(13):3974-3980.
29. Morgan JT, Chana G, Pardo CA, Achim C, Semendeferi K, Buckwalter J, Courchesne E, Everall IP. Microglial activation and increased microglial density observed in the dorsolateral prefrontal cortex in autism. *Biol Psychiatry*. 2010;68(4):368-376.
30. Voineagu I, Wang X, Johnston P, Lowe JK, Tian Y, Horvath S, Mill J, Cantor RM, Blencowe BJ, Geschwind DH. Transcriptomic analysis of autistic brain reveals convergent molecular pathology. *Nature*. 2011;474(7351):380-384.
31. Cagnin A, Brooks DJ, Kennedy AM, Gunn RN, Myers R, Turkheimer FE, Jones T, Banati RB. In-vivo measurement of activated microglia in dementia. *Lancet*. 2001;358(9280):461-467.
32. Banati RB. Visualising microglial activation in vivo. *Glia*. 2002;40(2):206-217.
33. Ouchi Y, Yoshikawa E, Sekine Y, Futatsubashi M, Kanno T, Ogasu T, Torizuka T. Microglial activation and dopamine terminal loss in early Parkinson's disease. *Ann Neurol*. 2005;57(2):168-175.
34. Najjar S, Pearlman D, Miller DC, Devinsky O. Refractory epilepsy associated with microglial activation. *Neurologist*. 2011;17(5):249-254.
35. Avignone E, Ulmann L, Levavasseur F, Rassendren F, Audinat E. Status epilepticus induces a particular microglial activation state characterized by enhanced purinergic signaling. *J Neurosci*. 2008;28(37):9133-9144.
36. Hashioka S, McGeer PL, Monji A, Kanba S. Anti-inflammatory effects of antidepressants: possibilities for preventives against Alzheimer's disease. *Cent Nerv Syst Agents Med Chem*. 2009;9(1):12-19.
37. Kato TA, Monji A, Mizoguchi Y, Hashioka S, Horikawa H, Seki Y, Kasai M, Utsunomiya H, Kanba S. Anti-inflammatory properties of antipsychotics via microglia modulations: are antipsychotics a "fire extinguisher" in the brain of schizophrenia? *Mini Rev Med Chem*. 2011;11(7):565-574.
38. Lord C, Rutter M, Le Couteur A. Autism Diagnostic Interview-Revised: a revised version of a diagnostic interview for caregivers of individuals with possible pervasive developmental disorders. *J Autism Dev Disord*. 1994;24(5):659-685.
39. Lord C, Risi S, Lambrecht L, Cook EH Jr, Leventhal BL, DiLavore PC, Pickles A, Rutter M. The Autism Diagnostic Observation Schedule-Generic: a standard measure of social and communication deficits associated with the spectrum of autism. *J Autism Dev Disord*. 2000;30(3):205-223.
40. First MB. *User's Guide for the Structured Clinical Interview for DSM-IV Axis I Disorders (SCID-I): Clinician Version*. Washington, DC: American Psychiatric Press; 1997.
41. Baron-Cohen S, O'Riordan M, Stone V, Jones R, Plaisted K. Recognition of faux pas by normally developing children and children with Asperger syndrome or high-functioning autism. *J Autism Dev Disord*. 1999;29(5):407-418.
42. Goodman WK, Price LH, Rasmussen SA, Mazure C, Fleischmann RL, Hill CL, Heninger GR, Charney DS. The Yale-Brown Obsessive Compulsive Scale, I: development, use, and reliability. *Arch Gen Psychiatry*. 1989;46(11):1006-1011.
43. Goodman WK, Price LH, Rasmussen SA, Mazure C, Delgado P, Heninger GR, Charney DS. The Yale-Brown Obsessive Compulsive Scale, II: validity. *Arch Gen Psychiatry*. 1989;46(11):1012-1016.
44. Nakai A, Miyachi T, Okada R, Tani I, Nakajima S, Onishi M, Fujita C, Tsujii M. Evaluation of the Japanese version of the Developmental Coordination Disorder Questionnaire as a screening tool for clumsiness of Japanese children. *Res Dev Disabil*. 2011;32(5):1615-1622.
45. Suzuki K, Sugihara G, Ouchi Y, Nakamura K, Tsujii M, Futatsubashi M, Iwata Y, Tsuchiya KJ, Matsumoto K, Takebayashi K, Wakuda T, Yoshihara Y, Suda S, Kikuchi M, Takei N, Sugiyama T, Irie T, Mori N. Reduced acetylcholinesterase activity in the fusiform gyrus in adults with autism spectrum disorders. *Arch Gen Psychiatry*. 2011;68(3):306-313.
46. Lammertsma AA, Hume SP. Simplified reference tissue model for PET receptor studies. *Neuroimage*. 1996;4(3, pt 1):153-158.
47. Gunn RN, Lammertsma AA, Hume SP, Cunningham VJ. Parametric imaging of ligand-receptor binding in PET using a simplified reference region model. *Neuroimage*. 1997;6(4):279-287.
48. Schuitmaker A, van Berckel BN, Kropholler MA, Veltman DJ, Scheltens P, Jonker C, Lammertsma AA, Boellaard R. SPM analysis of parametric (R)-[¹¹C]PK11195 binding images: plasma input versus reference tissue parametric methods. *Neuroimage*. 2007;35(4):1473-1479.
49. Kennedy DW, Abkowitz JL. Kinetics of central nervous system microglial and macrophage engraftment: analysis using a transgenic bone marrow transplantation model. *Blood*. 1997;90(3):986-993.
50. Chan WY, Kohsaka S, Rezaie P. The origin and cell lineage of microglia: new concepts. *Brain Res Rev*. 2007;53(2):344-354.
51. Man S, Ubogu EE, Ransohoff RM. Inflammatory cell migration into the central nervous system: a few new twists on an old tale. *Brain Pathol*. 2007;17(2):243-250.
52. Rebenko-Moll NM, Liu L, Cardona A, Ransohoff RM. Chemokines, mononuclear cells, and the nervous system: heaven (or hell) is in the details. *Curr Opin Immunol*. 2006;18(6):683-689.
53. Bailey A, Luthert P, Dean A, Harding B, Janota I, Montgomery M, Rutter M, Lantos P. A clinicopathological study of autism. *Brain*. 1998;121(pt 5):889-905.
54. Ritvo ER, Freeman BJ, Scheibel AB, Duong T, Robinson H, Guthrie D, Ritvo A. Lower Purkinje cell counts in the cerebella of four autistic subjects: initial findings of the UCLA-NSAC Autopsy Research Report. *Am J Psychiatry*. 1986;143(7):862-866.
55. Palmén SJ, van Engeland H, Hof PR, Schmitz C. Neuropathological findings in autism. *Brain*. 2004;127(pt 12):2572-2583.
56. Bauman ML, Kemper TL. Neuroanatomic observations of the brain in autism: a review and future directions. *Int J Dev Neurosci*. 2005;23(2-3):183-187.
57. Suzuki K, Nishimura K, Sugihara G, Nakamura K, Tsuchiya KJ, Matsumoto K, Takebayashi K, Isoda H, Sakahara H, Sugiyama T, Tsujii M, Takei N, Mori N. Metabolic alterations in the hippocampus of high-functioning adult subjects with autism. *Int J Neuropsychopharmacol*. 2010;13(4):529-534.
58. Marín-Teva JL, Dusart I, Colin C, Gervais A, van Rooijen N, Mallat M. Microglia promote the death of developing Purkinje cells. *Neuron*. 2004;41(4):535-547.
59. Ashwood P, Krakowiak P, Hertz-Picciotto I, Hansen R, Pessah IN, Van de Water J. Associations of impaired behaviors with elevated plasma chemokines in autism spectrum disorders. *J Neuroimmunol*. 2011;232(1-2):196-199.
60. Paolicelli RC, Bolasco G, Pagani F, Maggi L, Scianni M, Panzanelli P, Giustetto M, Ferreira TA, Guiducci E, Dumas L, Ragozzino D, Gross CT. Synaptic pruning by microglia is necessary for normal brain development. *Science*. 2011;333(6048):1456-1458.
61. Schlegelmilch T, Henke K, Peri F. Microglia in the developing brain: from immunity to behaviour. *Curr Opin Neurobiol*. 2011;21(1):5-10.
62. Pierce K, Courchesne E. Evidence for a cerebellar role in reduced exploration and stereotyped behavior in autism. *Biol Psychiatry*. 2001;49(8):655-664.
63. Allen G, Müller RA, Courchesne E. Cerebellar function in autism: functional magnetic resonance image activation during a simple motor task. *Biol Psychiatry*. 2004;56(4):269-278.
64. Ornitz EM, Atwell CW, Kaplan AR, Westlake JR. Brain-stem dysfunction in autism: results of vestibular stimulation. *Arch Gen Psychiatry*. 1985;42(10):1018-1025.
65. Minshew NJ, Keller TA. The nature of brain dysfunction in autism: functional brain imaging studies. *Curr Opin Neurol*. 2010;23(2):124-130.
66. Nakamura K, Sekine Y, Ouchi Y, Tsujii M, Yoshikawa E, Futatsubashi M, Tsuchiya KJ, Sugihara G, Iwata Y, Suzuki K, Matsuzaki H, Suda S, Sugiyama T, Takei N, Mori N. Brain serotonin and dopamine transporter bindings in adults with high-functioning autism. *Arch Gen Psychiatry*. 2010;67(1):59-68.
67. Friedman SD, Shaw DW, Artru AA, Dawson G, Petropoulos H, Dager SR. Gray and white matter brain chemistry in young children with autism. *Arch Gen Psychiatry*. 2006;63(7):786-794.