ORIGINAL ARTICLE

In Vivo Evaluation of Brain Iron in Alzheimer Disease Using Magnetic Resonance Imaging

George Bartzokis, MD; David Sultzer, MD; Jeffrey Cummings, MD; Lori E. Holt, PhD; Darwood B. Hance, MD; Victor W. Henderson, MD; Jim Mintz, PhD

Background: The basal ganglia contain the highest levels of iron in the brain, and postmortem studies indicate a disruption of iron metabolism in the basal ganglia of patients with Alzheimer disease (AD). Iron can catalyze free radical reactions and may contribute to oxidative damage observed in AD brains. Treatments aimed at reducing oxidative damage have offered novel ways to delay the rate of progression and could possibly defer the onset of AD. Brain iron levels were quantified in vivo using a new magnetic resonance imaging method.

Methods: Thirty-one patients with AD and 68 control subjects participated in this study. A magnetic resonance imaging method was employed that quantifies the iron content of ferritin molecules (ferritin iron) with specificity through the combined use of high and low field-strength magnetic resonance imaging instruments. Three basal ganglia structures (caudate, putamen, and globus pallidus) and one comparison region (frontal lobe white matter) were evaluated.

Results: Basal ganglia ferritin iron levels were significantly increased in the caudate ($P = .007$; effect size, 0.69) and putamen ($P = .008$; effect size, 0.67) of AD subjects, with a trend toward an increase in the globus pallidus ($P = .13$). The increased basal ganglia ferritin iron levels were not a generalized phenomenon; white matter ferritin iron levels were unchanged in patients with AD ($P = .50$).

Conclusions: The data replicate and extend prior results and suggest that basal ganglia ferritin iron levels are increased in AD. Prospective studies are needed to evaluate whether premorbid iron levels are increased in individuals who develop AD.

Arch Gen Psychiatry. 2000;57:47-53

From the Department of Psychiatry, University of Arkansas for Medical Sciences and the Mental Health Service, Central Arkansas Veterans Healthcare System, Little Rock (Dr Bartzokis); and the Mental Health Service, Department of Veterans Affairs Greater Los Angeles Healthcare System (Drs Bartzokis, Sultzer, and Mintz), the Departments of Psychiatry (Drs Bartzokis, Sultzer, Holt, and Mintz), Neurology (Dr Cummings), and Radiology (Dr Hance), University of California at Los Angeles, and the Department of Neurology, University of Southern California (Dr Henderson), Los Angeles.

THE INCIDENCE rate of Alzheimer disease (AD) increases dramatically with age.[1] Oxidative damage of the human brain also has been shown to be strongly age-related[2,3] and has been implicated in the pathophysiology of AD.[2,4-11]

Tissue iron can promote oxidative damage by catalyzing free-radical reactions, resulting in the formation of hydroxyl radical (the most reactive free-radical species), which denatures protein and DNA and initiates lipid peroxidation.[12] As with oxidative damage, brain iron levels increase with age.[13-16] Studies of bulk brain iron have reported increased iron levels in AD brains,[17-22] as have studies examining ferritin levels,[19,23] a spherical protein in which upwards of 90% of tissue nonheme iron is stored.[24,25] Although ferritin can sequester and store as many as 4500 iron atoms, many normal as well as pathologic processes can release iron from ferritin.[12,26-29] Toxins that disrupt metabolism and result in increased lactate levels with decreasing pH will release iron from the ferritin stores.[30] In addition, increases in reactive oxygen species may also release iron from ferritin,[30] as do other changes, such as increased nitric oxide levels.[31] Iron has been shown to interact with β-amyloid to promote neurotoxicity,[32] and increased iron and ferritin has been associated with senile plaques and neurofibrillary tangles, the hallmarks of AD neuropathology.[17,23,33-42]

Magnetic resonance imaging (MRI) instruments produce images whose contrast depends on differences in the way tissues interact with the magnetic field of the MRI instrument. The iron atoms inside ferritin molecules form ferric oxyhydroxide particles, which profoundly affect the magnetic field, thus shortening the transverse relaxation time (T2). Magnetic resonance imaging images that are sensitive to this T2 effect (referred to as *T2-weighted images*) become darker in regions with high iron content (**Figure 1**). However, the possibility of using simple T2 measures to investigate tissue iron levels has

©2000 American Medical Association. All rights reserved.
Downloaded From: http://archpsyc.jamanetwork.com/ on 09/02/2014

SUBJECTS AND METHODS

SUBJECTS

Initially, 49 subjects with AD participated in the MRI procedure after informed consent was obtained from subject and/or guardian. All participants were originally recruited from clinics associated with 2 metropolitan AD centers. Patients in these clinics undergo complete clinical assessment that includes review of clinical history, medical problems, medication use, comprehensive psychiatric and cognitive examination, blood chemistry analysis, and structural neuroimaging. All participants met National Institute of Neurological and Communicative Disorders and Stroke–Alzheimer's Disease and Related Disorders Association (NINCDS-ADRDA) diagnostic criteria[66] for probable or possible Alzheimer disease, as diagnosed by center-affiliated physicians. Participants were also required to speak English and have none of the following: ferromagnetic devices or implants, unstable medical illnesses or neurologic disorders that could cause cognitive deficits, history of substance use disorder within the past 2 years or prior use likely to lead to central nervous system impairment, and history of traumatic brain injury resulting in neurologic sequelae.

Eighteen of these 49 subjects were excluded from further analysis for the following reasons: 13 had unratable MRI data caused by motion or technical image artifact; 2 had a history of severe head trauma (with loss of consciousness for longer than 15 minutes) and/or seizures; 2 had a cortical infarct or a pattern consistent with multi-infarct dementia on MRI; and 1 was an outlier on the basis of age (95 years, more than 2 SDs higher than the mean age for both the AD and control groups).

The final AD population (n = 31) ranged in age from 59 to 85 years (mean, 75.6 years [SD, 6.7 years]) and consisted of 14 men and 17 women (26 whites [84%], 2 African Americans [6%], 2 Hispanics [6%], and 1 Asian [3%]); most (87% [n = 27]) were taking medications or vitamin supplements (18 [58%], psychoactive medications [eg, cholinesterase inhibitors, antidepressants]; 16 (52%), vitamin supplements [eg, E, C]; and 21 [68%], somatic medications for chronic but stable medical problems [eg, cardiovascular, arthritis]). Of the 31 subjects with AD, 27 met the NINCDS-ADRDA[66] criteria for probable and 4 for possible AD, and all had mild to severe AD, with Mini–Mental State Examination[67] scores ranging between 0 and 26 (mean, 17.3 [SD, 7.39]), an age of symptom onset ranging from 53.5 to 81 years (mean, 70.1 years [SD, 6.6 years]), and a length of illness (based on caregiver and/or medical record report of when symptoms were first noticed) ranging between 2 and 10 years (mean, 5.4 years [SD, 2.3 years]).

Seventy-six adult volunteers were recruited from the community and hospital staff and participated in the study as control subjects. Control subjects were excluded if they had a history of central nervous system disorder or head trauma resulting in loss of consciousness for longer than 15 minutes or if there was a family history of AD or another neurodegenerative disorder. Eight subjects were excluded from further analysis: 7 had unratable MRI data caused by technical image artifact and 1 had basal ganglia lesions on MRI examination. The final control population (n = 68) ranged in age from 59 to 82 years (mean, 68.8 years [SD, 5.3 years]) and consisted of 36 men and 32 women (59 whites [87%], 8 African Americans [12%], and 1 Asian [1%]). All control subjects denied problems with memory and scored between 27 and 30 (mean, 28.4 [SD, 0.92]) on the Mini–Mental State Examination.

MRI PROTOCOL

The methods have been described in detail elsewhere[15] and will only be summarized herein, since the principal difference consisted of the use of a new set of MRI instruments. All subjects were scanned using the same 2 MRI instruments (1.5 T and 0.5 T; Picker Instruments, Cleveland, Ohio), and the 2 scans were done within 1 hour of each other using the same imaging protocol.

Two pilot sequences were obtained to specify the location and spatial orientation of the head and the position of the axial image acquisition grid. A coronal pilot spin-echo image (repetition time [TR], 100 milliseconds; echo time [TE], 30 milliseconds; number of excitations, 1) of 10-mm thickness was acquired and used to align the subsequent sagittal pilot images. The middle slice of the sagittal pilot images was aligned on the coronal pilot to obtain a true midsagittal image of brain. After the sagittal pilot spin-echo images (TR, 550 milliseconds; TE, 26 milliseconds; number of excitations, 2) of 5-mm thickness were acquired, the midsagittal image was used to position the axial-image acquisition grid. The axial-image acquisition sequence acquired interleaved contiguous slices using a Carr Purcell Meiboom Gill dual-spin echo sequence (TR, 2500 milliseconds; TE, 20 and 90 milliseconds; number of excitations, 2; slice thickness, 3 mm; gradient steps, 192; field of view, 25 cm).

The coronal and sagittal pilot scans were used to determine the alignment and accuracy of head repositioning in the second MRI instrument. To consistently position the actual image slices identically within the brain and thus sample the same volume of tissue, the axial-slice select grid

been unrealized[43-47] because T2 shortening is not a specific marker of tissue iron, as many tissue characteristics can affect this measure.[15,48-50] For example, in addition to iron, the increased viscosity/density of the tightly packed myelinated axons of white matter can also shorten T2 (Figure 1). Thus, white matter has a T2 similar to caudate and putamen,[15] yet has only about half the iron of these structures.[13,15] Even more importantly, many pathologic processes increase the amount of tissue water detected by MRI instruments (MR visible water), and that water causes a marked increase in T2, which causes T2-weighted images to get brighter.[51] Since the T2 of tissue water, such as cerebrospinal fluid (Figure 1), is longer than 1000 milliseconds, while the T2 of brain parenchyma is shorter than 100 milliseconds, relatively small increases in MR visible water will lengthen the T2 and mask any T2 shortening caused by increased tissue iron levels.[52]

Fortunately, the ferric oxyhydroxide particles inside ferritin molecules have magnetic properties that give ferritin the unique property of causing more T2 shortening in an MRI instrument that uses a strong magnet

©2000 American Medical Association. All rights reserved.
Downloaded From: http://archpsyc.jamanetwork.com/ on 09/02/2014

was adjusted so that the anterior commissure was contained within the same slice in both high and low field-strength instruments. For increased consistency all subsequent measures were referenced to this slice.[15]

IMAGE ANALYSIS

The T2 was calculated for each voxel by an automated algorithm from the 2 signal intensities (TEs, 20 and 90 milliseconds) of the dual-spin echo sequence to produce gray scale–encoded T2 maps of the brain.[15]

The T2 measures were extracted using an Apple Macintosh configured image analysis workstation (Apple Computer Inc, Cupertino, Calif). A single rater who was blind to clinical information obtained all measurements. The image analysis software permitted the rater to delineate the region of interest using a mouse. The contours of the entire cross-sectional area of head of the caudate, putamen, and globus pallidus and a sample of frontal lobe white matter were drawn manually by the rater using the gray and white matter contrast of the early echo (TE, 20 milliseconds) images and were then transferred onto the T2 maps.

To obtain T2 measures of homogeneous brain tissue, all pixels with T2 values that fell above the right-side inflection point on the histogram distribution of the region of interest were eliminated. This minimized the influence of voxels containing small, partial volumes of cerebrospinal fluid, which can markedly increase the T2 of the voxel. Thus, the final measure was the average T2 for the remaining homogeneous region of brain tissue.[15]

The T2 data for each of the 4 regions of interest were obtained from contiguous pairs of slices. The slice containing the anterior commissure and the slice immediately superior to it were used to obtain the putamen and globus pallidus T2 data. The third and fourth slices above the anterior commissure were used to obtain the T2 data for the caudate nucleus and the second and third slices superior to the orbitofrontal gray matter were used to obtain the frontal lobe white matter data. The relaxation rate (R_2) was calculated as the reciprocal of T2 × 1000 ms/s. The average R_2 values of the 2 slices from both hemispheres were the final measures used in the subsequent analyses. The FDRI measure was calculated as the difference in R_2 (high-field R_2–low-field R_2). Test-retest reliability for FDRI measures was very high, with intraclass correlation coefficients ranging from 0.88 to 0.99 ($P<.002$).[15]

STATISTICAL METHODS

As a check on the validity of the FDRI method, mean FDRI measures from the 68 control subjects in the 4 regions (**Table**) were correlated with postmortem iron levels in normal adults published by Hallgren and Sourander[13] (Figure 2). In their study, Hallgren and Sourander[13] measured nonheme iron content histologically (milligrams of iron per 100 g of fresh tissue) in human brain specimens of normal individuals aged 30 to 100 years, thus providing reference values for the various brain regions (mean±SD: caudate, 9.28 ± 2.14 [n = 58]; globus pallidus, 21.3 ± 3.49 [n = 55]; putamen, 13.32 ± 3.43 [n = 56]; and frontal white matter, 4.24 ± 0.88 [n = 59]) used to validate in vivo methods of measuring iron levels.[15,16,50,56,59-61] Although Hallgren and Sourander[13] did not report the mean age of their sample, the age range of our control subject sample (59-82 years) is within the age range of their sample (30-100 years).

An analysis of covariance design with diagnosis (AD vs controls) as the independent variable and age and sex as covariates was used to determine whether subjects with AD had increased iron in the basal ganglia. Separate analyses of covariance were computed in each region. The specificity of the results was checked by performing an additional analysis on FDRI in the white matter, where differences in iron content between AD and control subjects were not expected based on our pilot data.[50] Age and sex were included as covariates in all analyses because of the known effects of age on brain ferritin iron levels[13] and the possible effects of sex on tissue iron status,[68] even though simple *t* tests (uncorrected for age and sex) result in the same significant findings as the analysis of covariance results we report. Preliminary analyses indicated that the interactions of diagnosis with age and sex were not significant, so those terms were dropped from the final models. In addition, an analysis controlling for structure volume was done to investigate possible effects of atrophy on FDRI.

Finally, separate analyses of high- and low-field R_2 were done in each of the basal ganglia regions and white matter using the same analysis of covariance design. These analyses of the separate field strengths were done to evaluate whether they added diagnostically relevant information in the white matter region, as suggested in our prior report.[50] Whereas the FDRI is a relatively specific measure of brain ferritin iron, high- and low-field measures of R_2 are strongly influenced by other variables, such as MR visible water.

To evaluate whether illness length affected the results, the AD sample was segregated into 2 groups according to illness duration: less than 5 years (n = 15) and 5 years or more (n = 16). These 2 groups were compared by *t* tests for differences in age and FDRI and by χ^2 test for differences in sex.

All statistical tests were 2-tailed, and $\alpha = .05$ a priori.

than in an instrument that uses a weaker magnet (field-dependent T2 shortening). In human tissue, ferritin and its breakdown product (hemosiderin) are the only physiologic sources of such iron particles, which will hereafter be referred to as *ferritin iron*.[53-56]

Mathematical manipulations of relaxation time measurements require the transformation of T2 (measured in milliseconds) into transverse relaxation rates (R_2) (expressed in seconds–1) using the simple formula, $R_2 = 1/(T2 \times 1000$ ms/s). An MRI technique called *field-dependent R_2 increase* (FDRI) uses the unique field-dependent effect of ferritin iron on R_2 to quantify brain ferritin iron levels with specificity.[15,16,50,53] Briefly, FDRI is the difference in measures of tissue R_2 obtained with 2 different field-strength MRI instruments (1.5 T and 0.5 T). In the presence of ferritin, R_2 increases with increasing magnetic field strength.[15,16,50,53,54,56-58] This field-dependent R_2 increase is specifically associated with the total iron contained in ferritin molecules[53,54] and has been shown to be independent of the amount of iron loading (number of iron atoms per ferritin molecule) of ferritin[57] and to be linearly related to field strength.[54,57,58]

©2000 American Medical Association. All rights reserved.
Downloaded From: http://archpsyc.jamanetwork.com/ on 09/02/2014

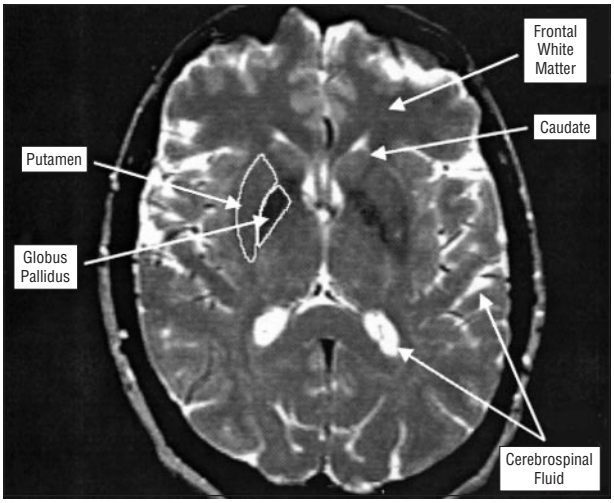

Figure 1. *A representative image of a control subject, showing one of the slices from which the putamen and globus pallidus data (outlined) are acquired. The caudate and frontal white matter regions are also indicated, as are bright cerebrospinal fluid regions. This T2-weighted image acquired with a high field-strength (1.5-T) magnetic resonance imaging instrument is sensitive to the effect of ferritin iron. The T2-shortening (image darkening) effect of iron is evident in regions with high iron levels, such as the globus pallidus. However, simple T2 measures are not specific for ferritin iron. This is demonstrated by examining the white matter region, which is as dark as the caudate and putamen even though it has only about half their content. The T2 shortening observed in the white matter is not caused by its ferritin content but primarily by its structural properties (eg, increased viscosity/density of the tightly packed myelinated axons).*

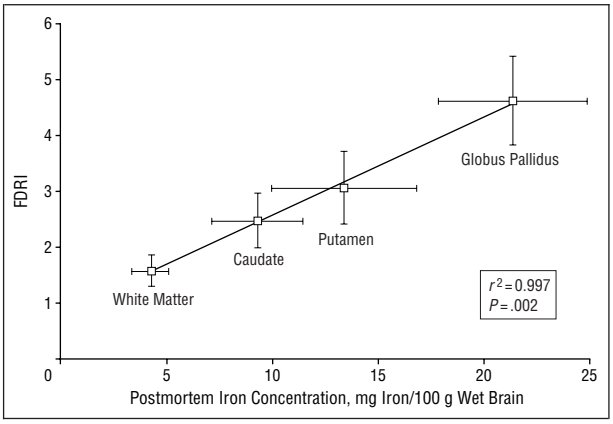

Figure 2. *Field-dependent relaxation rate (R_2) increase (FDRI) in control subjects vs postmortem iron concentrations in normal individuals. The FDRI is defined as the difference in the R_2 values of each brain region obtained using high (1.5-T) and low (0.5-T) field-strength magnetic resonance imaging instruments. The FDRI data are the means from 68 normal subjects 59 to 82 years of age. The postmortem data are the mean iron concentrations from 55 to 59 normal subjects aged 30 to 100 years (from Hallgren and Sourander[13]).*

Using a nonhuman primate model of hepatic hemosiderosis, a very high correlation (r = 0.94) between liver tissue iron levels and field-dependent changes in R_2 was demonstrated.[55] Finally, Hallgren and Sourander[13] published the mean iron concentration of various brain structures of a postmortem sample of normal older individuals between the ages of 30 and 100 years (in whom age-related increases in iron content are reduced and seem to eventually plateau compared with marked age-related increases in iron content seen in younger populations). Their data has served as a reference used to compare and validate in vivo measures of brain iron,[15,16,50,56,59-61] and FDRI measures of normal older individuals are highly correlated with their postmortem data (**Figure 2**). Thus, the FDRI measure is a specific, albeit indirect, measure of tissue ferritin iron.

The basal ganglia contain the highest levels of iron in the brain.[13-15] A prior pilot FDRI study performed on a small sample of men suggested that ferritin iron levels in the basal ganglia of patients with AD are increased when compared with control subjects.[50] This observation was in agreement with postmortem data indicating that basal ganglia iron homeostasis may be disrupted in AD[62-64] and that iron levels may be increased.[21,65] In the current study the FDRI method was used to evaluate brain ferritin iron in a new sample of male and female patients with AD and control subjects.

RESULTS

The AD and control groups differed in age (AD: mean, 75.6 years [SD, 6.7 years]; controls: mean, 68.8 years [SD, 5.3 years]) (t_{97} = 5.42; P<.001) but did not differ in sex (χ^2_1 = 0.516; P = .47) or race (χ^2_3 = 5.33; P = .15). In this older age range, correlations between age and FDRI did not reach significance for either the control or AD groups in any of the 4 structures (P>.25).

The relationship among FDRI measures of ferritin iron in caudate, putamen, globus pallidus, and white matter of our control group and published postmortem measures of iron in the same structures of normal individuals[13] was virtually linear (Figure 2) (r^2 = 0.997; P = .002).

For the 3 basal ganglia regions, FDRI was significantly different between AD and control subjects in the caudate and putamen (Table). These differences remain significant even after experimentwise adjustment of significance levels (Bonferroni correction). Controlling for structure volume did not alter the interpretation of either result (P = .02 for caudate and P = .009 for putamen).

Summary statistics for R_2 in the 4 brain regions of the AD and control groups are displayed separately at each of 2 field strengths (0.5 T and 1.5 T) (Table). The R_2 data show that the high field-strength (1.5-T) instrument, which is more affected by ferritin iron than the low field-strength (0.5-T) instrument, detected differences between AD and control subjects in the caudate and putamen. However, unlike the FDRI, which is a specific measure of ferritin iron, the high field-strength R_2 differences only reached conventional levels of significance (P<.05, not adjusted for multiple tests [Bonferroni]).

In addition, the R_2 analyses revealed highly significant differences between AD and control subjects in the white matter R_2 at both high and low field strength (Table). The difference remains significant even after Bonferroni correction.

Illness duration did not affect the results; when the AD subjects were separated into 2 groups according to illness duration, the 2 groups did not differ significantly (P>.30) in age, sex, or FDRI in any of the 4 regions of interest.

©2000 American Medical Association. All rights reserved.
Downloaded From: http://archpsyc.jamanetwork.com/ on 09/02/2014

Mean Field-Dependent Relaxation Rate (R_2 Increases (FDRI) and High and Low Field-Strength R_2 Values in Patients With Alzheimer Disease (AD) and Control Subjects in 3 Basal Ganglia Regions and 1 Comparison Region*

	FDRI†					High-Field R_2				Low-Field R_2			
Structure	AD (n = 31)‡	Control (n = 68)	F§	*P*§	d′‖	AD (n = 31)‡	Control (n = 68)	F§	*P*§	AD (n = 31)‡	Control (n = 68)	F§	*P*§
Caudate	2.81 (0.48)	2.49 (0.49)	7.53	.007	0.69	15.87 (0.63)	15.58 (0.70)	4.03	.048	13.06 (0.46)	13.09 (0.32)	0.01	.93
Putamen	3.59 (0.95)	3.07 (0.66)	7.28	.008	0.67	17.69 (1.31)	17.17 (0.94)	5.22	.025	14.09 (0.57)	14.11 (0.40)	0.70	.40
Globus pallidus	4.80 (1.03)	4.64 (0.79)	2.28	.13	0.38	19.32 (1.44)	19.37 (1.12)	1.73	.19	14.52 (0.60)	14.74 (0.51)	0.25	.62
White matter	1.46 (0.29)	1.57 (0.28)	0.50	.48	–0.18	14.61 (0.75)	15.62 (0.52)	27.40	.0001	13.16 (0.73)	14.05 (0.48)	26.40	.0001

*Values are per second. Data are presented as the unadjusted mean (SD). d′ indicates the effect size indec (calculated).

†The FDRI is an estimate of ferritin iron defined as the difference in the R_2 values of each brain region obtained using high (0.5 T) and low (0.5 T) field-strength magnetic resonance imaging instruments.

‡For AD white matter, n = 30.

§Based on an analysis of covariance model with age and sex as covariates: df = 1, 95 for the caudate, globus pallidus, and putamen; df = 1, 94 for white matter.

‖The difference in the covariate-adjusted means divided by the root mean square error (covariance-adjusted and pooled within-cell SD).

COMMENT

The data demonstrate significantly increased ferritin iron levels as measured by the FDRI method in the caudate and putamen of patients with AD. The data suggest that the increase in ferritin iron is specific to the caudate and putamen, since white matter ferritin iron did not differ between patients with AD and control subjects. This result is consistent with postmortem data suggesting that basal ganglia iron homeostasis may be disrupted in AD as indicated by decreased transferrin-iron ratios,[62] increased ceruloplasmin levels (a protein that can be increased by increased iron levels),[63] mild (5%-15%) increases in iron levels,[21,65] and absence of the expected age-related increases in levels of ferritin subunits in AD basal ganglia.[64] The report of no change in ferritin levels with aging in AD[64] suggests that the increase in FDRI we observed could be interpreted as an elevation in iron content per ferritin molecule in the basal ganglia of patients with AD. This possibility is supported by one autopsy study suggesting that ferritin from AD brains contains more iron ions per ferritin molecule than ferritin from normal brains.[69]

The significantly decreased white matter R_2 observed in the AD group with both high- and low-field instruments (Table) could be caused by either increased MR visible water[51] or decreased iron. The latter possibility is refuted by the FDRI data (Table). Therefore, the significantly decreased white matter R_2 observed in the AD group is consistent with earlier MRI reports suggesting processes that increase MR visible water, such as myelin loss or tissue water increase, in the AD brain.[70-74]

As shown in the Table, low-field R_2 seems to be a relatively pure measure of this second field-strength–independent process that decreases R_2 in the white matter of AD. The low-field instrument also shows no evidence of increased R_2 values in the caudate or globus pallidus of patients with AD since it is minimally affected by ferritin. Thus, the low-field R_2 measure provides a basis for "correction" of the high-field R_2 measure, subtracting variance associated with field-strength–independent effects on R_2.[15,52,53] Conversely, although the high-field R_2 measure is affected by ferritin iron and can detect differences in basal ganglia ferritin iron levels between the control and AD groups (Table), better discrimination is obtained with the FDRI method since the variance associated with field-strength–independent effects is eliminated (Table).

Important limitations of this study need to be considered when interpreting the data. The cross-sectional design could obscure some of the AD-vs-control differences in FDRI and R_2. This could happen if brain iron levels are associated with mortality and/or accelerated debilitation that cause patients to be excluded from, unable to participate in, or unable to complete the study. In addition, in a cross-sectional study, only limited inferences can be made about the causal relationship between increased iron levels and AD pathologic findings. It was not feasible to examine neocortical structures in this study, despite their relevance to AD. Accurate FDRI measurements require that the same tissue be identified and measured in the 2 different MRI scans. At present, this is technically difficult since the cortex is very thin and convoluted. Finally, the AD and control groups differed in mean age. However, in this age range (59 years and older), age and FDRI were not significantly correlated for either the control or AD group, and in addition, age was controlled for statistically by including it as a covariate in the analyses of covariance.

We attempted to evaluate whether the increased ferritin iron was simply a marker for disease-related cell loss that secondarily results in higher iron concentrations[17,75] or whether the iron contributes to the pathogenesis of the AD disease processes and aging, as others have suggested.[23,40,52,76-80] Differences in FDRI could not be accounted for solely by a reduction in the volume of the structures. Therefore, the observed changes in this study cannot be attributed solely to structure atrophy. Similarly, the length of illness seems to have no impact on basal ganglia ferritin iron levels, suggesting that the ferritin iron increases in AD are not caused by the illness itself and may be interpreted as a risk factor for AD.

An association between high iron levels and central nervous system damage has been observed in a va-

©2000 American Medical Association. All rights reserved.
Downloaded From: http://archpsyc.jamanetwork.com/ on 09/02/2014

riety of neurodegenerative disorders, and iron involvement in the process of oxidative damage has been suggested as a common mechanism.[15,50,52,80-86] In addition to AD, the involvement of iron and free-radical neurotoxic processes has been postulated for a variety of age-related neuropsychiatric disorders, such as Parkinson disease,[45,76,77,85] Huntington disease,[14,45,86] and tardive dyskinesia,[79,87] and for the process of brain aging itself.[15,78] Since brain iron levels increase with age,[13-15,49,75,88,89] the risk of iron-mediated damage may increase with age, suggesting a role for iron in age-related neurodegenerative disorders.

In vivo ferritin iron quantification could lead to improved diagnostic and prognostic criteria for AD. If a causal relationship is established between premorbid iron levels and AD through prospective in vivo MRI studies, new avenues of treatment and prevention of the disease may be possible. In addition, serial evaluations of FDRI could be used to monitor iron chelating treatments,[90] which are currently used in patients with transfusion hemosiderosis and have been tentatively shown to be effective in the treatment of some patients with AD.[91]

Accepted for publication September 28, 1999.

This work was supported by a merit review grant from the Department of Veterans Affairs, Washington, DC (Dr Bartzokis); a grant from the the Marie Wilson Howells Endowment (Dr Bartzokis); grants AG 10123 and AG 05142 from the National Institute of Aging Alzheimer Disease Center (Dr Cummings); a grant from the Alzheimer Disease Research Center of California (Dr Cummings); and the Sidell-Kogam Foundation, Los Angeles, Calif (Dr Cummings).

We thank Todd A. Tishler, BA, Kenneth Dery, MS, and Sun Sook Hwang, MS, for their assistance.

Reprints: George Bartzokis, MD, North Little Rock Veterans Affairs Medical Center (116A/NLR), 2200 Fort Roots Dr, Bldg 170, North Little Rock, AR 72114 (e-mail: gbar@ucla.edu).

REFERENCES

1. Gao S, Hendrie HC, Hall KS, Hui S. The relationships between age, sex, and the incidence of dementia and Alzheimer disease: a meta-analysis. *Arch Gen Psychiatry*. 1998;55:809-815.
2. Smith CD, Carney JM, Starke-Reed PE, Oliver CN, Stadtman ER, Floyd RA, Markesbery WR. Excess brain protein oxidation and enzyme dysfunction in normal aging and in Alzheimer disease. *Proc Natl Acad Sci U S A*. 1991;88:10540-10543.
3. Mecocci P, MacGarvey U, Kaufman AE, Koontz D, Shoffner JM, Wallace DC, Beal MF. Oxidative damage to mitochondrial DNA shows marked age-dependent increases in human brain. *Ann Neurol*. 1993;34:609-616.
4. Mecocci P, MacGarvey U, Beal MF. Oxidative damage to mitochondrial DNA is increased in Alzheimer's disease. *Ann Neurol*. 1994;36:747-751.
5. Lovell MA, Ehmann WD, Butler SM, Markesbery WR. Elevated thiobarbituric acid-reactive substances and antioxidant enzyme activity in the brain in Alzheimer's disease. *Neurology*. 1995;45:1594-1601.
6. Good PF, Werner P, Hsu A, Olanow CW, Perl DP. Evidence of neuronal oxidative damage in Alzheimer's disease. *Am J Pathol*. 1996;149:21-28.
7. Davis S, Helfaer MA, Traystman RJ, Hurn PD. Parallel antioxidant and antiexcitotoxic therapy improves outcome after incomplete global cerebral ischemia in dogs. *Stroke*. 1997;28:198-205.
8. Smith MA, Perry G, Richey PL, Sayre LM, Anderson VE, Beal MF, Kowall N. Oxidative damage in Alzheimer's. *Nature*. 1996;382:120-121.
9. Smith MA, Richey Harris PL, Sayre LM, Beckman JS, Perry G. Widespread peroxynitrite-mediated damage in Alzheimer's disease. *J Neurosci*. 1997;17:2653-2657.
10. Smith MA, Taneda S, Richey PL, Miyata S, Yan SD, Stern D, Sayre LM, Monnier VM, Perry G. Advanced Maillard reaction end products are associated with Alzheimer disease pathology. *Proc Natl Acad Sci U S A*. 1994;91:5710-5714.
11. Smith MA, Sayre LM, Anderson VE, Harris PL, Beal MF, Kowall N, Perry G. Cytochemical demonstration of oxidative damage in Alzheimer disease by immunochemical enhancement of the carbonyl reaction with 2,4-dinitrophenylhydrazine. *J Histochem Cytochem*. 1998;46:731-735.
12. Halliwell B, Gutteridge JM. Iron as biological pro-oxidant. *ISI Atlas Sci Biochem*. 1988;1:48-52.
13. Hallgren B, Sourander P. The effect of age on the non-haemin iron in the human brain. *J Neurochem*. 1958;3:41-51.
14. Klintworth GK. Huntington's chorea: morphologic contributions of a century. In: Barbeau A, Paulson GW, Chase TN, eds. *Advances in Neurology, Vol 1: Huntington's Chorea, 1872-1972*. New York, NY: Raven Press; 1973:353-368.
15. Bartzokis G, Mintz J, Sultzer D, Marx P, Herzberg JS, Phelan CK, Marder SR. In vivo MR evaluation of age-related increases in brain iron. *AJNR Am J Neuroradiol*. 1994;15:1129-1138.
16. Bartzokis G, Beckson M, Hance DB, Marx P, Foster JA, Marder SR. MR evaluation of age-related increase of brain iron in young adult and older normal males. *Magn Reson Imaging*. 1997;15:29-35.
17. Hallgren B, Sourander P. The non-haemin iron in the cerebral cortex in Alzheimer's disease. *J Neurochem*. 1960;5:307-310.
18. Ehmann WD, Markesbery WR, Alauddin M, Hossain TI, Brubaker EH. Brain trace elements in Alzheimer's disease. *Neurotoxicology*. 1986;7:195-206.
19. Dedman DJ, Treffry A, Candy JM, Taylor GA, Morris CM, Bloxham CA, Perry RH, Edwardson JA, Harrison PM. Iron and aluminium in relation to brain ferritin in normal individuals and Alzheimer's disease and chronic renal-dialysis patients. *Biochem J*. 1992;287:509-514.
20. Deibel MA, Ehmann WD, Markesbery WR. Copper, iron, and zinc imbalances in severely degenerated brain regions in Alzheimer's disease: possible relation to oxidative stress. *J Neurol Sci*. 1996;143:137-142.
21. Andorn AC, Britton RS, Bacon BR, Kalaria RN. Ascorbate-stimulated lipid peroxidation and non-heme iron concentrations in Alzheimer disease. *Mol Chem Neuropathol*. 1998;33:15-26.
22. Cornett CR, Markesbery WR, Ehmann WD. Imbalances of trace elements related to oxidative damage in Alzheimer's disease brain. *Neurotoxicology*. 1998;19:339-345.
23. Connor JR, Menzies SL, St Martin SM, Mufson EJ. A histochemical study of iron, transferrin, and ferritin in Alzheimer's diseased brains. *J Neurosci Res*. 1992;31:75-83.
24. Morris CM, Candy JM, Keith AB, Oakley AE, Taylor GA, Pullen RG, Bloxham CA, Gocht A, Edwardson JA. Brain iron homeostasis. *J Inorg Biochem*. 1992;47:257-265.
25. Floyd RA, Carney JM. The role of metal ions in oxidative processes and aging. *Toxicol Ind Health*. 1993;9:197-214.
26. Halliwell B, Gutteridge JM. Oxygen free radicals and iron in relation to biology and medicine: some problems and concepts. *Arch Biochem Biophys*. 1986;246:501-514.
27. Anggard E. Nitric oxide: mediator, murderer, and medicine. *Lancet*. 1994;343:1199-1206.
28. Dai L, Winyard PG, Zhang Z, Blake DR, Morris CJ. Ascorbate promotes low density lipoprotein oxidation in the presence of ferritin. *Biochim Biophys Acta*. 1996;1304:223-228.
29. Double KL, Maywald M, Schmittel M, Riederer P, Gerlach M. In vitro studies of ferritin iron release and neurotoxicity. *J Neurochem*. 1998;70:2492-2499.
30. Joshi JG. Ferritin: intracellular regulator of metal availability. In: Connor JR, ed. *Metals and Oxidative Damage in Neurological Disorders*. New York, NY: Plenum Press; 1997:131-143.
31. Dawson DA. Nitric oxide and oxidative damage in the CNS. In: Connor JR, ed. *Metals and Oxidative Damage in Neurological Disorders*. New York, NY: Plenum Press; 1997:188-199.
32. Schubert D, Chevion M. The role of iron in beta amyloid toxicity. *Biochem Biophys Res Commun*. 1995;216:702-707.
33. Connor JR, Menzies SL. Cellular management of iron in the brain. *J Neurol Sci*. 1995;134(suppl):33-44.
34. Good PF, Perl DP, Bierer LM, Schmeidler J. Selective accumulation of aluminum and iron in the neurofibrillary tangles of Alzheimer's disease: a laser microprobe (LAMMA) study. *Ann Neurol*. 1992;31:286-292.
35. Smith MA, Harris PL, Sayre LM, Perry G. Iron accumulation in Alzheimer disease is a source of redox-generated free radicals. *Proc Natl Acad Sci U S A*. 1997;94:9866-9868.
36. Makjanic J, McDonald B, Li-Hsian Chen CP, Watt F. Absence of aluminium in neurofibrillary tangles in Alzheimer's disease. *Neurosci Lett*. 1998;240:123-126.
37. Lovell MA, Robertson JD, Teesdale WJ, Campbell JL, Markesbery WR. Copper, iron and zinc in Alzheimer's disease senile plaques. *J Neurol Sci*. 1998;158:47-52.
38. Bouras C, Giannakopoulos P, Good PF, Hsu A, Hof PR, Perl DP. A laser microprobe mass analysis of brain aluminum and iron in dementia pugilistica: comparison with Alzheimer's disease. *Eur Neurol*. 1997;38:53-58.
39. Morris CM, Kerwin JM, Edwardson JA. Non-haem iron histochemistry of the normal and Alzheimer's disease hippocampus. *Neurodegeneration*. 1994;3:267-275.
40. Goodman L. Alzheimer's disease: a clinico-pathologic analysis of twenty-three cases with a theory on pathogenesis. *J Nerv Ment Dis*. 1953;118:97-130.
41. Grundke-Iqbal I, Fleming J, Tung YC, Lassmann H, Iqbal K, Joshi JG. Ferritin is a component of the neuritic (senile) plaque in Alzheimer dementia. *Acta Neuropathol (Berl)*. 1990;81:105-110.
42. Joshi JG, Fleming JT, Dhar M, Chauthaiwale V. A novel ferritin heavy chain messenger ribonucleic acid in the human brain. *J Neurol Sci*. 1995;134(suppl):52-56.
43. Brooks DJ, Luthert P, Gadian D, Marsden CD. Does signal-attenuation on high-

©2000 American Medical Association. All rights reserved.
Downloaded From: http://archpsyc.jamanetwork.com/ on 09/02/2014

field T_2-weighted MRI of the brain reflect regional cerebral iron deposition? observations on the relationship between regional cerebral water proton T_2 values and iron levels. *J Neurol Neurosurg Psychiatry*. 1989;52:108-111.
44. Chen JC, Hardy PA, Clauberg M, Joshi JG, Parravano J, Deck JH, Henkelman RM, Becker LE, Kucharczyk W. T_2 values in the human brain: comparison with quantitative assays of iron and ferritin. *Radiology*. 1989;173:521-526.
45. Chen JC, Hardy PA, Kucharczyk W, Clauberg M, Joshi JG, Vourlas A, Dhar M, Henkelman RM. MR of human postmortem brain tissue: correlative study between T_2 and assays of iron and ferritin in Parkinson and Huntington disease. *AJNR Am J Neuroradiol*. 1993;14:275-281.
46. Drayer BP. Basal ganglia: significance of signal hypointensity on T_2-weighted MR images. *Radiology*. 1989;173:311-312.
47. Kucharczyk W, Henkelman RM, Chen J. Brain iron and T_2 signal. *AJNR Am J Neuroradiol*. 1994;15:1795-1796.
48. Malisch TW, Hedlund LW, Suddarth SA, Johnson GA. MR microscopy at 7.0 T: effects of brain iron. *J Magn Reson Imaging*. 1991;1:301-305.
49. Schenker C, Meier D, Wichmann W, Boesiger P, Valavanis A. Age distribution and iron dependency of the T_2 relaxation time in the globus pallidus and putamen. *Neuroradiology*. 1993;35:119-124.
50. Bartzokis G, Sultzer D, Mintz J, Holt LE, Marx P, Phelan CK, Marder SR. In vivo evaluation of brain iron in Alzheimer's disease and normal subjects using MRI. *Biol Psychiatry*. 1994;35:480-487.
51. Kamman RL, Go KG, Brouwer W, Berendsen HJ. Nuclear magnetic resonance relaxation in experimental brain edema: effects of water concentration, protein concentration, and temperature. *Magn Reson Med*. 1988;6:265-274.
52. Bartzokis G. Magnetic resonance imaging of brain iron. In: Connor JR, ed. *Metals and Oxidative Damage in Neurological Disorders*. New York, NY: Plenum Press; 1997:41-56.
53. Bartzokis G, Aravagiri M, Oldendorf WH, Mintz J, Marder SR. Field dependent transverse relaxation rate increase may be a specific measure of tissue iron stores. *Magn Reson Med*. 1993;29:459-464.
54. Vymazal J, Brooks RA, Baumgarner C, Tran V, Katz D, Bulte JW, Bauminger R, Di Chiro G. The relation between brain iron and NMR relaxation times: an in vitro study. *Magn Reson Med*. 1996;35:56-61.
55. Bulte JW, Miller GF, Vymazal J, Brooks RA, Frank JA. Hepatic hemosiderosis in non-human primates: quantification of liver iron using different field strengths. *Magn Reson Med*. 1997;37:530-536.
56. Vymazal J, Hajek M, Patronas N, Giedd JN, Bulte JW, Baumgarner C, Tran V, Brooks RA. The quantitative relation between T_1-weighted and T_2-weighted MRI of normal gray matter and iron concentration. *J Magn Reson Imaging*. 1995;5:554-560.
57. Vymazal J, Zak O, Bulte JW, Aisen P, Brooks RA. T_1 and T_2 of ferritin solutions: effect of loading factor. *Magn Reson Med*. 1996;36:61-65.
58. Vymazal J, Brooks RA, Patronas N, Hajek M, Bulte JW, Di Chiro G. Magnetic resonance imaging of brain iron in health and disease. *J Neurol Sci*. 1995;134(suppl): 19-26.
59. Imon Y, Yamaguchi S, Katayama S, Oka M, Murata Y, Kajima T, Yamamura Y, Nakamura S. A decrease in cerebral cortex intensity on T_2-weighted with ageing images of normal subjects. *Neuroradiology*. 1998;40:76-80.
60. Schenck JF. Imaging of brain iron by magnetic resonance: T_2 relaxation at different field strengths. *J Neurol Sci*. 1995;134(suppl):10-18.
61. Rutledge JN, Hilal SK, Silver AJ, Defendini R, Fahn S. Study of movement disorders and brain iron by MR. *AJR Am J Roentgenol*. 1987;149:365-379.
62. Loeffler DA, Connor JR, Juneau PL, Snyder BS, Kanaley L, DeMaggio AJ, Nguyen H, Brickman CM, LeWitt PA. Transferrin and iron in normal, Alzheimer's disease, and Parkinson's disease brain regions. *J Neurochem*. 1995;65:710-716.
63. Loeffler DA, LeWitt PA, Juneau PL, Sima AA, Nguyen HU, DeMaggio AJ, Brickman CM, Brewer GJ, Dick RD, Troyer MD, Kanaley L. Increased regional brain concentrations of ceruloplasmin in neurodegenerative disorders. *Brain Res*. 1996; 738:265-274.
64. Connor JR, Snyder BS, Arosio P, Loeffler DA, LeWitt P. A quantitative analysis of isoferritins in select regions of aged, parkinsonian, and Alzheimer's diseased brains. *J Neurochem*. 1995;65:717-724.
65. Griffiths PD, Crossman AR. Distribution of iron in the basal ganglia and neocortex in postmortem tissue in Parkinson's disease and Alzheimer's disease. *Dementia*. 1993;4:61-65.
66. McKhann G, Drachman D, Folstein M, Katzman R, Price D, Stadlan EM. Clinical diagnosis of Alzheimer's disease: report of the NINCDS-ADRDA Work Group under the auspices of Department of Health and Human Services Task Force on Alzheimer's Disease. *Neurology*. 1984;34:939-944.
67. Folstein MF, Folstein SE, McHugh PR. "Mini-mental state": a practical method for grading the cognitive state of patients for the clinician. *J Psychiatr Res*. 1975; 12:189-198.
68. Custer EM, Finch CA, Sobel RE, Zettner A. Population norms for serum ferritin. *J Lab Clin Med*. 1995;126:88-94.
69. Fleming J, Joshi JG. Ferritin: isolation of aluminum-ferritin complex from brain. *Proc Natl Acad Sci U S A*. 1987;84:7866-7870.
70. Ebmeier KP, Besson JA, Crawford JR, Palin AN, Gemmell HG, Sharp PF, Cherryman GR, Smith FW. Nuclear magnetic resonance imaging and single photon emission tomography with radio-iodine labelled compounds in the diagnosis of dementia. *Acta Psychiatr Scand*. 1987;75:549-556.
71. Bondareff W, Raval J, Colletti PM, Hauser DL. Quantitative magnetic resonance imaging and the severity of dementia in Alzheimer's disease. *Am J Psychiatry*. 1988;145:853-856.
72. Besson JA, Crawford JR, Parker DM, Ebmeier KP, Best PV, Gemmell HG, Sharp PF, Smith FW. Multimodal imaging in Alzheimer's disease: the relationship between MRI, SPECT, cognitive and pathological changes. *Br J Psychiatry*. 1990; 157:216-220.
73. Hanyu H, Shindo H, Kakizaki D, Abe K, Iwamoto T, Takasaki M. Increased water diffusion in cerebral white matter in Alzheimer's disease. *Gerontology*. 1997;43: 343-351.
74. Hampel H, Teipel SJ, Alexander GE, Horwitz B, Teichberg D, Schapiro MB, Rapoport SI. Corpus callosum atrophy is a possible indicator of region- and cell type-specific neuronal degeneration in Alzheimer disease: a magnetic resonance imaging analysis. *Arch Neurol*. 1998;55:193-198.
75. Olanow CW, Holgate RD, Murtaugh R, Martinez C. MR imaging in Parkinson's disease and aging. In: Calne DB, ed. *Parkinsonism and Aging*. New York, NY: Raven Press; 1989:155-164.
76. Youdim MB, Ben-Shachar D, Yehuda S, Riederer P. The role of iron in the basal ganglion. *Adv Neurol*. 1990;53:155-162.
77. Jellinger K, Paulus W, Grundke-Iqbal I, Riederer P, Youdim MB. Brain iron and ferritin in Parkinson's and Alzheimer's diseases. *J Neural Transm Park Dis Dement Sect*. 1990;2:327-340.
78. Stadtman ER. Metal ion-catalyzed oxidation of proteins: biochemical mechanism and biological consequences. *Free Radic Biol Med*. 1990;9:315-325.
79. Bartzokis G, Garber HJ, Marder SR, Oldendorf WH. MRI in tardive dyskinesia: shortened left caudate T_2. *Biol Psychiatry*. 1990;28:1027-1036.
80. Connor JR, Snyder BS, Beard JL, Fine RE, Mufson EJ. Regional distribution of iron and iron-regulatory proteins in the brain in aging and Alzheimer's disease. *J Neurosci Res*. 1992;31:327-335.
81. Park BE, Netsky MG, Betsill WLJ. Pathogenesis of pigment and spheroid formation in Hallervorden-Spatz syndrome and related disorders. *Neurology*. 1975; 25:1172-1178.
82. Sadeh M, Sandbank U. Neuroaxonal dystrophy and hemosiderin in the central nervous system. *Ann Neurol*. 1980;7:286-287.
83. Kim RC, Ramachandran T, Parisi JE, Collins GH. Pallidonigral pigmentation and spheroid formation with multiple striatal lacunar infarcts. *Neurology*. 1981;31: 774-777.
84. Subbarao KV, Richardson JS, Ang LC. Autopsy samples of Alzheimer's cortex show increased peroxidation in vitro. *J Neurochem*. 1990;55:342-345.
85. Bartzokis G, Cummings JL, Markham CH, Marmarelis PZ, Treciokas LJ, Tishler TA, Marder SR, Mintz J. MRI evaluation of brain iron in earlier- and later-onset Parkinson's disease and normal subjects. *Magn Reson Imaging*. 1999;17:213-222.
86. Bartzokis G, Cummings J, Perlman S, Hance DB, Mintz J. Increased basal ganglia iron levels in Huntington disease. *Arch Neurol*. 1999;56:569-574.
87. Campbell WG, Raskind MA, Gordon T, Shaw CM. Iron pigment in the brain of a man with tardive dyskinesia. *Am J Psychiatry*. 1985;142:364-365.
88. Milton WJ, Atlas SW, Lexa FJ, Mozley PD, Gur RE. Deep gray matter hypointensity patterns with aging in healthy adults: MR imaging at 1.5 T. *Radiology*. 1991; 181:715-719.
89. Pujol J, Junque C, Vendrell P, Grau JM, Marti-Vilalta JL, Olive C, Gili J. Biological significance of iron-related magnetic resonance imaging changes in the brain. *Arch Neurol*. 1992;49:711-717.
90. Andersen PB, Birgegard G, Nyman R, Hemmingsson A. Magnetic resonance imaging in idiopathic hemochromatosis. *Eur J Haematol*. 1991;47:174-178.
91. Crapper McLachlan DR, Dalton AJ, Kruck TP, Bell MY, Smith WL, Kalow W, Andrews DF. Intramuscular desferrioxamine in patients with Alzheimer's disease. *Lancet*. 1991;337:1304-1308.

©2000 American Medical Association. All rights reserved.
Downloaded From: http://archpsyc.jamanetwork.com/ on 09/02/2014