ORIGINAL ARTICLE

The Hippocampus in Patients Treated With Electroconvulsive Therapy

A Proton Magnetic Resonance Spectroscopic Imaging Study

Gabriele Ende, PhD; Dieter F. Braus, MD; Sigrid Walter, MSc; Wolfgang Weber-Fahr, MSc; Fritz A. Henn, MD, PhD

Background: We monitored the effect of electroconvulsive therapy (ECT) on the nuclear magnetic resonance–detectable metabolites *N*-acetylaspartate, creatine and phosphocreatine, and choline-containing compounds in the hippocampus by means of hydrogen 1 magnetic resonance spectroscopic imaging. We hypothesized that if ECT-induced memory deterioration was associated with neuronal loss in the hippocampus, the *N*-acetylaspartate signal would decrease after ECT and any increased membrane turnover would result in an increase in the signal from choline-containing compounds.

Methods: Seventeen patients received complete courses of ECT, during which repeated proton magnetic resonance spectroscopic imaging studies of the hippocampal region were performed. Individual changes during the course of ECT were compared with values obtained in 24 healthy control subjects and 6 patients remitted from major depression without ECT.

Results: No changes in the hippocampal *N*-acetylaspartate signals were detected after ECT. A significant mean increase of 16% of the signal from choline-containing compounds after 5 or more ECT treatments was observed. Despite the mostly unilateral ECT application (14 of 17 patients), the increase in the choline-containing compound signal was observed bilaterally. Lactate or elevated lipid signals were not detected. All patients showed clinical amelioration of depression after ECT.

Conclusions: Electroconvulsive therapy is not likely to induce hippocampal atrophy or cell death, which would be reflected by a decrease in the *N*-acetylaspartate signal. Compared with an age-matched control group, the choline-containing compounds signal in patients with a major depressive episode was significantly lower than normal, before ECT and normalized during ECT.

Arch Gen Psychiatry. 2000;57:937-943

From Nuclear Magnetic Resonance Research in Psychiatry, Central Institute of Mental Health, Mannheim, Germany.

ELECTROCONVULSIVE therapy (ECT) is highly effective in the treatment of major depression and other selective psychiatric disorders. Nevertheless, ECT remains controversial because of its cognitive side effects and its unknown effects on cerebral function.[1,2] Structural brain imaging and postmortem neuropathologic studies,[2-5] however, provided no evidence that ECT produces brain damage. Human brain imaging studies are limited in their spatial resolution and cannot detect neuronal damage at the cellular level. Measurements of water T_2 relaxation times showed a significant increase in T_2 in the thalamus after ECT.[6] It has been observed[7] that after ECT, acetylcholine levels in cerebrospinal fluid rise, accompanied by increased activity of cholinesterase in cerebrospinal fluid and blood. Results of recent animal studies[8-10] have shown that mossy fiber sprouting in limbic brain regions is induced by multiple ECT treatments. To our knowledge, no magnetic resonance spectroscopic imaging (MRSI) studies have been reported monitoring the effects of ECT on the hippocampus. Three single-voxel hydrogen 1 (^{1}H) and phosphorus 31 studies[11-13] have reported pre- and post-ECT spectra in other brain regions, and the ^{1}H MRSI studies were aimed at lactate detection after ECT.

Known adverse effects of ECT are transient anterograde amnesia, involving rapid forgetting of newly learned information, and retrograde amnesia, involving loss of memory for information learned before treatment, which might be persistent or permanent.[14] This association of ECT with a classic amnestic syndrome involving anterograde and retrograde amnesia implicates a dysfunction in medial temporal lobe structures, especially the hippocampus.[14-16] Therefore, metabolite changes after ECT could be expected in this region. We hypothesized that 2 types of metabolite changes might be induced by ECT. First is a decrease of *N*-acetylaspartate (NAA) due

©2000 American Medical Association. All rights reserved.
Downloaded From: http://archpsyc.jamanetwork.com/ on 08/29/2016

PATIENTS AND METHODS

PATIENTS

Twenty-three inpatients of the Central Institute of Mental Health in Mannheim, Germany, with major depressive episodes were studied with proton MRSI of the hippocampal region. Seventeen patients underwent ECT and 6 were remitted from major depression under treatment with amitriptyline hydrochloride. The latter 6 patients had not previously undergone ECT. The patients were consecutively recruited, the purpose and the procedures of the study were explained to all participants, and written informed consent was obtained. All depressed patients met *DSM-IV*[18] and *International Classification of Diseases, 10th Revision,*[19] criteria for major depressive episodes on the basis of a structured clinical diagnosis interview (including Hamilton Depression Rating Scale [HAM-D], 21 items, score ≥19). A summary of the subjects' clinical history is provided in the **Table**. Of 17 patients undergoing ECT, 12 were psychotic. All patients undergoing ECT were right-handed. The HAM-D score in patients undergoing ECT ranged from 19 to 35 (mean±SD, 27.7±4.9) before ECT started. Patients underwent 5 to 18 treatments of ECT, and 1 patient underwent 2 ECT courses 6.5 months apart.

The 6 remitted patients and 24 healthy subjects were studied as control groups. Three individuals were studied 4 times and 2 were studied twice with the same protocol for comparison of the longitudinal variability of the metabolite signals. Healthy controls were recruited from the hospital staff and family members and friends of the investigators.

Patients and controls with a history of neurologic or psychiatric disorders other than depression were excluded from our study. A further exclusion criterion was substance abuse, with the exception that 2 patients undergoing ECT with mild alcohol abuse were included. Those 2 patients were abstinent at the time of ECT.

ECT TREATMENTS

Electroconvulsive therapy was administered 3 times per week with a square-wave, brief-pulse, constant-current device (Thymatron DG; Somatics Inc, Lake Bluff, Ill). The standard bifrontotemporal placement and the d'Elia[20] placement of electrodes were used for bilateral and unilateral treatment, respectively. Stimulus intensity was determined as a function of age[21] and was successively readjusted individually with the goal to stimulate at least 20 to 25 seconds of tonic-clonic movement or 25 to 30 seconds of electroencephalographic seizure activity.[22]

Fourteen patients were administered exclusively unilateral right-sided ECT at a stimulus intensity of 40% to 100% (100%=504 millicoulombs; mean±SD stimulus intensity, 67%±21%). Three patients were administered bilateral ECT after 3 to 11 unilateral administrations at a stimulus intensity of 50% to 100% (mean±SD, 61%±14.5%).

Antidepressive medication treatment had been discontinued a mean±SD of 8±4 days before the start of ECT. Because effects of the anesthesia on the metabolite concentrations are possible but unknown, the MRSI measurements were performed at least 30 hours after ECT to avoid such effects on the metabolite concentrations.

MRSI PROTOCOL

Patient compliance was a crucial point in this study: more than 50% of the patients undergoing ECT refused participation in the additional MRSI studies. The main reasons were claustrophobia, problems with lying motionless in the supine position for 40 minutes, or paranoid symptoms related to the investigation. At least 2 data sets were acquired from each patient: one before ECT started and a second after 5 or more ECT treatments within 30 hours to 10 days after ECT.

All ^{1}H MRSI studies were performed on a 1.5-T Siemens Vision MRI/MRS system (Erlangen, Germany) equipped with a standard head coil. For MRSI localization, 2-dimensional, fast low-angle shot (FLASH) images in coronal, sagittal, and oblique transverse orientations were

to neuronal loss, which would be reflected in a permanent NAA decrease, or dysfunction, which could be associated with a reversible NAA decrease in the hippocampus. Both types of NAA decrease could explain a memory deterioration. Second is an increase in the signal from choline-containing compounds (Ch) due to an increased membrane turnover possibly related to hippocampal mossy fiber sprouting. The creatine (Cr) level in the brain is supposed to be relatively stable[17] and therefore was not expected to be affected by ECT. As a consequence of the time between the actual ECT and our MRSI measurement of at least 30 hours we did not expect to find an elevated lactate level. Furthermore, lactate could not be detected in the previous single-voxel studies[11-13] aimed at detecting a lactate increase. Woods and Chiu[12] reported elevated lipid signal levels after ECT using an echo time of 30 milliseconds. We chose an echo time of 135 milliseconds for our MRSI studies, which is not suitable for lipid detection but produces less baseline distortions and thus facilitates evaluation of NAA, Cr, and Ch signals.

The purpose of this study was to monitor quantitative changes of the NAA and Ch signals in the hippocampal region of patients during the course of repetitive ECT sessions.

RESULTS

HIPPOCAMPAL METABOLITE VALUES IN HEALTHY CONTROLS

The metabolite signals of NAA, Cr, and Ch in the healthy control group (n=24) were tested for age-related effects using a Spearman ρ correlation coefficient. This yielded no significant correlations for NAA (Spearman $\rho=-0.20$, $P=.35$, 2-tailed) and Cr (Spearman $\rho=0.25$, $P=.25$, 2-tailed). The Ch signal was significantly correlated with age: Ch increased with increasing age (Spearman $\rho=0.51$, $P=.01$, 2-tailed). A linear regression analysis based on the control data was used for age correction of all 3 metabolite signals in the further analysis. No sex-related differ-

©2000 American Medical Association. All rights reserved.
Downloaded From: http://archpsyc.jamanetwork.com/ on 08/29/2016

acquired. The transverse images were angulated parallel to the long axis of the hippocampus. Point resolved spectroscopy (PRESS) volume preselection was performed parallel to the transverse images and included both hippocampi.[23] Patients were carefully positioned to avoid a sideward tilt of the head, enabling the MRI and MRSI volumes to be centered on the midline of both hippocampi. This procedure ensures that voxels obtained from successive MRSI measures of the same individual could be selected from identical locations. **Figure 1** illustrates the oblique transverse orientation of the MRI slice and MRSI volume and their reproducibility in 2 data sets obtained in a patient undergoing ECT. An MRSI field of view of 210 × 210 mm and a PRESS volume thickness of 15 mm was used with circular k-space sampling equivalent to a maximum of 24 × 24 phase encoding steps.[24] Other measurement parameters included repetition time of 1.8 seconds and echo time of 135 milliseconds, resulting in a measurement time of 13 minutes. Total measurement time was approximately 40 minutes, including setup time and acquisition of 1 MRSI data set.

MRSI DATA PROCESSING

An average of 6 voxels (range, 2-8 voxels) from each hippocampus, including primarily tissue from the hippocampal body, were selected for evaluation. Anterior voxels were avoided because of the poorer spectral quality in this region and the suboptimal excitation profile of the 180° selective pulse in the anteroposterior direction of the volume of interest. This, in combination with the chemical shift displacement error of 2.4 mm between NAA and Ch in the in-plane directions (0.8 mT/m gradient strength), leads to disturbed ratios in the first 2 voxels from the anterior and posterior borders of the volume of interest. Care was taken to choose voxels from repetitive measurements of one patient from identical locations because metabolite signal intensities can vary with location within the region of one hippocampus.[25] Per data set, mean values of spectra from the left and right hippocampus are reported and added spectra are shown in Figure 1, A and B.

Postprocessing of the MRSI data was done with an automated spectral fitting program[26-28] that uses a parametric spectral model with acquisition-specific a priori information combined with a wavelet-based, nonparametric characterization of baseline signals. A k-space apodization resulting in an effective voxel size of approximately 2.4 cm^3 and zero filling to 32 × 32 k-space points was applied before the spatial Fourier transformation. Zero filling from 512 to 1024 time domain data points and Gaussian multiplication corresponding to 0.6-Hz line broadening were carried out before the time domain Fourier transformation. Spectral phasing was also performed automatically. Voxels including primarily gray matter from the hippocampus were selected and the signals of NAA, Cr, and Ch were curve fit. Absolute integral values of the model peaks obtained by the fitting algorithm for NAA, Cr, and Ch were corrected for differential head coil loading by multiplication with the transmitter reference voltage.[23,29-31] This yields a semiquantitative measure, and thus metabolite ratios can be avoided.

STATISTICAL ANALYSIS

All statistical analyses were performed using statistical software (SPSS for Windows, release 8.0.0; SPSS Inc, Chicago, Ill). The metabolite signals (NAA, Cr, and Ch) of healthy controls were tested for age-related effects using Spearman ρ correlation coefficients, and a linear regression analysis was used for age correction.

Two-tailed, paired *t* tests were applied to evaluate significant changes of the metabolite signals from repeated MRSI measurements in the same individual.

For between-group analysis of the metabolite signals, a general linear model with Tukey post hoc analysis for multiple comparison for the observed means was used. Treatment group was the between-subject factor. The control metabolite signals were also tested within this model for significant sex differences, with sex as the between-subject factor. Statistical significance was evaluated at the $P = .05$ level using 2-sided tests. Data are given as mean ± SD.

ences for the metabolite signals were found in the control group in a general linear model analysis.

Five control subjects were studied twice or more at least 4 weeks apart. A 2-tailed paired *t* test revealed no significant differences for repeatedly measured NAA, Cr, or Ch in these controls ($t_4 = -0.73$ to $+0.38$, $P > .5$).

CLINICAL RESPONSE TO ECT AND METABOLITE CHANGES INDUCED BY ECT

All patients showed clinical amelioration of depression after ECT (≥50% reduction in HAM-D score). The final HAM-D values ranged from 3.0 to 12.0 (mean 7.4 ± 2.9). A summary of the patient information, number of ECT treatments, and HAM-D scores before and after ECT is given in the Table.

Comparison of summed spectra from the hippocampal region before and after ECT shows obvious changes in the relative intensity ratio between NAA and Ch signals, as illustrated in Figure 1, A and B, for the spectra obtained from a patient undergoing ECT.

A 2-tailed paired *t* test for metabolite signals before vs after ECT revealed that NAA was unchanged (11.4 ± 1.3 vs 11.8 ± 0.9; $t_{16} = -1.8$, $P = .10$), Cr was slightly increased (7.2 ± 0.8 vs 7.7 ± 1.1; $t_{16} = -2.2$, $P = .04$), and Ch was substantially increased (7.9 ± 0.8 vs 9.1 ± 0.9; $t_{16} = -6.0$, $P < .001$).

The mean intraindividual Ch increase was 15.9% ± 11.8%, with a maximum of 39.5%. Despite the mostly unilateral ECT application (14 of 17 patients), the Ch increase was observed bilaterally. The plot of individual Ch signals before and after ECT in **Figure 2** shows that in all but 1 patient the Ch signal increased during ECT.

For between-group analysis of intraindividual metabolite signal changes, the differences ΔNAA, ΔCr, and ΔCh between measurements 1 and 2 were used. For patients undergoing ECT this was metabolite signals after minus before ECT; for healthy controls this was the difference between 2 data sets acquired at least 4 weeks apart.

©2000 American Medical Association. All rights reserved.
Downloaded From: http://archpsyc.jamanetwork.com/ on 08/29/2016

Characteristics of Study Participants*

Characteristic	ECT Patients (n = 17)	Amitriptyline-Treated Patients (n = 6)	Healthy Control Subjects (n = 24)
Age, y	61.28 (13.42)	49.67 (13.37)	35.33 (11.64)
Sex, F/M	10/7	2/4	12/12
ECT treatments			
Total	10.67 (3.68)	NA	NA
Unilateral, No.	14	NA	NA
Unilateral and bilateral, No.	3	NA	NA
MRSI measurements, No.	3.44 (1.58)	1.50 (1.22)	1.21 (0.41)
HAM-D score before ECT	27.67 (4.93)	26.83 (3.31)	NA
HAM-D score after ECT	7.39 (2.93)	3.83 (2.40)	NA
Age at onset of depression, y	45.24 (15.65)	45.00 (13.37)	NA
Episodes of depression, No.	4.78 (5.42)	1.67 (0.52)	NA
Illness duration, mo	11.34 (15.94)	6.75 (7.35)	NA
Presence of suicidality	0	0	0
Substance abuse	0	0	0
Alcohol abuse			
Yes	2†	0	0
No	15	6	24
Previous medication use, No.			
Tricyclic and tetracyclic antidepressants	17	6	0
Selective serotonin reuptake inhibitors	13	1	0
Serotonin and norepinephrine reuptake inhibitors	6	0	0
Monoamine oxidase inhibitors	4	1	0
Atypical antipsychotics	6	1	0
Typical antipsychotics	8	0	0
Lithium	8	0	0
Carbamazepine	4	0	0
Valproinate	1	0	0

*Data are given as mean (SD) unless otherwise indicated. ECT indicates electroconvulsive therapy; NA, not applicable; MRSI, magnetic resonance spectroscopic imaging; and HAM-D, Hamilton Depression Rating Scale.

†One patient started to drink 3 to 4 drinks per day 6 months before ECT and discontinued drinking 2 weeks before ECT started. In a second patient, a diagnosis of alcohol abuse was given 1 year before ECT but could not be confirmed later.

A general linear model with Tukey correction for multiple comparisons, with ΔNAA, ΔCr, and ΔCh as dependent variables and treatment group (ECT group, n=17; healthy control group, n=5) as the between-subject factor was applied. This comparison yielded no significant differences for ΔNAA ($F_{1,20}$=1.17, P=.29) and ΔCr ($F_{1,20}$=0.34, P=.56) but a highly significant difference for ΔCh (ΔCh_{ECT}=1.20±0.82 and $\Delta Ch_{controls}$=−0.08±0.90; $F_{1,20}$=9.02, P=.007).

IS Ch DECREASED BEFORE ECT OR INCREASED AFTER ECT?

For between-group analysis of the metabolite signals, a general linear model with Tukey correction for multiple comparisons was used. Dependent variables were the metabolite signals and the between-subject factor was treatment group (ECT group, n=17; amitriptyline group, n=6; and healthy control group, n=24).

No significant differences were found for NAA ($F_{2,44}$=2.58, P=.09) and Cr ($F_{2,44}$=2.87, P=.07).

A significant group difference was found for the age-corrected Ch signal ($Ch_{before\ ECT}$=−1.35±0.78, $Ch_{amitriptyline}$=0.41±1.02, $Ch_{controls}$=0.00±0.64; $F_{2,44}$=20.88, P<.001). The Tukey correction for multiple comparisons revealed a substantially different Ch signal between patients before ECT and controls and between patients before ECT and remitted patients treated with amitriptyline (P<.001 for both).

The metabolite signals after ECT were evaluated with the same general linear model. No significant group differences were found (NAA: $F_{2,44}$=1.39, P=.26; Cr: $F_{2,44}$=0.64, P=.53; and Ch: $F_{2,44}$=0.78, P=.46). In a Tukey post hoc test with correction for multiple comparisons, P>.25 for NAA, Cr, and Ch in comparisons among post-ECT patients, amitriptyline-treated patients, and healthy controls. **Figure 3** illustrates these findings with boxplots of the age-corrected signals of NAA, Cr, and Ch in patients before and after ECT, remitted patients treated with amitriptyline, and healthy controls.

COMMENT

This investigation yielded 2 clear conclusions. First, NAA is stable in the hippocampus throughout a course of ECT. Second, Ch seems to be lower in the hippocampus of patients with a major depressive episode compared with controls and increases during a successful course of ECT. The MRSI-detectable Ch signal has been found to be altered in the basal ganglia in depressed patients,[32-35] but the direction of the changes is controversial. In addition, results of our study confirm the age-related increase previously reported[36] for choline in in vivo proton MR spectra. The fact that NAA remains stable

©2000 American Medical Association. All rights reserved.
Downloaded From: http://archpsyc.jamanetwork.com/ on 08/29/2016

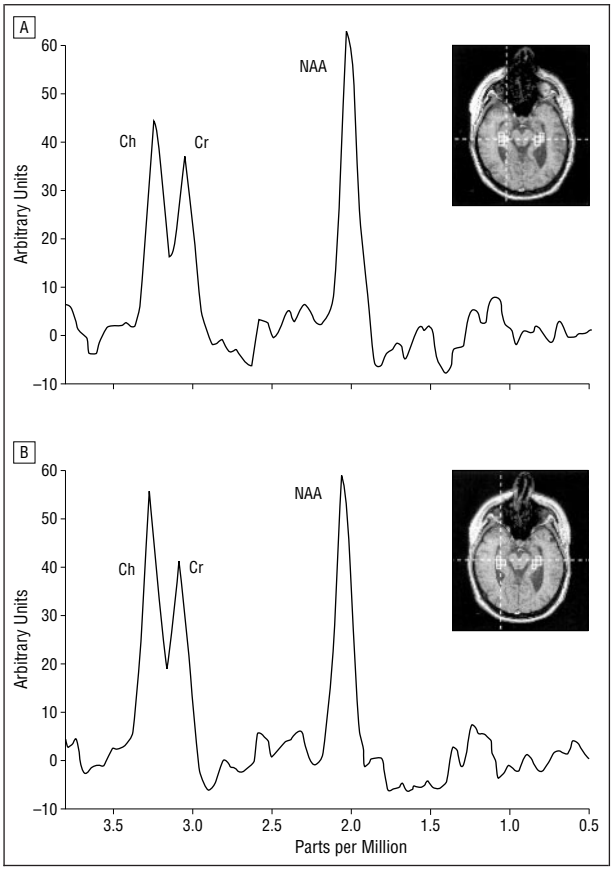

Figure 1. *A, Added spectra from the left and right hippocampal regions of a patient before electroconvulsive therapy (ECT) and a transverse fast low-angle shot localizer image angulated parallel to the long axis of the hippocampus. The location of the evaluated voxels is shown in the inset. B, Added spectra of the same patient after 9 ECT sessions, and a transverse fast low-angle shot localizer image with voxel location is shown in the inset. The choline-containing compound (Ch) signal is obviously increased compared with the creatine (Cr) and* N*-acetylaspartate (NAA) signals in the same spectrum and with the Ch signal in (A) before ECT.*

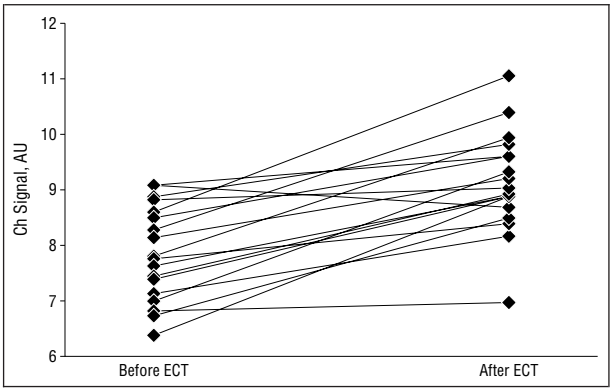

Figure 2. *Individual choline-containing compound (Ch) signals before and after electroconvulsive therapy (ECT) (n=18 [2 data pairs were acquired during 2 successive courses of ECT in one patient]). AU indicates arbitrary units.*

throughout a course of ECT is consistent with a host of neuropathologic[1-9] and volumetric[37,38] evidence after ECT suggesting that no tissue damage occurs because of ECT. The finding in this study of stable NAA signals implies that there is no hippocampal atrophy, neuronal damage, or cell death induced by ECT. The question of whether a hippocampal dysfunction would be reflected in measurable NAA loss has not yet been answered.

As expected, we did not find elevated lactate levels, which is probably due to the 30-hour interval between the actual ECT and MRSI measurement. Moreover, lactate could not be detected in the previous single-voxel studies,[11-13] which were carried out to detect a lactate increase.

The Ch signal increase seen during a course of ECT might well reflect a metabolic reaction induced by ECT. The MRSI-detectable Ch signal represents the quaternary *N*-methyl groups of a variety of Ch. The MRSI resonance is composed of acetylcholine, phosphocholine, glycerophosphocholine, and free choline. Most of the signal arises from phosphocholine and glycerophosphocholine, free choline is less than 5%, and the contribution from acetylcholine is negligible. An increased Ch signal most likely reflects an increase in membrane turnover.

Phosphatidylcholine, the major choline-containing metabolite of the normal brain, is MR invisible in myelin, cell membranes, and other brain lipids under normal circumstances. However, under certain conditions, visible choline might be released from this pool.[17] From the acquired ^{1}H spectra it cannot be determined what happened to specific choline compounds. The most likely explanation is increased membrane phospholipid turnover. An alternative explanation of the results might be an increase of the Ch T_2 relaxation. This is unlikely because it would necessitate an increase in the Ch T_2 relaxation time by a factor of 2.2 to account for a 25% signal increase, assuming a normal T_2 of about 330 milliseconds.[23] Such a marked change in relaxation time in an essentially stable cellular environment is unlikely.

Proton decoupled phosphorous 31 spectroscopy offers the possibility to distinguish between glycerophosphocholine and phosphocholine. But phosphorous 31 MRSI is much less sensitive than ^{1}H MRSI, and, hence, spatial resolution is poor and measurement time is prolonged.

Several authors[8-10] recently reported studies on the effect of ECT on the expression of growth factors in brain, as well as alterations in the function and structure of certain populations of neurons. Duman and Vaidya[8] hypothesize that ECT and antidepressant drug use, via regulation of neurotrophic factors, reverse the atrophy of stress-vulnerable neurons or protect these neurons from further damage. These assumptions are based on results of recent studies[37,38] suggesting that the pathophysiological mechanism of stress and depression involves atrophy or death of hippocampal neurons. The finding of hippocampal atrophy in depression is not without controversy.[39,40] In one study,[40] hippocampal volume was not found to discriminate a typical clinical population of older depressed patients from age-similar control subjects. Nevertheless, relations between hippocampal volumes and clinical phenomena in depressed patients, but not in controls, were found. These findings have been interpreted as potentially meaningful interactions between hippocampal structure and the expression of major depression in older persons.

Vaidya et al[9] and Gombos et al[10] reported that long-term administration of ECT induces sprouting of the granule cell mossy fiber pathway in the hippocampus in ani-

©2000 American Medical Association. All rights reserved.
Downloaded From: http://archpsyc.jamanetwork.com/ on 08/29/2016

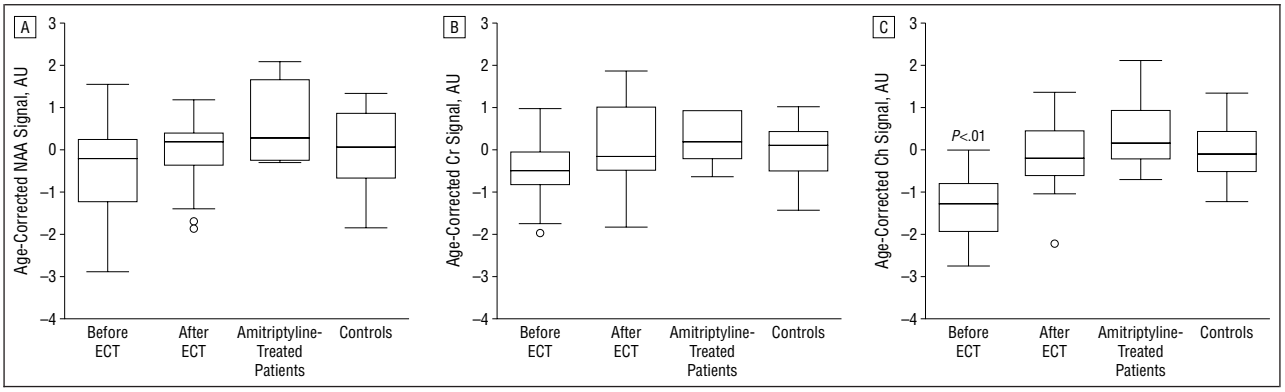

Figure 3. *Boxplots of the age-corrected signals of* N*-acetylaspartate (NAA) (A), creatine (Cr) (B), and choline-containing compounds (Ch) (C) in patients before and after electroconvulsive therapy (ECT) (n=17), remitted patients treated with amitriptyline (n=6), and healthy control subjects (n=24). AU indicates arbitrary units; circles, patient values outside 95% confidence limits.*

mals. This sprouting depends on repeated administration of ECT, reaches a maximum 12 days after the last treatment, and is long lasting (ie, up to 6 months). Multiple seizures- and ECT-induced sprouting occurs in the absence of neuronal loss, indicating that sprouting is not a compensatory response to cell death. This is different from the sprouting induced by kindling or excitotoxin treatment, which induce cell death along with recurrent seizures. Vaidya et al[9] conclude that although the functional consequences remain unclear, sprouting of the mossy fiber pathway would seem to oppose the actions of stress and could thereby contribute to the therapeutic actions of ECT. Stringer et al[41] previously examined the relation between cell death and sprouting of the mossy fibers. Repeated seizures of the hippocampal-parahippocampal circuit were elicited in anesthetized rats. The authors found that the same number of repeated seizures that caused sprouting of the mossy fibers did not cause detectable cell death or severe stress in any cells within the hippocampus, subicular region, or adjacent entorhinal cortex. From these experiments, the authors conclude that repeated seizures of the hippocampal-parahippocampal circuits can cause sprouting of mossy fibers in the absence of evidence of cell death. Our MRSI findings of increased Ch signal in the absence of decreased NAA signal are concordant with an increased membrane turnover without neuronal loss or damage. These results might be explicable by the observations of mossy fiber sprouting in the hippocampus. Our findings may open a new direction aimed at understanding the metabolic mechanisms underlying ECT response and suggest that a loss of trophic activation in the hippocampus could be the underlying factor in depressive illness.

This study has several limitations. Memory and other cognitive functions were not quantitatively assessed before and after ECT and thus could not be correlated to the observed Ch signal increase after ECT. Our MRSI study was spatially limited to the hippocampal region. Therefore, it is not known whether the observed changes in the Ch signal are solely restricted to the hippocampus. Another brain region where physiological effects of ECT on blood flow, glucose metabolism, and electroencephalographic slow-wave activity were found is the prefrontal cortex. Because patient compliance is crucial for our MRSI studies, it was not possible to put the patients through a prolonged MRSI examination including the prefrontal cortex. On the other hand, the size of the MRSI voxels is relatively large and only averaged data from all hippocampal subregions, such as CA1 and CA3, with known sensitivity to alterations due to seizure, could be obtained. If changes in NAA were to occur strictly localized to a small subfield, our method might not be sensitive enough to detect them. Furthermore, the noninvasive method of MRSI yields only one MRSI signal consisting of a variety of choline-containing compounds and thus the true nature of the Ch signal increase remains unresolved. At present, the interpretation of our results that the Ch signal increase reflects mossy fiber sprouting remains a hypothesis and requires a better understanding of the origin of the increased Ch signals.

Accepted for publication May 15, 2000.

This work was supported by Forschungsfond der Universität Heidelberg/Mannheim 2016, Mannheim, Germany.

Presented in part at the annual meetings of the Society of Magnetic Resonance in Medicine, Sydney, Australia, April 20, 1998, and Philadelphia, Pa, May 26, 1999.

We thank Norbert Schuff, PhD, for providing the spherical k-space sampling MRSI sequences; Andrew Maudsley, PhD, and Brian Soher, PhD, for providing the automated spectral fitting routine; Petra Hubrich-Ungureanu, MD, and Thomas Obergriesser, MD, for assistance with patient demographic data; and Bertram Krumm, PhD, for assistance with the statistical evaluation.

Reprints: Fritz A. Henn, MD, PhD, NMR Research in Psychiatry, Central Institute of Mental Health, Postfach 122120, D-68072 Mannheim, Germany (e-mail: henn@as200.zi-mannheim.de).

REFERENCES

1. Salzman C. ECT, research, and professional ambivalence. *Am J Psychiatry.* 1998; 155:1-2.
2. Coffey CE, Weiner RD, Djang WT, Figiel GS, Soady SA, Patterson LJ, Holt PD, Spritzer CE, Wilkinson WE. Brain anatomic effects of electroconvulsive therapy: a prospective magnetic resonance imaging study. *Arch Gen Psychiatry.* 1991; 48:1013-1021.

©2000 American Medical Association. All rights reserved.
Downloaded From: http://archpsyc.jamanetwork.com/ on 08/29/2016

3. Scott AIF, Turnbull LW, Blane A, Douglas RHB. Electroconvulsive therapy and brain damage [letter]. *Lancet.* 1991;338:264.
4. Coffey CE. The role of structural brain imaging in ECT. *Psychopharmacol Bull.* 1994;30:477-483.
5. Devanand DP, Dwork AJ, Hutchinson ER, Bolwig TG, Sackeim HA. Does ECT alter brain structure? *Am J Psychiatry.* 1994;151:957-970.
6. Diehl DJ, Keshavan MS, Kanal E, Nebes RD, Nichols TE, Gillen JSSO. Post-ECT increases in MRI regional T_2 relaxation times and their relationship to cognitive side effects: a pilot study. *Psychiatry Res.* 1994;54:177-184.
7. Fink F. How does convulsive therapy work? *J Neuropsychopharmacol.* 1990;3:73-82.
8. Duman RS, Vaidya VA. Molecular and cellular actions of chronic electroconvulsive seizures. *J ECT.* 1998;14:181-193.
9. Vaidya VA, Siuciak JA, Du F, Duman RS. Hippocampal mossy fiber sprouting induced by chronic electroconvulsive seizures. *Neuroscience.* 1999;89:157-166.
10. Gombos Z, Spiller A, Cottrell GA, Racine RJ, McIntyre Burnham W. Mossy fiber sprouting induced by repeated electroconvulsive shock seizures. *Brain Res.* 1999;844:28-33.
11. Woods BT, Chiu TM. In vivo ^{1}H spectroscopy of the human brain following electroconvulsive therapy. *Ann Neurol.* 1990;28:245-249.
12. Woods BT, Chiu TM. Induced and spontaneous seizures in man produce increases in regional brain lipid detected by in vivo proton magnetic resonance spectroscopy. *Adv Exp Med Biol.* 1992;318:267-274.
13. Felber SR, Pycha R, Hummer M, Aichner FT, Fleischhacker WW. Localized proton and phosphorus magnetic resonance spectroscopy following electroconvulsive therapy. *Biol Psychiatry.* 1993;33:651-654.
14. Sackeim HA, Freeman J, McElhiney M, Coleman E, Prudic J, Devanand DP. Effects of major depression on estimates of intelligence. *J Clin Exp Neuropsychol.* 1992;14:268-288.
15. Squire LR. Mechanisms of memory. *Science.* 1986;232:1612-1619.
16. Sobin C, Sackeim HA, Prudic J, Devanand DP, Moody BJ, McElhiney MC. Predictors of retrograde amnesia following ECT. *Am J Psychiatry.* 1995;152:995-1001.
17. Danielsen E, Ross B. The clinical significance of metabolites. In: *Magnetic Resonance Spectroscopy Diagnosis of Neurological Diseases.* New York, NY: Marcel Dekker Inc; 1999:23-43.
18. American Psychiatric Association. *Diagnostic and Statistical Manual of Mental Disorders, Fourth Edition.* Washington, DC: American Psychiatric Association; 1994.
19. World Health Organization. *International Classification of Diseases, 10th Revision (ICD-10).* Geneva, Switzerland: World Health Organization; 1992.
20. d'Elia G. Unilateral electroconvulsive therapy. *Acta Psychiatr Scand Suppl.* 1970;215:1-98.
21. Swartz CM, Abrams R. *ECT Instruction Manual.* 5th ed. Lake Bluff, Ill: Somatics Inc; 1994.
22. Sackeim HA, Prudic J, Devanand DP, Kiersky JE, Fitzsimons L, Moody BJ, McElhiney MC, Coleman EA, Settembrino JM. Effects of stimulus intensity and electrode placement on the efficacy and cognitive effects of electroconvulsive therapy. *N Engl J Med.* 1993;328:839-846.
23. Ende G, Laxer KD, Knowlton R, Schuff N, Matson GB, Weiner MW. Temporal lobe epilepsy: bilateral hippocampal metabolite changes revealed at proton MR spectroscopic imaging. *Radiology.* 1997;202:809-818.
24. Maudsley AA, Matson GB, Hugg JW, Weiner MW. Reduced phase encoding in spectroscopic imaging. *Magn Reson Med.* 1994;1:645-651.
25. Vermathen P, Laxer KD, El Din M, Matson GB, Weiner MW. ^{1}H MRSI of the hippocampus shows strong anterior-posterior differences in epilepsy patients and in controls [abstract]. *ISMRM Vancouver.* 1997:36.
26. Young K, Govindaraju V, Soher BJ, Maudsley AA. Automated spectral analysis, I: formation of a priori information by spectral simulation. *Magn Reson Med.* 1998;40:812-815.
27. Young K, Soher BJ, Maudsley AA. Automated spectral analysis, II: application of wavelet shrinkage for characterization of non-parameterized signals. *Magn Reson Med.* 1998;40:816-821.
28. Soher BJ, Young K, Govindaraju V, Maudsley AA. Automated spectral analysis, III: application to in-vivo proton MR spectroscopy and spectroscopic imaging. *Magn Reson Med.* 1998;40:822-831.
29. Hoult DI, Richards RE. The signal-to-noise ratio of the nuclear magnetic resonance experiment. *J Magn Reson.* 1976;24:71-85.
30. Austin SJ, Connelly A, Gadian DG, Benton JS, Brett EM. Localized ^{1}H NMR spectroscopy in Canavan's disease: a report of two cases. *Magn Reson Med.* 1991;19:439-445.
31. Michaelis T, Merboldt KD, Bruhn H, Hänicke W, Frahm J. Absolute concentration of metabolites in the adult human brain in vivo: quantification of localized proton MR spectra. *Radiology.* 1993;187:219-227.
32. Charles HC, Lazeyras F, Krishnan KR, Boyko OB, Payne M, Moore D. Brain choline in depression: in vivo detection of potential pharmacodynamic effects of antidepressant therapy using hydrogen localized spectroscopy. *Prog Neuropsychopharmacol Biol Psychiatry.* 1994;18:1121-1127.
33. Renshaw PF, Lafer B, Babb SM, Fava M, Stoll AL, Christensen JD, Moore CM, Yurgelun Todd DA, Bonello CM, Pillay SS, Rothschild AJ, Nierenberg AA, Rosenbaum JF, Cohen BM. Basal ganglia choline levels in depression and response to fluoxetine treatment: an in vivo proton magnetic resonance spectroscopy study. *Biol Psychiatry.* 1997;41:837-843.
34. Soares JC, Krishnan KR, Keshavan MS. Nuclear magnetic resonance spectroscopy: new insights into the pathophysiology of mood disorders. *Depression.* 1996;4:14-30.
35. Kato T, Hamakawa H, Shioiri T, Murashita J, Takahashi Y, Takahashi S, Inubushi TJ. Choline-containing compounds detected by proton magnetic resonance spectroscopy in the basal ganglia in bipolar disorder. *J Psychiatry Neurosci.* 1996;21:248-254.
36. Soher BJ, van Zijl PC, Duyn JH, Barker PB. Quantitative proton MR spectroscopic imaging of the human brain. *Magn Reson Med.* 1996;35:356-363.
37. Sheline YI, Wang PW, Gado MH, Csernansky JG, Vannier MW. Hippocampal atrophy in recurrent major depression. *Proc Natl Acad Sci U S A.* 1996;93:3908-3913.
38. Sheline YI, Sanghavi M, Mintun MA, Gado MH. Depression duration but not age predicts hippocampal volume loss in medically healthy women with recurrent major depression. *J Neurosci.* 1999;19:5034-5043.
39. Pantel J, Schroder J, Essig M, Popp D, Dech H, Knopp MV, Schad LR, Eysenbach K, Backenstrass M, Friedlinger M. Quantitative magnetic resonance imaging in geriatric depression and primary degenerative dementia. *J Affect Disord.* 1997;42:69-83.
40. Ashtari M, Greenwald BS, Kramer-Ginsberg E, Hu J, Wu H, Patel M, Aupperle P, Pollack S. Hippocampal/amygdala volumes in geriatric depression. *Psychol Med.* 1999;29:629-638.
41. Stringer JL, Agarwal KS, Dure LS. Is cell death necessary for hippocampal mossy fiber sprouting? *Epilepsy Res.* 1997;7:67-76.

©2000 American Medical Association. All rights reserved.
Downloaded From: http://archpsyc.jamanetwork.com/ on 08/29/2016