

Comparison of Progressive Cortical Gray Matter Loss in Childhood-Onset Schizophrenia With That in Childhood-Onset Atypical Psychoses

Nitin Gogtay, MD; Alexandra Sporn, MD; Liv S. Clasen, PhD; Tom F. Nugent III, AB; Deanna Greenstein, PhD; Rob Nicolson, MD; Jay N. Giedd, MD; Marge Lenane, MSW; Pete Gochman, MA; Alan Evans, PhD; Judith L. Rapoport, MD

Background: Recent anatomical brain magnetic resonance imaging (MRI) studies show a striking postpsychotic progressive loss of cortical gray matter (GM) in patients with childhood-onset schizophrenia (COS), which appears greater than that seen for adult patients. However, the diagnostic specificity and the relationship of these changes to drug treatment and cognitive functioning remain unclear. We performed a comparative prospective brain MRI study in patients with COS and pediatric patients with transient psychosis with behavior problems (psychosis not otherwise specified) provisionally considered multidimensionally impaired (MDI). We hypothesized that cortical GM loss would occur in patients with COS but not in adolescents with atypical psychoses.

Methods: Anatomical brain MRI was performed at baseline and follow-up in 19 patients in the MDI group (mean [SD] age of 13.3 [3.1] years); in 23 patients with COS matched for age, sex, IQ score, and drug treatment (mean [SD] age of 13.9 [2.5] years); and 38 healthy control subjects matched for age and sex (mean [SD] age of 13.3 [3.1] years). The mean (SD) follow-up was 2.5 (0.8) years. Volumes of the cerebrum and total and regional GM were

obtained by using automated analysis, and percent change in volume across time was calculated. One-way analyses of variance with post hoc Tukey Honestly Significantly Different comparisons were performed to examine group differences in the percent change in GM across follow-up.

Results: The COS group had significantly greater total, frontal, temporal, and parietal GM loss than did the MDI or healthy control groups; analysis of variance post hoc *P* values ranged from .03 to .001. The MDI and control groups did not differ significantly from each other.

Conclusions: The cortical GM volume loss in COS appears diagnostically specific; it was not seen in children and adolescents with atypical psychosis. Because both patient groups had similar early developmental patterns, cognitive functioning, medications, and hospitalizations, this progressive loss appears to be intrinsic to COS. An ongoing neurodevelopmental process and/or brain response specific to the illness could account for these changes.

Arch Gen Psychiatry. 2004;61:17-22

From the Child Psychiatry Branch, National Institute of Mental Health, Bethesda, Md (Drs Gogtay, Sporn, Clasen, Greenstein, Nicolson, Giedd, and Rapoport, Messrs Nugent and Gochman, and Ms Lenane); and the Montreal Neurological Institute, Montreal, Quebec (Dr Evans).

CHILDHOOD-ONSET SCHIZOPHRENIA (COS), defined as onset of psychotic symptoms before the 13th birthday, is a rare and severe form of the illness, which is continuous with its adult counterpart.¹ Longitudinal magnetic resonance imaging (MRI) studies of brain changes in adult patients with schizophrenia showed mixed results, with some researchers finding progressive changes and others noting no differential progression relative to control subjects.^{2,3} However, researchers in other MRI studies, in which tissue classification was used, noted abnormal volume loss for the whole brain, total cortical, frontal, and temporal gray matter (GM) and progressive expansion of the lateral ven-

tricles, as compared with findings in healthy control subjects.^{2,4-8} Prospective brain MRI studies in patients with COS reveal a more striking progressive loss of total cerebral volume and total and regional cortical GM volumes during adolescence, as compared with findings in healthy control subjects.^{9,10} Effect size comparison indicates that this progression is greater in adolescent patients with COS than that reported in adult patients with schizophrenia.¹¹

These intriguing findings are confounded by the effects of illness severity and the probably related lower cognitive level of subjects with COS. Prospective examination in patients without schizophrenia who were treated with similar medications could provide a comparison population with similar antipsychotic

treatment and chronic illness to evaluate the diagnostic specificity of these brain changes.

To address these confounding variables of chronic stress of illness, cognitive level, and medication exposure, we compared the brain developmental changes in patients with COS with the changes in patients without schizophrenia who were matched for age, sex, and IQ score. The latter group had received comparable treatment and had been referred for the COS study but were considered to have psychosis not otherwise specified. These subjects had transient psychotic symptoms and behavioral dyscontrol.^{12,13} At follow-up, none became schizophrenic but most continued to have behavioral and affective problems necessitating residential or special school placement and long-term medication management.¹⁴

We hypothesized that the progressive brain changes in patients with COS were specific to the illness and not caused by medication exposure, cognitive impairment, or other illness-related confounding variables, and thus the patients who were multidimensionally impaired (MDI) would not show prospective longitudinal loss of brain tissue.

METHODS

COS GROUP

Since 1991, through review of more than 1500 case records and in-person screening of more than 230 subjects, 72 patients met DSM-IV criteria for schizophrenia with the onset of psychosis before the 13th birthday.^{13,15} Patients with a history of substantial medical problems, substance abuse, or an IQ score lower than 70 prior to the onset of psychotic symptoms were excluded. Further details of patient selection are described elsewhere.¹⁵ All subjects with COS participated in a prospective brain MRI developmental study.^{16,17}

MDI GROUP

This subgroup of subjects excluded from the COS study had transient psychotic symptoms but were primarily impaired by disruptive behaviors. These patients were considered to have a psychotic disorder not otherwise specified (psychosis not otherwise specified; 298.9 in DSM-IV) and were considered MDI according to 2 child psychiatrists (N.G., A.S., J.L.R.) using clinical and structured interviews, including the Schedule for Affective Disorders and Schizophrenia for School-Age Children.^{12,13,18}

Although these patients reported hallucinations and delusions, their symptoms were brief (ie, lasting for only a few minutes) and infrequent (occurring a few times a month), usually in response to stress. Their psychotic symptoms were distressing, but their impairment was mostly attributable to affective instability and associated aggressive behavior. These patients had all been treated with antipsychotic medications, at doses similar to those used in patients with COS, before the screening at the National Institute of Mental Health, Bethesda, Md.¹² Although these children and adolescents did not fulfill criteria at baseline for schizophrenia or any other major Axis I disorder apart from attention-deficit/hyperactivity disorder, their morbidity, including recurrent lengthy psychiatric hospitalizations, and early developmental profiles were similar to those in patients with COS. In parallel with the COS group, the patients in the MDI group underwent assessment clinically and neurobiologically, including MRI, at their entry into the study and were observed prospectively.

CONTROL GROUP

A group of healthy children and adolescents, all of whom underwent MRI at least twice, was selected from a larger prospective study of normal brain development.¹⁷ Control subjects were free of lifetime medical or psychiatric disorders as determined by means of clinical examination and standardized interview. Psychiatric illness in a first-degree relative was also exclusionary.

STUDY SAMPLE

From the 2 patient groups, we were able to match for sex, age, and medication status 19 patients who were MDI (mean [SD] age of 13.3 [3.1] years) and 23 patients with COS (mean [SD] age of 13.9 [2.5] years) who had undergone 2 prospective MRI studies. Thus, the only basis for exclusion of subjects with COS was the failure to match with the MDI group and/or the lack of 2 prospective MRI studies. Thirty-eight healthy community volunteers (mean [SD] age of 13.3 [3.1] years) matched for age and sex who had undergone 2 prospective MRI studies were selected as control subjects. Sample characteristics are given in **Table 1**.

This study was approved by the institutional review board of the National Institute of Mental Health. Parents or legal guardians of all participants provided written informed consent, and all patients gave written assent for their participation.

MRI AND ANALYSIS

All images were acquired with the same 1.5-T imager (Signa; GE Medical Systems, Milwaukee, Wis) located at the National Institutes of Health Clinical Center, Bethesda. A 3-dimensional spoiled gradient-recalled echo in the steady-state sequence designed to optimize discrimination of GM, white matter, and cerebrospinal fluid was used to acquire 124 contiguous 1.5-mm-thick sections in the axial plane and 124 contiguous 2.0-mm-thick sections in the coronal plane. Imaging parameters were as follows: repetition time, 24 milliseconds; echo time, 5 milliseconds; flip angle, 45°; acquisition matrix, 256 × 192; number of signals acquired, 1; and field of view, 24 cm.

Total and regional GM and white matter volumes were generated by a fully automated system that classifies tissue according to voxel intensity by using a probabilistic atlas and provides lobar (frontal, parietal, temporal, and occipital) parcellation of cortical GM volumes. Total cerebral volume was defined as the algebraic sum of all GM voxels and white matter pixels, excluding the cerebellum and brainstem. Anatomical boundaries for classification of brain voxels were based on 4000 points selected by a trained neuroanatomist for GM, white matter, cerebrospinal fluid, fat, and background by using reference space and the coordinate system from Talairach space.^{19,20} Additional information about anatomical boundaries is available at request from the authors²¹ and on our Web site at <http://intramural.nimh.nih.gov/chp/>.

STATISTICAL ANALYSIS

Comparisons of patients and control subjects for baseline and follow-up age and imaging interval were examined with 1-way analysis of variance (ANOVA). Sex and handedness for the 3 groups were compared by using χ^2 tests, while clinical functioning, full-scale IQ score, and antipsychotic medication use in the 2 patient groups were compared by using *t* tests. Percent change in total cerebral and total and regional GM volumes was calculated and compared between the 3 groups. One-way ANOVA was performed for percent change differences in total cerebral volume and total and regional (parietal, frontal, temporal, and occipital) GM volumes between the 3 groups,

Table 1. Demographic and Clinical Characteristics of Patients in the COS and MDI Groups and Healthy Control Subjects

Characteristic	Subjects*			Test Statistic	P Value
	COS (n = 23)	MDI (n = 19)	Control (n = 38)		
Baseline age, y	13.9 (2.5)	13.3 (3.1)	13.3 (3.1)	$F_{2,77} = 0.43$.65
Follow-up age, y	16.4 (2.5)	15.9 (2.9)	15.8 (3.0)	$F_{2,77} = 0.25$.78
Follow-up, y	2.4 (0.7)	2.6 (0.9)	2.6 (0.8)	$F_{2,77} = 0.46$.63
Sex, M:F	19:4	16:3	32:6	$\chi^2_{1} = 0.03$.9
Age at onset of psychosis, y	10.13 (2.1)	7.8 (1.9)	NA	NA	NA
Lifetime medication exposure, y	3.8 (2.0)	5.5 (3.0)	NA	$t_{40} = 2.07$.04
Full-scale IQ score†	75.8 (18.3)	82.4 (12.2)	120.9 (11.9)	$t_{40} = 1.3$.2
Clinical functioning at MRI 1					
CGI	5.1 (1.0)	4.2 (0.9)	NA	$t_{40} = 2.0$.01
BPRS	43.1 (14.4)	31.5 (5.2)	NA	$t_{40} = -3.3$.001
SAPS	39.3 (18.0)	16.4 (8.0)	NA	$t_{40} = -5.1$	>.001
SANS	56.4 (25.4)	18 (18.0)	NA	$t_{40} = -5.4$	>.001
Clinical functioning at MRI 2‡					
CGI	4.8 (1.0)	4.1 (0.9)	NA	$t_{40} = 2.3$.02
BPRS	37 (8.0)	30.7 (5.2)	NA	$t_{40} = -2.9$.005
SAPS	18.7 (13.1)	12.1 (7.6)	NA	$t_{40} = -1.9$.06
SANS	47.6 (21.4)	24.5 (15.3)	NA	$t_{40} = -3.9$	>.001
Handedness, No. (%)					
Right	18 (78)	17 (89)	36 (95)	$\chi^2_{1} = 7.4$.1
Left	4 (17)	1 (5)	0 (0)		
Mixed	1 (4)	1 (5)	2 (5)		
Medication at MRI 1, No. (%)‡					
Antipsychotic medications	22 (96)	18 (95)	NA	$\chi^2_{1} = 0.02$.89
Typical:atypical	17:5	15:3	NA	$\chi^2_{1} = 0.25$.88
Mood stabilizers	5 (22)	10 (53)	NA	$\chi^2_{1} = 4.32$.04
Medication at MRI 2, No. (%)‡					
Antipsychotic medications	23 (100)	13 (68)	NA	$\chi^2_{1} = 8.47$.003
Typical:atypical	0:23	1:12	NA	$\chi^2_{1} = 10.17$.006
Clozapine	15 (65)	0	NA	$\chi^2_{1} = 19.30$.001
Mood stabilizers	2 (9)	10 (53)	NA	$\chi^2_{1} = 9.80$.002

Abbreviations: BPRS, Brief Psychiatric Rating Scale; CGI, Clinical Global Impression Scale; COS, childhood-onset schizophrenia; MDI, multidimensionally impaired; MRI, magnetic resonance imaging; NA, not applicable; SANS, Scale for the Assessment of Negative Symptoms; SAPS, Scale for the Assessment of Positive Symptoms. *Values are mean (SD) unless otherwise specified.

†According to the Wechsler Intelligence Scale for Children.

‡Comparison between COS and MDI.

followed by post hoc Tukey Honestly Significantly Different testing for significant group differences.²² The SPSS 10.0 statistical package for Windows (SPSS Inc, Chicago, Ill) was used for all analyses; a 2-tailed *P* value of .05 was considered to indicate statistical significance.

RESULTS

As seen in Table 1, the 3 groups did not differ significantly with respect to their age at baseline or follow-up, the length of follow-up, sex, or handedness. The 2 patient groups had lower IQ scores than did control subjects but did not differ significantly from each other. The patients had developed psychotic symptoms at a young age; in patients with COS, mean (SD) was 10.13 (2.1) years, and in patients in the MDI group, mean (SD) was 7.8 (1.9) years. The patients also had had considerable exposure to antipsychotic medications during the course of illness (COS, 3.8 [2.0] years; MDI, 5.5 [3.0] years), with most patients having had 2 or more years of continuous antipsychotic medication exposure at baseline. Also at baseline, typical and atypical antipsychotic medication exposure was approximately equal between the 2

patient groups. At follow-up, most patients in both groups continued to receive atypical antipsychotic medications, although 15 (65%) in the COS group were receiving clozapine, while none of the patients in the MDI group was. The use of mood stabilizers was more frequent in the MDI group, as compared with findings in the COS group both at baseline (MDI, 10 [53%]; COS, 5 [22%]) and at follow-up (MDI, 10 [53%]; COS, 2 [9%]).

At baseline and at follow-up, both patient groups were significantly clinically ill as assessed by means of the Clinical Global Impression Scale, Brief Psychiatric Rating Scale, Scale for the Assessment of Positive Symptoms, and Scale for the Assessment of Negative Symptoms, but the COS group was relatively more impaired. In both patient groups, there was no significant change in IQ score at follow-up. Clinical improvement measures in the COS group at follow-up did not correlate significantly with the percent change in GM loss (Pearson correlations all >0.1).

Table 2 shows total and regional GM volumes for all 3 groups at MRI 1 and MRI 2 and the percent change across follow-up. As seen in Table 2, the reduction in GM volumes for the COS group was greater than for both the MDI and control groups.

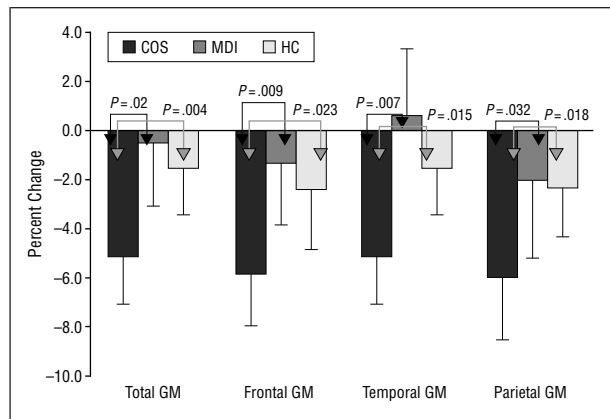
Table 2. Total and Regional GM Volumes for Patients in the COS and MDI Groups and Healthy Control Subjects at MRI 1 and MRI 2 With Percent Change in Volume Calculated Across Follow-up*

Volume, mL	Patients in the COS Group			Patients in the MDI Group			Healthy Control Subjects		
	MRI 1	MRI 2	Percent Change†	MRI 1	MRI 2	Percent Change†	MRI 1	MRI 2	Percent Change†
Total cerebral	1113.85 (82.09)	1089.99 (129.63)	-2.1 (0.6)	1053.01 (126.04)	1048.89 (128.34)	-0.4 (3.1)	1149.53 (87.69)	1144.38 (90.56)	-0.5 (2.9)
Total GM	714.64 (82.09)	677.91 (81.32)	-5.1 (3.9)	683.19 (75.16)	679.28 (80.24)	-0.5 (5.1)	746.22 (60.14)	734.77 (63.94)	-1.5 (3.8)
Parietal GM	115.68 (16.09)	108.52 (14.83)	-6.0 (5.1)	112.94 (13.12)	110.64 (14.68)	-2.0 (6.3)	124.24 (12.33)	121.29 (12.39)	-2.4 (4.0)
Frontal GM	219.25 (27.17)	206.48 (26.80)	-5.8 (4.3)	209.54 (24.20)	206.88 (26.97)	-1.3 (5.0)	231.42 (18.82)	225.91 (21.78)	-2.3 (4.9)
Temporal GM	186.49 (21.25)	179.03 (21.03)	-3.9 (4.6)	176.18 (17.27)	177.15 (18.69)	-0.6 (5.4)	189.08 (15.54)	188.12 (15.45)	-0.4 (4.3)
Occipital GM	64.29 (11.42)	61.75 (11.40)	-3.8 (7.6)	59.92 (10.37)	61.19 (8.04)	3.3 (10.8)	68.36 (9.15)	69.94 (8.76)	2.8 (8.3)

Abbreviations: COS, childhood-onset schizophrenia; GM, gray matter; MDI, multidimensionally impaired; MRI, magnetic resonance imaging.

*Values are mean (SD).

†Calculated as follows: [(MRI 2 - MRI 1)/MRI 1] × 100.



Comparison of percent change in total and regional gray matter (GM) volumes between 23 patients with childhood-onset schizophrenia (COS), 19 patients who were multidimensionally impaired (MDI), and 38 healthy control subjects (HC) across 2½ years. The *P* values were obtained with 1-way analysis of variance with Tukey Honestly Significantly Different post hoc testing. Error bars indicate SD. The MDI and HC groups do not differ significantly for any measure (all *P* > .6).

The GM loss (percent reduction) for the 3 groups is plotted graphically in the **Figure**. One-way ANOVA comparisons of percent change in total and regional GM volumes between the 3 groups were all significant ($F_{2,77}=2.7$ to 7.7 , $P=.03$ to $.001$). Post hoc Tukey Honestly Significantly Different tests, which account for multiple comparisons, revealed that the percent reductions for the total and regional GM volumes were significantly greater in the COS group than in the MDI and control groups (Figure). The MDI and control groups did not differ significantly from each other.

COMMENT

The progressive loss of cortical GM previously reported in patients with COS appears to be diagnostically specific. The comparison group of adolescent patients with transient psychotic symptoms and chronic affective and behavioral disorders (the MDI group) did not show progressive cortical loss. The MDI group as a whole ($n=29$) at follow-up of 2 to 8 years exhibited several clinical trajectories, with approximately half ($n=15$) having a diagnosis of chronic affective disorder or psychotic disorder, while the others ($n=14$) retained the diagnosis of

psychosis not otherwise specified.¹⁴ It is thus probable that these illnesses have different neurodevelopmental trajectories distinct from that of schizophrenia. This finding is in agreement with those of Pantelis et al²³; in their study, subjects at high risk who were not receiving medication and developed affective illness did not show progressive loss of brain tissue, while the ones progressing to first episode did. It is, however, important to note that although no progressive changes were seen for MDI in our study, these are crude whole-lobe measures of GM volume. It is probable that more localized regional measures will indicate substantial changes in select cortical regions for the MDI group (eg, medial brain structures), which may show abnormal trajectories with the onset of affective psychosis, as seen in the neuroimaging studies of mood or affective disorders.^{24,25}

At initial MRI, despite longer exposure to antipsychotic medications (mean [SD] 5.5 [3.0] years for MDI and 3.8 [2.0] years for COS), the MDI group did not have smaller GM volumes, as compared with those in healthy control subjects (unlike findings in patients with COS who had smaller GM volumes, as compared with findings in control subjects at initial imaging), which suggests that the GM reduction is specific to schizophrenia. Although the MDI group was comparable with the COS group for medication and hospitalization at first MRI, differences in medication status were seen at follow-up.

Although most patients in the MDI group at follow-up continued to receive atypical antipsychotic medications, none was receiving clozapine, while most patients with COS (15 [65%]) were receiving clozapine. The effect of clozapine on cortical GM has not been well studied either in animals or humans. In animal studies, clozapine can increase the striatal volume in rats undergoing long-term treatment,^{26,27} and in primates, antipsychotic treatment, including clozapine, can result in increased glial density, which can result in cortical hypertrophy.²⁸ Results in human studies support the increase in striatal volume with typical antipsychotic treatment, which is normalized with atypical antipsychotic medications.^{29,30}

However, there is no evidence that clozapine, as compared with other atypical agents, differentially influences either the degree or the rate of progression of the GM volume changes seen in schizophrenia. When the slopes of GM loss in patients with schizophrenia receiving clozapine ($n=13$) were compared with those in pa-

tients not receiving clozapine (n=25) from our larger sample of patients with COS (n=36) studied longitudinally, there was no significant difference between the slopes ($t_{36}=0.8$, $P=.4$).³¹ Similarly, for our larger COS cohort (n=36), slopes of GM loss for patients receiving clozapine (n=19) did not differ significantly from those for patients receiving olanzapine (n=13) for 2 to 4 years ($t_{30}=0.77$, $P=.4$).³¹

In agreement with our findings, other investigators have also found no significant association between clozapine treatment and prospective brain change³² (Daniel Mathalon, MD, oral communication, November 2002). Lieberman et al³³ in a multicenter study reported potential protective effects of olanzapine vs haloperidol use for 3 months to 2 years; however, we do not find evidence for a protective effect of olanzapine vs clozapine for COS at long-term follow-up.

More patients in the MDI group were receiving mood stabilizers as compared with patients in the COS group at baseline and follow-up. Mood stabilizers are claimed to have neuroprotective and neurotropic effects, which could cause hypertrophic changes in cortical GM.^{34,35} However, the mean slopes for patients receiving mood stabilizers in the MDI group (n=10) did not differ significantly from the mean slopes for patients in the MDI group not receiving these medications (n=9; $t_{16}=0.75$, $P=.46$). Again, within the larger sample of patients with COS (n=36) studied longitudinally, no significant association was found between GM reduction or slope, in loss of milliliters per year, and the groups receiving medication, including the 8 subjects receiving mood stabilizers ($t_{30}=0.06$, $P=.9$).³¹ Thus, the progressive GM loss seen in patients with COS appears to be independent of medication status.

The mechanism underlying GM loss in COS remains unknown. Either a progressive neurodevelopmental process and/or a specific plastic brain response to schizophrenia could account for this loss. Contrary to our prior findings,³⁶ a larger sample (n=50) of patients with COS showed no postpsychotic cognitive decline at 2 to 8 years (P. Gochman, MA, unpublished data, November 2003). Thus, the pronounced GM loss does not appear to be directly related to the loss of cognitive functioning. We speculate that the GM loss represents in part a plastic response of the brain to dysfunctional synaptic processing. Further studies will be necessary to test this hypothesis and its relationship to clozapine or other treatment.

In summary, patients with atypical nonschizophrenic childhood-onset psychotic disorders did not show the exaggerated longitudinal GM loss seen in a matched group of patients with COS. These results suggest that the progressive GM loss seen in COS during adolescence is specific to the illness and unrelated to medication exposure. Ongoing longitudinal MRI studies of full siblings of patients with COS are addressing whether this abnormal development may be a trait marker.

Submitted for publication February 24, 2003; final revision received June 9, 2003; accepted June 12, 2003.

Corresponding author: Nitin Gogtay, MD, Child Psychiatry Branch, Bldg 10, Room 3N 202, 10 Center Dr, MSC 1600, Bethesda, MD 20892-1600 (e-mail: nitin@codon.nih.gov).

- Nicolson R, Rapoport JL. Childhood-onset schizophrenia: rare but worth studying. *Biol Psychiatry*. 1999;46:1418-1428.
- Mathalon DH, Sullivan EV, Lim KO, Pfefferbaum A. Progressive brain volume changes and the clinical course of schizophrenia in men: a longitudinal magnetic resonance imaging study. *Arch Gen Psychiatry*. 2001;58:148-157.
- Weinberger DR, McClure RK. Neurotoxicity, neuroplasticity, and magnetic resonance imaging morphometry: what is happening in the schizophrenic brain? *Arch Gen Psychiatry*. 2002;59:553-558.
- DeLisi LE, Sakuma M, Tew W, Kushner M, Hoff AL, Grimson R. Schizophrenia as a chronic active brain process: a study of progressive brain structural change subsequent to the onset of schizophrenia. *Psychiatry Res*. 1997;74:129-140.
- Gur RE, Cowell P, Turetsky BI, Gallacher F, Cannon T, Bilker W, Gur RC. A follow-up magnetic resonance imaging study of schizophrenia: relationship of neuroanatomical changes to clinical and neurobehavioral measures. *Arch Gen Psychiatry*. 1998;55:145-152.
- Hirayasu Y, Shenton ME, Salisbury DF, Kwon JS, Wible CG, Fischer IA, Yurgelun-Todd D, Zarate C, Kikinis R, Jolesz FA, McCarley RW. Subgenual cingulate cortex volume in first-episode psychosis. *Am J Psychiatry*. 1999;156:1091-1093.
- Lieberman J, Chakos M, Wu H, Alvir J, Hoffman E, Robinson D, Bilder R. Longitudinal study of brain morphology in first episode schizophrenia. *Biol Psychiatry*. 2001;49:487-499.
- Wood SJ, Velakoulis D, Smith DJ, Bond D, Stuart GW, McGorry PD, Brewer WJ, Bridle N, Eritaia J, Desmond P, Singh B, Copolov D, Pantelis C. A longitudinal study of hippocampal volume in first episode psychosis and chronic schizophrenia. *Schizophr Res*. 2001;52:37-46.
- Rapoport JL, Giedd J, Kumra S, Jacobsen L, Smith A, Lee P, Nelson J, Hamburger S. Childhood-onset schizophrenia: progressive ventricular change during adolescence. *Arch Gen Psychiatry*. 1997;54:897-903.
- Rapoport JL, Giedd JN, Blumenthal J, Hamburger S, Jeffries N, Fernandez T, Nicolson R, Bedwell J, Lenane M, Zijdenbos A, Paus T, Evans A. Progressive cortical change during adolescence in childhood-onset schizophrenia: a longitudinal magnetic resonance imaging study. *Arch Gen Psychiatry*. 1999;56:649-654.
- Gogate N, Giedd J, Janson K, Rapoport JL. Brain imaging in normal and abnormal brain development: new perspectives for child psychiatry. *Clin Neurosci Res*. 2001;1:283-290.
- Kumra S, Jacobsen LK, Lenane M, Zahn TP, Wiggs E, Alagband-Rad J, Castellanos FX, Frazier JA, McKenna K, Gordon CT, Smith A, Hamburger S, Rapoport JL. "Multidimensionally impaired disorder": is it a variant of very early-onset schizophrenia? *J Am Acad Child Adolesc Psychiatry*. 1998;37:91-99.
- McKenna K, Gordon CT, Lenane M, Kaysen D, Fahey K, Rapoport JL. Looking for childhood-onset schizophrenia: the first 71 cases screened. *J Am Acad Child Adolesc Psychiatry*. 1994;33:636-644.
- Nicolson R, Lenane M, Brookner F, Gochman P, Kumra S, Spechler L, Giedd JN, Thaker GK, Wudarsky M, Rapoport JL. Children and adolescents with psychotic disorder not otherwise specified: a 2- to 8-year follow-up study. *Compr Psychiatry*. 2001;42:319-325.
- Kumra S, Frazier JA, Jacobsen LK, McKenna K, Gordon CT, Lenane MC, Hamburger SD, Smith AK, Albus KE, Alagband-Rad J, Rapoport JL. Childhood-onset schizophrenia: a double-blind clozapine-haloperidol comparison. *Arch Gen Psychiatry*. 1996;53:1090-1097.
- Giedd JN, Snell JW, Lange N, Rajapakse JC, Casey BJ, Kozuch PL, Vaituzis AC, Vauss YC, Hamburger SD, Kaysen D, Rapoport JL. Quantitative magnetic resonance imaging of human brain development: ages 4-18. *Cereb Cortex*. 1996;6:551-560.
- Giedd JN, Blumenthal J, Jeffries NO, Castellanos FX, Liu H, Zijdenbos A, Paus T, Evans AC, Rapoport JL. Brain development during childhood and adolescence: a longitudinal MRI study [letter]. *Nat Neurosci*. 1999;2:861-863.
- Chambers WJ, Puig-Antich J, Hirsch M, Paez P, Ambrosini PJ, Tabrizi MA, Davies M. The assessment of affective disorders in children and adolescents by semi-structured interview: test-retest reliability of the schedule for affective disorders and schizophrenia for school-age children, present episode version. *Arch Gen Psychiatry*. 1985;42:696-702.
- Talairach J, Tournoux P. *Co-Planar Stereotaxic Atlas of the Human Brain: 3-D Proportional System: An Approach to Cerebral Imaging*. New York, NY: Thieme Medical Publishers; 1988.
- Collins DL, Zijdenbos AP, Kollokian V, Sled JG, Kabani NJ, Holmes CJ, Evans AC. Design and construction of a realistic digital brain phantom. *IEEE Trans Med Imaging*. 1998;17:463-468.
- Zijdenbos AP, Dawant BM, Margolin RA. Automatic detection of intracranial contours in MR images. *Comput Med Imaging Graph*. 1994;18:11-23.
- Tabachnick BG, Fidell LS. *Computer-Assisted Research Design and Analysis*. Needham Heights, Mass: Allyn & Bacon; 2001:130-132.

23. Pantelis C, Velakoulis D, McGorry PD, Wood SJ, Suckling J, Phillips LJ, Yung AR, Bullmore ET, Brewer W, Soulsby B, Desmond P, McGuire PK. Neuroanatomical abnormalities before and after onset of psychosis: a cross-sectional and longitudinal MRI comparison. *Lancet*. 2003;361:281-285.
24. Drevets WC. Neuroimaging studies of mood disorders. *Biol Psychiatry*. 2000;48:813-829.
25. Drevets WC. Neuroimaging and neuropathological studies of depression: implications for the cognitive-emotional features of mood disorders. *Curr Opin Neurobiol*. 2001;11:240-249.
26. Andersson C, Hamer RM, Lawler CP, Mailman RB, Lieberman JA. Striatal volume changes in the rat following long-term administration of typical and atypical antipsychotic drugs. *Neuropsychopharmacology*. 2002;27:143-151.
27. Lee H, Tarazi FI, Chakos M, Wu H, Redmond M, Alvir JM, Kinon BJ, Bilder R, Creese I, Lieberman JA. Effects of chronic treatment with typical and atypical antipsychotic drugs on the rat striatum. *Life Sci*. 1999;64:1595-1602.
28. Selemon LD, Lidow MS, Goldman-Rakic PS. Increased volume and glial density in primate prefrontal cortex associated with chronic antipsychotic drug exposure. *Biol Psychiatry*. 1999;46:161-172.
29. Chakos MH, Lieberman JA, Alvir J, Bilder R, Ashtari M. Caudate nuclei volumes in schizophrenic patients treated with typical antipsychotics or clozapine. *Lancet*. 1995;345:456-457.
30. Frazier JA, Giedd JN, Kayser D, Albus K, Hamburger S, Alagband-Rad J, Lenane MC, McKenna K, Breier A, Rapoport JL. Childhood-onset schizophrenia: brain MRI rescan after 2 years of clozapine maintenance treatment. *Am J Psychiatry*. 1996;153:564-566.
31. Sporn AL, Greenstein DK, Gogtay N, Jeffries NO, Lenane M, Gochman P, Clasen LS, Blumenthal J, Giedd JN, Rapoport JL. Progressive brain volume loss during adolescence in childhood-onset schizophrenia. *Am J Psychiatry*. In press.
32. Fannon D, Chitnis X, Doku V, Tennakoon L, O'Ceallaigh S, Soni W, Sumich A, Lowe J, Santamaria M, Sharma T. Features of structural brain abnormality detected in first-episode psychosis. *Am J Psychiatry*. 2000;157:1829-1834.
33. Lieberman J, Charles C, McEvoy J, Perkins D, Hamer RM, Sharma T, Zipursky R, Kahn R, Gur R, Centorrino F, Glick I, Green AI, Nemeroff C, Rothchild A, Murray R. Antipsychotic treatment effects on progression of brain pathomorphology in first episode schizophrenia. Paper presented at: Annual Meeting of the American College of Neuropsychopharmacology; December 8-12, 2002; San Juan, Puerto Rico.
34. Manji HK, Moore GJ, Chen G. Clinical and preclinical evidence for the neurotrophic effects of mood stabilizers: implications for the pathophysiology and treatment of manic-depressive illness. *Biol Psychiatry*. 2000;48:740-754.
35. Mora A, Gonzalez-Polo RA, Fuentes JM, Soler G, Centeno F. Different mechanisms of protection against apoptosis by valproate and Li+. *Eur J Biochem*. 1999;266:886-891.
36. Bedwell JS, Keller B, Smith AK, Hamburger S, Kumra S, Rapoport JL. Why does postpsychotic IQ decline in childhood-onset schizophrenia? *Am J Psychiatry*. 1999;156:1996-1997.