

# Pathways That Make Voices

## White Matter Changes in Auditory Hallucinations

Daniela Hubl, MD; Thomas Koenig, PhD; Werner Strik, MD; Andrea Federspiel, PhD; Roland Kreis, PhD; Chris Boesch, MD, PhD; Stephan E. Maier, PhD; Gerhard Schroth, MD; Karl Lovblad, MD; Thomas Dierks, MD

**Background:** The origin of auditory hallucinations, which are one of the core symptoms of schizophrenia, is still a matter of debate. It has been hypothesized that alterations in connectivity between frontal and parietotemporal speech-related areas might contribute to the pathogenesis of auditory hallucinations. These networks are assumed to become dysfunctional during the generation and monitoring of inner speech. Magnetic resonance diffusion tensor imaging is a relatively new in vivo method to investigate the directionality of cortical white matter tracts.

**Objective:** To investigate, using diffusion tensor imaging, whether previously described abnormal activation patterns observed during auditory hallucinations relate to changes in structural interconnections between the frontal and parietotemporal speech-related areas.

**Methods:** A 1.5 T magnetic resonance scanner was used to acquire twelve 5-mm slices covering the Sylvian fissure. Fractional anisotropy was assessed in 13 patients prone to auditory hallucinations, in 13 patients without auditory hallucinations, and in 13 healthy control subjects. Structural magnetic resonance imaging was conducted in the same session. Based on an analysis of vari-

ance, areas with significantly different fractional anisotropy values between groups were selected for a confirmatory region of interest analysis. Additionally, descriptive voxel-based *t* tests between the groups were computed.

**Results:** In patients with hallucinations, we found significantly higher white matter directionality in the lateral parts of the temporoparietal section of the arcuate fasciculus and in parts of the anterior corpus callosum compared with control subjects and patients without hallucinations. Comparing patients with hallucinations with patients without hallucinations, we found significant differences most pronounced in the left hemispheric fiber tracts, including the cingulate bundle.

**Conclusion:** Our findings suggest that during inner speech, the alterations of white matter fiber tracts in patients with frequent hallucinations lead to abnormal co-activation in regions related to the acoustical processing of external stimuli. This abnormal activation may account for the patients' inability to distinguish self-generated thoughts from external stimulation.

*Arch Gen Psychiatry.* 2004;61:658-668

From the Department of Psychiatric Neurophysiology, University Hospital of Clinical Psychiatry, Bern, Switzerland (Drs Hubl, Koenig, Strik, Federspiel, and Dierks); the Departments of Magnetic Resonance Spectroscopy and Methodology (Drs Kreis and Boesch) and Neuroradiology (Drs Schroth and Lovblad), University of Bern, Bern; and the Department of Radiology, Brigham and Women's Hospital, Harvard Medical School, Boston, Mass (Dr Maier).

**A**UDITORY HALLUCINATIONS (AH), one of the most common psychiatric symptoms, elude a compelling explanation. They have been discussed in nearly every conceivable context, ranging from a very private experience to abnormal brain function in the frame of schizophrenia. In 1838, Esquirol<sup>1</sup> was the first to formulate the concept of a brain-based origin of hallucinations. Although AH occur with a lifetime prevalence of 10% to 15% in persons without neuropsychiatric diseases,<sup>2</sup> they are most common in schizophrenia, with an average prevalence of 60%.<sup>3</sup> Therefore, recent models of AH were generally based on results gained from investigations of patients with schizophrenia.<sup>4-6</sup> Neuropathologic,<sup>7,8</sup> structural magnetic

resonance imaging (MRI)<sup>9-12</sup> and functional MRI<sup>13-19</sup> studies suggest that the superior temporal lobe is altered in patients with AH, creating dysfunctions within brain regions that are important for language and auditory processing.

The present hypotheses of the generation of AH, considering recent neuroimaging findings, propose that AH derive from inner speech misidentified as external by means of defective self-monitoring.<sup>15</sup> Functional imaging studies in schizophrenic AH revealed involvement of the frontal motor and premotor speech areas (the Broca area and supplementary motor area) and temporoparietal speech areas (the Wernicke area) that are necessary for the decoding and encoding of language.<sup>15</sup> Additional regions described as involved in AH were the

**Table 1. Subject Characteristics\***

	Patients With Hallucinations	Patients Without Hallucinations	Healthy Control Subjects
Sample size	13	13	13
Age, mean $\pm$ SD, y†	33.3 $\pm$ 8.5	31.0 $\pm$ 9.3	32.0 $\pm$ 8.4
Sex	8 men; 5 women	8 men; 5 women	8 men; 5 women
Duration of illness, mean $\pm$ SD, y†	7.4 $\pm$ 7.2	8.9 $\pm$ 7.8	NA
Onset of illness, mean $\pm$ SD, y†	25.9 $\pm$ 7.1	22.1 $\pm$ 5.3	NA

Abbreviation: NA, not applicable.

\*Patients (n = 26) and healthy control subjects (n = 13) were all right-handed and matched for age. The 2 patient groups did not differ in duration of disease and onset of disease.

†Not significant as determined by *t* test.

primary<sup>13</sup> and higher-order auditory and association cortex located in the temporal lobe, mainly in the left hemisphere.<sup>13-18</sup> In right-handed individuals, the speech-relevant areas are predominantly located in the left hemisphere,<sup>20</sup> which may be related to the fact that the left hemisphere also appears to be more functionally involved in the generation of AH than the right hemisphere.<sup>4,5</sup> For normal speech functions, intact connections between speech-relevant regions are necessary,<sup>20</sup> but recent functional MRI<sup>21</sup> and electroencephalography<sup>22</sup> studies applying language tasks suggest dysfunctional interactions between frontal, parietal, and temporal brain regions in patients with AH. This finding supports the more general theories that schizophrenia involves disturbed frontoparietotemporal connectivity.<sup>23-25</sup> The microstructural foundation of these connections was not yet investigated because of a lack of methodical feasibility. Magnetic resonance diffusion tensor imaging (DTI) assesses the directionality of water diffusion (anisotropy), which is restricted by boundaries such as white matter (WM) fibers. The amount of anisotropy correlates with the directionality and coherence of fiber tracts.<sup>26</sup> Thus, a loss of WM directionality or disruption of the microstructure is reflected in reduced anisotropy values.<sup>27</sup> Of the relatively few studies published using DTI in schizophrenia, the majority reported reduced anisotropy in subjects with schizophrenia,<sup>28-34</sup> whereas the minority did not find differences between patients and control subjects.<sup>35-37</sup> However, these studies vary widely in terms of MRI methods and analysis strategies and are not directly comparable among each other. The more recent studies<sup>32,34</sup> focused on the WM fiber tracts connecting the frontal with the temporal and parietal cortex. Both studies demonstrated pathologic features in schizophrenia; a lack of normal left-greater-than-right asymmetry in the uncinate fasciculus in patients with schizophrenia<sup>32</sup> respectively decreased WM integrity in the left hemispheric arcuate and uncinate fasciculus.<sup>34</sup> Those studies provide in vivo support of the aforementioned neuroanatomical and neuro-functional reports of disruption of the frontal and temporal brain regions.

In an earlier functional MRI study, we demonstrated an increase of neuronal activity in the primary auditory cortex and language-related areas during hallucinations in patients with schizophrenia,<sup>13</sup> however, the relation to structural cerebral alterations remained unclear. In this study, we investigate whether altered neuronal activity during AH may be mediated by altered WM

connections in patients with schizophrenia with a history of frequent AH in comparison with patients with schizophrenia who reported never having perceived AH and healthy control subjects. We expected the most prominent hallucination-related differences in the arcuate fasciculus. This frontoparietotemporal fiber tract connects important language-related areas<sup>38</sup> that were reported to be most affected in schizophrenia in studies of structural and functional imaging.

## METHODS

### PARTICIPANTS

We investigated 13 patients with acute schizophrenia (*International Classification of Diseases, 10th Revision* diagnosis criteria)<sup>39</sup> with frequent AH (group H), 13 patients with acute schizophrenia who reported that they had never perceived AH (group N), and 13 healthy control subjects (group C). All patients were patients of the University Hospital for Clinical Psychiatry in Bern, Switzerland. The groups were matched for age and sex, and all subjects were right-handed (**Table 1**). None of the patients reported substance abuse before hospitalization except sporadic cannabis consumption by 4 patients (3 in group N; 1 in group H). Only patients and subjects without relevant medical disorders (except schizophrenia) were included based on medical history and medical and neurological examination. All patients but 2 received typical or atypical antipsychotic treatment in conventional dosages, in both patient groups. The investigation was conducted in accordance with the Declaration of Helsinki and approved by the local ethics committee. Before the investigation began, all patients and healthy control subjects gave their written informed consent to participate in the study.

### CLINICAL MEASURES

To assign each individual patient to 1 subtype of symptom (trait), an extensive semistructured interview concerning medical history, with a special focus on the perception of AH, was assessed before scanning. Furthermore, the files of every patient were studied to add missing data. The group without hallucinations included only patients who had never experienced AH, neither at the time of this investigation nor at any time in their previous history. The patients prone to hallucinations experienced verbal AH at the time of the present hospitalization as well as during all the prior exacerbations of their disease.

The Oulis et al<sup>40</sup> AH rating scale was used to document the character of AH. The hallucinations fulfilled the criteria of the Schneiderian first-rank symptoms of comment or dialog

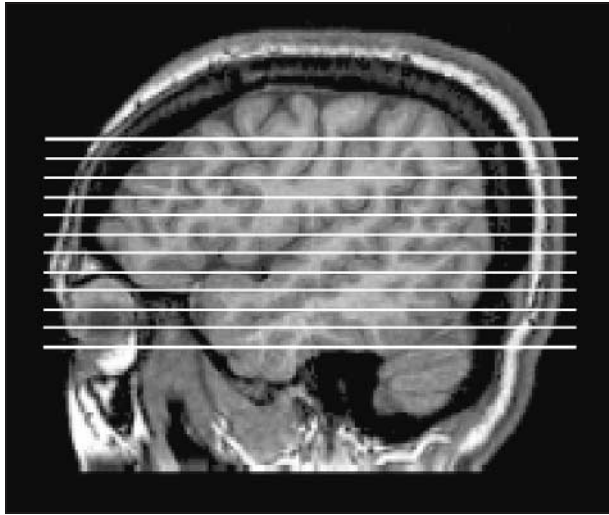
**Table 2. Assessment of Clinical Measures\***

	Patients With Hallucinations	Patients Without Hallucinations	t Test	
			t Statistic	P Value
PANSS				
Total	91.7 ± 14.3	83.0 ± 18.3	1.35	.19
Positive	23.2 ± 5.9	17.7 ± 6.7	2.21	.04†
Negative	21.6 ± 4.3	22.3 ± 6.6	0.31	.76
CGI	5.5 ± 1.1	5.4 ± 0.5	0.47	.69

Abbreviations: CGI, Clinical Global Impressions Scale; PANSS, Positive and Negative Syndrome Scale.

\*Values are expressed as mean ± SD unless otherwise indicated. Patients with hallucinations (n = 13) scored higher ( $P \leq .05$ ) than patients without hallucinations (n = 13) in the positive subscore and total score because of higher scores in the questions concerning hallucinations and delusion.

†Significant at  $P \leq .05$ .



**Figure 1.** Localization of 12 acquired axial slices. Measured volume was optimized to cover regions known to be important in the generation of auditory hallucinations, such as the inferior frontal gyrus, the superior temporal gyrus, and the Wernicke area.

voices in all patients with AH. Eight of 13 patients reported that the voices were coming from outside their heads, whereas 3 of 13 experienced voices coming from inside and outside the head. Eight of 13 patients perceived the voices to be as loud as real voices, and 3 of 13 perceived them to be quieter or like a whispering voice. All patients were convinced that the voices were real. Two patients refused the interview for the hallucination assessment.

The Positive and Negative Syndrome Scale<sup>41</sup> and Clinical Global Impressions Scale<sup>42</sup> were used to assess psychopathologic symptoms and the severity and acuity of the disease (state). The Positive and Negative Syndrome Scale did not differ significantly between the patient groups for the total score and the negative subscore. The positive subscore was significantly higher in the group with AH ( $P \leq .05$ ). Higher values were because of higher scores on the hallucination and delusion subscore (**Table 2**).

#### MAGNETIC RESONANCE IMAGING

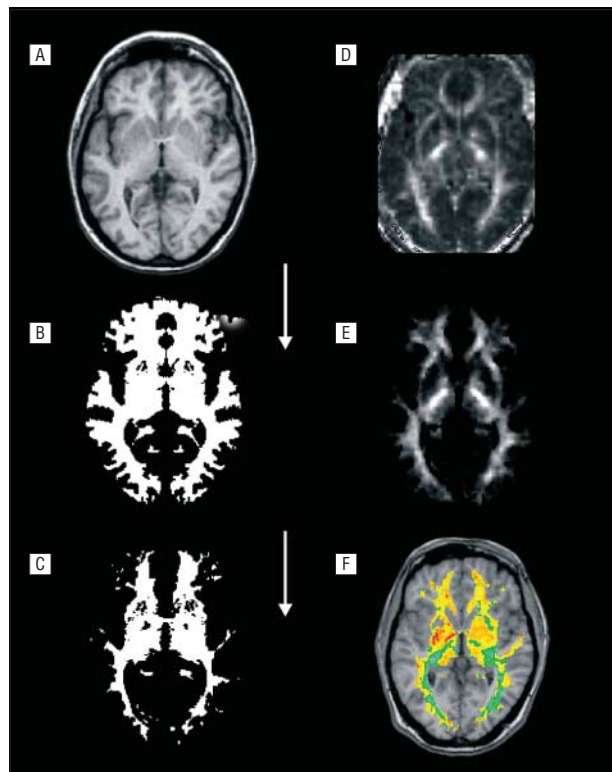
A 1.5 T Signa MR system (version 5.8, equipped with echo-sped gradients of 22 mT/m; General Electric Medical Systems, Milwaukee, Wis) was used for the investigations. In 1 session, 3-dimensional structural images and diffusion tensors were assessed. Individual whole brain 3-dimensional anatomy was measured with a 3-dimensional gradient echo sequence, providing 124 axial slices with 1.2-mm thickness,

240 mm × 240-mm field of view, and 256 × 128-pixel resolution. Further scanning parameters were as follows: repetition time, 22 milliseconds; echo time, 8 milliseconds; and flip angle, 45°. The original voxel size of 0.94 × 1.88 × 1.20 mm<sup>3</sup> was interpolated to a voxel size of 1 × 1 × 1 mm<sup>3</sup> with Brain-Voyager2000 software (BrainInnovation, Maastricht, the Netherlands). Total 3-dimensional scan time was 9.04 minutes.

Diffusion tensor imaging was realized with a line-scan technique<sup>43</sup> that provides a line-by-line spin-echo sampling of each slice. In contrast to the more widespread echo planar (ie, gradient echo) method, this technique is less sensitive to susceptibility-related distortions and, as with single-shot echo planar imaging, it is fairly motion insensitive, which is favorable when imaging is done on patients with schizophrenia. Eddy current-related distortions are also very small, in particular after an eddy-current correction of the DTIs, which is based on cross-correlation with T2-weighted images. In the line-scan technique, patient motion does not lead to ringing artifacts in phase direction but rather to discontinuities that can be detected and eliminated in postprocessing. This leads to robustness with respect to patient motion. The reliability of the apparent diffusion coefficient determined by line scanning was found to be very high in healthy subjects and patients who had had strokes.<sup>44</sup> Similarly, the fractional anisotropy (FA)<sup>45</sup> values are more reproducible with the line-scan technique than with echo planar imaging sequences (S.E.M., unpublished data, November 2003). Twelve axial slices (parallel to the anatomical data set) with 5-mm slice thickness and 1-mm interslice distance were measured. This volume covered a region around the Sylvian fissure, including the inferior frontal gyrus up to the angular gyrus (**Figure 1**). For each slice, 6 images with high diffusion weighting ( $\beta = 1000 \text{ s/mm}^2$ ) in 6 different directions and 2 images with low diffusion weighting ( $\beta = 5 \text{ s/mm}^2$ ) were collected. The field of view was 220 mm × 165 mm; scan matrix, 128 × 96 pixels, interpolated to a final image size of 256 × 256 pixels; repetition time, 3360 milliseconds; echo time, 90 milliseconds; and interpolated DTI voxel size, 0.86 × 0.64 × 5.00 mm<sup>3</sup>. Scanning time for the complete diffusion tensor sequences was 16.34 minutes. Total magnetic resonance scanning time including the localizer scan was about 30 minutes.

#### DATA PROCESSING AND ANALYSIS

After reconstruction of the DTIs, eigenvalues and eigenvectors of the diffusion tensor were determined. Fractional anisotropy values were calculated for each image. The 2-dimensional diffusion maps were incorporated into the 3-dimensional anatomy data sets through interpolation to the same resolution (voxel size, 1 mm<sup>3</sup>). This allowed us to superimpose 3-dimensional statistical maps onto the 3-dimensional anatomical data sets for visualization of statistical differences. The 2-dimensional diffusion images and 3-dimensional structural measurement were aligned using posi-



**Figure 2.** Three-dimensional anatomical data (A) were analyzed, and coregistered fractional anisotropy maps were rotated, normalized, and transformed to Talairach space (D). Individually, anatomy was segmented at the gray–white-matter (WM) boundary (B). Ninety percent WM probability was estimated using  $\chi^2$  distribution (C). Fractional anisotropy analysis was restricted to the WM volume (E). Voxelwise analysis of variance and *t* test comparisons were computed between groups, and significant results were fused with the anatomical data for better orientation (F).

tion files of the magnetic resonance scanner. For confirmation of the coregistration accuracy, a structural 2-dimensional data set was obtained by reslicing the 3-dimensional data and compared visually with the DTI data in each individual. For each subject, the structural data sets were transformed into Talairach space, following the transformation procedure published elsewhere.<sup>13</sup> On the basis of the parameters for importing the 2-dimensional DTI slices into the 3-dimensional data and on the parameters for transforming the 3-dimensional data sets into Talairach space, the complete DTI data set of each subject was also transformed into Talairach space. The study focused on alterations in WM fiber tracts. Therefore, after the individual anatomical data sets at the gray matter–WM boundary were segmented,<sup>46</sup> the analysis was restricted to voxels identified as WM. Because the segmentation in the region of the basal ganglia was inconsistent across subjects, this region was excluded from analysis. To avoid spurious effects, group statistics were computed only where there was a significant ( $P \leq .10$ ) preponderance of WM over gray matter as assessed by  $\chi^2$  statistics across subjects (**Figure 2**).

In a first step, a voxel-based 1-way analysis of variance (ANOVA) restricted to WM volume was performed with the factor “group” (C, H, and N) as a single factor. To avoid potential registration errors and disease-related misalignments in Talairach space, a region of interest (ROI) analysis based on the ANOVA was computed. The WM tracts identified as significantly different between groups by the ANOVA were selected in each study subject by using the individual coregistered T1 and DTIs. The mean FA values of each ROI were used for a 3-way ANOVA (factors were “group” [C, H, and N], “hemisphere” [left, right], and “ROI” [lateral and medial arcuate fas-

**Table 3. Analysis of Significant Clusters for Comparison Between 13 Healthy Control Subjects (Group C) and 26 Patients (Group P)\***

	Talairach Coordinate			Cluster Size, No. of Voxels	Group With Higher Value in Comparison
	x	y	z		
Arcuate fasciculus					
Temporoparietal					
Left hemisphere	-34	-45	26	569	C
Right hemisphere	24	-43	35	100	C
Frontal					
Left hemisphere	-32	-23	29	394	C
Right hemisphere	22	-8	35	274	C
Right hemisphere	25	-19	35	499	C
Temporal					
Left hemisphere	-31	-43	8	126	C
Right hemisphere	33	-33	7	409	C
Uncinate fasciculus					
Left hemisphere	-19	12	-6	195	C
Right hemisphere	34	2	-2	154	C
Inferior longitudinal fasciculus					
Left hemisphere	-26	-60	8	550	C
Right hemisphere	28	-61	4	553	C
Corpus callosum					
Anterior					
Left hemisphere	-14	27	2	547	C
Right hemisphere	21	31	10	2133	C
Left hemisphere	-16	9	29	712	C
Right hemisphere	1	21	7	118	C
Posterior					
Left hemisphere	-26	-60	8	550	C
Right hemisphere	28	-61	4	553	C

\*White matter fiber tract, hemisphere, Talairach coordinates (x, y, z), and cluster size (number of voxels) for the regions located in the main white matter fiber bundles with a difference of  $P \leq .05$  in the *t* statistics between groups C and P are tabulated. For every region, the C group reaches higher values compared with the group of all patients.

ciculus]). Post hoc unpaired *t* tests were computed between the groups where appropriate.

Subsequently, for further descriptive statistics, 3-dimensional statistical maps (using a voxelwise, 2-tailed, unpaired *t* test) were computed, comparing the FA values between healthy control subjects and patients, between the 2 patient groups (H vs N), and between each patient group and control subjects (H vs C and N vs C). To identify the most involved regions and to reduce the problem of multiple testing, clusters containing more than 99 neighboring voxels ( $100 \text{ mm}^3$ ) with differences of  $P \leq .05$  were identified. For each cluster, FA values were averaged and tabulated (**Table 3** and **Table 4**). Further, the Talairach<sup>47</sup> coordinates of the center of gravity were noted. Clusters were assigned to the underlying WM fiber tracts using 3-dimensional anatomical data. Data analysis and visualization were realized with BrainVoyager and in-house software.

## RESULTS

In the voxel-based 1-way ANOVA, several significant clusters in long association and commissural fiber tracts were found. As we focused on speech- and language-related brain regions, the subsequent confirmatory ROI analysis (3-way ANOVA) included values for the medial and lateral arcuate fasciculus of both hemispheres



**Table 4. Analysis of Significant Clusters for Comparison Between 13 Patients With Hallucinations (Group H) and 13 Patients Without Hallucinations (Group N) and 13 Healthy Control Subjects (Group C)\***

	Talairach Coordinate			Cluster Size, No. of Voxels	Group With Higher Value in Comparison
	x	y	z		
<b>(A) H vs N</b>					
Arcuate fasciculus					
Frontal					
Left hemisphere	-27	5	25	345	H
Left hemisphere	-39	-6	26	120	H
Frontoparietal					
Left hemisphere	-29	-20	31	324	H
Right hemisphere	26	-24	34	145	H
Right hemisphere	50	-21	27	142	H
Temporoparietal					
Left hemisphere	-41	-46	14	402	H
Right hemisphere	37	-44	29	126	H
Temporal					
Left hemisphere	-41	-34	2	128	H
Left hemisphere	-34	-38	9	131	H
Right hemisphere	44	-30	7	186	H
Inferior longitudinal fasciculus					
Left hemisphere	-36	-42	-6	233	N
Left hemisphere	-27	-27	-2	152	N
Cingulate bundle					
Frontoparietal					
Left hemisphere	-7	-29	32	168	H
Inferoposterior					
Left hemisphere	-15	-28	0	150	H
Corpus callosum					
Anterior					
Left hemisphere	-11	33	13	837	H
Right hemisphere	10	30	7	512	H
Posterior					
Left hemisphere	-19	-48	20	135	H
<b>(B) H vs C</b>					
Arcuate fasciculus					
Prefrontal					
Left hemisphere	-31	25	17	314	C
Right hemisphere	33	26	15	125	C
Frontoparietal					
Left hemisphere	-33	-43	26	305	C
Right hemisphere	26	-19	35	209	C
Temporoparietal					
Left hemisphere	-42	-46	23	127	H
Right hemisphere	40	-44	18	145	H
Temporal					
Right hemisphere	33	-35	6	206	C
Uncinate fasciculus					
Left hemisphere	-33	-29	-2	688	C
Right hemisphere	35	-13	-11	292	C
Inferior longitudinal fasciculus					
Left hemisphere	-26	-63	5	738	C
Right hemisphere	30	-60	0	503	C
Corpus callosum					
Anterior					
Left hemisphere	-8	30	16	280	H
Right hemisphere	18	26	13	1992	C
Left hemisphere	-14	28	4	299	C
Left hemisphere	-18	23	23	116	C
Left hemisphere	-16	0	32	371	C

(continued)

(Figure 3A). The ANOVA demonstrated a significant main effect of hemisphere and a significant interaction of group  $\times$  hemisphere (Table 5). Post hoc *t* tests ( $P \leq .05$ ) showed that (1) FA values were higher in the

right than in the left hemisphere, (2) patients with AH had higher FA values in the left lateral arcuate fascicle than did both patients without AH and healthy control subjects, and (3) control subjects had higher FA values

**Table 4. Analysis of Significant Clusters for Comparison Between 13 Patients With Hallucinations (Group H) and 13 Patients Without Hallucinations (Group N) and 13 Healthy Control Subjects (Group C)\* (cont)**

	Talairach Coordinate			Cluster Size, No. of Voxels	Group With Higher Value in Comparison
	x	y	z		
(C) N vs C					
Arcuate fasciculus					
Frontal					
Left hemisphere	-24	1	40	139	C
Right hemisphere	21	15	37	149	C
Left hemisphere	-23	0	32	363	C
Right hemisphere	20	-11	43	107	C
Frontoparietal					
Left hemisphere	-32	-20	30	794	C
Left hemisphere	-26	-21	39	112	C
Right hemisphere	25	-17	35	1292	C
Temporoparietal					
Left hemisphere	-32	-40	26	280	C
Right hemisphere	38	-30	26	154	C
Left hemisphere	-38	-53	26	222	C
Temporal					
Right hemisphere	33	-32	8	520	C
Uncinate fasciculus					
Left hemisphere	-36	-21	-5	611	C
Right hemisphere	33	5	1	214	C
Inferior longitudinal fasciculus					
Left hemisphere	-25	-62	7	267	C
Right hemisphere	27	-61	6	256	C
Corpus callosum					
Anterior					
Right hemisphere	26	35	9	1132	C
Right hemisphere	19	30	19	240	C
Left hemisphere	-13	28	1	420	C
Right hemisphere	11	28	3	344	C
Left hemisphere	-13	14	26	773	C
Middle					
Left hemisphere	-20	-22	28	141	C

\*Regions located in the main white matter fiber bundles with a difference of  $P \leq .05$  in  $t$  statistics for the comparison of the 2 patient groups with each other ( $t$  test comparison A) and the comparison of each patient group with the healthy subjects are tabulated ( $t$  test comparisons B and C). White matter fiber tract, hemisphere, Talairach coordinates (x, y, z), and cluster size (number of voxels) are given for these regions.

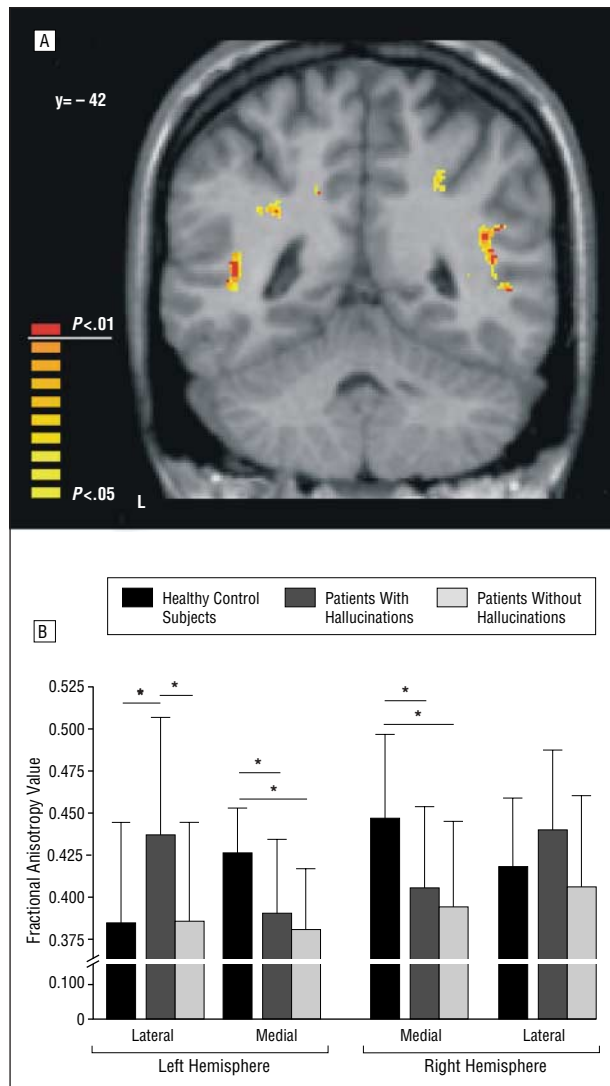
in the medial arcuate fascicle than did patients with AH and patients without AH (Table 5) (Figure 3B).

#### COMPARISON OF FA VALUES BETWEEN HEALTHY CONTROL SUBJECTS AND ALL PATIENTS WITH SCHIZOPHRENIA

In the voxelwise  $t$  tests, FA values were lower in patients with schizophrenia in many parts of the WM. The identification of voxel clusters and the corresponding WM tracts yielded 17 significant regions (Table 3), 8 clusters in the left and 9 in the right hemisphere. Significantly higher FA values in the voxel-based analysis for control subjects were observed in the long anterior-to-posterior association fibers in large parts of the arcuate fasciculus (superior longitudinal fasciculus), the uncinate fasciculus, and the inferior longitudinal fasciculus in both hemispheres (Figure 4). Further, higher FA values were observed in control subjects in parts of the corpus callosum (CC) (Figure 4). There were no clusters with higher values in patients with schizophrenia.

#### COMPARISON OF FA VALUES BETWEEN PATIENTS WITH SCHIZOPHRENIA WITH AND WITHOUT HALLUCINATIONS

Patients with AH showed voxels with significant higher FA values in many parts of the WM (Figure 5A). A total of 12 clusters were located in the left hemisphere and 5 in the right. There were 15 clusters with higher FA values in patients with AH compared with patients without AH and only 2 clusters with higher FA values in patients without AH compared with patients with AH. The most important differences for the 2 patient groups could be observed in the arcuate fasciculus (10 of 17 clusters), with a slight dominance of the left hemisphere (6 of 10 clusters). The significantly higher FA clusters in patients with AH were distributed from prefrontal WM passing the parietal WM down into the temporal lobe part of the arcuate fasciculus. The largest cluster (402 voxels) was located in the left temporoparietal section of the arcuate fasciculus (Figure 5A). Furthermore in the left cingulate bundle, part of the limbic system, patients with AH had higher FA values compared with patients with-



**Figure 3.** A, Significant voxels resulting from a 1-way analysis of variance comparing healthy control subjects ( $n=13$ ), patients with hallucinations ( $n=13$ ), and patients without hallucinations ( $n=13$ ). B, On the basis of this analysis of variance, a confirmatory region of interest analysis was calculated for 4 regions, including the medial (left hemisphere, mean [SD] Talairach coordinates  $x, y, z$ , respectively,  $-32 [1], -42 [2]$ , and  $25 [2]$ ; right hemisphere,  $22 [2], -42 [2]$ , and  $34 [2]$ ) and lateral arcuate fasciculus (left hemisphere,  $-42 [2], -38 [8], 4 [3]$ ; right hemisphere,  $38 [2], -43 [1]$ , and  $17 [2]$ ). Mean (SD) fractional anisotropy values and post hoc results are presented. Asterisk indicates  $P \leq .05$ .

out AH. Finally, there were higher FA values in the anterior and posterior parts of the interhemispherical commissural fibers of the CC (Figure 5 A). The clusters with higher FA values in patients without AH were located in the left inferior longitudinal fasciculus.

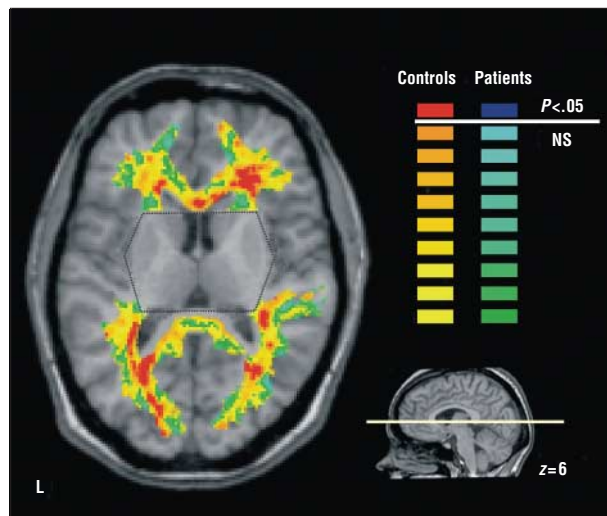
#### COMPARISON OF FA VALUES BETWEEN PATIENTS WITH SCHIZOPHRENIA WITH HALLUNICATIONS AND HEALTHY CONTROL SUBJECTS

There were 16 significant clusters in the comparison of patients with schizophrenia with AH vs healthy control subjects. Thirteen demonstrated lower values in patients with schizophrenia with AH whereas 3 showed

**Table 5. Repeated Measures Analysis of Variance\***

	F Test (df)	P Value
Group	2.72 (2,35)	.07
Region	0.27 (1,35)	.61
Hemisphere	6.67 (1,35)	.01
Group $\times$ region	7.17 (2,35)	.002
Group $\times$ hemisphere	0.84 (2,35)	.44
Region $\times$ hemisphere	0.01 (1,35)	.92
Group $\times$ region $\times$ hemisphere	0.25 (2,35)	.78

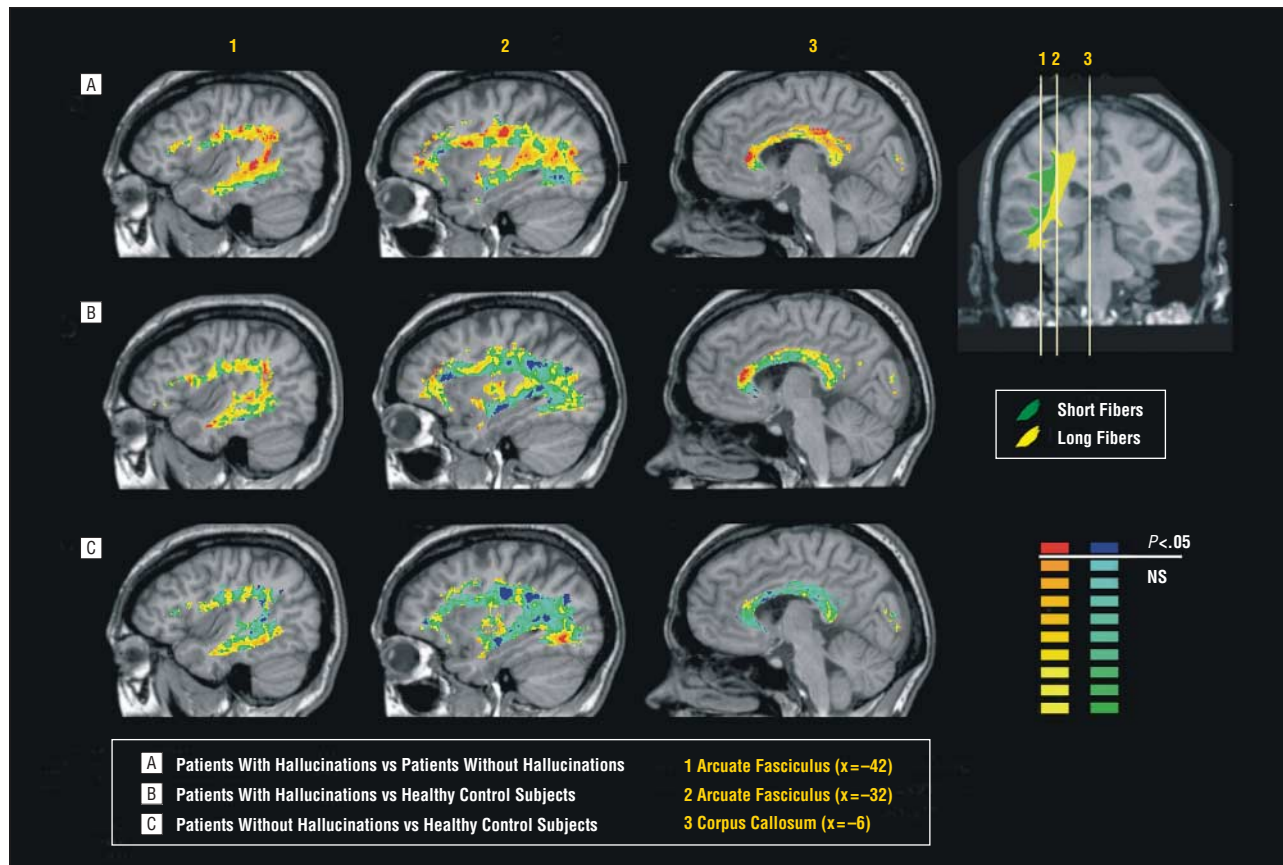
\*Factors were group (healthy controls, patients with hallucinations, patients without hallucinations), region (lateral arcuate fasciculus, medial arcuate fasciculus), and hemisphere (left, right).



**Figure 4.** Voxelwise comparison between healthy control subjects ( $n=13$ ) and all patients with schizophrenia ( $n=26$ ). Patients with schizophrenia show lower fractional anisotropy values in wide parts of various white matter tracts. In this axial slice, the lower fractional anisotropy values in patients are shown at the level of the corpus callosum and the inferior longitudinal fasciculus. The region of the basal ganglia, which was excluded from the analysis because of inconsistent segmentation, is indicated by the dotted gray line. NS indicates not significant.

higher values in patients with schizophrenia with AH (Table 4B). These regions in which patients with AH had significantly higher FA values compared with control subjects were located in the lateral left and right temporo-parietal section of the arcuate fasciculus close to the posterior end of the Sylvian fissure—where the Wernicke area is located—and close to the auditory regions (Figure 5B). Patients with AH showed generally higher FA values in the lateral part of the arcuate fasciculus whereas control subjects showed generally higher FA values in the medial parts of the arcuate fasciculus. Further, patients with AH did have higher FA values in the left anterior CC compared with control subjects (Figure 5B).

In 13 clusters (6 in the left, 7 in the right hemisphere), lower FA values were observed in patients with AH in comparison with control subjects. These clusters were distributed in the prefrontal to the temporal arcuate fasciculus (medial), in the uncinata fasciculus, and in the inferior longitudinal fasciculus. Further clusters were located in the more ventral part of the anterior CC (Figure 5B).



**Figure 5.** The medial part of the arcuate fasciculus contains long fibers connecting the frontal with the temporal cortex, whereas the lateral part, with its shorter U-shaped fibers, connects, for example, the language-related regions in the frontal and parietotemporal lobes. The main differences between patients with hallucinations ( $n = 13$ ) and healthy control subjects ( $n = 13$ ) as well as patients without hallucinations ( $n = 13$ ) were located in the lateral fibers of the arcuate fasciculus (1) and the anterior corpus callosum (3). NS indicates not significant.

### COMPARISON OF FA VALUES BETWEEN PATIENTS WITH SCHIZOPHRENIA WITHOUT AH AND HEALTHY CONTROL SUBJECTS

In all 21 clusters with significant differences, patients with schizophrenia without AH had lower FA values compared with control subjects (Table 3). Eleven of the 21 clusters were located in the left hemisphere. Significant clusters were located in the frontotemporal arcuate fasciculus (Figure 5C), the uncinate fasciculus, and the inferior longitudinal fasciculus as well as in the anterior and medial sections of the CC (Figure 5C).

#### COMMENT

In 1919, Kraepelin<sup>48</sup> had already postulated that AH were a result of temporal lobe abnormalities. This hypothesis was supported by severe abnormalities in the left temporal lobe in the brains of patients with schizophrenia, found post mortem or in structural imaging studies<sup>49</sup>; these abnormalities were thought to be related to AH. In 1900, Wernicke<sup>30</sup> hypothesized that a pathologic activation of the primary acoustic cortex was the basis of the experience of external sensory stimulation during AH. In fact, a dysfunction of temporal cortical areas, in particular of the primary auditory cortex, and of frontal speech areas was reported in AH, suggesting an association with im-

paired auditory and language-processing networks.<sup>19</sup> However, it remained unclear to what degree WM alterations in fiber tracts constituting parts of these functional networks were involved in the pathogenesis of AH.

In the present study, we investigated the integrity of WM fiber tracts in patients with schizophrenia with frequent AH, patients who had never experienced hallucinations, and healthy control subjects. Using a line-scan DTI sequence,<sup>43</sup> we obtained FA data in a 3-dimensional volume covering the Sylvian fissure. The arcuate fasciculus contains—among others—fibers connecting the frontal, parietal, and temporal language and auditory areas. Compared with healthy control subjects, patients with a history of AH demonstrated, especially in the left hemisphere, an imbalance in directionality of the arcuate fasciculus, with higher directionality in the lateral part of the arcuate fasciculus and decreased directionality of WM fibers in the medial part of the arcuate fasciculus. This pattern could not be demonstrated for patients without AH. The arcuate fasciculus is divided into (1) a medial part that contains longer fibers connecting the lateral frontal cortex with the dorsolateral parietal and temporal cortex and (2) a lateral part, with shorter U-shaped fibers connecting the frontoparietal, parietooccipital, and parietotemporal cortex<sup>51</sup>; fibers originate in the prefrontal and premotor gyri (mainly the Broca area) and project among others posterior to the Wer-



nicke area. Thus, the lateral part of the arcuate fasciculus provides a pathway by which frontal speech-production areas can influence auditory and speech perception areas during overt and inner speech. The importance of the arcuate fasciculus in language is underlined by results from neurological findings in aphasia research. A disruption of the arcuate fasciculus leads to a disturbance of the neuronal connections from the frontal Broca area to the temporal Wernicke area, which results in a disturbance of the stream of speech.<sup>52</sup> One link between AH and inner speech is the common clinical observation that the content of AH is often closely related to the content of the patient's own thought and sometimes is even reported as thoughts becoming loud. The exact neurobiological functional correlate of alterations of FA remains unclear; however, most in vivo human and animal studies investigating FA values during neuronal development and functional disturbances in neuropsychiatric diseases suggest that an increase of FA values is related to an increase of connectivity in WM bundles.<sup>53</sup> Therefore, it can be hypothesized that high WM directionality in the lateral part of the arcuate fasciculus in AH is associated with high connectivity between distributed language and auditory areas. This may facilitate the dysfunctional coactivation of the primary auditory cortex and language-related areas that has been previously described during AH.<sup>13</sup> In the medial part of the arcuate fasciculus, both patient groups showed smaller directionality than did control subjects, which is in accordance with a recent report observing reduced left hemispherical FA values in the arcuate fascicle in schizophrenia.<sup>34</sup> This might provide a structural alteration associated with disrupted frontotemporal processing.<sup>23-25</sup> The more pronounced alterations in the left hemisphere, the same hemisphere reportedly more affected in schizophrenia, may be related to language dominance.<sup>54</sup> The fiber tracts found to be affected here coincide with those that show the strongest developmental changes during childhood and adolescence.<sup>55</sup> This allows speculation about a developmental origin of the aforementioned alterations of the arcuate fasciculus in patients with AH and suggests a relation between AH and WM aberrance.

The CC carries most of the commissural fibers in the cerebrum, interconnecting left with the correspondent right hemispheric regions,<sup>38</sup> mediating interhemispheric communication. It was argued<sup>56</sup> that the deficit in information processing in schizophrenia might be related to alterations in the CC. Many studies on the size of the CC have shown smaller volumes in schizophrenia; however, these findings are not unequivocal.<sup>49,57</sup> Even if no concluding macrostructural results were obvious, behavioral experiments gave evidence for a specific excessive callosal transfer in schizophrenia.<sup>58</sup> However, a recent study searching for a specific relation between AH and the CC failed to show clear volumetric differences.<sup>59</sup> In the present study, we report higher directionality in the anterior part of the CC, including fibers that connect the left with the right frontal speech-related areas. This gives—on a microstructural level—support to the earlier assumption of higher callosal transfer in patients with schizophrenia with AH.

In most parts of the CC, however, patients demonstrated smaller FA values compared with control subjects. Results on FA values in the CC of previous DTI studies are not fully consistent, even though most showed reduced FA values in schizophrenia.<sup>30,31</sup> However, 1 group failed to replicate their own findings in a second study.<sup>36</sup>

The uncinate fasciculus connects the temporal pole with the orbitofrontal cortex. It includes projection fibers from the somatosensory cortex and auditory cortex.<sup>38</sup> In the present study, the directionality in the uncinate fasciculus was significantly smaller in both groups with schizophrenia compared with healthy subjects, and there was no difference between patients with and without hallucinations. Thus, compared with the arcuate fasciculus, the uncinate fasciculus appears less important for the generation of AH. In general, our results agree with previously found reduced FA values in the left uncinate fascicle, although we found reduced values in both hemispheres.<sup>34</sup> Although we found reduced anisotropy in the uncinate fasciculus in schizophrenia, we could not confirm the previously reported related loss of normal left-higher-than-right FA asymmetry,<sup>32</sup> a physiological asymmetry that might indirectly relate to specialized, lateralized functions such as language to AH. Kubicki et al<sup>32</sup> raised the issue of whether their findings were restricted to the uncinate fascicle or a general phenomenon in schizophrenia. Our results show various fasciculi to be affected in schizophrenia and a differential involvement of the WM tracts depending on psychopathologic features (in this study, AH).

The third important frontotemporal fiber tract besides the arcuate and uncinate fasciculus is the cingulate bundle. It is, in contrast to the arcuate and uncinate fasciculus, part of the limbic system. The cingulate gyrus is discussed as an “interface between emotion and cognition,”<sup>60(p107)</sup> and impairment is found in several psychiatric disorders such as schizophrenia,<sup>61</sup> obsessive-compulsive disorder,<sup>62</sup> and major depression.<sup>63</sup> In the cingulate bundle, we demonstrated a reduced anisotropy in patients without hallucinations compared with patients who had hallucinations, but restricted to the left hemisphere. This difference was not obvious in the comparison of either patient group with control subjects. This is in accordance with the earlier studies that also did not find differences of FA values in the cingulate bundle when comparing patients with schizophrenia without respect to psychopathologic features.<sup>34</sup> From functional imaging studies, there is evidence of the involvement of the anterior<sup>64-66</sup> and of the left-sided posterior regions<sup>67</sup> of the cingulate gyrus in the generation of AH. Our finding of higher FA values in AH is located in the left medioposterior part of the cingulate bundle and may be related to a microstructural level to reports of pathologic, high activation shown in imaging studies.

In conclusion, those WM fibers that we found to be most altered in patients who had AH constitute the most important connections between language-related frontal and temporal regions. These alterations may have a developmental origin and may contribute to an understanding of how internally generated language is perceived to be generated externally. The aberrant connections may lead to abnormal activation in regions that

normally process external acoustical and language stimuli. That accounts for these patients' inability to distinguish self-generated thoughts from external stimulation.

Submitted for publication September 29, 2002; final revision received June 4, 2003; accepted February 6, 2004.

This study was supported by grants 3200-059077.99 (Dr Dierks) and 31-59082.99 (Dr Kreis) from the Swiss National Science Foundation, Bern.

We thank Karin Zwygart for performing the magnetic resonance imaging measurements.

Correspondence: Daniela Hubl, MD, Department of Psychiatric Neurophysiology, University Hospital of Clinical Psychiatry, Bolligenstrasse 111, CH-3000 Bern 60, Switzerland (hubl@puk.unibe.ch).

## REFERENCES

1. Esquirol E. *Des maladies mentales considérées sous les rapports médicaux*. Paris, France: Baillière; 1838.
2. Tien AY. Distributions of hallucinations in the population. *Soc Psychiatry Psychiatr Epidemiol*. 1991;26:287-292.
3. Slade P, Bentall R. *Sensory Deception: A Scientific Analysis of Hallucination*. London, England: Croom Helm; 2002.
4. Weiss AP, Heckers S. Neuroimaging of hallucinations: a review of the literature. *Psychiatry Res*. 1999;92:61-74.
5. David AS. Auditory hallucinations: phenomenology, neuropsychology and neuroimaging update. *Acta Psychiatr Scand Suppl*. 1999;395:95-104.
6. Nayani TH, David AS. The auditory hallucination: a phenomenological survey. *Psychol Med*. 1996;26:177-189.
7. Southard EE. A study of the dementia praecox group in the light of certain cases showing abnormalities or scleroses in particular brain regions. *Am J Insanity*. 1910;67:119-176.
8. Southard EE. On the topographic distribution of cortex lesions and anomalies in dementia praecox with some account of their functional significance. *Am J Insanity*. 1915;71:671.
9. Barta PE, Pearlson GD, Powers RE, Richards SS, Tune LE. Auditory hallucinations and smaller superior temporal gyral volume in schizophrenia. *Am J Psychiatry*. 1990;147:1457-1462.
10. Levitan C, Ward PB, Catts SV. Superior temporal gyral volumes and laterality correlates of auditory hallucinations in schizophrenia. *Biol Psychiatry*. 1999;46:955-962.
11. Shapleske J, Rossell SL, Simmons A, David AS, Woodruff PW. Are auditory hallucinations the consequence of abnormal cerebral lateralization? a morphometric MRI study of the sylvian fissure and planum temporale. *Biol Psychiatry*. 2001;49:685-693.
12. Flaum M, O'Leary DS, Swayze VW, Miller DD, Arndt S, Andreasen NC. Symptom dimensions and brain morphology in schizophrenia and related psychotic disorders. *J Psychiatr Res*. 1995;29:261-276.
13. Dierks T, Linden DE, Jandl M, Formisano E, Goebel R, Lanfermann H, Singer W. Activation of Heschl's gyrus during auditory hallucinations. *Neuron*. 1999;22:615-621.
14. McGuire PK, Shah GM, Murray RM. Increased blood flow in Broca's area during auditory hallucinations in schizophrenia. *Lancet*. 1993;342:703-706.
15. McGuire PK, Silbersweig DA, Wright I, Murray RM, David AS, Frackowiak RS, Frith CD. Abnormal monitoring of inner speech: a physiological basis for auditory hallucinations. *Lancet*. 1995;346:596-600.
16. Shergill SS, Bullmore E, Simmons A, Murray R, McGuire P. Functional anatomy of auditory verbal imagery in schizophrenic patients with auditory hallucinations. *Am J Psychiatry*. 2000;157:1691-1693.
17. Shergill SS, Brammer MJ, Williams SC, Murray RM, McGuire PK. Mapping auditory hallucinations in schizophrenia using functional magnetic resonance imaging. *Arch Gen Psychiatry*. 2000;57:1033-1038.
18. Lennox BR, Park SB, Medley I, Morris PG, Jones PB. The functional anatomy of auditory hallucinations in schizophrenia. *Psychiatry Res*. 2000;100:13-20.
19. Halligan PW, David AS. Cognitive neuropsychiatry: towards a scientific psychopathology. *Nat Rev Neurosci*. 2001;2:209-215.
20. Roland P. Language. In: Roland P, ed. *Brain Activation*. New York, NY: Wiley-Liss; 1993:269-290.
21. Lawrie SM, Buechel C, Whalley HC, Frith CD, Friston KJ, Johnstone EC. Reduced frontotemporal functional connectivity in schizophrenia associated with auditory hallucinations. *Biol Psychiatry*. 2002;51:1008-1011.
22. Ford JM, Mathalon DH, Whitfield S, Faustman WO, Roth WT. Reduced communication between frontal and temporal lobes during talking in schizophrenia. *Biol Psychiatry*. 2002;51:485-492.
23. Andreasen NC. Schizophrenia: the fundamental questions. *Brain Res Brain Res Rev*. 2000;31:106-112.
24. Frith CD, Friston KJ, Herold S, Silbersweig D, Fletcher P, Cahill C, Dolan RJ, Frackowiak RS, Liddle PF. Regional brain activity in chronic schizophrenic patients during the performance of a verbal fluency task. *Br J Psychiatry*. 1995;167:343-349.
25. Liddle PF. Functional imaging—schizophrenia. *Br Med Bull*. 1996;52:486-494.
26. Basser PJ, Mattiello J, LeBihan D. MR diffusion tensor spectroscopy and imaging. *Biophys J*. 1994;66:259-267.
27. Le Bihan D, Mangin JF, Poupon C, Clark CA, Pappata S, Molko N, Chabriat H. Diffusion tensor imaging: concepts and applications. *J Magn Reson Imaging*. 2001;13:534-546.
28. Buchsbaum MS, Tang CY, Peled S, Gudbjartsson H, Lu D, Hazlett EA, Downhill J, Haznedar M, Fallon JH, Atlas SW. MRI white matter diffusion anisotropy and PET metabolic rate in schizophrenia. *Neuroreport*. 1998;9:425-430.
29. Lim KO, Hedehus M, Moseley M, de Crespigny A, Sullivan EV, Pfefferbaum A. Compromised white matter tract integrity in schizophrenia inferred from diffusion tensor imaging. *Arch Gen Psychiatry*. 1999;56:367-374.
30. Foong J, Maier M, Clark CA, Barker GJ, Miller DH, Ron MA. Neuropathological abnormalities of the corpus callosum in schizophrenia: a diffusion tensor imaging study. *J Neurol Neurosurg Psychiatry*. 2000;68:242-244.
31. Agartz I, Andersson JL, Skare S. Abnormal brain white matter in schizophrenia: a diffusion tensor imaging study. *Neuroreport*. 2001;12:2251-2254.
32. Kubicki M, Westin CF, Maier SE, Frumin M, Nestor PG, Salisbury DF, Kikinis R, Jolesz FA, McCarley RW, Shenton ME. Uncinate fasciculus findings in schizophrenia: a magnetic resonance diffusion tensor imaging study. *Am J Psychiatry*. 2002;159:813-820.
33. Wolkin A, Choi SJ, Szilagyi S, Sanfilippo M, Rotrosen JP, Lim KO. Inferior frontal white matter anisotropy and negative symptoms of schizophrenia: a diffusion tensor imaging study. *Am J Psychiatry*. 2003;160:572-574.
34. Burns J, Job D, Bastin ME, Whalley H, Macgillivray T, Johnstone EC, Lawrie SM. Structural disconnectivity in schizophrenia: a diffusion tensor magnetic resonance imaging study. *Br J Psychiatry*. 2003;182:439-443.
35. Steel RM, Bastin ME, McConnell S, Marshall I, Cunningham-Owens DG, Lawrie SM, Johnstone EC, Best JJ. Diffusion tensor imaging (DTI) and proton magnetic resonance spectroscopy (1H MRS) in schizophrenic subjects and normal controls. *Psychiatry Res*. 2001;106:161-170.
36. Foong J, Symms MR, Barker GJ, Maier M, Miller DH, Ron MA. Investigating regional white matter in schizophrenia using diffusion tensor imaging. *Neuroreport*. 2002;13:333-336.
37. Lim KO, Helpman JA. Neuropsychiatric applications of DTI—a review. *NMR Biomed*. 2002;15:587-593.
38. Nieuwenhuys R, Voogd J, van Huijzen C. Lange Assoziationsbahnen und commissurale Verbindungen. In: Nieuwenhuys R, Voogd J, van Huijzen C, eds. *Das zentrale Nervensystem des Menschen*. 2nd ed. Berlin, Germany: Springer-Verlag; 1978:381-392.
39. Bramer GR. International statistical classification of diseases and related health problems: 10th revision. *World Health Stat Q*. 1988;41:32-36.
40. Oulis PG, Mavreas VG, Mamounas JM, Stefanis CN. Clinical characteristics of auditory hallucinations. *Acta Psychiatr Scand*. 1995;92:97-102.
41. Kay SR, Fiszbein A, Opler LA. The Positive and Negative Syndrome Scale (PANSS) for schizophrenia. *Schizophr Bull*. 1987;13:261-276.
42. National Institute for Mental Health. Clinical global impressions. In: Guy W, Bonato R, eds. *Manual for the ECDEU Assessment Battery*. 2nd rev ed. Chevy Chase, Md: National Institute for Mental Health; 1970.
43. Mamata H, Mamata Y, Westin CF, Shenton ME, Kikinis R, Jolesz FA, Maier SE. High-resolution line scan diffusion tensor MR imaging of white matter fiber tract anatomy. *AJNR Am J Neuroradiol*. 2002;23:67-75.
44. Maier SE, Gudbjartsson H, Patz S, Hsu L, Lovblad KO, Edelman RR, Warach S, Jolesz FA. Line scan diffusion imaging: characterization in healthy subjects and stroke patients. *AJR Am J Roentgenol*. 1998;171:85-93.
45. Papadakis NG, Xing D, Houston GC, Smith JM, Smith MI, James MF, Parsons AA, Huang CL, Hall LD, Carpenter TA. A study of rotationally invariant and symmetric indices of diffusion anisotropy. *Magn Reson Imaging*. 1999;17:881-892.
46. Kriegeskorte N, Goebel R. An efficient algorithm for topologically correct segmentation of the cortical sheet in anatomical MR volumes. *Neuroimage*. 2001;14:329-346.
47. Talairach J, Tournoux P. *Co-Planar Stereotaxic Atlas of the Human Brain*. Stuttgart, Germany: Thieme Medical Publishers; 1988.
48. Kraepelin E. *Dementia Praecox*. New York, NY: Churchill Livingstone Inc; 1919.
49. Shenton ME, Dickey CC, Frumin M, McCarley RW. A review of MRI findings in schizophrenia. *Schizophr Res*. 2001;49:1-52.

50. Wernicke C. Zwanzigste Vorlesung. In: Wernicke C, ed. *Grundriss der Psychiatrie in klinischen Vorlesungen*. Leipzig, Germany: Verlag von Georg Thieme; 1900: 201.
51. Catani M, Howard RJ, Pajevic S, Jones DK. Virtual in vivo interactive dissection of white matter fasciculi in the human brain. *Neuroimage*. 2002;17:77-94.
52. Kolb B, Whishaw I. Language. In: *Fundamentals of Human Neuropsychology*. 4th ed. New York, NY: WH Freeman; 1996:387-415.
53. Dong Q, Welsh RC, Chenevert TL, Carlos RC, Maly-Sundgren P, Gomez-Hassan DM, Mukherji SK. Clinical applications of diffusion tensor imaging. *J Magn Reson Imaging*. 2004;19:6-18.
54. Schultz SK, Andreasen NC. Schizophrenia. *Lancet*. 1999;353:1425-1430.
55. Paus T, Zijdenbos A, Worsley K, Collins DL, Blumenthal J, Giedd JN, Rapoport JL, Evans AC. Structural maturation of neural pathways in children and adolescents: in vivo study. *Science*. 1999;283:1908-1911.
56. Gruzelier J. Hemispheric imbalance: syndromes of schizophrenia, premorbid personality, and neurodevelopmental influences. In: Steinhauer S, Gruzelier J, Zubin J, eds. *Handbook of Schizophrenia: Neuropsychology, Psychophysiology and Information Processing, vol. 5*. New York, NY: Elsevier; 1991:599-650.
57. Innocenti GM, Ansermet F, Parnas J. Schizophrenia, neurodevelopment and corpus callosum. *Mol Psychiatry*. 2003;8:261-274.
58. David AS. Callosal transfer in schizophrenia: too much or too little? *J Abnorm Psychol*. 1993;102:573-579.
59. Rossell SL, Shapleske J, Fukuda R, Woodruff PW, Simmons A, David AS. Corpus callosum area and functioning in schizophrenic patients with auditory-verbal hallucinations. *Schizophr Res*. 2001;50:9-17.
60. Allman JM, Hakeem A, Erwin JM, Nimchinsky E, Hof P. The anterior cingulate cortex: the evolution of an interface between emotion and cognition. *Ann N Y Acad Sci*. 2001;935:107-117.
61. Tamminga CA, Vogel M, Gao X, Lahti AC, Holcomb HH. The limbic cortex in schizophrenia: focus on the anterior cingulate. *Brain Res Brain Res Rev*. 2000;31:364-370.
62. Graybiel AM, Rauch SL. Toward a neurobiology of obsessive-compulsive disorder. *Neuron*. 2000;28:343-347.
63. Brody AL, Barsom MW, Bota RG, Saxena S. Prefrontal-subcortical and limbic circuit mediation of major depressive disorder. *Semin Clin Neuropsychiatry*. 2001; 6:102-112.
64. Cleghorn JM, Garnett ES, Nahmias C, Brown GM, Kaplan RD, Szechtman H, Szechtman B, Franco S, Dermer SW, Cook P. Regional brain metabolism during auditory hallucinations in chronic schizophrenia. *Br J Psychiatry*. 1990;157:562-570.
65. Silbersweig DA, Stern E, Frith C, Cahill C, Holmes A, Grootoonk S, Seaward J, McKenna P, Chua SE, Schnorr L, Jones T, Frackowiak RSJ. A functional neuroanatomy of hallucinations in schizophrenia. *Nature*. 1995;378:176-179.
66. Lennox BR, Park SB, Jones PB, Morris PG, Park G. Spatial and temporal mapping of neural activity associated with auditory hallucinations. *Lancet*. 1999;353: 644.
67. Copolov DL, Seal ML, Maruff P, Ulusoy R, Wong MT, Tochon-Danguy HJ, Egan GF. Cortical activation associated with the experience of auditory hallucinations and perception of human speech in schizophrenia: a PET correlation study. *Psychiatry Res*. 2003;122:139-152.

### Correction

**Error in Reference and Page Numbers.** In the "Art and Images in Psychiatry" article titled "Agony," published in the April issue of the ARCHIVES (2004;61: 334), a reference and page number were incorrect. In the last paragraph, line 9, the numbers should have been reference 6 (Herrera), page 586. We regret the error.