

Whole-Brain Morphometric Study of Schizophrenia Revealing a Spatially Complex Set of Focal Abnormalities

Christos Davatzikos, PhD; Dinggang Shen, PhD; Ruben C. Gur, PhD; Xiaoying Wu, MS; Dengfeng Liu, MS; Yong Fan, PhD; Paul Huggett, PhD; Bruce I. Turetsky, MD; Raquel E. Gur, MD, PhD

Context: Neuroanatomic abnormalities in schizophrenia may underlie behavioral manifestations. Characterization of such abnormalities is required for interpreting functional data. Frontotemporal abnormalities have been documented by using predetermined region-of-interest approaches, but deformation-based morphometry permits examination of the entire brain.

Objectives: To perform whole-brain analyses of structural differences between patients with schizophrenia and controls, to examine sex and medication effects, and to apply a high-dimensional nonlinear pattern classification technique to quantify the degree of separation between patients and controls, thereby testing the potential of this new technique as an aid to diagnostic procedures.

Design: Whole-brain morphologic analysis using high-dimensional shape transformations.

Setting: Schizophrenia Research Center, University of Pennsylvania Medical Center.

Participants: Neuroleptic-naïve and previously treated patients with *DSM-IV* schizophrenia (n=69) and socio-demographically matched controls (n=79).

Main Outcome Measures: Gray matter, white matter, and ventricular cerebrospinal fluid volumes in the brain.

Results: Magnetic resonance images showed reduced gray matter and increased ventricular cerebrospinal fluid volumes in patients with schizophrenia in the whole brain and in specific foci: the hippocampus and adjacent white matter, the cingulate and orbitofrontal cortex, the frontotemporal and parietotemporal areas, and the occipital areas near the lingual gyrus. The classifier had a mean classification accuracy of 81.1% for men and women combined (82% for women and 85% for men, when each group was treated separately), determined via cross-validation.

Conclusions: This study confirms previous findings of reduced frontotemporal volumes and suggests new hypotheses, especially involving occipital association and speech production areas. It also suggests finer localization of volume reduction in the hippocampus and other limbic structures and in the frontal lobe. Pattern classification showed high sensitivity and specificity for the diagnosis of schizophrenia, suggesting the potential utility of magnetic resonance imaging as a diagnostic aid.

Arch Gen Psychiatry. 2005;62:1218-1227

Author Affiliations: Section of Biomedical Image Analysis, Department of Radiology (Drs Davatzikos, Shen, and Fan, Ms Wu, and Mr Liu) and Brain Behavior Laboratory and Schizophrenia Research Center, Department of Psychiatry (Drs Huggett, Turetsky, R. C. Gur, and R. E. Gur), University of Pennsylvania Medical Center, Philadelphia.

UNDERSTANDING NEURAL substrates of schizophrenia requires determination of the extent and distribution of abnormalities in brain anatomy. Neuroanatomic studies using magnetic resonance imaging (MRI) have documented reductions in parenchymal volume that appeared to be specific to gray matter (GM) accompanied by proportionate increases in ventricular cerebrospinal fluid (CSF) volume.¹⁻⁴ Quantitation of regional abnormalities is more demanding because reliable expert-based delineation is labor intensive and is limited to a priori regions of interest

(ROIs). Because symptoms and neurocognitive deficits of schizophrenia implicate frontotemporal dysfunction, most expert-guided ROI studies have focused on these areas, although subcortical regions, including the hippocampus and basal ganglia, have also been examined.¹⁻⁴

Automated methods for regional parcellation and voxel-based morphometry can efficiently yield information on the entire brain, thereby permitting the validation of current findings and the discovery of regions not previously implicated.^{5,6} Previous voxel-based morphometry studies⁷⁻¹⁶ have generally supported the ROI-guided findings in demonstrating tissue re-

PARTICIPANTS

duction in frontotemporal regions and revealing abnormalities in the volume or shape of specific regions, such as the thalamus¹⁷ and the hippocampus.¹⁸ More regionally specific methods that use high-dimensional transformations^{11,13,19,20} can be coupled with pattern classification methods that use shape measurements to distinguish patients with schizophrenia from controls.²¹⁻²³ An important step in validating automated techniques is their comparison with the ROI approach, and several studies^{9,13,24,25} reported similar findings within samples.

The main challenge for automated processing lies in the large variability among individuals, particularly in sulci and gyri. Voxel deformation- or tensor-based morphometric approaches to computational anatomy perform a spatial transformation that places images into a stereotaxic space. This is followed by a voxel-wise statistical analysis of the spatial distribution of tissue compartments,²⁶ the properties of the spatial transformation,^{20,27} or combined measurements of the residual image and the spatial transformation.²⁸ Because these methods examine each voxel separately, not all voxels jointly, they constitute “mass univariate” and not multivariate approaches. This can result in biased interpretations of the data and in overlooking interactions among different brain regions.²⁹ Such interrelations can help separate 2 or more populations and may predict whether an individual is at risk for a brain disorder.

The goal of the present study is to apply automated image analysis based on deformation morphometry to a sample of well-characterized patients with schizophrenia and matched controls. The morphometric protocol has been integrated and validated on an aging population.³⁰ After automated segmentation, mass-preserving shape transformations warp individual images into a template, and the total amount of tissue in any region is preserved for subsequent analysis.^{28,31,32} A classifier is then applied by forming a morphologic signature of the individual brain via the high-dimensional shape transformation.^{33,34}

Previous studies on this sample used the ROI approach and identified globally reduced GM and increased ventricular CSF volumes in patients.³⁵ Regional effects showed reduced frontal,³⁶ temporolimbic,³⁷ and thalamic³⁸ volumes and increased basal ganglia volumes in previously treated compared with neuroleptic-naïve patients.³⁸ Sex differences were observed. Women with schizophrenia showed increased amygdala volume and reduced orbitofrontal volume compared with healthy women, whereas men with schizophrenia had reduced amygdala volume and normal orbitofrontal volume relative to healthy men.³⁷ By applying the present method to the same sample we can evaluate its sensitivity to effects established using the expert-guided ROIs. Because the sample includes never-treated and previously treated patients, we can assess the effects of medication, which will help gauge the confidence we can place in new potential findings. We also sought to determine whether a feature classifier based on the morphometric parameters could reliably separate participants with schizophrenia from healthy people.

Sixty-nine patients (46 men and 23 women) with schizophrenia and 79 controls (41 men and 38 women) participated in the study. All the participants were right-handed, and all the women were premenopausal. The mean \pm SD values of sociodemographic variables did not differ in patients with schizophrenia vs controls: age, 29.9 \pm 8.4 years vs 28.2 \pm 7.5 years ($t_{146} = 1.34$; $P = .18$), and parental education, 13.9 \pm 3.8 years vs 14.5 \pm 3.5 years ($t_{146} = 1.05$; $P = .30$). As expected, patients with schizophrenia attained lower mean \pm SD education levels than controls (13.5 \pm 2.6 vs 15.8 \pm 2.2 years; $t_{149} = 6.01$; $P < .001$). Participants were recruited and assessed at the Schizophrenia Research Center, University of Pennsylvania Medical Center, and they underwent medical, neurologic, and psychiatric evaluations to exclude for a history of illness that affects brain function, including substance abuse, hypertension, metabolic disorders, neurologic disorders, and head trauma with loss of consciousness.³⁹ For patients, the comprehensive intake evaluation included a structured diagnostic interview⁴⁰ and a review of medical records and information available from family and care providers that contributed to a consensus diagnosis of schizophrenia.⁴¹ The clinical examination included an assessment of symptoms and function, and it was performed by trained and reliable (interclass correlation coefficient >0.90) investigators.³⁹ Patients had mild-to-moderate symptoms at the time of study as evaluated using the Brief Psychiatric Rating Scale⁴² (mean \pm SD score, 36.7 \pm 10.8), the *Scale for the Assessment of Negative Symptoms*⁴³ (1.7 \pm 1.1), and the *Scale for the Assessment of Positive Symptoms*⁴⁴ (1.5 \pm 0.9). Onset of illness was defined as the emergence of symptoms in the context of functional decline. Level of functioning was assessed using the Premorbid Adjustment Scale⁴⁵ and the Quality of Life Scale.⁴⁶ Mean \pm SD duration of illness, defined as age at study entry minus age at symptom onset, was 5.6 \pm 6.3 years. At study entry, 32 patients were first-episode neuroleptic naïve and 37 were treated with antipsychotic medications. The 2 groups did not differ in education (13.5 \pm 2.9 years vs 13.7 \pm 2.4 years; $t_{67} = 0.37$; $P = .71$), parental education (13.8 \pm 3.6 years vs 14.4 \pm 3.8 years; $t_{67} = 0.76$; $P = .45$), Brief Psychiatric Rating Scale score (38.5 \pm 10.7 vs 35.9 \pm 10.7; $t_{67} = 1.34$; $P = .18$), *Scale for the Assessment of Negative Symptoms* score (1.8 \pm 1.1 vs 1.6 \pm 1.1; $t_{67} = 1.77$; $P = .08$), *Scale for the Assessment of Positive Symptoms* score (1.5 \pm 0.8 vs 1.6 \pm 1.0; $t_{67} = 0.94$; $P = .35$), Quality of Life Scale score (3.2 \pm 1.1 vs 2.9 \pm 1.3; $t_{67} = 1.01$; $P = .38$), or Premorbid Adjustment Scale score (2.0 \pm 1.1 vs 1.9 \pm 1.1; $t_{67} = 0.35$; $P = .73$), but, as expected, first-episode patients were younger (26.3 \pm 6.8 years vs 30.8 \pm 6.7 years; $t_{67} = 2.60$; $P = .009$) and had a shorter duration of illness (2.0 \pm 3.2 years vs 8.6 \pm 6.3 years; $t_{67} = 5.24$; $P < .001$). Men with schizophrenia did not differ from women with schizophrenia on any of these measures: education (13.5 \pm 2.8 years vs 13.8 \pm 2.5 years; $t_{67} = 0.33$; $P = .75$), parental education (14.3 \pm 3.8 years vs 13.5 \pm 3.5 years; $t_{67} = 0.58$; $P = .56$), Brief Psychiatric Rating Scale score (38.4 \pm 10.8 vs 34.4 \pm 10.2; $t_{67} = 0.93$; $P = .34$), *Scale for the Assessment of Negative Symptoms* score (1.9 \pm 1.1 vs 1.3 \pm 0.8; $t_{67} = 1.01$; $P = .32$), *Scale for the Assessment of Positive Symptoms* score (1.6 \pm 0.9 vs 1.3 \pm 1.0; $t_{67} = 0.49$; $P = .62$), Quality of Life Scale score (2.9 \pm 1.2 vs 3.4 \pm 1.2; $t_{67} = 1.36$; $P = .18$), Premorbid Adjustment Scale score (2.0 \pm 1.1 vs 1.7 \pm 1.0; $t_{67} = 1.06$; $P = .29$), age (27.7 \pm 7.2 years vs 30.8 \pm 6.2 years; $t_{67} = 1.60$; $P = .11$), and duration of illness (5.3 \pm 6.1 years vs 4.6 \pm 5.5 years; $t_{67} = 0.42$; $P = .67$).

Controls underwent the *Structured Clinical Interview for DSM-IV Axis I Disorders, Non-Patient Edition*,⁴⁷ and reported no first-degree relatives with schizophrenia or affective illness. The sample overlaps with samples reported in earlier publications.³⁶⁻³⁸ The current data set includes all patients with schizophrenia and demographically matched controls who have been studied using

Table 1. Global Volumetric Measurements for Gray Matter, White Matter, and Ventricular CSF*

	Whole Sample								Men			Women		
	Controls	SCZ	FE	PT	<i>P</i> Value†	<i>P</i> Value‡	<i>P</i> Value§	<i>P</i> Value	Controls	SCZ	<i>P</i> Value	Controls	SCZ	<i>P</i> Value
GM	553 ± 58	519 ± 56	521 ± 57	517 ± 56	<.001	.005	<.001	.36	569 ± 60	541 ± 42	.006	537 ± 53	475 ± 57	<.001
WM	447 ± 59	439 ± 56	435 ± 44	443 ± 65	.20	.15	.35	.29	469 ± 59	456 ± 47	.11	423 ± 49	406 ± 58	.12
CSF	16 ± 7	20 ± 8	19 ± 8	20 ± 7	<.001	.01	<.001	.23	17 ± 7	19 ± 7	.05	14 ± 6	20 ± 8.5	.001

Abbreviations: CSF, ventricular cerebrospinal fluid; FE, first episode; GM, gray matter; PT, previously treated; SCZ, patients with schizophrenia; WM, white matter.

*Data are given as mean ± SD in cubic centimeters.

†Controls vs SCZ.

‡Controls vs FE.

§Controls vs PT.

||FE vs PT.

Table 2. Summary of the Results Obtained by Voxel-Wise Statistical Analysis of the RAVENS Maps of Controls and Patients With Schizophrenia

Structure	<i>P</i> Value*
Frontal gyri	
Superior frontal gyrus right	.002
Inferior frontal gyrus left and right	.004
Lateral fronto-orbital gyrus left	.001
Temporal gyri	
Superior temporal gyrus left	.001
Middle temporal gyrus left	.002
Inferior temporal gyrus left	.002
Insula left	.001
Lateral occipitotemporal gyrus right	.001
Parietal gyri	
Angular gyrus left and right	.002 (left)/.001 (right)
Supramarginal gyrus left	.001
Occipital gyri	
Lingual gyrus left	.001
Middle occipital gyrus right	.001
Limbic	
Hippocampal formation left and right	.003 (left)/.001 (right)
Cingulate region left and right	.001
White matter	
Temporal lobe right (close to hippocampus right)	.02
Vicinity of lingual gyrus left	.046

*The *P* values of the *t* statistic after statistical parametric mapping correction for multiple comparisons are shown (only regions with significance at *P* < .05, after correction).

the same scanner with the same protocol and who had suitable quality of scan for automated analysis of the entire supertentorial brain. Some studies using spoiled gradient recalled acquisition in the steady state (GRASS) MRI included larger samples because they involved regions unaffected by “ghosting” artifacts that precluded whole-brain analysis. The study was approved by the University of Pennsylvania institutional review board and was performed after written informed consent was obtained.

MRI ACQUISITION AND ANALYSIS

T1-weighted images were obtained using a 1.5-T scanner (1.5T Signa; General Electric Medical Systems, Milwaukee, Wis) using spoiled GRASS pulse sequence (flip angle, 35°; repetition time, 35 milliseconds; echo time, 6 milliseconds; field of view, 24 cm; and NEX 1, 1-mm section thickness and no intersection gaps).

In-plane resolution was 0.9375 × 0.9375 mm. No parenchymal lesions or skull abnormalities were evident neuroradiologically.

Images were analyzed via a deformation-based morphometric analysis protocol as previously detailed,^{27,28,31,32,34} which included skull stripping; tissue classification into GM, white matter (WM), and ventricular CSF; and spatial normalization to a standardized stereotactic space, a step necessary for group analysis, using a high-dimensional elastic spatial normalization transformation.^{33,34} Three tissue density (RAVENS³² [Regional Analysis of Volumes Examined in Normalized Space]) maps were generated, 1 for each tissue type, reflecting the regional amount of the respective tissues in the vicinity of each voxel.

STATISTICAL ANALYSIS

Spatially normalized RAVENS maps of patients and controls and of subgroups (men and women and neuroleptic-naïve and treated patients) were compared statistically using voxel-wise *t* tests and voxel-wise effect sizes after spatial smoothing with a Gaussian filter of full-width half-maximum equal to 8 mm. Correction for multiple comparisons was performed using the methods embedded in the statistical parametric mapping software.⁴⁸ Only the clusters that exceeded a significance threshold of *P* < .05 after correction for multiple comparisons are reported.

MRI-BASED DIAGNOSIS VIA PATTERN CLASSIFICATION

In addition to RAVENS maps, we applied a pattern classification method to examine whether the morphologic profiles measured using the RAVENS density maps can be used to separate patients with schizophrenia from controls. This approach considers all brain voxels jointly in a high-dimensional space rather than examining each brain region individually.⁴⁹ Although in each brain region there could be considerable overlap between control and schizophrenia, thereby leading to poor diagnostic accuracy, a nonlinear multivariate analysis of all brain regions simultaneously could separate the 2 groups with higher classification sensitivity. We used the jackknife (leave-1-out) method, that is, we trained the classifier on all but 1 patient and tested it on the (independent) left out sample for robust estimation of performance.

RESULTS

TOTAL BRAIN TISSUE VOLUMES

The mean ± SD global volumes for GM, WM, and ventricular CSF are given in **Table 1**. Patients with schizo-

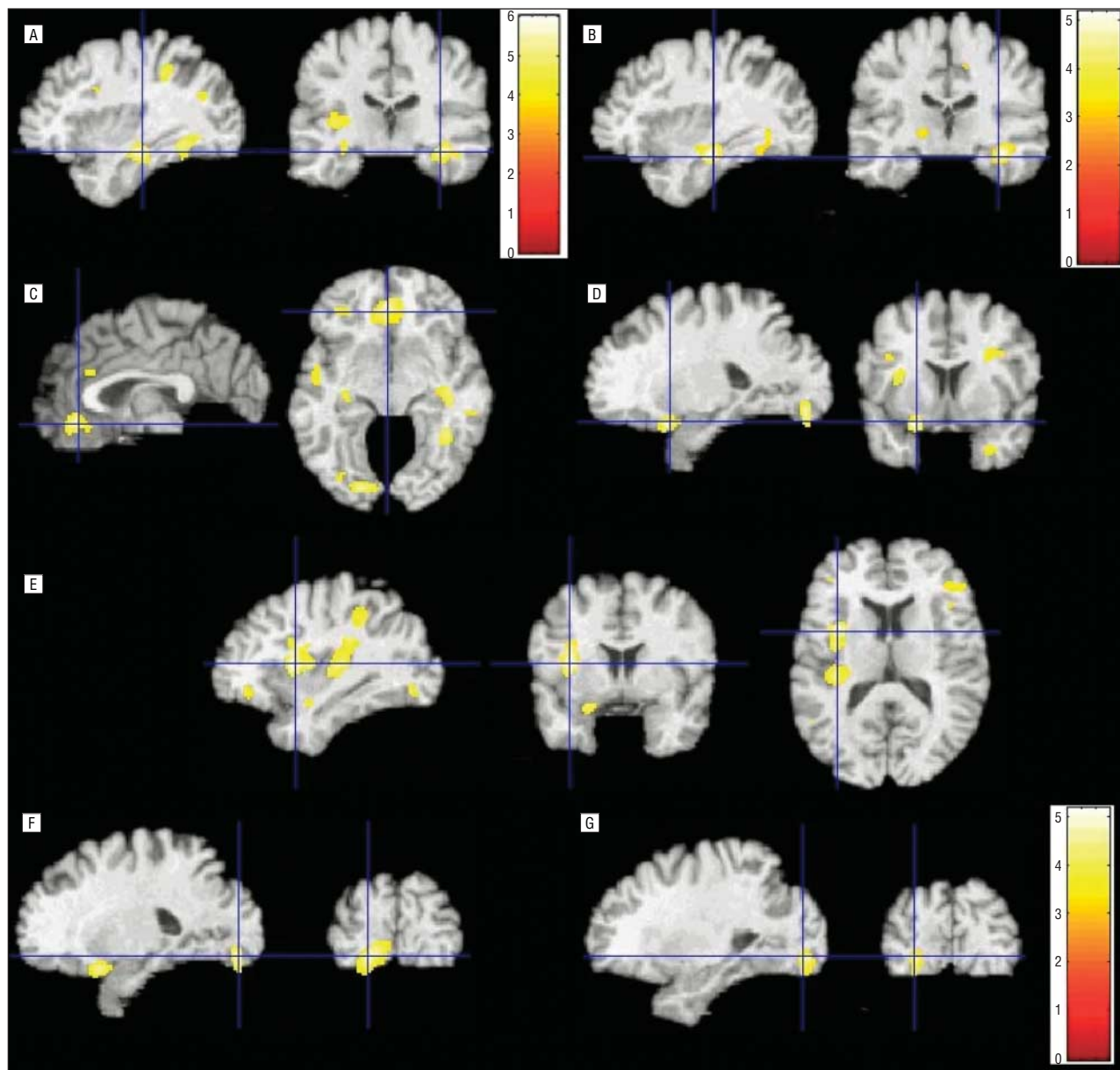


Figure 1. Regions with reduced gray matter (GM) or white matter (WM) volume. A, Hippocampal GM. B, Hippocampal WM. C, Cingulate gyrus GM. D, Orbitofrontal gyrus GM. E, Insula GM. F, Lingual gyrus/Brodmann areas 18 and 19 GM. G, Lingual gyrus/Brodmann areas 18 and 19 WM. Color-coding is according to the scale in A, except for B and G. Images are displayed in neurologic convention (left hemisphere on viewer's left).

phrenia showed significantly lower GM and higher ventricular CSF volumes, whereas the WM total volume difference was not significant between the 2 groups. For patients, GM, WM, and ventricular CSF volumes did not correlate with duration of illness ($r=-0.29$, -0.17 , and 0.12), mean *Scale for the Assessment of Negative Symptoms* scores ($r=0.20$, 0.01 , and -0.24), or mean *Scale for the Assessment of Positive Symptoms* scores ($r=0.05$, -0.07 , and -0.26).

LOCAL VOLUMETRIC MEASUREMENTS

Voxel-based statistical analysis of the RAVENS maps revealed a spatially complex pattern of volumetric differences between groups. The volume reduction in

patients was not diffuse, with several foci of abnormality evident. The abnormalities were primarily in prefrontal and temporal regions, but other areas also showed significant differences. **Table 2** summarizes the regions in which the peaks of the local clusters were located and their associated P values after correction for multiple comparisons. Unlike GM, WM did not show any significant group difference. The only peaks that approached significance were in the WM adjacent to the right hippocampus ($P=.02$) and the left lingual gyrus ($P=.046$). Both regions also showed a significant difference in GM volume.

Figure 1 depicts several representative images with overlays of color-coded clusters of significant group differences and the underlying template used for spatial nor-

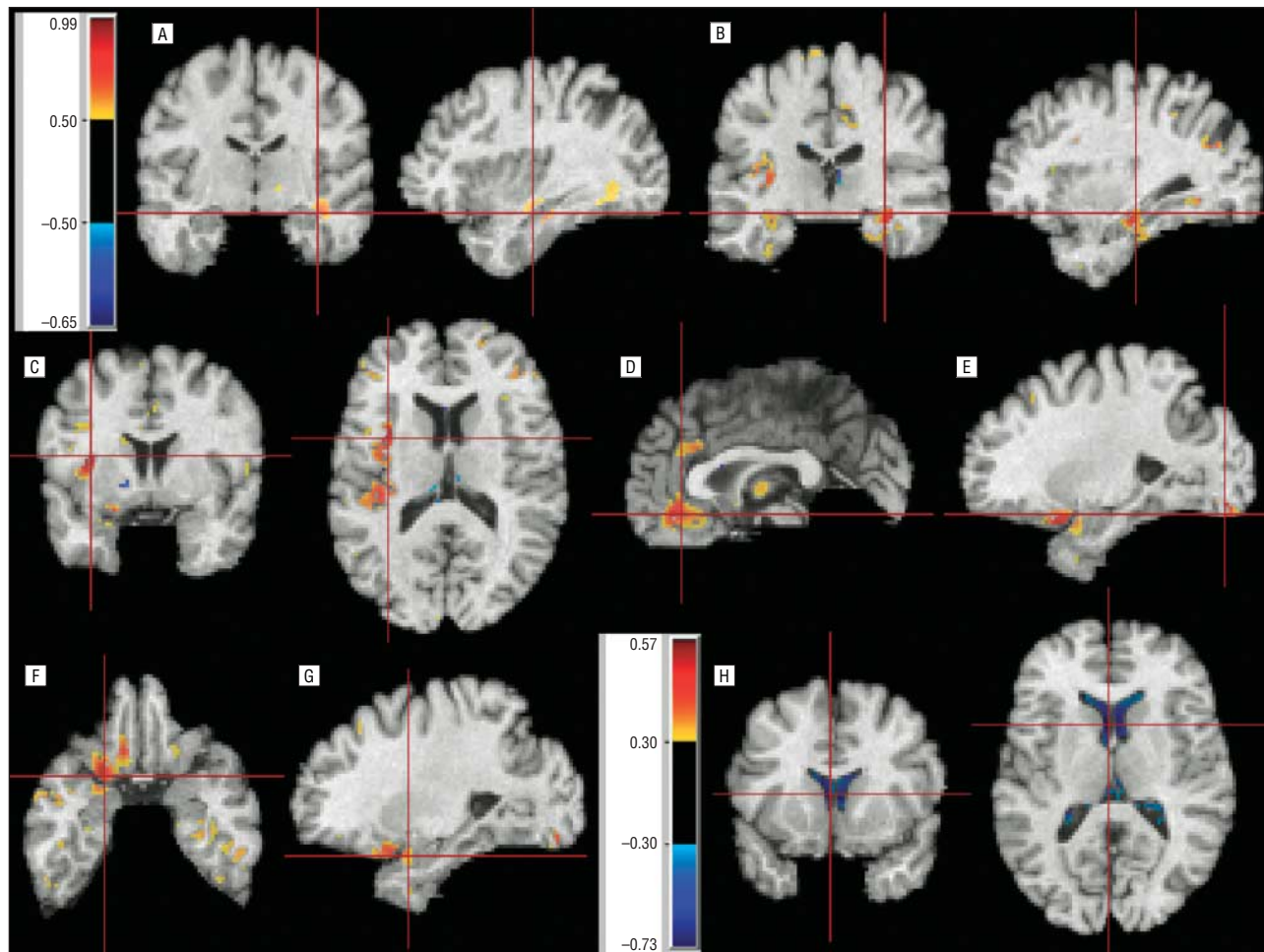


Figure 2. Effect size maps for the entire sample. A, Right hippocampal white matter (WM). B, Right hippocampal gray matter (GM). C, Left insula GM. D, Cingulate gyrus GM. E, Left lingual gyrus GM. F, Left orbitofrontal gyrus. G, Left amygdala and orbitofrontal GM. H, Ventricular cerebrospinal fluid. The color bar in A applies to all maps, except for the one in H. Images are displayed in neurologic convention.

malization. Color-coding is based on the values of the t statistic. Only voxels with significant group differences are shown overlaid on the template.

Examination of effect sizes for the entire sample (**Figure 2**) shows local maxima in regions of statistical significance and also demonstrates the expansion in ventricular CSF (Figure 2H). Noticeable is the enlargement of the anterior compared with the posterior ventricles. The statistical parametric mapping global analysis did not show any significant effects of the moderator variables because there were no sex \times region or diagnosis \times sex \times region interactions, and neither were there significant interactions when neuroleptic-naïve and previously treated patients were contrasted. Thus, overall volume differences between patients and controls are not entirely moderated by these factors. However, evaluation of the effect sizes in patients separated by sex (**Figure 3**) and medication (**Figure 4**) suggested that such factors are worthy of further examination with larger samples. Specifically, women with schizophrenia displayed higher effect size magnitudes compared with men. The statistical significance of this difference seems to have been attenuated by the smaller sample size of female patients. The spatial pattern of the group differences was similar between men and women. However, reduced or-

bit volume seemed more pronounced and extended in women, whereas reduced amygdala volume was more pronounced in men.

Comparing neuroleptic-naïve with previously treated patients likewise showed a similar pattern in both groups (Figure 4). However, the basal ganglia had negative signs, indicating expansion in patients relative to controls, and this effect was more pronounced in treated than in untreated patients. The effect sizes of the treated patients were similar albeit of higher magnitude.

To ensure that our accuracy was not adversely affected by registration errors, we formed the average of all 148 spatially normalized images after they were warped to the template. This method is used for visually evaluating the accuracy of the template warping method because residual variability caused by error in the warping mechanism produces fuzziness of the resultant average images. The clarity of the mean in Figure 3D reflects the high accuracy of the underlying template warping procedure and, therefore, of our morphologic measurements.

In addition to the cross-sectional views of the effect sizes in Figure 2 and Figure 3, we also formed 3-dimensional renditions of the effect sizes of the combined group, as shown in Figure 3C, which projects the average effect

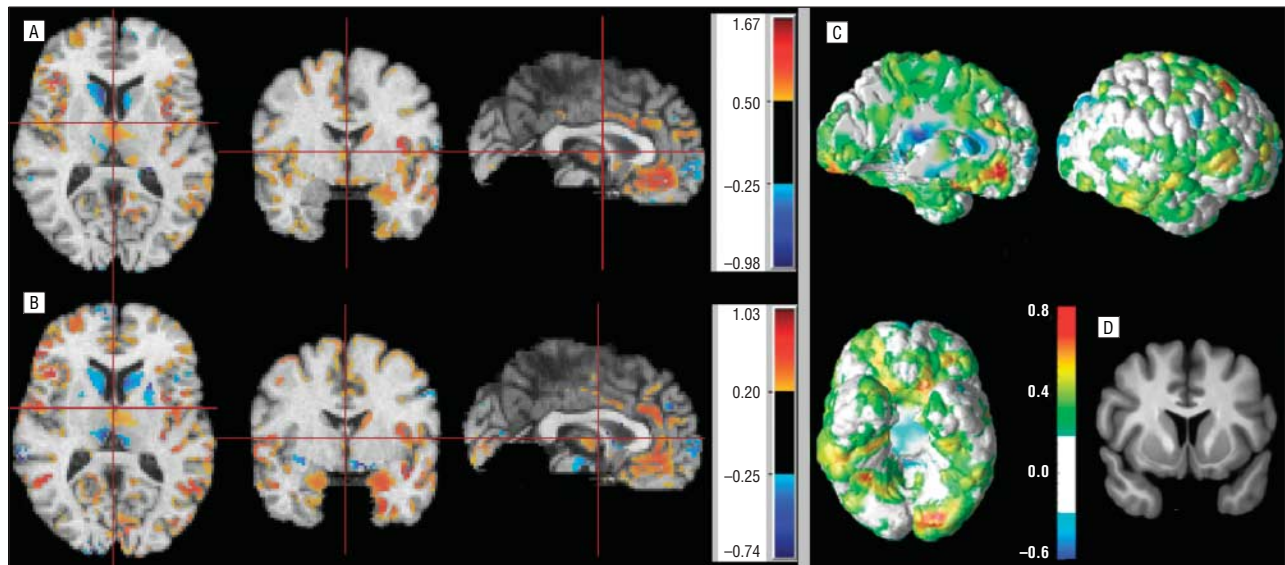


Figure 3. Effect size maps for patients with schizophrenia vs controls. Effect size maps for women (A) and men (B) displayed in neurologic convention. C, Effect size maps for men and women combined projected on the outer cortical surface. D, Mean of the 148 images after they were spatially normalized via elastic warping to the template.

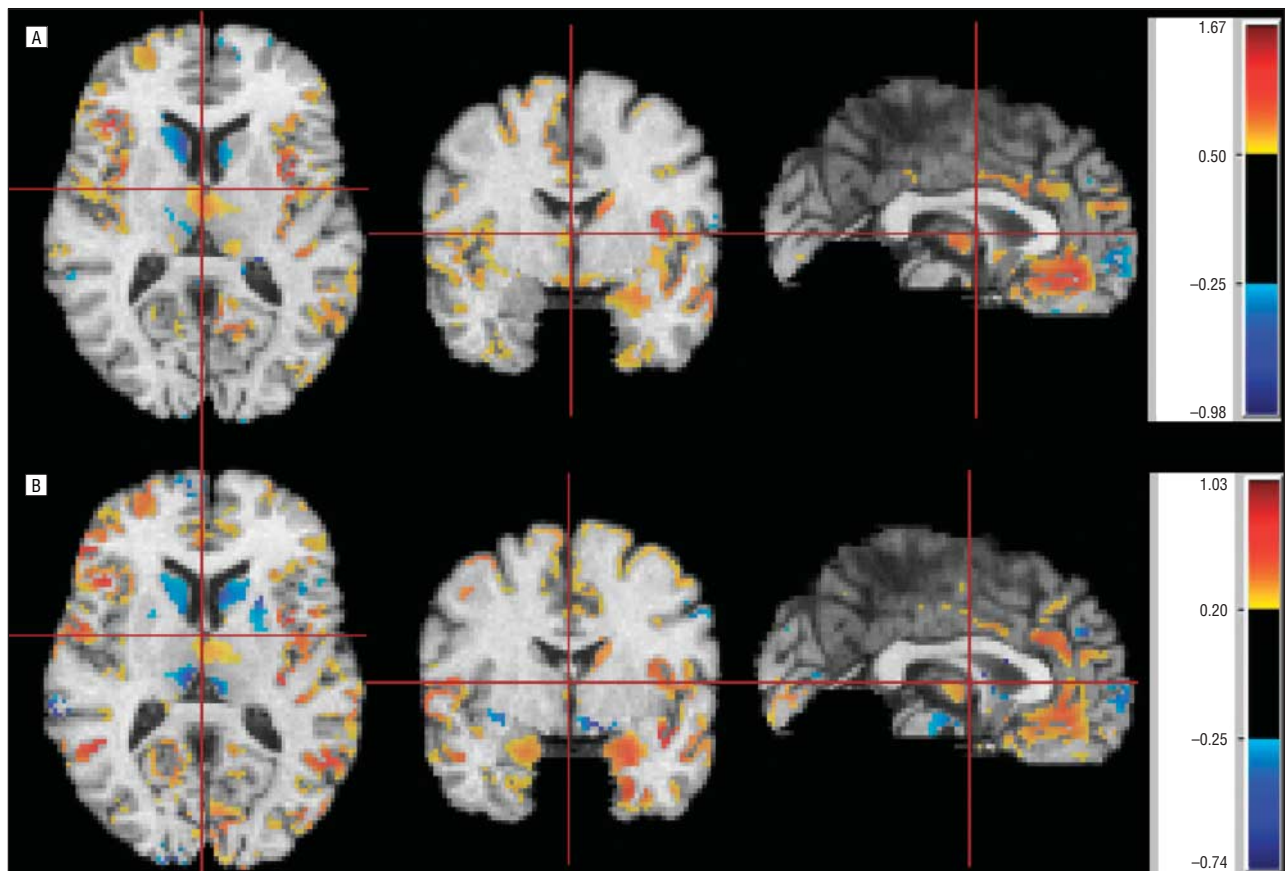


Figure 4. Effect size maps for control vs patient group difference calculated separately for neuroleptic-naïve patients (A) and treated patients (B). Treated patients showed a pronounced increase in basal ganglia volumes (blue). Images are displayed in neurologic convention.

size maps of Figure 2 within a neighborhood around the outer cortical surface of the template onto this surface. This map is informative because it summarizes the spatial pattern of volumetric findings and highlights the vulnerability of inferior temporal, occipitotemporal, and or-

bitofrontal regions. However, it is only complementary to Figure 2 because it shows only relatively superficial findings (within 8 mm of the outer cortex). Moreover, it significantly reduces the peak effect sizes by averaging within a spherical neighborhood with a radius of 8 mm.

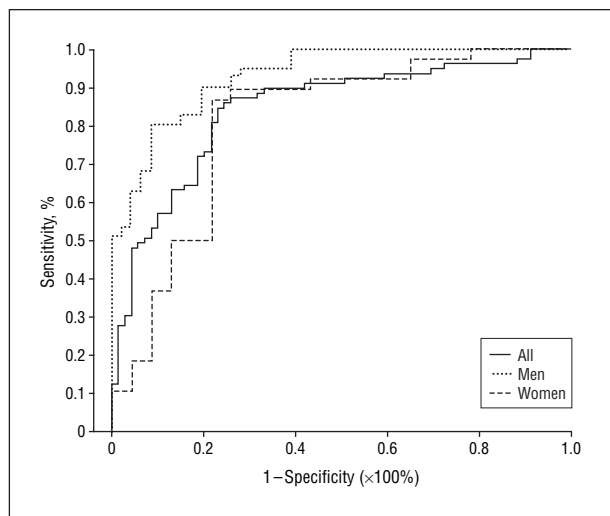


Figure 5. Receiver operating characteristic curves for the 3 classifiers: all participants, men only, and women only.

MRI-BASED PATIENT CLASSIFICATION ACCURACY

The nonlinear classification method achieved 100% fitting accuracy when applied on the training set. We obtained an estimate of how well the classifier would generalize to new patients by using the jackknife technique. The classification accuracy was 81.1% (87.3% specificity and 73.9% sensitivity) for the classifier combining men and women. Accuracy for the individual male and female classifiers was 85.0% (78.0% specificity and 91.0% sensitivity) and 82.0% (86.9% specificity and 73.9% sensitivity), respectively. Sensitivity reflects the probability of disease detection, and specificity reflects the probability of correct classification of controls.

To test the statistical significance of the classification result, we performed random permutation tests. In particular, we performed 8 random assignments of all participants to patient or control categories, then performed the leave-1-out procedure. This resulted in a total of $8 \times 148 = 1184$ classifiers and testing images. The cumulative distribution of the classification accuracy showed that most trials yielded performance similar to that of a coin toss, as would be expected. The mean \pm SD of the classification accuracy of these random assignment experiments was $49.0\% \pm 6.5\%$ (which yielded a significance value of the classification results [$P < .001$]), which is extremely low and bolsters our confidence in the results. Finally, we performed an receiver operating characteristic curve analysis (the varying parameter was the decision threshold of the classifier) for each of the 3 classifiers (**Figure 5**).

COMMENT

The present study applied an automated and accurate protocol for whole-brain and regional morphometric analysis using measured deformation patterns for automated diagnostic classification. Although measures for whole-brain volumes were not directly comparable with earlier studies that used dual-echo images for segmenta-

tion,³⁵ the differences between patients and controls are of comparable magnitude. For example, whole-brain GM in the present study showed an approximately 7% reduction in schizophrenia compared with approximately 6% in the larger sample using dual-echo images. White matter volume did not show significant differences in either study, whereas ventricular CSF volume showed an increase of approximately 20% in both studies and was almost double in women compared with men with schizophrenia. These changes are also consistent with those reported in the meta-analysis by Wright et al,⁴ albeit on the high end of the 90% confidence interval. Because meta-analyses necessarily include studies with different rigor of diagnostic procedures, the larger effect size we observe could be a result of careful screening of patients and controls. Another possible discrepancy with earlier studies on whole-brain changes is our observation that women show larger effect sizes. Although this observation is consistent with the earlier study³⁵ using dual-echo MRI, it is inconsistent with another study⁵⁰ that reported less ventricular increase in women. This issue merits further scrutiny in future studies.

The regional effects, likewise, were consistent with the ROI-based analysis. Thus, the lower volume in superior and inferior temporal gyri and in the hippocampus was evident in the ROI analysis.³⁷ Furthermore, the amygdala did not show reduced volume for the total sample with either method. The frontal lobe effects are more difficult to compare because the ROIs we used were major subdivisions (lateral, medial, dorsal, and orbital).³⁶ However, the location of the significant reduction in the superior and inferior frontal regions in the present study is in the dorsal and medial regions that showed significant reduction in the ROI study. Overall, for the frontotemporal regions, the present analysis yielded findings consistent with our previous studies and with the literature on ROI-based approaches.¹⁻⁴ Other voxel-based studies have reported reduced cortical volume in schizophrenia in the ventral and medial prefrontal regions⁷; the orbitofrontal, superotemporal, and occipitotemporal regions⁹; the right medial frontal lobe; the left midtemporal gyrus²⁵; and the left superior temporal gyrus.^{10,13} All the temporal regions that showed clusters of reduced volume had the peak reduction on the left except for the lateral occipitotemporal gyrus, with a right hemispheric peak, and the hippocampus, with bilateral volume reduction. This is consistent with other findings that support the hypothesis of left temporal lobe dysfunction in schizophrenia.^{1-4,10,12,37}

Regarding subcortical regions, the automated approach did not detect the reduced thalamic volume previously reported using ROI methods³⁸ and automated methods.^{8,17,51} Measurements of subcortical structures may require a different tissue classification technique because subcortical structures, especially the thalamus, have MRI signal characteristics that place them between GM and WM. Incorporation of fuzzy classification methods may help address this problem. Other voxel-based studies^{9,51} have observed reduced thalamic volume.

Examining potential moderators yielded results that were likewise consistent with findings using the ROI approach. Larger effect sizes for women were observed in

frontal³⁸ and temporal³⁷ comparisons, and we also reported reduced orbitofrontal volume relative to amygdala volume in women compared with men with schizophrenia.⁵² The contrast between neuroleptic-naïve and previously treated patients revealed the increased volume of basal ganglia associated with treatment, as previously reported using the ROI approach.^{38,53,54}

In addition to generally supporting earlier findings, our voxel-based analysis showed that in the affected structures, abnormalities were quite focal. We speculate that the clusters seem associated with 3 networks: the temporolimbic and fronto-orbital network, involved in regulating emotion⁵⁵; the frontotemporal network for episodic memory⁵⁶; and the prefrontal-cingulate network, which regulates rule-controlled action.⁵⁷ All these networks are implicated in schizophrenia.^{52,58-60} The method permitted more precise pinpointing of the abnormalities. For example, the reduced hippocampal volume was localized in the middle to posterior hippocampus and medially (Figure 1A). Moreover, reduced volume of the adjacent WM of the parahippocampal gyrus (particularly around the subiculum) was measured at exactly the same level along the anteroposterior direction (Figure 1B). In conjunction with the focal volumetric reduction of the cingulate genu, this might imply disruption of neuronal bodies and respective axons in parts of the medial limbic system, implicated in emotion-processing deficits of schizophrenia.^{52,58} A set of foci of volumetric decrease also involved the medial orbitofrontal and adjacent cingulate cortex (Figure 1C) and the dorsomedial thalamus. These areas complement the limbic system in modulating affective and motivational aspects of behavior.⁵⁵

A distinct set of clusters of volume reduction was evident in the frontotemporal cortex. There was focal reduction in the middle superior aspect of the superotemporal gyrus (Figure 1E) and prominent clusters in the areas of Broca and Wernicke. For the Wernicke area, there was an asymmetry in the abnormality pattern, with only the left hemisphere displaying widespread and significant volumetric differences. These regions, mediating language and auditory processing, have been studied extensively, and abnormalities have been related to electrophysiologic and neurocognitive deficits.⁶¹ Finally, the inferior frontal gyrus displayed bilateral decrease in patients with schizophrenia, although the extent was relatively small (Figure 1E). Some studies^{1,3,4,36,59} reported dorsolateral frontal volume reduction. However, previous studies partitioned the frontal lobe into relatively larger structures, which limits the spatial localization of the measured effects. Although abnormalities in left hemispheric parietal receptive language areas have been reported,^{37,61-64} supporting the hypothesis of left hemispheric dysfunction in schizophrenia, speech production regions have received less attention, but we found them to be equally affected.

Thus, it seems that the automated method for segmentation and parcellation is about as sensitive as the ROI approach to neuroanatomic changes associated with schizophrenia and effects of moderators. Therefore, examination of new regions of neuroanatomic differences revealed by this method has merit. A notable new area of abnormality is in the inferior occipital region, where substantial vol-

ume reduction was observed, with a broad spatial extent (Figure 1F and G). This cluster seems to be primarily located in the lingual gyrus, although it is unclear exactly which occipital area is affected. We place the cluster in Brodmann areas 18 and 19, regions involved in visual association and orientation.^{65,66} Although the visual system has been considered to be generally intact in schizophrenia, our anatomical findings suggest further investigation. Deficits in the visual-processing cascade may underlie downstream dysfunction in more complex operations that require visual input.

Differences between patients and controls were observed almost exclusively in GM and ventricles. The only WM regions in which group differences reached marginal significance were close to the right hippocampus and the left occipital area, where GM volume was also reduced. Although we did not find that women have a significantly larger corpus callosum, as has been reported in earlier studies,⁶⁷ there was a trend for women to have higher volume in the splenium of the callosum, which did not survive correction for multiple comparisons. Therefore, our negative results should not be considered as contradicting findings from studies that have examined the corpus callosum in detail.⁶⁸

Our classification results suggest that complex spatial patterns of morphologic characteristics can ultimately be used as an image-based diagnostic aid. If these results are replicated on an independent sample, with sensitivity and specificity relative to other disorders, they can support the utility of MRI as an aid in the diagnosis of schizophrenia. There are 2 reasons for our confidence that the classification accuracy estimates we report will generalize. First, we used cross-validation, the jackknife (leave-1-out) procedure, thereby testing the classifier on images that were never seen before. The jackknife is well-established⁶⁹ as a means for obtaining relatively unbiased estimates of future performance. Second, we split the sample into men and women and obtained similar classification performance. We also noted a sex difference in discriminability parameters. The classifier had higher sensitivity than specificity for diagnosing schizophrenia in men and higher specificity than sensitivity for diagnosing schizophrenia in women. Replication of these findings in larger samples is required. We are also examining methods for improved classification accuracy, including selection of wavelet or other basis functions and more effective feature selection schemes. The potential benefits of such diagnostic tools are enhanced by our finding that the abnormalities are present in first-episode, neuroleptic-naïve patients. It seems important to examine whether these morphologic characteristics of schizophrenia occur early in life and relate to disease vulnerability, onset, and course. Such knowledge can be gained from genetic and longitudinal paradigms.

Our method has several limitations. Because of the need to control for multiple comparisons, large samples are necessary to establish regional group differences. Thus, although our sample size was sufficient to document differences between patients and controls, it is insufficiently powered to establish, for example, sex differences within diagnostic groups. The different findings for GM and WM might reflect an underlying difference in the way neuro-

nal bodies and axonal connections are affected by the disease. However, it might also be due to the limitations of standard T1-weighted MRI to resolve WM structures. Future studies using diffusion tensor imaging will be able to resolve WM anatomy in greater detail. Another limitation of our method is its focus on cortical structures. Subcortical measurements would require a different tissue classification technique because subcortical structures, especially the thalamus, have MRI signal characteristics that place them between GM and WM. Because our morphologic analysis was based on a hard segmentation method, it is bound to be limited when examining subcortical structures. Incorporation of fuzzy classification methods⁷⁰ might, to some extent, alleviate this problem. All voxel-based morphometric analysis methods are susceptible to the effects of the spatial normalization transformation that registers images of different individuals. Regions in which this spatial transformation has relatively lower accuracy will tend to display artificially higher variability, which will adversely affect statistical significance. For example, registration and measurement of highly variable prefrontal cortical regions is less accurate than measurement of less variable structures, such as the precen- tral gyrus. We demonstrated that the accuracy of our study was not adversely affected by registration errors, as indicated by the clarity of the average image, which was even clearer than the template itself. This is only possible when the spatially normalized images are accurately co-registered. A future direction involves quantifying variability in every region, after spatial normalization. Because such residual variability is directly related to our ability to measure the respective structure, it will further assist in the interpretation of results.

The present methods for automated analysis of morphometric data largely support findings from earlier studies using expert-guided ROIs or automated procedures. In addition to finer localization of anatomical abnormalities in previously implicated regions, the main new finding we report is reduced volume in visual association areas that include the lingual gyrus. The focal nature of volume reduction in schizophrenia contrasts with that in other brain diseases, such as Alzheimer disease, in which diffuse patterns are evident.

Submitted for Publication: November 24, 2004; final revision received April 25, 2005; accepted May 2, 2005.

Correspondence: Christos Davatzikos, PhD, Department of Radiology, University of Pennsylvania, 3600 Market St, Suite 380, Philadelphia, PA 19104 (christos@rad.upenn.edu).

Funding/Support: This study was supported by grants R01AG14971, MH60722, MH64045, and MO1RR0040 from the National Institutes of Health, Bethesda, Md.

REFERENCES

- Lawrie S, Abukmeil S. Brain abnormality in schizophrenia: a systematic and quantitative review of volumetric magnetic resonance imaging studies. *Br J Psychiatry*. 1998;172:110-120.
- Nelson MD, Saykin AJ, Flashman LA, Riordan HJ. Hippocampal volume reduction in schizophrenia as assessed by magnetic resonance imaging. *Arch Gen Psychiatry*. 1998;55:433-440.
- Shenton ME, Dickey CC, Frumin M, McCarley RW. A review of MRI findings in schizophrenia. *Schizophr Res*. 2001;49:1-52.
- Wright IC, Rabe-Hesketh S, Woodruff PWR, David AS, Murray RM, Bullmore ET. Meta-analysis of regional brain volumes in schizophrenia. *Am J Psychiatry*. 2000; 157:16-25.
- Ashburner J, Friston KJ. Voxel-based morphometry: the methods. *Neuroimage*. 2000;11:805-821.
- Toga AW, Thompson PM, Mega MS, Narr KL, Blanton RE. Probabilistic approaches for atlas normal and disease-specific brain variability. *Anat Embryol (Berl)*. 2001;204:267-282.
- Ananth H, Popescu I, Critchley HD, Good CD, Frackowiak RSJ, Dolan RJ. Cortical and subcortical gray matter abnormalities in schizophrenia determined through structural magnetic resonance imaging with optimized volumetric voxel-based morphometry. *Am J Psychiatry*. 2002;159:1497-1505.
- Gaser C, Nenadic I, Buchsbaum BR, Hazlett EA, Buchsbaum MS. Ventricular enlargement in schizophrenia related to volume reduction of the thalamus, striatum, and superior temporal cortex. *Am J Psychiatry*. 2004;161:154-156.
- Hulshoff Pol HE, Schnack HG, Mandl RCW, van Haren NE, Koning H, Collins DL, Evans AC, Kahn RS. Focal gray matter density changes in schizophrenia. *Arch Gen Psychiatry*. 2001;58:1118-1125.
- Kubicki M, Shenton ME, Salisbury DF, Hirayasu Y, Kasai K, Kikinis R, Jolesz FA, McCarley RW. Voxel-based morphometric analysis of gray matter in first episode schizophrenia. *Neuroimage*. 2002;17:1711-1719.
- Kuperberg GR, Broome MR, McGuire PK, David AS, Eddy M, Ozawa F, Goff D, West WC, Williams SC, van der Kouwe AJ, Salat DH, Dale AM, Fischl B. Regionally localized thinning of the cerebral cortex in schizophrenia. *Arch Gen Psychiatry*. 2003;60:878-888.
- Narr K, Thompson P, Sharma T, Moussai J, Zoumalan C, Rayman J, Toga A. Three-dimensional mapping of gyral shape and cortical surface asymmetries in schizophrenia: gender effects. *Am J Psychiatry*. 2001;158:244-255.
- Park HJ, Levitt J, Shenton ME, Salisbury DF, Kubicki M, Kikinis R, Jolesz FA, McCarley RW. An MRI study of spatial probability brain map differences between first-episode schizophrenia and normal controls. *Neuroimage*. 2004; 22:1231-1246.
- Sigmundsson T, Suckling J, Maier M, Williams S, Bullmore E, Greenwood K, Fukuda R, Ron M, Toone B. Structural abnormalities in frontal, temporal, and limbic regions and interconnecting white matter tracts in schizophrenic patients with prominent negative symptoms. *Am J Psychiatry*. 2001;158:234-243.
- Sowell ER, Levitt J, Thompson PM, Holmes CJ, Blanton RE, Kornsand DS, Caplan R, McCracken J, Asarnow R, Toga AW. Brain abnormalities in early-onset schizophrenia spectrum disorder observed with statistical parametric mapping of structural magnetic resonance images. *Am J Psychiatry*. 2000;157: 1475-1484.
- Wright IC, Sharma T, Ellison ZR, McGuire PK, Friston KJ, Brammer MJ, Murray RM, Bullmore ET. Supra-regional brain systems and the neuropathology of schizophrenia. *Cereb Cortex*. 1999;9:366-378.
- Andreassen NC, Arndt S, Swayze V II, Cizadlo T, Flaum M, O'Leary D, Ehrhardt JC, Yuh WT. Thalamic abnormalities in schizophrenia visualized through magnetic resonance image averaging. *Science*. 1994;266:294-298.
- Csernansky JG, Joshi S, Wang L, Haller JW, Gado M, Miller JP, Grenander U, Miller MI. Hippocampal morphometry in schizophrenia by high dimensional brain mapping. *Proc Natl Acad Sci U S A*. 1998;95:11406-11411.
- Narr KL, Sharma T, Woods RP, Thompson PM, Sowell ER, Rex D, Kim S, Asuncion D, Jang S, Mazziotta J, Toga AW. Increases in regional subarachnoid CSF without apparent cortical gray matter deficits in schizophrenia: modulating effects of sex and age. *Am J Psychiatry*. 2003;160:2169-2180.
- Thompson P, Vidal C, Giedd J, Gochman P, Blumenthal J, Nicolson R, Toga AW, Rapoport JL. Mapping adolescent brain change reveals dynamic wave of accelerated gray matter loss in very early-onset schizophrenia. *Proc Natl Acad Sci U S A*. 2001;98:11650-11655.
- Gerig G, Styner M, Lieberman J. Shape versus size: improved understanding of the morphology of brain structures. In: *Proceedings of the 4th International Conference on Medical Image Computing and Computer-Assisted Intervention*. London, England: Springer-Verlag; 2001:24-32.
- Golland P, Grimson WEL, Shenton ME, Kikinis R. Deformation analysis for shape based classification. *Lect Notes Comput Sci*. 2001;2082:517-530.
- Wang L, Joshi SC, Miller MI, Csernansky JG. Statistical analysis of hippocampal asymmetry in schizophrenia. *Neuroimage*. 2001;14:531-545.
- Gaser C, Nenadica I, Buchsbaum BR, Hazlett EA, Buchsbaum MS. Deformation-based morphometry and its relation to conventional volumetry of brain lateral ventricles in MRI. *Neuroimage*. 2001;13:1140-1145.
- Job DE, Whalley HC, McConnell S, Glabus M, Johnstone EC, Lawrie SM. Structural gray matter differences between first-episode schizophrenics and normal controls using voxel-based morphometry. *Neuroimage*. 2002;17: 880-889.

26. Good CD, Scahill RI, Fox NC, Ashburner J, Friston KJ, Chan D, Crum WR, Ros-
sor MN, Frackowiak RS. Automatic differentiation of anatomical patterns in the
human brain: validation with studies of degenerative dementias. *Neuroimage*.
2002;17:29-46.
27. Davatzikos C. Mapping of image data to stereotaxic spaces. *Hum Brain Mapp*.
1998;6:334-338.
28. Davatzikos C. Measuring biological shape using geometry-based shape
transformations. *Image Vis Comput*. 2001;19:63-74.
29. Davatzikos C. Why voxel-based morphometric analysis should be used with great
caution when characterizing group differences. *Neuroimage*. 2004;23:17-20.
30. Resnick SM, Pham DL, Kraut MA, Zonderman AB, Davatzikos C. Longitudinal
magnetic resonance imaging studies of older adults: a shrinking brain. *J Neurosci*.
2003;23:3295-3301.
31. Davatzikos C, Genc A, Xu D, Resnick SM. Voxel-based morphometry using the
RAVENS maps: methods and validation using simulated longitudinal atrophy.
Neuroimage. 2001;14:1361-1369.
32. Goldszal AF, Davatzikos C, Pham D, Yan M, Bryan RN, Resnick SM. An image
processing protocol for the analysis of MR images from an elderly population.
J Comput Assist Tomogr. 1998;22:827-837.
33. Shen D, Davatzikos C. HAMMER: hierarchical attribute matching mechanism for
elastic registration. *IEEE Trans Med Imaging*. 2002;21:1421-1439.
34. Shen D, Davatzikos C. Very high-resolution morphometry using mass-
preserving deformations and HAMMER elastic registration. *Neuroimage*. 2003;
18:28-41.
35. Gur R, Turetsky B, Bilker W, Gur R. Reduced gray matter volume in schizophrenia.
Arch Gen Psychiatry. 1999;56:905-911.
36. Gur R, Cowell P, Latshaw A, Turetsky BI, Grossman RI, Arnold SE, Bilker WB,
Gur RC. Reduced dorsal and orbital prefrontal gray matter volumes in schizophrenia.
Arch Gen Psychiatry. 2000;57:761-768.
37. Gur R, Turetsky B, Cowell P, Finkelman C, Maany V, Grossman RI, Arnold SE,
Bilker WB, Gur RC. Temporolimbic volume reductions in schizophrenia. *Arch Gen
Psychiatry*. 2000;57:769-775.
38. Gur R, Maany V, Mozley D, Swanson C, Bilker W, Gur R. Subcortical MRI vol-
umes in neuroleptic-naive and treated patients with schizophrenia. *Am J Psychiatry*.
1998;155:1711-1717.
39. Gur R, Mozley P, Resnick S, Levick S, Erwin R, Saykin AJ, Gur RC. Relations
among clinical scales in schizophrenia. *Am J Psychiatry*. 1991;148:472-478.
40. First M, Spitzer R, Williams J, Gibbon M. *Structured Clinical Interview for DSM-
IV: Patient Version (SCID-P)*. New York: Biometric Research, New York State Psy-
chiatric Institute; 1996.
41. American Psychiatric Association. *Diagnostic and Statistical Manual of Mental
Disorders, Fourth Edition*. Washington, DC: American Psychiatric Association;
1994.
42. Overall J, Gorham D. The Brief Psychiatric Rating Scale. *Psychol Rep*. 1962;10:
799-812.
43. Andreasen NC. *Scale for the Assessment of Negative Symptoms (SANS)*. Iowa
City: University of Iowa; 1984.
44. Andreasen NC. *Scale for the Assessment of Positive Symptoms (SAPS)*. Iowa
City: University of Iowa; 1984.
45. Cannon-Spoor H, Potkin S, Wyatt R. Measurement of premorbid adjustment in
chronic schizophrenia. *Schizophr Bull*. 1982;8:470-484.
46. Heinrichs D, Hanlon T, Carpenter WJ. The Quality of Life Scale: an instrument
for rating the schizophrenic deficit syndrome. *Schizophr Bull*. 1984;10:388-
398.
47. First M, Spitzer R, Gibbon M, Williams J. *Structured Clinical Interview for DSM-IV
Axis I Disorders, Non-Patient Edition (SCID-NP)*. New York: Biometric Re-
search, New York State Psychiatric Institute; 1995.
48. Friston KJ, Holmes AP, Worsley KJ, Poline JB, Frith CD, Frackowiak RSJ. Sta-
tistical parametric maps in functional imaging: a general linear approach. *Hum
Brain Mapp*. 1995;2:189-210.
49. Lao Z, Shen D, Xue Z, Karacali B, Resnick SM, Davatzikos C. Morphological clas-
sification of brains via high-dimensional shape transformations and machine learn-
ing methods. *Neuroimage*. 2004;21:46-57.
50. Nopoulos P, Flaum M, Andreasen NC. Sex differences in brain morphology in
schizophrenia. *Am J Psychiatry*. 1997;154:1648-1654.
51. Kemether EM, Buchsbaum MS, Byne W, Hazlett EA, Haznedar M, Brickman AM,
Platholi J, Bloom R. Magnetic resonance imaging of mediodorsal, pulvinar, and
centromedian nuclei of the thalamus in patients with schizophrenia. *Arch Gen
Psychiatry*. 2003;60:983-991.
52. Gur RE, Kohler C, Turetsky BI, Siegel SJ, Kanes SJ, Bilker WB, Brennan AR, Gur
RC. A sexually dimorphic ratio of orbitofrontal to amygdala volume is altered in
schizophrenia. *Biol Psychiatry*. 2004;55:512-517.
53. Chakos M, Lieberman J, Bilder R, Borenstein M, Lerner G, Bogerts B, Wu H, Ki-
non B, Ashtari M. Increase in caudate nuclei volumes of first-episode schizo-
phrenic patients taking antipsychotic drugs. *Am J Psychiatry*. 1994;151:1430-
1436.
54. Elkashef A, Buchanan R, Gellad F, Munson R, Breier A. Basal ganglia pathology
in schizophrenia and tardive dyskinesia: an MRI quantitative study. *Am J Psychiatry*.
1994;151:752-755.
55. Bechara A, Damasio AR. Emotion, decision making and the orbito-
frontal cortex. *Cereb Cortex*. 2000;10:295-307.
56. Squire LR, Zola-Morgan S. The medial temporal lobe memory system. *Science*.
1991;253:1380-1386.
57. Miller EK. The prefrontal cortex and cognitive control. *Nat Rev Neurosci*. 2000;
1:59-65.
58. Gur RE, McGrath C, Chan RM, Schroeder L, Turner T, Turetsky BI, Kohler C, Al-
sop D, Maldjian J, Ragland JD, Gur RC. An fMRI study of facial emotion pro-
cessing in patients with schizophrenia. *Am J Psychiatry*. 2002;159:1992-1999.
59. Ragland JD, Gur RC, Valdez J, Turetsky BI, Elliott M, Kohler C, Siegel S, Kanes
S, Gur RE. Event-related fMRI of frontotemporal activity during word encoding
and recognition in schizophrenia. *Am J Psychiatry*. 2004;161:1004-1015.
60. Weinberger DR, Berman KF, Suddath R, Torrey EF. Evidence of dysfunction of a
prefrontal-limbic network in schizophrenia: a magnetic resonance imaging and
regional cerebral blood flow of discordant monozygotic twins. *Am J Psychiatry*.
1992;149:890-897.
61. McCarley RW, Salisbury DF, Hirayasu Y, Yurgelun-Todd DA, Tohen M, Zarate C,
Kikinis R, Jolesz FA, Shenton ME. Association between smaller left posterior su-
perior temporal gyrus volume on magnetic resonance imaging and smaller left
temporal P300 amplitude in first-episode schizophrenia. *Arch Gen Psychiatry*.
2002;59:321-331.
62. Barta PE, Pearlson GD, Brill LB II, Royall R, McGilchrist IK, Pulver AE, Powers
RE, Casanova MF, Tien AY, Frangou S, Petty RG. Planum temporale asymmetry
reversal in schizophrenia: replication and relationship to gray matter abnormalities.
Am J Psychiatry. 1997;154:661-667.
63. Hirayasu Y, McCarley RW, Salisbury DF, Tanaka S, Kwon JS, Frumin M, Sny-
derman D, Yurgelun-Todd D, Kikinis R, Jolesz FA, Shenton ME. Planum tempo-
rale and Heschl gyrus volume reduction in schizophrenia: a magnetic resonance
imaging study of first-episode patients. *Arch Gen Psychiatry*. 2000;57:692-699.
64. Kwon JS, McCarley RW, Hirayasu Y, Anderson JE, Fischer IA, Kikinis R, Jolesz
FA, Shenton ME. Left planum temporale volume reduction in schizophrenia. *Arch
Gen Psychiatry*. 1999;56:142-148.
65. Cohen M, Kosslyn S, Breiter H, DiGirolamo GJ, Thompson WL, Anderson AK,
Brookheimer SY, Rosen BR, Belliveau JW. Changes in cortical activity during men-
tal rotation: a mapping study using functional MRI. *Brain*. 1996;119:89-100.
66. Kaas J. Theories of visual cortex organization in primates: areas of the third level.
Prog Brain Res. 1996;112:213-221.
67. Mitchell TN, Free SL, Merschhemke M, Lemieux L, Sisodiya SM, Shorvon SD.
Reliable callosal measurement: population normative data confirm sex-related
differences. *AJNR Am J Neuroradiol*. 2003;24:410-418.
68. Innocenti GM, Ansermet F, Parnas J. Schizophrenia, neurodevelopment and cor-
pus callosum. *Mol Psychiatry*. 2003;8:261-274.
69. Hastie T, Tibshirani R, Friedman J. *The Elements of Statistical Learning: Data
Mining, Inference and Prediction*. New York, NY: Springer-Verlag; 2001.
70. Pham DL, Prince JL. An adaptive fuzzy C-means algorithm for image segmen-
tation in the presence of intensity inhomogeneities. *Pattern Recognit Lett*. 1999;
20:57-68.