

Magnetic Resonance Imaging and Head Circumference Study of Brain Size in Autism

Birth Through Age 2 Years

Heather Cody Hazlett, PhD; Michele Poe, PhD; Guido Gerig, PhD; Rachel Gimpel Smith, BA; James Provenzale, MD; Allison Ross, MD; John Gilmore, MD; Joseph Piven, MD

Context: While the neuroanatomical basis of autism is not yet known, evidence suggests that brain enlargement may be characteristic of this disorder. Inferences about the timing of brain enlargement have recently come from studies of head circumference (HC).

Objectives: To examine brain volume and HC in individuals with autism as compared with control individuals.

Design: A cross-sectional study of brain volume was conducted at the first time point in an ongoing longitudinal magnetic resonance imaging study of brain development in autism. Retrospective longitudinal HC measurements were gathered from medical records on a larger sample of individuals with autism and local control individuals.

Setting: Clinical research center.

Participants: The magnetic resonance imaging study included 51 children with autism and 25 control children between 18 and 35 months of age (the latter included both developmentally delayed and typically developing children). Retrospective, longitudinal HC data

were examined from birth to age 3 years in 113 children with autism and 189 local control children.

Main Outcome Measures: Cerebral cortical (including cortical lobes) and cerebellar gray and white matter magnetic resonance imaging brain volumes as well as retrospective HC data from medical records were studied.

Results: Significant enlargement was detected in cerebral cortical volumes but not cerebellar volumes in individuals with autism. Enlargement was present in both white and gray matter, and it was generalized throughout the cerebral cortex. Head circumference appears normal at birth, with a significantly increased rate of HC growth appearing to begin around 12 months of age.

Conclusions: Generalized enlargement of gray and white matter cerebral volumes, but not cerebellar volumes, are present at 2 years of age in autism. Indirect evidence suggests that this increased rate of brain growth in autism may have its onset postnatally in the latter part of the first year of life.

Arch Gen Psychiatry. 2005;62:1366-1376

Author Affiliations: Neurodevelopmental Disorders Research Center, University of North Carolina, Chapel Hill (Drs Hazlett, Poe, Gerig, Gilmore, and Piven and Ms Smith); and Departments of Radiology (Dr Provenzale) and Anesthesiology (Dr Ross), Duke University Medical Center, Durham, NC.

AUTISM IS A COMPLEX NEURODEVELOPMENTAL disorder defined by the presence of social deficits, abnormalities in communication, the presence of stereotyped, repetitive behaviors, and a characteristic course.¹ While the neuroanatomical basis of this condition is not yet known, numerous lines of evidence suggest that abnormalities in brain volume may be characteristic of autism. Head circumference (HC) studies in children and adults with autism have consistently identified a subset of approximately 20% of persons with autism with macrocephaly (ie, greater than the 98th percentile for HC),²⁻⁴ and 2 postmortem studies have shown a high proportion of individuals with autism who have increased brain weight.^{5,6}

We first described increased brain size on magnetic resonance imaging (MRI) in 2 independent samples of adolescents and adults with autism in comparison with age-, sex-, and IQ-comparable controls.^{7,8} More recently, Courchesne et al⁹ examined a cross-sectional sample of 60 males with autism (IQ range, 36-122) and 52 male controls with typical development (TYP) (IQ>85) aged 2 to 16 years. Post hoc analysis revealed enlargement of gray matter (GM) and white matter (WM) cerebral volumes in individuals with autism who were aged 2 through 4 years, but the volumes actually decreased in individuals with autism who were aged 5 to 16 years. White matter cerebellar volumes were increased in the 2- to 4-year-olds but were significantly decreased in adolescence, and cerebellar GM volumes were slightly (but not significantly) in-

creased in the 2- to 4-year-olds and decreased in adolescence. Sparks et al¹⁰ described increased brain volume on MRI in 3- to 4-year-olds with autism as compared with both a nonautistic comparison group with TYP and a nonautistic comparison group with developmental delay (DD), but GM and WM volumes were not examined. Cerebellar volumes were increased in the subjects with autism as compared with the controls with TYP. Aylward et al¹¹ examined a large sample of high-functioning (IQ >80) individuals with autism and controls with TYP who were aged 8 to 46 years. No differences were found in overall total brain volume (TBV). However, increased brain volume was observed in a subset of subjects with autism who were younger than 12 years. No differences were detected in the older age group. A recent study by Herbert et al¹² of 17 high-functioning boys with autism who were aged 7 to 11 years revealed increased WM volume in individuals with autism as compared with 15 controls with TYP, after controlling for total brain size. Finally, Lotspeich et al¹³ have recently described increased GM, but not WM, volume in the cerebral cortex of 31 high- and low-functioning individuals with autism who were aged 8 to 18 years.

While the finding of brain enlargement on MRI has been consistent across all of these studies and consistent with HC and postmortem descriptions, the distribution (across structures, regions, and tissues),^{12,13} associated demographic features (eg, sex, IQ), course, and clinical correlates of this phenomenon are not yet clear. Methodological differences between studies make comparisons difficult. Perhaps of greatest importance in contributing to the variation across studies, however, is the use of cross-sectional data to make inferences about longitudinal, developmental, morphological brain changes. As demonstrated in the important study by Giedd et al,¹⁴ findings from a longitudinal design can provide results that are substantially different from those of cross-sectional analyses of the developing brain.

Inferences about the timing of brain enlargement have recently come from retrospective, longitudinal studies of HC. In a retrospective record review study of individuals with autism and macrocephaly, Lainhart et al³ found evidence suggesting that macrocephaly was not present at birth. Other studies have found results consistent with this finding.^{4,9,15} Most recently, Courchesne et al¹⁶ described retrospective, longitudinal HC data from a small sample of individuals with autism (15 subjects who were examined at 4 time points, and 7 subjects with data from birth plus 1 other time point) vs normative data available from the population, and they noted that individuals with autism in this study had a decreased HC at birth, increased HC at 6 to 14 months of age, and a subsequent decreasing rate of HC growth with increasing age. Previous studies, with the exception of that by Bailey et al,² have also compared HC in individuals with autism with available population norms.

In the present study, we sought to address some of these issues by conducting a longitudinal study of MRI GM and WM brain volumes in a large sample of 2-year-old children with autism and a comparison group that includes both children with TYP and children with DD (without evidence of autism). These children are part of

a longitudinal study and will be examined again at age 4 years. We describe here the results of our "time 1" cross-sectional study of subjects between ages 18 and 35 months. In addition, we examined a longitudinal, retrospective HC data set on a large sample of individuals with autism who were diagnosed with semistructured measures as well as local controls comparable in exclusion criteria, sex, ethnicity, and body mass to provide insight into the timing of brain size changes in this disorder.

METHODS

SAMPLE

Subjects included 51 children with autism and 25 comparison children aged 18 to 35 months. In the comparison group, there were 11 children with DD without evidence of a pervasive developmental disorder and 14 children with TYP. The children with DD were included to enrich the control sample with subjects who were comparable to the subjects with autism in cognitive development. Children with autism were primarily referred from 9 specialty clinics for pervasive developmental disorders in North Carolina (Treatment and Education of Autistic and Related Communication Handicapped Children [TEACCH] centers). Children with DD were referred from selected regional state Children's Developmental Services Agencies in North Carolina. Children with TYP were recruited from community advertisements. Subjects with autism were referred after receiving a clinical diagnosis of an autism spectrum disorder. Subjects with DD were referred only if they had no known identifiable cause for their delay (eg, prematurity, genetic disorder, or neurological disorder) and had no indication of a pervasive developmental disorder. Subjects were excluded for having evidence of a medical condition thought to be associated with autism,¹⁷ including fragile X syndrome, tuberous sclerosis, gross central nervous system injury (eg, cerebral palsy, significant perinatal or postnatal complications or trauma, drug exposure), seizures, and significant motor or sensory impairments. Study approval was acquired from both the University of North Carolina and Duke University institutional review boards, and written informed consent was obtained by getting parental (or custodial guardian) consent for each subject.

All of the subjects in the MRI study were included in the HC study. An additional 62 subjects with autism and 164 children with TYP were added to improve the power needed for the statistical model. The total sample therefore included 113 subjects with autism and 189 controls (11 subjects with DD and 178 subjects with TYP). The additional subjects with autism were selected from other studies conducted by our group^{18,19} using the same diagnostic and exclusionary criteria used in the current study. Subjects with TYP were selected from the children born at University of North Carolina hospitals between 2000 and 2002 who also had medical records available from the University of North Carolina outpatient clinic through 2004 and were aged 2 to 4 years. Medical records from these controls were screened, and subjects were excluded for evidence of prematurity (gestational age <37 months), genetic or neurological disorder (including fragile X syndrome, gross central nervous system injury, cerebral palsy, significant obstetric complications or perinatal or postnatal trauma, drug exposure, seizures, or significant motor or sensory impairments). Birth and well-baby visits were reviewed, and for each available visit, HC, height, and weight were recorded. Additional descriptive data included birth date, sex, race, ethnicity, home ZIP code, parental education level and occupation, and number of siblings. Institutional review board permission was obtained to perform this hospital records review.

Table 1. Sample Characteristics

Group	Sample Size, No.	Male, %	Age, Mean (SD), y	IQ Estimate, Mean (SD)*	Adaptive Behavior Score, Mean (SD)†
Autism	51	90	2.7 (0.3)	54.1 (9.3)	60.7 (6.1)
Developmental delay	11	55	2.7 (0.4)	58.5 (9.9)	63.0 (11.4)
Typically developing	14	71	2.4 (0.4)	108.1 (19.0)	99.8 (13.8)

*Estimate of IQ is from the Mullen Composite Standard Scale score.

†Adaptive behavior estimate is from the Vineland Adaptive Behavior Composite.

Additional reference data, not used in the case-control analyses in this study, were obtained from the Centers for Disease Control HC data set.²⁰

CLINICAL ASSESSMENT

Subjects with autism were enrolled between 18 and 35 months of age. Medical records and developmental history were reviewed. Diagnosis was confirmed using the Autism Diagnostic Interview–Revised²¹ and the Autism Diagnostic Observation Schedule–Generic.²² Subjects were included if they met Autism Diagnostic Interview–Revised algorithm criteria for autism and obtained Autism Diagnostic Observation Schedule–Generic scores consistent with autism. All of the cases met *DSM-IV* criteria¹ for autistic disorder. At time 1, our 18- to 35-month-old sample fell below the recommended age range for use of these measures in the diagnosis of autism. In the design of our study, diagnosis will be reassessed at the more conventional time for standardized assessment of autism with these instruments, which is age 4 years (age 42–59 months), and it is possible that some subjects may no longer meet the full criteria for autistic disorder at that time.

All of the subjects were given a battery of measures, including the Mullen Scales of Early Learning,²³ the Vineland Adaptive Behavior Scales,²⁴ Preschool Language Scale (fourth edition),²⁵ behavioral rating scales, and a standardized neurodevelopmental examination, to exclude subjects with any notable dysmorphism, evidence of neurocutaneous abnormalities, or other significant neurological abnormalities (eg, lateralized deficits). All of the subjects with autism and DD received testing (cytogenetic or molecular) for fragile X syndrome. Children with DD and TYP were screened for autism with the Childhood Autism Rating Scale,²⁶ and they were excluded if they reached the cutoff score for autism (total score ≥ 30). Medical records were also reviewed for any possible evidence of autism or pervasive developmental disorder not otherwise specified, and subjects were excluded from this group for any suggestion of these disorders. **Table 1** displays the subject characteristics (sex, age, cognitive ability, and adaptive functioning) of the final study population.

MRI ACQUISITION

All of the subjects were scanned at the Duke–University of North Carolina Brain Imaging and Analysis Center, Durham, on a 1.5-T GE Signa MRI scanner (General Electric Medical Systems, Milwaukee, Wis). Image acquisition was designed to maximize gray and white tissue contrast for the 18- to 35-month-old children. This included¹ a coronal T1-weighted sequence with the following parameters: inversion recovery preparation pulse, 300 milliseconds; repetition time, 12 milliseconds; echo time, 5 milliseconds; flip angle, 20°; thickness, 1.5 mm; number of excitations, 1; field of view, 20 cm; and matrix, 256 × 192.² It also included a coronal PD/T2-weighted 2-dimensional dual fast spin-echo acquisition with the following parameters: repetition time, 7200 mil-

liseconds; echo time, 17/75 milliseconds; thickness, 3.0 mm; number of excitations, 1; field of view, 20 cm; and matrix, 256 × 160. A series of localizer scans and a set of phantoms were used to standardize assessments over time and individuals.

Subjects with autism and DD were scanned using moderate sedation (combination of pentobarbital and fentanyl citrate as per hospital sedation protocol) administered by a sedation nurse under the supervision of a pediatric anesthesiologist. Physiological monitoring was conducted throughout the scan and recovery. Subjects with TYP were scanned without sedation in the evening while sleeping. All of the scans were reviewed by a pediatric neuroradiologist and were screened for significant abnormalities (eg, malformations, lesions, etc). Seven scans were excluded from the TBV measures for motion artifact or acquisition problems. An additional scan was excluded from the regional and lobe analyses for an error in image acquisition.

IMAGE PROCESSING

Initial image processing to register and align the T1 and PD/T2 scans into a standardized plane was conducted with BRAINS2 software (University of Iowa, Iowa City).^{27–33} All of the scans were registered along an anteroposterior commissure axis. For a small number of scans with suboptimal PD/T2 scan quality, a fit-interleave correction using BRAINS2 was also performed. The coregistered and aligned images were then processed for tissue segmentation using the Expectation Maximization Segmentation (EMS) software (originally developed at the Catholic University of Leuven, Leuven, Belgium,^{34,35} and adapted by our laboratory³⁶). Reliability and validity of the EMS software has been rigorously examined by the developers and within our laboratory.^{34,35,37,38} Our initial attempts to apply the existing adult-based EMS template brain atlas provided unsatisfactory results. Therefore, a new pediatric template atlas was created by our laboratory using MRI brain scans of 14 children (comprising 9 autism, 2 DD, and 3 TYP cases that were randomly selected) that first were tissue classified using BRAINS2, which provides semi-automated tissue classification procedures, and then were averaged to create a probabilistic spatial prior template. This resulted in an averaged probabilistic brain atlas that was aligned to each subject's brain using a linear, affine transformation in a fully automated procedure. After bias estimation, inhomogeneity correction, and nonbrain stripping procedures were conducted, subject scans were processed with EMS to produce GM, WM, and cerebrospinal fluid (CSF) tissue segmented images for each subject. Total brain volume measures included total GM and WM and all of the CSF. Total tissue volume (TTV) included all of the GM and WM in the cerebrum and cerebellum.

Regional lobe measurements were obtained using a manually parcellated template (atlas) MRI developed by our group of a 2-year-old brain (H.C.H., G.G., R.G.S., J. P. M. Jomier, MS, and V. Jewells, MD, unpublished data, 2005). This scan was randomly selected from our database based on having good image quality. Anatomical landmarks were chosen based on standard

Table 2. Description of Tracing Boundaries for Brain Regions*

Region	Boundaries
Cerebellum	Surrounding CSF forms the posterior, inferior, and lateral boundaries. The superior boundary is the inferior extent of the cerebrum. The boundary between the cerebellum and brainstem is the point where the cerebellar peduncles join with the brainstem. Cerebellar peduncles are included in this region.
Subcortical area	The following areas are traced as part of the subcortical "exclusion" area: caudate, thalamus, putamen, globus pallidus, brainstem, internal, external, and extreme capsules, and ventricles within this region. In general, the trace follows the "external" boundaries, the caudate, external or extreme capsule, and the thalamus, along with the boundary of the brainstem with the cerebellum. The superior and posterior boundaries are the callosal sulcus; the anterior boundary is the extent of the caudate nucleus; and the inferior boundary is the inferior extent of the thalamus and the brainstem (just inferior to the cerebellum).
Frontal lobe	Bounded at its superior, anterior, and lateral extents by surface CSF. The medial boundary is the interhemispheric fissure and existing traces of interior structures. The posterior boundary is the central sulcus. The inferior boundary is CSF in the anterior portions, then the sylvian fissure, and in the more posterior slices, a line drawn (in the coronal plane) across the central white matter between the central sulcus and the inferior extent of the corpus callosum.
Occipital lobe	Bounded at its posterior and posterolateral extents by surface CSF. The cerebellum forms the inferior boundary. The anteromedial boundary is formed by the parietal-occipital sulcus. The anterolateral and superior boundary is determined by a straight line drawn (in the coronal plane) across the white matter to the most lateral occipital gyrus. The medial occipital-temporal gyrus is included with the occipital lobe.
Temporal lobe	Bounded at its anterior, lateral, and inferior extents by surface CSF. The sylvian fissure is the superior boundary. The medial boundary is formed by CSF and the existing internal traces. The posterosuperior boundary is determined in the sagittal plane by drawing a line from the upper extent of the sylvian fissure through the parallel sulcus (horizontal posterior segment) to the occipital lobe trace or surface of brain (in lateral slices). The lateral occipital-temporal and fusiform gyri are included with the temporal lobe.
Parietal lobe	This lobe consists of all of the remaining cortex and central white matter not already included with other lobes. The superior and lateral boundaries are surface CSF. The anterior boundary is the central sulcus. The posterior boundary is the occipital lobe. The inferior boundary is determined by the existing traces of interior structures. The isthmus is included with the parietal lobe.

Abbreviation: CSF, cerebrospinal fluid.

*Traces are performed systematically in the order that they are numbered to allow more easily defined regions to provide borders for more difficult regions. The first 3 steps for brain parcellation (not shown here) include tracing boundaries for the following: (1) cingulate gyrus, (2) insula, and (3) corpus callosum.

neuroanatomy references,³⁹⁻⁴⁴ consultation with pediatric neuroradiology experts, and any existing protocols from the literature. Delineated regions included the frontal, temporal, parietal, and occipital lobes, cerebellum, corpus callosum, and interhemispheric fissure (see **Table 2** for description of boundaries). A "subcortical area" was produced to exclude basal ganglia, thalamus, deep WM, and brainstem from all of the other regions. This area was not used to perform any regional comparisons, as other image processing methods are more appropriate and successful in subdividing this area. The insula and cingulate gyrus were also defined, but for the purposes of these analyses, the insula was included in the cerebrum measure, and the cingulate gyrus was included with the frontal and parietal lobes.

The template brain was then mapped onto the T1 images from our data set (after being adjusted for intensity differences and being affine registered using the Rview program⁴⁵) to obtain label maps for all of these regions using a fluid high-dimensional deformation algorithm⁴⁶⁻⁴⁸ that is completely automated. The results of our construct and criterion validity studies show that the output from this protocol is both anatomically valid and closely approximates a manual parcellation. For example, the cerebrum, cerebellum, and frontal lobe regions produced highly consistent volumes with warping alone (intra-class correlation coefficients of overlap between warped volume and manual trace volume ranging from 0.97 to 0.99). Our review of the results revealed difficulty separating the borders between the parietal and occipital lobes, so these 2 lobes were combined for our analyses of this region. Label maps were then combined with the EMS tissue-classified images to produce GM, WM, and CSF volumes for each of these lobe compartments.

STATISTICAL ANALYSES

A priori hypotheses were tested using mixed models with repeated measures over the regional brain volume domains. In all of the models, the regional volume was the dependent vari-

able, with diagnostic group as the predictor of interest and age and sex as covariates. Diagnostic group was entered as a 3-level categorical variable (autism, DD, TYP). Separate parameters were estimated for the DD and TYP groups. A combined estimate for controls was then created using a weighted average of the 2 control groups.

Three sets of analyses were performed to examine segmented brain volume and autism diagnosis. The first set of analyses examined brain volume comparisons of total GM, WM, and CSF. For this model, there were 3 observations per individual (GM, WM, and CSF volumes), with a categorical variable indicating tissue type. Estimates for TBV were created by combining GM, WM, and CSF volumes whereas estimates for TTV were created by combining the estimates for GM and WM volumes. The second set of analyses examined regional brain volumes for the cerebellum and cerebrum. In this analysis, there were 8 observations per individual. The model included 3 categorical variables indicating region, hemisphere (left or right), and tissue (GM or WM). The third set of analyses examined lobe volumes of the cerebrum. In this analysis, there were 12 observations for each individual that were defined by hemisphere (left or right), tissue (GM or WM), and lobe (frontal, temporal, or parietal-occipital).

Age, sex, and group were included as predictors in each of the models, along with all of the 2-, 3-, and 4-way interactions between lobe, hemisphere, tissue, and group, the 2-, 3-, and 4-way interactions between sex and hemisphere, tissue, and lobe, and all of the 2- and 3-way interactions between age, hemisphere, tissue, and lobe.

Laterality indices for GM and WM tissue volumes were calculated using the following formula: $[\text{left} - \text{right} / (\text{left} + \text{right})] \times 100$, where left-hemisphere laterality is indicated by positive values and right-hemisphere laterality is indicated by negative values. Group, age, and sex were regressed on laterality for each lobe and tissue.

Table 3. Adjusted Mean Brain Volumes in Subjects With Autism and in Control Subjects*

Region	Autism Group Brain Volume, Mean (SE), cm ³	Combined Control Group Brain Volume, Mean (SE), cm ³	DD Group Brain Volume, Mean (SE), cm ³	TYP Group Brain Volume, Mean (SE), cm ³
Total brain	1264.6 (13.4)	1208.1 (16.2)	1185.7 (20.5)	1225.6 (23.3)
Total tissue	1136.4 (11.9)	1087.2 (15.1)	1065.7 (19.6)	1104.1 (21.1)
Total GM	819.1 (8.9)	787.5 (10.7)	771.9 (13.9)	799.8 (14.8)
Total WM	317.3 (3.4)	299.7 (4.6)	293.8 (5.9)	304.4 (6.7)
CSF	128.3 (2.6)	120.8 (2.8)	120.0 (5.0)	121.5 (3.3)
Cerebrum				
Total	941.5 (10.5)	890.5 (12.3)	874.4 (17.2)	903.1 (17.4)
GM	676.7 (7.7)	644.2 (8.8)	633.5 (12.4)	652.7 (12.2)
WM	264.7 (3.1)	246.2 (3.7)	240.9 (5.1)	250.4 (5.4)
Cerebellum				
Total	114.1 (1.5)	114.4 (2.2)	113.8 (4.0)	114.9 (2.5)
GM	96.4 (1.4)	96.4 (1.9)	95.4 (3.3)	97.2 (2.2)
WM	17.7 (0.2)	18.0 (0.5)	18.3 (0.9)	17.7 (0.5)

Abbreviations: CSF, cerebrospinal fluid; DD, developmentally delayed; GM, gray matter; TYP, typically developing; WM, white matter.

*Means are adjusted for sex and age.

The retrospective, longitudinal study of HC was performed to compare growth trajectories for HC between the groups. A nonlinear mixed model was fit using an exponential growth function, $y = b_0 + b_1(e^{(b^2) \times \text{age}})$, with b_0 as the random effect. All of the observations were limited to those at age 4 years and younger. The mean number of observations per group was 4 for the autism and TYP groups and 7 for the DD group. Reliability of the retrospective HC data was unknown, as this was all taken from hospital medical records. Two models were fit: the first included only race and sex as covariates, and the second added body mass index as an additional covariate. An estimate of socioeconomic status (maternal education) was intended to be included in the model. However, the majority of medical records of children with TYP were missing this information, and the remaining subset was too small to meaningfully examine this factor. The inclusion of subject characteristics (eg, body mass index, sex, race) was thought to control for any major group differences from these factors.

RESULTS

A description of the sample (sample size, sex, age, IQ, and adaptive behavior) appears in Table 1. Group differences were evaluated for age, sex, adaptive functioning (from the Vineland Adaptive Behavior Scales), and IQ (from the Mullen Scales of Early Learning). Sex was unequally distributed across groups and was therefore included as a covariate in all of the analyses. We did not have a large enough group of girls to perform separate analyses by group for the brain volumes. Age differences were also observed (with the TYP group being slightly younger), so age was also included as a covariate in the analyses. The inclusion of the DD and TYP groups was sufficient to control for IQ differences, as IQ was not found to be a significant predictor when considered simultaneously with these groups.

TOTAL BRAIN VOLUME

Adjusted means for TBV, TTV, total GM volume, total WM volume, and total CSF volume for the autism, TYP and DD groups are in **Table 3**. Subjects with autism had

significant enlargement in TBV, TTV, total GM volume, and total WM volume as well as marginal evidence suggesting enlargement of CSF volume ($P = .05$) as compared with controls. Percentages of increases in brain volumes in subjects with autism over the combined group of controls ranged from 4.0% to 6.1%. Mean differences, standard errors, P values, and percentages of brain volume differences are reported in **Table 4**.

Group comparisons were performed for the cerebral cortical and cerebellar volumes between the subjects with autism and the control subjects. No significant differences in the group by hemisphere effect ($F_{7,71} = 1.03$; $P = .42$) were detected; therefore, left and right differences by region and tissue type are not reported. Mean and adjusted brain volumes are included in Table 3 for the group comparisons. Children with autism had significant enlargement in total cerebral cortical volume (mean volume increased 5.7% vs controls; $P = .002$); however, significant differences were not detected in cerebellar volume (total [$P = .91$], GM [$P = .99$], or WM [$P = .60$]) vs controls. Gray matter and WM cerebral volumes were significantly larger in subjects with autism than in controls ($P = .005$ for GM; $P < .001$ for WM).

Although we acknowledge the small size of the DD and TYP control subgroups for separate analysis, further exploratory comparisons were made with subjects with autism to gain insight into the specificity of the observed effects for autism rather than generalized DD (or mental retardation), as individuals with autism commonly have co-occurring mental retardation. Subjects with autism had significant enlargement in TBV ($P = .001$), TTV ($P = .002$), total GM volume ($P = .004$), and total WM volume ($P = .001$) as compared with the DD subgroup. In contrast, while the subjects with autism had increased brain volumes as compared with the TYP group, the difference did not reach the level necessary for statistical significance ($P = .16$ for TBV; $P = .19$ for TTV; $P = .27$ for GM; $P = .09$ for WM). Differences were also not detected between the DD and TYP groups. Compared with the DD subgroup, subjects with

Table 4. Group Comparisons for Brain Volumes

Region	Autism vs Controls				Autism vs TYP				Autism vs DD			
	Brain Volume Difference, Mean, cm ³	SE	P Value	Brain Volume Difference, %	Brain Volume Difference, Mean, cm ³	SE	P Value	Brain Volume Difference, %	Brain Volume Difference, Mean, cm ³	SE	P Value	Brain Volume Difference, %
Total brain	56.6	20.8	.008	4.7	39.0	27.3	.16	3.2	78.9	23.3	.001	6.7
Total tissue	49.2	19.0	.01	4.5	32.3	24.4	.19	2.9	70.7	22.3	.002	6.6
Total GM	31.6	13.8	.02	4.0	19.3	17.5	.27	2.4	47.2	16.0	.004	6.1
Total WM	17.6	5.6	.003	5.9	12.9	7.5	.09	4.2	23.5	6.7	.001	8.0
CSF	7.4	3.8	.05	6.1	6.8	4.1	.10	5.6	8.2	5.6	.15	6.9
Cerebellum	-0.3	2.7	.91	0.3	-0.8	3.0	.79	0.7	0.4	4.2	.93	0.3
GM	0.0	2.3	.99	0.0	-0.8	2.6	.76	0.8	1.0	3.5	.78	1.0
WM	-0.3	0.5	.60	1.5	0.0	0.6	.99	0.0	-0.6	0.9	.50	-3.2
Cerebrum	51.0	15.6	.002	5.7	38.3	20.2	.06	4.2	67.1	19.2	<.001	7.7
GM	32.5	11.3	.005	5.0	24.0	14.5	.10	3.7	43.2	13.9	.003	6.8
WM	18.5	4.6	<.001	7.5	14.3	6.2	.02	5.7	23.8	5.7	<.001	9.9

Abbreviations: CSF, cerebrospinal fluid; DD, developmentally delayed; GM, gray matter; TYP, typically developing; WM, white matter.

autism had significant enlargement of total cerebral volume ($P < .001$) as well as cerebral GM ($P = .003$) and WM ($P < .001$) volumes. A graph of cerebral volumes appears in **Figure 1**. No significant cerebellar volume differences were found in any of the group comparisons (autism vs DD [$P = .93$ for total cerebellar volume; $P = .78$ for GM; $P = .50$ for WM] or TYP [$P = .79$ for total cerebellar volume; $P = .76$ for GM; $P = .99$ for WM]).

CEREBRAL CORTICAL LOBE VOLUMES

Mean adjusted GM and WM lobe volumes for the groups are reported in **Table 5**. Subjects with autism had significant enlargement of both GM and WM in frontal, temporal, and parietal-occipital lobes as compared with the combined control group. Percentages of differences in TTV across the lobes between subjects with autism and control subjects ranged from 3.5% to 9.1% (**Table 6**). In general, percentages of increases in WM volumes were greater than those in GM volumes. For both WM and GM, the largest percentage of increase was observed in the temporal lobe.

Compared with the DD group, the autism group had significantly enlarged left temporal ($P = .001$), right temporal ($P < .001$), left frontal ($P = .004$), and right frontal ($P = .02$) GM volumes. Parietal-occipital GM volume was not significantly enlarged, but the enlargement approached significance ($P = .06$ for both left and right hemispheres). The autism group also had significantly enlarged left temporal ($P = .002$), right temporal ($P = .002$), left frontal ($P = .001$), right frontal ($P = .003$), left parietal-occipital ($P = .002$), and right parietal-occipital ($P = .001$) WM volumes (Table 6) as compared with the DD group. For the autism and TYP comparison, WM volumes in the left and right temporal and parietal-occipital lobes were significantly enlarged in the autism group. Right temporal GM volume was also enlarged, but not significantly ($P = .06$).

HEAD CIRCUMFERENCE

Growth trajectories of HC were examined using longitudinal ratings from birth to age 4 years. The average num-

ber of HC ratings available from medical records across the 0- to 4-year-old age interval for each group was the following: autism, 4; DD, 7; TYP, 4. The correlation between HC and TBV for the sample was $P = .88$. Overall, the growth curves for subjects with autism and control subjects, displayed in **Figure 2**, were significantly different ($\beta_0 = -1.67$, $\beta_1 = 1.65$, $\beta_2 = -0.03$; $P < .001$ for all of the terms). No group differences between HC ratings were found at birth. The 2 curves begin to diverge at around 12 months of age, with the autism group showing an increased rate of HC growth that continues throughout the rest of the age interval.

Body mass index was calculated on a subset of the sample (autism, 41; DD, 11; TYP, 135) to take differences in body size into account and to address the specificity of the HC effect. Differences in HC between the autistic and TYP groups were unchanged in comparisons with the inclusion of body mass index, suggesting that the observed effects in HC and MRI brain volumes were not the result of a generalized enlargement in body size. For comparison with other studies, we also examined HC in our subject groups vs the normative data published by the Centers for Disease Control and Prevention. In this comparison, the autism group appears to have a slightly smaller HC at birth than the Centers for Disease Control and Prevention group, but otherwise, no considerable differences were observed.

COMMENT

In the present study, we found evidence of brain enlargement in a relatively large sample of 2-year-olds with autism as compared with a control group that includes both children with TYP and children with DD. This approximate 5% overall enlargement appears primarily to be the result of increases in both GM and WM volumes of the cerebral cortex. In general, we observed brain volume enlargement in both the GM and WM tissue compartments, although WM volume increases appeared somewhat more robust than proportionate differences seen in GM. These findings are largely consistent with those of Courchesne et al,⁹ who described GM and WM enlargement

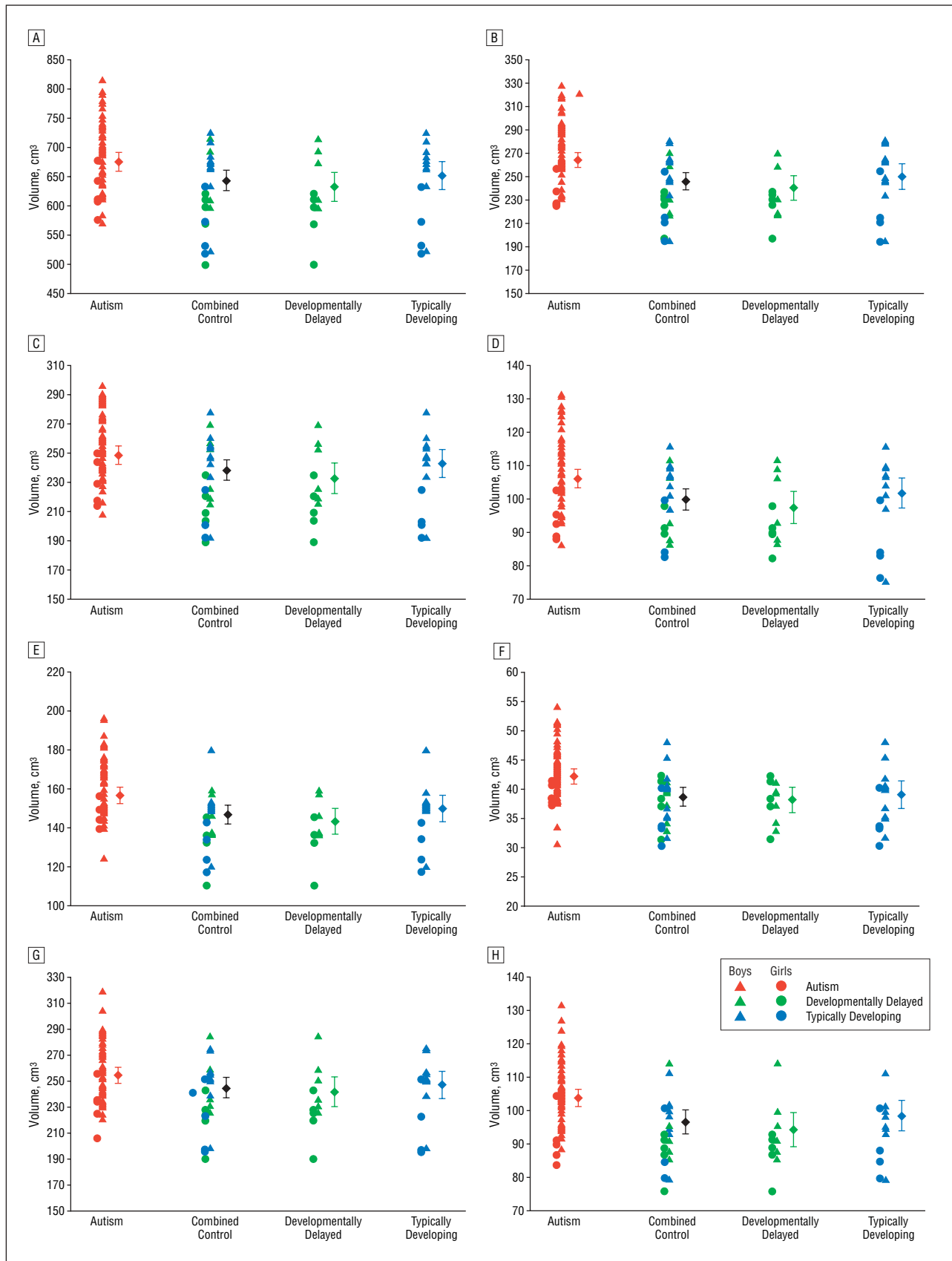


Figure 1. Distributions of regional volumes by group in the following areas: gray matter, cerebrum (A); white matter, cerebrum (B); gray matter, frontal lobe (C); white matter, frontal lobe (D); gray matter, temporal lobe (E); white matter, temporal lobe (F); gray matter, parietal-occipital lobe (G); and white matter, parietal-occipital lobe (H). The estimated mean (adjusted for age and sex) and standard error for each group are represented by a solid diamond and error bars, respectively. The raw values are to the left of each mean and SE.

Table 5. Adjusted Lobe Volumes for Children With Autism, Developmental Delay, and Typical Development*

Region	Autism Group Lobe Volume, cm ³ (n = 51)	Control Group Lobe Volume, cm ³ (n = 25)	DD Group Lobe Volume, cm ³ (n = 11)	TYP Group Lobe Volume, cm ³ (n = 14)
Frontal				
Gray matter				
Total	249.0 (3.1)	238.7 (3.6)	233.0 (5.3)	243.3 (4.7)
Right	124.5 (1.5)	119.9 (1.8)	117.1 (2.7)	122.0 (2.4)
Left	124.5 (1.6)	118.9 (1.8)	115.9 (2.6)	121.2 (2.4)
White matter				
Total	106.3 (1.4)	100.1 (1.6)	97.6 (2.4)	102.0 (2.3)
Right	53.3 (0.7)	50.4 (0.8)	49.3 (1.2)	51.3 (1.2)
Left	53.0 (0.7)	49.6 (0.8)	48.3 (1.2)	50.7 (1.1)
Temporal				
Gray matter				
Total	156.7 (2.0)	147.1 (2.4)	143.4 (3.3)	150.1 (3.3)
Right	80.6 (1.1)	75.3 (1.2)	73.2 (1.7)	76.9 (1.6)
Left	76.3 (1.0)	71.9 (1.2)	70.2 (1.5)	73.2 (1.8)
White matter				
Total	42.1 (0.6)	38.6 (0.8)	38.0 (1.1)	39.0 (1.2)
Right	21.2 (0.3)	19.4 (0.4)	19.2 (0.5)	19.6 (0.6)
Left	20.9 (0.3)	19.1 (0.4)	18.8 (0.6)	19.4 (0.6)
Parietal-occipital region				
Gray matter				
Total	254.4 (3.1)	244.8 (3.9)	242.1 (5.5)	247.0 (5.2)
Right	124.4 (1.5)	120.3 (1.9)	118.8 (2.6)	121.4 (2.7)
Left	130.0 (1.6)	124.6 (2.0)	123.4 (3.1)	125.5 (2.6)
White matter				
Total	103.9 (1.3)	96.7 (1.7)	94.4 (2.5)	98.5 (2.3)
Right	52.2 (0.6)	48.5 (0.9)	47.6 (1.2)	49.1 (1.2)
Left	51.7 (0.7)	48.2 (0.9)	46.8 (1.3)	49.4 (1.1)

Abbreviations: DD, developmentally delayed; TYP, typically developing.
*Values are expressed as mean (SE). Means are adjusted for sex and age.

Table 6. Group Comparisons for Lobes by Tissue and Hemisphere

Region	Autism vs Controls			Autism vs TYP			Autism vs DD		
	Lobe Volume Difference, Mean, cm ³	P SE Value	Lobe Volume Difference, %	Lobe Volume Difference, Mean, cm ³	P SE Value	Lobe Volume Difference, %	Lobe Volume Difference, Mean, cm ³	P SE Value	Lobe Volume Difference, %
Gray matter, parietal-occipital	9.6	5.0 .06	3.9	7.5	6.0 .22	3.0	12.3	6.4 .06	5.1
Left	5.4	2.6 .04	4.3	4.4	3.0 .14	3.5	6.6	3.5 .06	5.4
Right	4.2	2.4 .09	3.5	3.0	3.0 .32	2.5	5.7	3.0 .06	4.8
White matter, parietal-occipital	7.2	2.2 .001	7.4	5.4	2.6 .04	5.5	9.5	2.9 .001	10.1
Left	3.5	1.1 .003	7.2	2.3	1.3 .07	4.8	4.9	1.5 .002	10.5
Right	3.7	1.1 .001	7.7	3.0	1.3 .03	6.2	4.6	1.4 .001	9.6
Gray matter, temporal	9.8	3.1 .002	6.6	6.8	4.0 .10	4.5	13.5	3.6 <.001	9.4
Left	4.4	1.6 .007	6.1	3.1	2.1 .15	4.2	6.1	1.7 .001	8.7
Right	5.4	1.6 .001	7.1	3.7	2.0 .06	4.9	7.4	2.0 <.001	10.1
White matter, temporal	3.5	1.0 .001	9.1	3.1	1.4 .03	8.0	4.0	1.2 .001	10.6
Left	1.7	0.5 .002	9.1	1.5	0.7 .04	7.7	2.1	0.6 .002	11.0
Right	1.8	0.5 .002	9.1	1.6	0.8 .03	8.3	2.0	0.6 .002	10.2
Gray matter, frontal	10.3	4.7 .03	4.3	5.8	5.8 .32	2.4	16.0	5.9 .008	6.9
Left	5.6	2.4 .02	4.7	3.3	2.9 .26	2.7	8.6	2.9 .004	7.4
Right	4.7	2.4 .05	3.9	2.5	3.0 .40	2.0	7.4	3.0 .02	6.3
White matter, frontal	6.2	2.1 .004	6.2	4.3	2.7 .11	4.2	8.7	2.7 .002	8.9
Left	3.4	1.1 .002	6.8	2.3	1.3 .09	4.5	4.7	1.4 .001	9.7
Right	2.9	1.1 .008	5.7	2.0	1.4 .15	3.9	4.0	1.3 .003	8.1

Abbreviations: DD, developmentally delayed; TYP, typically developing.

in 2- to 4-year-olds, and Sparks et al,¹⁰ who found enlargement in 3- to 4-year-olds with autism. However, as compared with both of those studies, we failed to find any evi-

dence of enlargement in cerebellar volume in either total, GM, or WM volumes. These findings also differ from our own previous description of overall cerebellar vol-

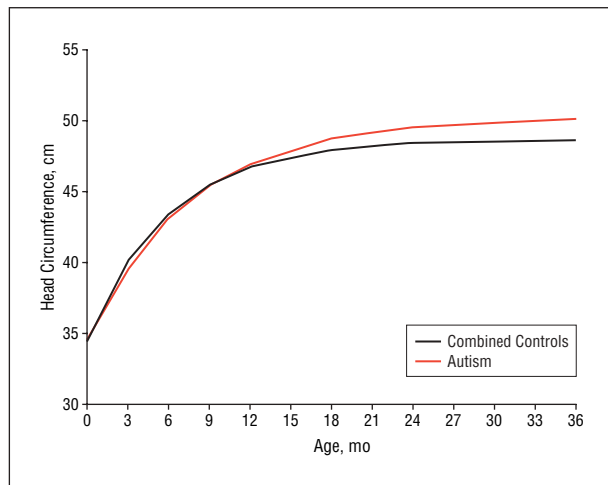


Figure 2. Growth trajectory of head circumference by group.

ume enlargement in an adolescent and adult sample.⁷ Of note, our current sample differs from the samples in the studies by Courchesne and colleagues and Sparks and colleagues. It is possible that cerebellar enlargement is a later-occurring effect that we will detect at follow-up of our current 2-year-old cohort at age 4 years. Alternatively, apparent differences in results for cerebellar volume may result from differences in image processing. In the present study, we used an automated high-dimensional warping method based on an atlas of the 2-year-old brain whereas in the studies by both Sparks and colleagues and Courchesne and colleagues, manual tracings of the cerebellum were conducted. In our previous study, cerebellar volume was measured using an automated system based on the Talarach coordinates, which we believe is less anatomically valid than our current approach.

Cerebral cortical enlargement in our sample appeared to be the result of a generalized enlargement in the 3 cortical regions examined (frontal, temporal, and parietal-occipital lobes), although the percentage of enlargement was greatest in the temporal lobe. In a previous study⁸ of adolescents and adults with autism performed by our group, again using the Talarach coordinates for automated measurement of lobe volumes, we did not detect significant enlargement in frontal lobes. However, in a recent reexamination of this earlier adolescent and adult sample using an updated version of the same Talarach coordinates software that allowed us to segment GM and WM volumes (which we did not previously study), we detected enlargement in frontal, temporal, and parietal lobes but not in the occipital lobe,⁴⁹ paralleling findings described by Carper et al⁵⁰ using a manual method for lobe parcellation in 2- to 3-year-olds. Our semiautomated method did not allow us to confidently separate parietal regions from occipital regions, and we are therefore unable to comment on whether the differences that we detected are the result of enlargement of the parietal lobe and/or occipital lobe. Given the large inter-individual variation in autism, such differences will need to be examined prospectively in a longitudinal analysis before more definitive conclusions about patterns across lobes and tissues over time can be made with confidence.

Our combined control group took into account the fact that autism is often associated with mental retardation, which may itself have an effect on brain development separate from that seen in autism without mental retardation. Although we are hesitant to make too much of the exploratory analyses between subjects with autism and our relatively small samples of TYP ($n=14$) and DD ($n=11$) control subgroups, differences in these comparisons were observed and warrant comment. Brain enlargement in subjects with autism in our study was more readily apparent when subjects with autism were compared with the DD group than when compared with the TYP group. If, as we believe, mental retardation is important to take into consideration in MRI studies of the brain in autism, then based on our comparison of subjects with autism and our small group of individuals with DD, it can be concluded that the effect of autism is generalized across both GM and WM compartments. However, if observations were limited to a comparison with 2-year-olds with TYP only, then one would conclude that the autism effect is more specific to WM, limited to temporal and parietal-occipital regions of the cortex, and somewhat less robust. Of note, no significant relationship between IQ and brain volume was detected in individuals with autism, suggesting that IQ is not important and that observations in this study may be the result of abnormalities or bias in the DD group. However, the standard error in brain volumes of the DD group was actually less than that seen in the TYP group, somewhat going against the idea that the DD group may have been more heterogeneous and less representative. It is also worth noting that evaluation of IQ at this early age, as in our sample, is problematic. Almost all of the 2-year-olds with autism in our sample showed evidence of low IQ, as children identified with autism at very young ages are more noticeably impaired than higher-functioning individuals with autism who are often not detected until later ages. Overall, more definitive interpretations regarding the effect of IQ in MRI studies of autism await studies using larger comparison groups of both individuals with TYP and individuals with DD followed up over time.

In the present study, we detected no evidence of cerebral laterality. In our recent reanalysis⁴⁹ of an earlier sample,⁸ we observed left laterality (disproportionately greater in subjects with autism than that which is normally present in controls) in temporal lobe GM. Longitudinal analysis of volume changes over time may reveal that this effect emerges at older ages. Examination for clinical correlates using global measures (Autism Diagnostic Interview–Revised algorithm subdomain scores: social, communication, ritualistic repetitive behavior, abnormal development) aimed more specifically at diagnosis than measurement of specific symptom domains in 2-year-olds did not reveal any obvious brain-behavior correlations. As noted above, IQ effects were also not observed in this young sample. Sex effects were not examined, as we had too few girls with autism to explore this confidently.

We examined retrospective, longitudinal data on HC in a large sample of individuals with autism who were diagnosed with standardized measures. We compared these subjects with a large sample of locally ascertained

controls using exclusion criteria comparable to autistic cases and taking several potential confounding variables into account, including sex, race, and body size. We confirmed the significant enlargement of HC in autism and found strong evidence to suggest that the increased trajectory of HC growth has its origin during the postnatal period around 12 months of age. We acknowledge that subtle differences in this estimate can occur given the statistical model used, and that greater differences (ie, an earlier onset of enlargement) may possibly be detected if the comparison group includes a larger sample of individuals with DD without autism. These findings are not inconsistent with those of Courchesne et al,¹⁶ who detected significant enlargement in an age interval between 6 and 14 months.

The findings from this study confirm the presence of generalized cerebral cortical GM and WM brain volume enlargement at age 2 in individuals with autism. Given the strong relationship between HC and brain volume,⁹ the onset of this enlargement appears likely to be during the postnatal period and may begin as late as the latter part of the first year of life. Enlargement during this period is consistent with either a decrease in the normal loss of neuronal processes (eg, dendritic pruning) or overexuberant dendritic arborization. Our ability to link knowledge of brain patterning from genetic studies in animals⁵¹ to existing data on patterns of brain development in autism will be important as candidate genes continue to be identified for autism.² The data we present on the possible timing of brain enlargement in autism also raise the possibility that the onset of autistic symptoms may be associated with postnatal changes in brain volume, and that there may exist a presymptomatic period in autism in which intervention may have more potent effects. While this hypothesis is admittedly quite speculative, it is nevertheless important to consider. Clearly, the longitudinal study of very early brain and behavior development in autism has the potential to provide important clues that are relevant to early detection and early mechanisms underlying changes in the brain in autism.

Several limitations of this study should be noted. The difficulty in ascertaining and scanning large numbers of subjects without autism at age 2 years, and particularly those with DD without autism or other neurological sequelae often associated with DD, limited our ability to have a larger comparison group for the subjects with autism in this study. Also, children with TYP, who were scanned without the benefits of sedation, present challenges to obtaining high-quality MRI scans. Given the young age of our autism group, we suspect that our sample may be biased toward more severely affected individuals who present clinically between 18 and 35 months of age. Certainly, our sample of subjects with autism appears to have more individuals with mental retardation than appear in current population estimates of autism, where there is an increasing prevalence of individuals in the higher IQ range.¹⁷ We are currently enriching our sample of 4-year-olds with individuals with autism and higher IQ whom we were unable to find at age 2 years. Despite these challenges, our study design attempts to take potential IQ effects into account by including both children with DD and TYP for comparison.

Submitted for Publication: February 17, 2005; final revision received April 29, 2005; accepted May 2, 2005.

Correspondence: Heather Cody Hazlett, PhD, Neurodevelopmental Disorders Research Center, University of North Carolina, Campus Box 3367, Chapel Hill, NC 27599-3367 (heather_cody@med.unc.edu).

Funding/Support: This work was supported by grants EB002779 (Dr Gerig), MH61696 (Dr Piven), and HD03110 (Dr Piven) from the National Institutes of Health, Bethesda, Md.

Acknowledgment: We express our appreciation for the assistance we received from the following: the Treatment and Education of Autistic and Related Communication Handicapped Children (TEACCH) centers, the Neurodevelopmental Disorders Research Center Autism Subject Registry, and North Carolina Children's Developmental Services Agencies for assisting with recruitment; Matthieu Jomier, MS, and Martin Styner, PhD, for providing image processing support; Peg Nopoulos for her comments on the manuscript; and most importantly, the families who have participated in this study.

REFERENCES

1. American Psychiatric Association. *Diagnostic and Statistical Manual of Mental Disorders, Fourth Edition*. Washington, DC: American Psychiatric Association; 1994.
2. Bailey A, Le Couteur A, Gottesman I, Bolton P, Simonoff E, Yudza E, Rutter M. Autism as a strongly genetic disorder: evidence from a British twin study. *Psychol Med*. 1995;25:63-77.
3. Lainhart JE, Piven J, Wzorek M, Landa R, Santangelo SL, Coon H, Folstein SE. Macrocephaly in children and adults with autism. *J Am Acad Child Adolesc Psychiatry*. 1997;36:282-289.
4. Stevenson RE, Schroer RJ, Skinner C, Fender D, Simensen RJ. Autism and macrocephaly. *Lancet*. 1997;349:1744-1745.
5. Bailey A, Luthert P, Bolton P, Le Couteur A, Rutter M, Harding B. Autism and megalencephaly. *Lancet*. 1993;341:1225-1226.
6. Bauman M, Kemper TL. Histoanatomic observations of the brain in early infantile autism. *Neurology*. 1985;35:866-874.
7. Piven J, Nehme E, Simon J, Barta P, Pearson G, Folstein SE. Magnetic resonance imaging in autism: measurement of the cerebellum, pons, and fourth ventricle. *Biol Psychiatry*. 1992;31:491-504.
8. Piven J, Arndt S, Bailey J, Andreasen N. Regional brain enlargement in autism: a magnetic resonance imaging study. *J Am Acad Child Adolesc Psychiatry*. 1996;35:530-536.
9. Courchesne E, Karns CM, Davis HR, Ziccardi R, Carper RA, Tigue ZD, Chisum HJ, Moses P, Pierce K, Lord C, Lincoln AJ, Pizzo S, Schreibman L, Haas RH, Akshoomoff NA, Courchesne RY. Unusual brain growth patterns in early life in patients with autistic disorder: an MRI study. *Neurology*. 2001;57:245-254.
10. Sparks BF, Friedman SD, Shaw DW, Aylward EH, Echelard D, Artru AA, Maravilla KR, Giedd JN, Munson J, Dawson G, Dager SR. Brain structural abnormalities in young children with autism spectrum disorder. *Neurology*. 2002;59:184-192.
11. Aylward EH, Minshew NJ, Field K, Sparks BF, Singh N. Effects of age on brain volume and head circumference in autism. *Neurology*. 2002;59:175-183.
12. Herbert MR, Ziegler DA, Deutsch CK, O'Brien LM, Lange N, Bakardjiev A, Hodgson J, Adrien KT, Steele S, Makris N, Kennedy D, Harris GJ, Caviness VS Jr. Dissociations of cerebral cortex, subcortical and cerebral white matter volumes in autistic boys. *Brain*. 2003;126:1182-1192.
13. Lotspeich LJ, Kwon H, Schumann CM, Fryer SL, Goodlin-Jones BL, Buonocore MH, Lammers CR, Amaral DG, Reiss AL. Investigation of neuroanatomical differences between autism and Asperger syndrome. *Arch Gen Psychiatry*. 2004;61:291-298.
14. Giedd JN, Blumenthal J, Jeffries NO, Castellanos FX, Liu H, Zijdenbos A, Paus T, Evans AC, Rapoport JL. Brain development during childhood and adolescence: a longitudinal MRI study. *Nat Neurosci*. 1999;2:861-863.
15. Torrey EF, Dhavale D, Lawlor JP, Yolken RH. Autism and head circumference in the first year of life. *Biol Psychiatry*. 2004;56:892-894.
16. Courchesne E, Carper R, Akshoomoff N. Evidence of brain overgrowth in the first year of life in autism. *JAMA*. 2003;290:337-344.

17. Fombonne E. Epidemiological surveys of autism and other pervasive developmental disorders: an update. *J Autism Dev Disord.* 2003;33:365-382.
18. Collaborative Linkage Study of Autism Group. Incorporating language phenotypes strengthens evidence of linkage to autism. *Am J Med Genet.* 2001;105:539-547.
19. Piven J, Palmer P, Jacobi D, Childress D, Arndt S. Broader autism phenotype: evidence from a family history study of multiple-incidence autism families. *Am J Psychiatry.* 1997;154:185-190.
20. Kuczumski RJ, Ogden CL, Guo SS, Grummer-Strawn LM, Flegal KM, Mei Z, Wei R, Curtin LR, Roche AF, Johnson CL. 2000 CDC growth charts for the United States: methods and development. *Vital Health Stat 11.* 2002;No. 246:1-190.
21. Lord C, Rutter M, Le Couteur A. Autism Diagnostic Interview-Revised: a revised version of a diagnostic interview for caregivers of individuals with possible pervasive developmental disorders. *J Autism Dev Disord.* 1994;24:659-685.
22. DiLavore PC, Lord C, Rutter M. The pre-linguistic autism diagnostic observation schedule. *J Autism Dev Disord.* 1995;25:355-379.
23. Mullen EM. *Mullen Scales of Early Learning: AGS Edition.* Circle Pines, Minn: American Guidance Service; 1995.
24. Sparrow SS, Balla DA, Cicche HV. *Vineland Adaptive Behavior Scales: Interview Edition, Survey Form Manual.* Circle Pines, Minn: American Guidance Service; 1984.
25. Zimmerman IL, Steiner VG, Pond RE. *Preschool Language Scale.* 4th ed. San Antonio, Tex: Psychological Corp; 2002.
26. Mesibov GB, Schopler E, Schaffer B, Michal N. Use of the childhood autism rating scale with autistic adolescents and adults. *J Am Acad Child Adolesc Psychiatry.* 1989;28:538-541.
27. Andreasen NC, Cohen G, Harris G, Cizadlo T, Parkkinen J, Rezaei K, Swayze VW II. Image processing for study of the brain structure and function: problems and programs. *J Neuropsychiatry Clin Neurosci.* 1992;4:125-133.
28. Andreasen NC, Cizadlo T, Harris G, Swayze VW II, O'Leary DS, Cohen G, Ehrhardt J, Yuh WT. Voxel processing techniques for the antemortem study of neuroanatomy and neuropathology using magnetic resonance imaging. *J Neuropsychiatry Clin Neurosci.* 1993;5:121-130.
29. Andreasen NC, Rajarethinam R, Cizadlo T, Arndt S, Swayze VW II, Flashman LA, O'Leary DS, Ehrhardt JC, Yuh WT. Automatic atlas-based volume estimation of human brain regions from MR images. *J Comput Assist Tomogr.* 1996;20:98-106.
30. Arndt S, Swayze V, Cizadlo T, O'Leary D, Cohen G, Yuh WT, Ehrhardt JC, Andreasen NC. Evaluating and validating 2 methods for estimating brain structure volumes: tessellation and simple pixel counting. *Neuroimage.* 1994;1:191-198.
31. Cohen G, Andreasen NC, Alliger R, Arndt S, Kuan J, Yuh WT, Ehrhardt J. Segmentation techniques for the classification of brain tissue using magnetic resonance imaging. *Psychiatry Res.* 1992;45:33-51.
32. Magnotta VA, Harris G, Andreasen NC, O'Leary DS, Yuh WT, Heckel D. Structural MR image processing using the BRAINS2 toolbox. *Comput Med Imaging Graph.* 2002;26:251-264.
33. Harris G, Andreasen NC, Cizadlo T, Bailey JM, Bockholt HJ, Magnotta VA, Arndt S. Improving tissue classification in MRI: a 3-dimensional multispectral discriminant analysis method with automated training class selection. *J Comput Assist Tomogr.* 1999;23:144-154.
34. Van Leemput K, Maes F, Vandermeulen D, Suetens P. Automated model-based bias field correction of MR images of the brain. *IEEE Trans Med Imaging.* 1999;18:885-896.
35. Van Leemput K, Maes F, Vandermeulen D, Suetens P. Automated model-based tissue classification of MR images of the brain. *IEEE Trans Med Imaging.* 1999;18:897-908.
36. Prastawa M, Gilmore J, Lin W, Gerig G. Automatic segmentation of MR images of the developing newborn brain. *Med Image Anal.* 2005;9:457-466.
37. Park J, Gerig G, Chakos M, Vandermeulen D, Lieberman JA. Neuroimaging of psychiatry disease: reliable and efficient automatic brain tissue segmentation for increased sensitivity. *Schizophr Res.* 2001;49:163.
38. Styner M, Charles C, Park J, Gerig G. Multisite validation of image analysis methods: assessing intra and inter site variability. *Proc SPIE.* 2002;4684:278-286.
39. Parent A. *Carpenter's Human Neuroanatomy.* 9th ed. Baltimore, Md: Williams & Wilkins; 1996.
40. Crossman AR, Neary D. *Neuroanatomy: An Illustrated Colour Text.* New York, NY: Churchill Livingstone; 1995.
41. Duvernoy H. *The Human Brain: Surface Three-Dimensional Anatomy and MRI.* New York, NY: Springer-Verlag; 1991.
42. Hanaway J. *The Brain Atlas: A Visual Guide to the Human Central Nervous System.* Bethesda, Md: Fitzgerald Science Press; 1998.
43. Tamraz JC, Comair YG. *Atlas of Regional Anatomy of the Human Brain Using MRI: With Functional Correlations.* New York, NY: Springer-Verlag; 2000.
44. Mai JK, Assheuer J, Paxinos G. *Atlas of the Human Brain.* New York, NY: Academic Press; 1997.
45. Schnabel JA, Rueckert D, Quist M, Blackall JM, Castellano Smith AD, Hartkens T, Penney GP, Hall WA, Liu H, Truwit CL, Gerritsen FA, Hill DLG, Hawkes JD. A generic framework for nonrigid registration based on nonuniform multilevel free-form deformations. In: Niessen WJ, Viergever MA, eds. *Medical Image Computing and Computer-Assisted Intervention: MICCAI 2001, Fourth International Conference, Utrecht, The Netherlands, October 14-17, 2001, Proceedings.* New York, NY: Springer; 2001:573-581. *Lecture Notes in Computer Science*; vol 2208.
46. Joshi S, Grenander U, Miller MI. On the geometry and shape of brain submanifolds. *Int J Pattern Recognition Artif Intell.* 1997;11:1317-1343.
47. Miller MI, Joshi SC, Christensen GE. Large deformation fluid diffeomorphisms for landmark and image matching. In: Toga AW, ed. *Brain Warping.* San Diego, Calif: Academic Press; 1999:115-132.
48. Joshi S, Davis B, Jomier M, Gerig G. Unbiased diffeomorphic atlas construction for computational anatomy. *Neuroimage.* 2004;23(suppl 1):S151-S160.
49. Hazlett HC, Poe MD, Gerig G, Gimpel R, Piven J. Cortical gray and white brain tissue volume in adolescents and adults with autism. *Biol Psych.* In press.
50. Carper RA, Moses P, Tigue ZD, Courchesne E. Cerebral lobes in autism: early hyperplasia and abnormal age effects. *Neuroimage.* 2002;16:1038-1051.
51. Monuki ES, Walsh CA. Mechanisms of cerebral cortical patterning in mice and humans. *Nat Neurosci.* 2001;4(suppl):1199-1206.