

Protein Binding in Patients With Late-Life Depression

Anand Kumar, MD; Vladimir Kepe, PhD; Jorge R. Barrio, PhD; Prabha Siddarth, PhD; Vicki Manoukian, MA; Virginia Elderkin-Thompson, PhD; Gary W. Small, MD

Context: Depression has been identified as a risk factor and a prodrome of dementia. Common neurobiological mechanisms may underlie this clinical and phenomenologic overlap.

Objective: To examine and compare protein (amyloid and tau) binding in critical brain regions in patients diagnosed as having late-life major depressive disorder (MDD) and healthy control individuals using 2-(1-{6-[(2-[¹⁸F]fluoroethyl)(methyl)-amino]-2-naphthyl}ethylidene) malononitrile ([¹⁸F]FDDNP) positron emission tomography.

Design: A cross-section neuroimaging study using positron emission tomography.

Setting: University of California, Los Angeles.

Patients: Our samples comprised 20 patients diagnosed as having MDD and 19 healthy control individuals of comparable age, sex, and educational level.

Main Outcome Measure: Relative distribution volume in regions of interest was used as the measure of [¹⁸F]FDDNP binding in all study participants.

Results: When compared with controls, [¹⁸F]FDDNP binding was significantly higher overall and in the posterior cingulate and lateral temporal regions in the MDD group.

Conclusions: These findings suggest that neuronal injury associated with higher protein load in critical brain regions might provide a mechanism in the pathophysiologic manifestation of MDD in late life and have implications for the therapeutics of depression in elderly individuals.

Arch Gen Psychiatry. 2011;68(11):1143-1150

CLINICALLY SIGNIFICANT DEPRESSION, especially its most severe form, major depressive disorder (MDD), is among the most common mental disorders in the elderly population and is responsible for considerable adverse medical, psychosocial, and economic outcomes.¹ Although the broad effect of clinical depression in the elderly population has been established, the underlying neurobiological underpinnings still are being clarified.^{1,2} Neuroimaging, neuropathologic, and genetic approaches have provided early insights into the biological underpinnings of MDD in late life.^{1,2}

Findings from clinical and preclinical neuroscientific studies^{3,4} suggest a role for neurodegeneration and vascular mechanisms in the pathophysiologic manifestation of late-life depression. Magnetic resonance imaging (MRI)-based neuroimaging determinations have identified smaller volumes in critical cortical and subcortical regions of the brain in patients diagnosed as

having late-life MDD when compared with control individuals.^{5,6} Brain regions implicated in MDD include areas of the prefrontal cortex, hippocampus, and subcortical nuclei. Smaller brain volumes, identified using volumetric MRI estimates, are presumed to reflect neurodegeneration, although neuropathologic findings indicate only circumscribed neuronal loss in MDD.² Vascular mechanisms also are relevant to the pathogenesis of MDD, and degeneration and vascular injury may be complementary mechanisms in the pathophysiologic manifestation of MDD.^{4,7} Preliminary evidence from plasma data indicating that the ratio of amyloid β (A β)-42 to A β 40 may be a biomarker of early Alzheimer disease (AD) in healthy individuals and possibly in patients diagnosed as having MDD has generated recent interest in the role of amyloid in the pathophysiologic manifestation of MDD.⁸⁻¹¹

Depression in the elderly population has been identified as a risk factor and a prodrome for AD.¹²⁻¹⁵ An early epidemio-

Author Affiliations: Departments of Psychiatry and Biobehavioral Sciences (Drs Kumar, Siddarth, and Small) and Molecular and Medical Pharmacology (Drs Kepe and Barrio) and the Semel Institute for Neuroscience and Human Behavior (Ms Manoukian and Dr Elderkin-Thompson), University of California, Los Angeles. Dr Kumar is currently with the Department of Psychiatry at the University of Illinois at Chicago.

logic study¹² identified prior depression, including clinically significant nonmajor forms of the disorder, as a risk factor for AD. The study, based on a population-based sample, reported that prior depression increased the risk of developing AD after controlling for age, sex, educational level, and premorbid cognition. The Religious Orders Study¹⁶ identified baseline depression as predictive of the subsequent development of AD in a sample of more than 600 elderly individuals. In this study, depressive symptoms were associated with a decline in episodic memory and spatial ability but not in semantic or working memory. The Multi-Institutional Research in Alzheimer's Genetic Epidemiology study¹⁷ analyzed data from a sample of 4046 individuals and concluded that although depressive symptoms were associated with the development of AD, the risk was greater when depression occurred in the year immediately before the onset of cognitive impairment. This raises the possibility that depressive symptoms may be a prodrome of AD in specific clinical samples. Earlier reports from Alexopoulos and coworkers¹⁸ identified patients with MDD and executive function impairment as more likely to develop clinical dementia over time. Kral and Emery¹⁹ also reported that patients initially diagnosed as having MDD are more likely to develop dementia during several years. Although published studies^{15,20,21} have found the association between depression and dementia to be relatively weak, the preponderance of evidence supports the assertion that depression can be a risk factor and a prodrome for dementia, especially AD.

The definitive diagnosis of AD requires a history of cognitive decline together with the neuropathologic hallmarks of AD—neuritic plaques and neurofibrillary tangles. Clinical and neuropathologic evidence indicates that the neurobiological changes²² underlying AD begin decades before the clinical manifestations of the disorder become apparent.²³ Braak and Braak²⁴ reported that neurofibrillary tangle density increases in some individuals as early as the fourth decade of life, presumably in individuals destined to develop AD over time. Neuritic plaque distribution in the neocortex and limbic regions also can begin decades before AD becomes clinically manifest.¹³

Positron emission tomography (PET) with specific radioligands has been used to characterize and estimate the in vivo protein load in the brain.²⁵⁻²⁷ 2-(1-{6-[(2-[¹⁸F]fluoroethyl)(methyl)amino]-2-naphthyl}-ethylidene) malononitrile ([¹⁸F]FDDNP) is a molecular imaging probe sensitive for the detection of amyloid and tau protein deposition in the brain.^{25,28,29} Binding of [¹⁸F]FDDNP in vivo correlates well with patterns of amyloid and tau distribution known to exist in AD and determined post mortem.^{25,30} 2-(4'-[¹¹C]methylamino)phenyl-6-hydroxybenzothiazole ([¹¹C]PIB) has been reported to label plaques but not tangles and, like [¹⁸F]FDDNP, it has the ability to discriminate between patients diagnosed as having AD and controls.³¹ In addition, [¹⁸F]FDDNP has shown the expected binding progression from mild cognitive impairment (MCI) to dementia that is supported by neuropathologic data in MCI and AD.^{30,32} Binding of [¹⁸F]FDDNP also is increased in patients diagnosed as having Down syndrome.³³ Of interest, higher [¹⁸F]FDDNP binding in the temporal and frontal lobes has been demon-

strated in preliminary findings in patients with MCI and in cognitively intact elderly participants with higher depression and anxiety ratings.³⁴

Ercoli and associates³⁵ have identified 3 clusters of [¹⁸F]FDDNP binding in middle-aged and older adults without dementia (normal aging and MCI): high temporal posterior cingulate (HT/PC), high frontal-parietal (HF/PA), and low overall. On cognitive testing, the HT/PC and HF/PA groups performed significantly worse than the low global group.³⁵ The HF/PA [¹⁸F]FDDNP subgroup also shows a pattern via F 18 fluorodeoxyglucose (FDG)-PET consistent with increased risk for AD, but the HT/PC [¹⁸F]FDDNP subgroup demonstrates heterogeneity in FDG patterns via PET, consistent with the risk for mixed and/or other forms of dementia, including frontotemporal dementia.³⁶ Such differential patterns of [¹⁸F]FDDNP binding may be useful in subsets of patients who show varying outcomes in what appears to be a possible clinical continuum among late-life depression, MCI, and dementia.³⁷

The purpose of this preliminary investigation is to use [¹⁸F]FDDNP to visualize and characterize protein binding in critical brain regions in a sample of patients diagnosed as having MDD and controls of comparable age, sex, and educational level. This approach would help us directly ascertain the extent and magnitude of protein binding in key brain regions in patients diagnosed as having MDD. On the basis of reports of widespread structural and biophysical abnormalities in the brains of patients diagnosed as having late-life MDD, we hypothesized that these patients would demonstrate significantly higher overall [¹⁸F]FDDNP binding in the cortex when compared with controls.^{5,6,38-41} We additionally hypothesized, based on previously reported neuroanatomical findings,^{5,6} that differences in [¹⁸F]FDDNP binding between patients and controls would be greater in the temporal (especially the mesial temporal) and prefrontal regions.

METHODS

CLINICAL METHODS

Our samples comprised 20 patients (9 men and 11 women) diagnosed as having MDD using established DSM-IV criteria and 19 healthy controls (8 men and 11 women). All patients and controls were recruited from the community in response to local newspaper advertisements, newsletters, and radio advertisements. All study participants provided written informed consent in keeping with the guidelines of the Human Subjects Protection Committee of the University of California, Los Angeles.

All study participants received a Structured Clinical Interview for DSM based on the DSM-IV. Inclusion criteria encompassed diagnosis of MDD, Hamilton Depression Scale⁴² scores of 15 or greater on the 17-item scale, having not taken antidepressants and other psychotropic medications for at least 2 weeks before clinical assessments, and absence of dementia by medical history and mental status examination. Exclusion criteria were history of substance abuse or other Axis I disorder as determined from the Structured Clinical Interview for DSM, clinical evidence of dementia, Mini-Mental State Examination⁴³ score of less than 26, neurologic disorder such as Parkinson disease, history of transient ischemic attack, lifetime history of head trauma with loss of consciousness, current or unstable serious

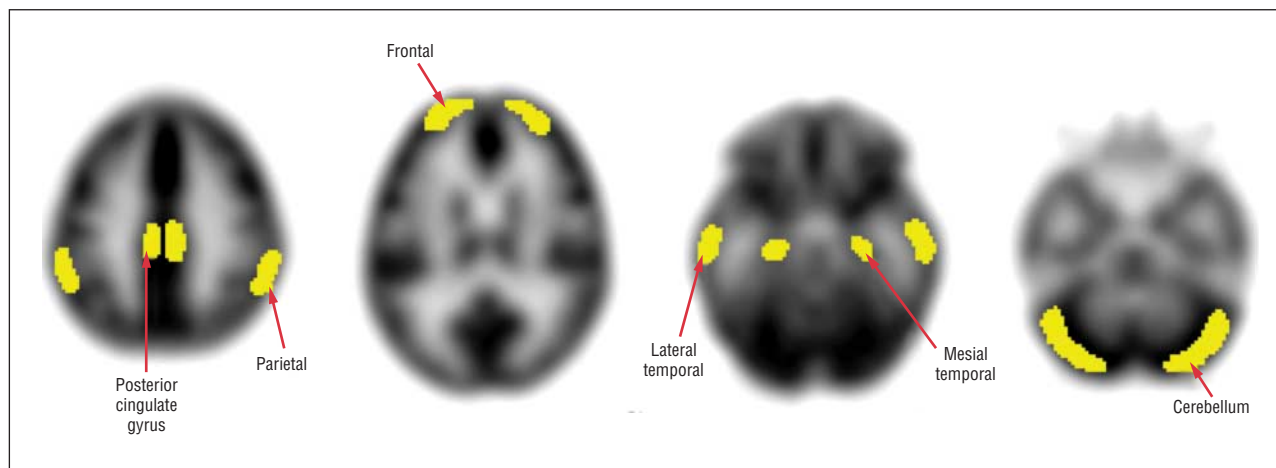


Figure 1. Region of interest (in clusters) analysis approach used in the study.

medical illness, chronic disease such as syphilis that could affect cognitive function, or history or evidence of psychotic symptoms or concurrent Axis I psychiatric disorder. Stable chronic conditions, such as diabetes mellitus, hypertension, or history of cancer, were not exclusionary. All patients received a comprehensive laboratory assessment and a comprehensive neuropsychological battery. Although many of the patients and controls had stable, chronic medical illnesses, none of them had any concurrent brain or psychiatric disorder or any unstable medical illness.

All study participants were screened for dementia based on the clinical evaluation of history, current mental status, and Mini-Mental State Examination score less than 26. Mild cognitive impairment was operationally defined as scoring -1.5 SDs from the mean on 2 or more tests of verbal or visual delayed recall. One patient with MDD met the criteria for MCI. The tests used for the evaluation included the California Verbal Learning Test–Second Edition, the Rey–Osterrieth Complex Figure test, and the Visual Reproduction subtest of the Wechsler Memory Scale–Third Edition (WMS-III). The California Verbal Learning Test and the Visual Reproduction subtest from the Wechsler Memory Scale were normed according to national samples and the Rey–Osterrieth Complex Figure Design test was normed on the control mean of our large research data bank ($N=162$ controls). These tests were selected from a comprehensive neuropsychological battery administered to all participants after completion of the imaging phase. The battery included assessment of literacy, explicit verbal learning and recall, explicit nonverbal learning and recall, executive function, attention and processing, implicit learning, and semantic and phonetic language fluency.

METHODS OF PET

The radiofluorinated imaging probe [^{18}F]FDDNP was prepared at high specific activities (>37 GBq/ μmol), as described elsewhere.⁴⁴ All brain scans were performed at the University of California, Los Angeles, Ahmanson Biological Imaging Center with the EXACT HR+ tomograph (Siemens Medical Solutions, Inc, Munich, Germany; and CTI Molecular Imaging Inc, Knoxville, Tennessee), with individuals in the supine position and the imaging plane placed parallel to the orbitomeatal line. After the injection of the positron emission tomographic tracer (320–410 MBq) as a bolus via the indwelling venous catheter, the consecutive dynamic scans via PET were performed for as long as 2 hours. All scans via PET were decay corrected and reconstructed using filtered back-projection (Hann filter, 5.5-mm full width at half maximum) with scatter correction

and measured attenuation correction. The resulting images contained 63 contiguous sections with a plane-to-plane separation of 2.42 mm.

QUANTITATIVE ANALYSIS OF DATA FROM IMAGING VIA PET

Image data were analyzed and regions of interest (ROIs) determined, with investigators masked to clinical findings. Quantification of the data regarding [^{18}F]FDDNP binding was performed with the Logan graphic method, with the cerebellum as the reference region for time points between 30 and 125 minutes.^{45,46} Similar results were obtained when analyses were performed in intervals of between 30 and 60 minutes. The slope of the linear portion of the Logan plot is the relative distribution volume (DVR), which is equal to the distribution volume of the tracer in an ROI divided by the distribution volume of the tracer in the reference region. Early frame [^{18}F]FDDNP images via PET (sum of 0–5 minutes) were oriented in anterior commissure–posterior commissure orientation by rigid coregistration with the SPM2 software package (The MathWorks, Inc, Natick, Massachusetts) to the template for PET provided in the package. The parameters determined in this step were used to orient the [^{18}F]FDDNP DVR images in the same, coregistered, orientation.

A set of ROIs was drawn bilaterally on the frontal, PA, PC, anterior cingulate, mesial temporal, and lateral temporal lobe areas and the cerebellum on each coregistered early frame [^{18}F]FDDNP image via PET separately using the ROI set shown in **Figure 1** as a guide. The resulting ROI sets were imported in their corresponding [^{18}F]FDDNP DVR images and DVR values were extracted. Drawing of ROIs and extraction of DVR values were performed using the AMIDE Medical Image Data Examiner software package.⁴⁵ Each regional DVR or binding value was expressed as the mean of the left and right regions, and global DVR values were calculated as means of the values for all these regions. Rules for ROI drawing were based on the identification of gyral and sulcal landmarks with respect to the atlas of Talairach and Tournoux.⁴⁷

Brain MRI results were obtained for all study participants with the exception of 2 controls using a 3T scanner (Siemens Medical Solutions, Inc). For each of these individuals, coronal sections that were 1.6-mm thick were obtained (repetition time, 20 milliseconds; echo time, 6 milliseconds; field of vision, 22 cm; 256×256 matrix; number of excitations, 1.5; and flip angle, 45°). Axial sections 3-mm thick also were obtained (repetition time, 4000 milliseconds; echo time, 14/112 milliseconds;

Table 1. Demographic and Clinical Measures in the Patient and Control Groups

Measure	Mean (SD)		Results	P Value
	Patients With MDD	Control		
Age, y	67.45 (8.18)	66.58 (6.27)	.37 ^a	.70
Sex, No.			.03 ^b	.80
Male	9	8
Female	11	11
MMSE score	29.15 (1.14)	28.79 (1.40)	.89 ^a	.40
Educational level, y	15.73 (2.83)	16.84 (2.46)	-1.31 ^a	.20
Verbal IQ	112.55 (10.18)	116.94 (9.73)	-1.36 ^a	.20

Abbreviations: ellipses, not applicable; MDD, major depressive disorder; MMSE, Mini-Mental State Examination.

^a *t* Test.

^b χ^2 Test.

field of vision, 24 cm; 256 × 256 matrix; and number of excitations, 1). All MRI results were examined for space-occupying and other focal lesions, including stroke. Patients described in this study were free of overt neuroanatomical abnormalities.

The [¹⁸F]FDDNP DVR parametric images of 20 patients with MDD and the 8 controls with available T1-weighted MRI results were coregistered to the T1-weighted MRI results using the transformation parameters determined during the coregistration of [¹⁸F]FDDNP images, summed for the first 5 minutes after injection, to the T1-weighted MRI results using statistical parametric mapping (SPM) software. Although 17 of the 19 controls had MRI results, only 8 of them had T1-weighted images that could be used in this analysis. The T1-weighted MRI results and coregistered images via PET were further transformed into the common space using SPM software. The ROIs were drawn on the normalized T1-weighted MRI results bilaterally on the superior and middle frontal gyri on the frontal lobe; the middle temporal gyrus in the lateral temporal lobe; the hippocampus proper, the entorhinal cortex, and the parahippocampal gyrus in the medial temporal lobe; the inferior lobule in the PA lobe; the anterior cingulate gyrus; and the PC gyrus.

The ROI sets were used to extract the DVR values from coregistered [¹⁸F]FDDNP parametric images. The DVR values for each brain region are given as the means of the left and right hemisphere DVR values. We imported positron emission tomographic–drawn ROIs into coregistered MRI results and found good matching of ROIs with gray matter areas on MRI results.

STATISTICAL ANALYSIS

The primary statistical analysis was performed on the data obtained from the group of 20 patients diagnosed as having MDD and from 19 controls in whom the regional [¹⁸F]FDDNP binding values were obtained directly from the images via PET without MRI coregistration. Data were checked for outliers and normality assumptions. The 2 study groups were compared on demographic characteristics using *t* tests for continuous variables and χ^2 tests for categorical variables. We compared the study groups on global [¹⁸F]FDDNP binding levels using a *t* test. To compare the study groups on the regional [¹⁸F]FDDNP binding levels, we estimated a mixed-effects model with repeated measures with group (controls and depressed patients) as the intersubject and region (frontal, medial temporal, lateral temporal, PA, PC, and anterior cingulate) as the intrasubject classification variables. If this model was significant, post hoc *t* tests then were conducted to ascertain which regions were significantly different between the 2 study groups. Also, data from the subset of 28 study participants (20 patients with depression and 8 controls) in whom MRI facili-

tated [¹⁸F]FDDNP–positron emission tomographic analysis was performed were analyzed using nonparametric methods. Global and regional binding levels in this subset of participants were compared using the Wilcoxon-Mann-Whitney test. Analyses were repeated excluding the patient who met criteria for amnesic MCI. All tests were 2-tailed, and the significance level was set at .05. Correction for multiple comparisons were not performed because this is an exploratory study.⁴⁸

RESULTS

The groups did not differ significantly regarding demographic variables (**Table 1**). Study participants ranged in age from 60 to 82 years (mean [SD] age, 67.0 [7.2] years) and were well educated (mean [SD] educational level, 16.3 [2.7] years). They showed minimal impairment on cognitive testing (mean [SD] Mini-Mental State Examination score, 29.0 [1.3]; mean [SD] verbal IQ score, 114.6 [10.1]).

The global [¹⁸F]FDDNP binding value was significantly higher in our MDD group (n=20) when compared with that of controls (n=19; **Table 2**). The groups also were significantly different in their regional [¹⁸F]FDDNP binding levels, as revealed by the mixed-effects model ($F_{1,37}=9.52, P=.004$). Post hoc *t* tests demonstrated that the depressed group had significantly higher binding in the lateral temporal and PC regions when compared with controls (Cohen *d* effect sizes of 0.92 and 0.67, respectively; Table 2 and **Figure 2**).³¹ Group differences in [¹⁸F]FDDNP binding levels in the anterior cingulate and mesial temporal regions approached statistical significance. **Figure 3** shows scans of a healthy control individual (low levels of [¹⁸F]FDDNP binding) and a patient with MDD (areas of HF, posterior cingulate, and PA binding). In the patient with MDD who met the criteria for MCI, [¹⁸F]FDDNP binding values were close to the mean for the MDD group in all regions examined. Furthermore, all findings remained the same when we eliminated this individual from the analyses.

Nonparametric analyses comparing the 20 patients with MDD with the 8 controls (in whom MRI-facilitated [¹⁸F]FDDNP–positron emission tomographic analysis was performed) yielded significant group differences in global [¹⁸F]FDDNP binding levels (Cohen *d* effect size of 1.12, $P=.03$), as well as in PC binding (Cohen *d* effect size of 1.07, $P=.04$).

Table 2. [¹⁸F]FDDNP Binding Levels by Brain Region and Study Group

Brain Region	Mean (SD)		Patients With MDD vs Controls <i>t</i> Test (<i>df</i>)	<i>P</i> Value	Effect Size Cohen <i>d</i>
	Patients With MDD (n=20)	Control Individuals (n=19)			
Global	1.10 (0.04)	1.07 (0.03)	2.55 (37)	.01	0.82
Parietal	1.07 (0.04)	1.05 (0.04)	1.69 (37)	.10	0.54
Frontal	1.04 (0.06)	1.03 (0.03)	1.13 (37)	.27	0.36
Posterior cingulate	1.13 (0.04)	1.10 (0.04)	2.09 (37)	.04	0.67
Anterior cingulate	1.09 (0.05)	1.07 (0.04)	1.96 (37)	.06	0.63
Mesial temporal	1.11 (0.05)	1.09 (0.04)	1.74 (37)	.09	0.56
Lateral temporal	1.11 (0.04)	1.07 (0.04)	2.88 (37)	.007	0.92

Abbreviations: [¹⁸F]FDDNP, 2-(1-(6-[(2-[¹⁸F]fluoroethyl)(methyl)-amino]-2-naphthyl)ethylidene) malononitrile; MDD, major depressive disorder.

COMMENT

The key finding of this exploratory study is that patients with late-life MDD demonstrated significantly higher [¹⁸F]FDDNP binding globally in the cortex with regional accentuation in the lateral temporal and PC regions when compared with healthy controls. Other regions, notably the anterior cingulate and mesial temporal, also showed higher [¹⁸F]FDDNP binding when compared with controls, although the differences did not reach statistical significance. These findings, along with those of plasma studies of amyloid and [¹⁸F]FDDNP binding correlates of anxiety and depression symptoms in patients diagnosed as having MCI and cognitively intact elderly individuals,^{8,9,34} indicate that neuronal injury, secondary to amyloid and tau, may represent a pathophysiologic pathway that, together with vascular compromise, may predispose elderly individuals to mood and related behavioral syndromes and disorders.

This pattern of high [¹⁸F]FDDNP binding in the PC and lateral temporal regions is the same pattern described in a subgroup of 56 individuals without dementia.³⁵ The pattern of binding differs from the pattern typically observed in patients diagnosed as having AD in whom [¹⁸F]FDDNP binding is higher than controls throughout much of the neocortex and more pronounced in mesial temporal and parietal regions. In a more recent study,³⁵ we compared [¹⁸F]FDG–positron emission tomographic cerebral metabolic patterns in individuals without dementia in 3 subgroups defined according to their [¹⁸F]FDDNP binding patterns. In that study, the [¹⁸F]FDDNP subgroup with high lateral temporal and PC binding demonstrated heterogeneity in its [¹⁸F]FDG–positron emission tomographic patterns, with a predominance of anterior frontal and anterior temporal hypometabolism, consistent with risk of mixed and/or other forms of dementia, including frontotemporal dementia.³⁶ Our current results suggest that this high lateral temporal and PC binding in patients with MDD can be associated with different clinical patterns: some individuals show a clinical syndrome consistent with MCI but others demonstrate only depression symptoms. Longitudinal follow-up of these patients is necessary to evaluate the significance of these clusters and the clinical outcomes of these patient subgroups.³⁷

The control and MDD groups in the current study showed a range of regional [¹⁸F]FDDNP binding values (Figure 2), suggesting that subgroups of the patients with

MDD may show alternative patterns of regional binding, including the [¹⁸F]FDDNP pattern HF/PA cluster. As shown in a separate study, this [¹⁸F]FDDNP pattern is associated with an [¹⁸F]FDG–positron emission tomographic pattern consistent with increased risk of AD (bilateral hypometabolism in the PA, temporal posterior cingulate, and dorsolateral prefrontal regions).³⁶ Also, longitudinal data of patients with MCI indicate that this HF/PA pattern confers a high risk of cognitive decline after 2 years of follow-up.⁴⁹ In these patients with MDD with the HF/PA pattern, depressive symptoms may be the initial manifestations of progressive neurodegenerative disease.

Neuroimaging studies, primarily MRI-based studies, have been used extensively to characterize the neuroanatomical and physiologic changes that underlie late-life MDD. Neuroanatomical approaches have revealed smaller brain volumes in key prefrontal, limbic, and subcortical regions in patients with MDD when compared with controls.^{2,3} Changes in gray matter density identified using sophisticated algorithms have shown increases and decreases when compared with controls.^{38,39} Magnetization transfer-based studies have revealed somewhat diffuse biophysical abnormalities in gray and white matter regions in the brains of patients with MDD.^{40,41} Magnetic resonance imaging–identified high-intensity lesions and abnormalities in fractional anisotropy detected using diffusion tensor imaging also are widespread in patients with MDD.^{50–52} Our current finding of relatively widespread increases in [¹⁸F]FDDNP binding, with more marked involvement of some regions, is consistent with the findings of earlier neuroimaging studies that indicate that the biological underpinnings of late-life MDD are diffuse and involve multiple regions and neuronal circuits. Our MRI-facilitated positron emission tomographic image analysis of a subgroup also indicated widespread increase in [¹⁸F]FDDNP binding, although the small sample size precluded regional measures of binding from becoming statistically significant.

The role of amyloid in the pathophysiologic manifestation of depression and dementia has received recent attention, although the findings sometimes are conflicting.^{8,11,53–58} Mayeux and coworkers⁵⁴ reported that the risk of developing AD increased for individuals with higher plasma levels of Aβ42. Other reports suggest that lower Aβ42:Aβ40 ratios in the plasma identify individuals at risk for dementia, especially AD.^{53,55} Pomara and Murali Doraiswamy⁵⁶ first proposed that increased platelet activa-

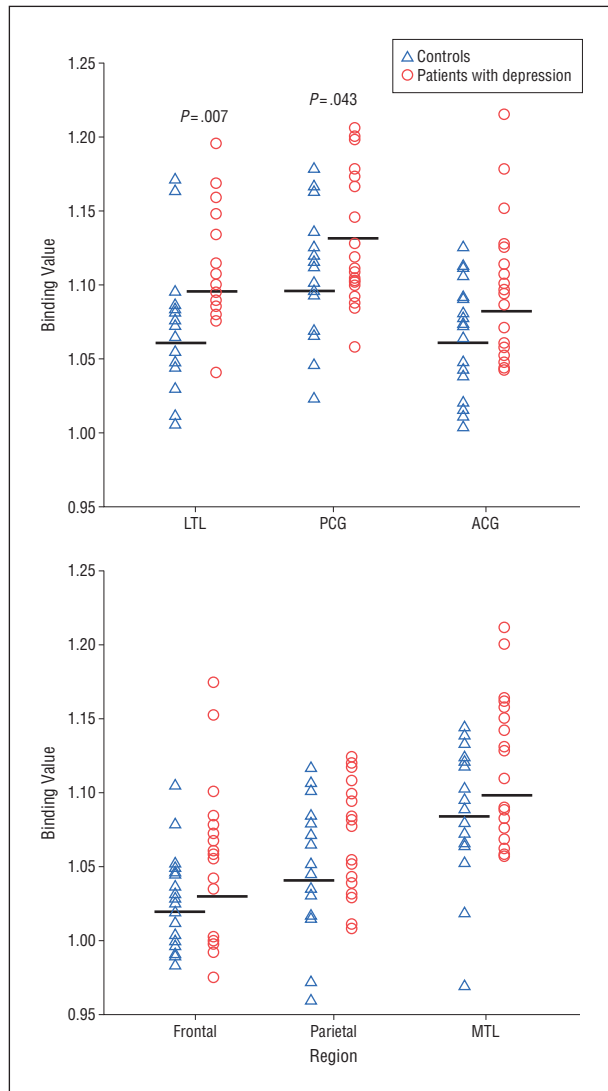


Figure 2. Plot of 2-(1-[6-[(2-[¹⁸F]fluoroethyl)(methyl)-amino]-2-naphthyl)ethylidene] malononitrile binding values in 6 regions of interest in patients with major depressive disorder and healthy control individuals. ACG indicates anterior cingulate; horizontal line, mean; LTL, lateral temporal; MTL, mesial temporal; and PCG, posterior cingulate.

tion in patients with recurrent depression may lead to higher plasma levels of A β that, in turn, contribute to higher brain deposition of amyloid. Plasma studies by Sun and associates¹¹ in patients diagnosed as having late-life MDD demonstrate that a subgroup of patients have lower levels of A β 42 and higher A β 40:A β 42 ratios. In this study, patients with this plasma profile (high A β 40:A β 42 ratio) show impairments in memory and other cognitive domains comparable to the deficits observed in patients with AD. Pomara and Sidtis¹⁰ reported in their sample of patients with late-life MDD that patients with depression had higher levels of A β 42 and A β 42:A β 40 ratios when compared with controls. Their data also suggest that higher A β 42:A β 40 ratios were associated with MRI-related brain abnormalities in patients with MDD. Despite this apparent discrepancy in the literature, both groups of investigators assert that changes in the A β 42:A β 40 ratios rather than changes in the absolute levels of either peptide are the relevant peripheral biological marker. These, together with other re-

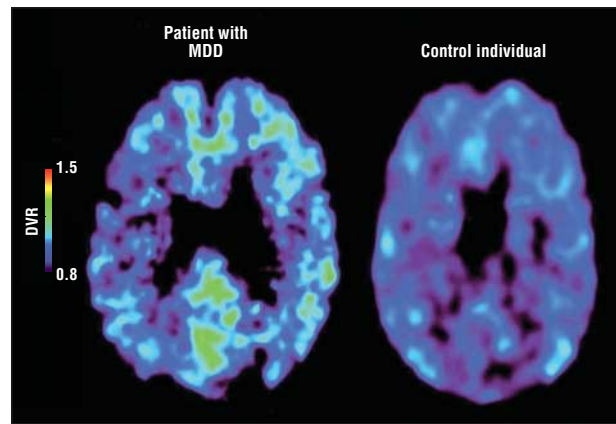


Figure 3. 2-(1-[6-[(2-[¹⁸F]fluoroethyl)(methyl)-amino]-2-naphthyl)ethylidene] malononitrile ([¹⁸F]FDDNP) binding in a healthy control individual and a patient with major depressive disorder (MDD). [¹⁸F]FDDNP relative distribution volume (DVR) parametric images with Logan graphic analysis with the cerebellum as the reference region are shown.

lated observations, have led to the amyloidogenic theory of depression in late life that asserts that in a subgroup of patients with late-life MDD, perturbations of amyloid deposition and biology may be pathophysiologically relevant and may contribute to clinical and/or neuroimaging profiles suggestive of early dementia.⁵⁶ Although the plasma results are intriguing, they are peripheral markers of neurobiology and reflect brain activity only indirectly.⁵⁹⁻⁶² The precise relationship of plasma levels to brain neuronal levels in disease states and preclinical models has yet to be demonstrated.⁵⁹⁻⁶² A study of PET images with validated imaging probes permits a more direct visualization of protein load and amyloid-induced injury in the brain.

An earlier study of PET images using [¹¹C]PIB and a small sample of patients with late-life MDD and controls identified higher [¹¹C]PIB brain retention in patients with MDD compared with controls. Higher [¹¹C]PIB retention was observed in several cortical areas comparable to the distribution seen in patients diagnosed as having AD.⁶³ Of interest, higher [¹¹C]PIB retention was observed most noticeably in patients with MDD who concurrently met criteria for MCI (amnestic, nonamnestic, and mixed variety). Patients with MDD who did not meet the clinical criteria for MCI had [¹¹C]PIB brain retention parameters comparable to those for controls. In our sample, only 1 of the 20 patients with MDD met the criteria for MCI, and that patient's [¹⁸F]FDDNP binding parameters and distribution were similar to those of other patients with MDD. Our primary findings indicate that in patients with MDD who do not meet the established criteria for MCI, [¹⁸F]FDDNP cortical binding is higher than in controls, indicating that brain neuropathologic aggregate deposition is present in MDD even in patients without discernible cognitive impairment.

Depression in late life is clinically and biologically heterogeneous. Current nosologic classifications follow empirical descriptive criteria and a somewhat arbitrary age cutoff for late-life disorders. Comparable to other behavioral and psychiatric classifications, late-life depression is diagnosed exclusively on clinical grounds with no acknowledgment of plausible etiologic considerations. Given this approach, it is not surprising that an entity or entities so defined will be biologically heterogeneous. Studies from sev-

eral laboratories, including ours, have described multiple neuroimaging findings demonstrating several abnormalities in the brains of patients diagnosed as having late-life MDD. These findings include smaller brain volumes, biophysical abnormalities in multiple brain regions, and brain lesions of putative vascular origin. Although it would be premature to include late-life MDD in the category of amyloid and tauopathies, our current findings directly demonstrate that increased neuronal injury also can be correlated (or be secondary) to brain protein deposition, which may constitute another relevant biological mechanism in the underlying biology of MDD. At the cellular level, disparate mechanisms and pathways may converge and synergistically compromise neuronal structure and function even further.

Limitations of the current study include its preliminary nature, relatively small sample size of study groups, and the cross-sectional nature of the design. A longitudinal study with larger study samples is needed to establish the relationship of [¹⁸F]FDDNP binding patterns, in vivo, to clinical outcomes. Also, we did not acquire genetic information regarding our patients and control groups. Although the prevalence of the *APOE* ε4 allele, which is strongly associated with the risk of developing AD, is low in the general population, we are unable to comment on the association, if any, between *APOE* status and [¹⁸F]FDDNP binding in this sample. Also, although we have previously established that [¹⁸F]FDDNP binding in AD is predominantly associated with tau aggregate deposition in the medial temporal lobe and largely reflects amyloid aggregates in other cortical areas, it is not possible to more precisely characterize the relative contributions of both of these proteins to [¹⁸F]FDDNP binding in vivo.³⁰

In conclusion, this is the first report, to our knowledge, to demonstrate increased [¹⁸F]FDDNP binding in focal brain regions suggesting higher amyloid and tau deposition in these brain areas in patients diagnosed as having late-life MDD. The pattern of binding, moreover, differs from that typically seen in patients with AD but it is consistent with that observed in controls at risk for dementia or patients with MCI. Neuronal injury secondary to higher protein deposition may represent a biologically plausible pathway to depression in late life. Longitudinal studies using large clinical samples are needed to determine whether higher [¹⁸F]FDDNP binding at baseline leads to AD over time. Also, [¹⁸F]FDDNP imaging via PET before and after treatment with conventional antidepressant therapy and anti-amyloid agents will provide additional information regarding the change in protein neuropathologic deposition status after successful therapy with biologically relevant agents.

Submitted for Publication: April 27, 2011; final revision received May 31, 2011; accepted June 1, 2011.

Correspondence: Anand Kumar, MD, Department of Psychiatry, University of Illinois at Chicago, 1601 W Taylor, Ste 573, MC 912, Chicago, IL 60612 (akumar@psych.uic.edu).

Financial Disclosure: The University of California, Los Angeles, owns US patent No. 6 274 119, titled "Methods for Labeling β-Amyloid Plaques and Neurofibrillary Tangles," that uses the approach outlined in this article. Drs Small and Barrio are among the inventors of this work, have received

royalties for it, and will receive royalties on future sales. Dr Small reports having served as a consultant and/or having received lecture fees from Brainstorming Co; Dakim, Inc; Eisai Co, Ltd; Forest Pharmaceuticals, Inc; Medivation, Inc; Myriad Genetics, Inc; Novartis AG; Ortho-McNeil-Janssen Pharmaceuticals; Pfizer Inc; Radica Games Limited; and Siemens Medical Solutions USA, Inc. Dr Small also reports having received stock options from Dakim, Inc. Dr Barrio reports having served as a consultant for and having received lecture fees from Nihon Medi-Physics Co, Ltd; Bristol-Meyers Squibb; PETNET Solutions; Noscira S.A.; and Siemens Medical Solutions USA, Inc. He also gratefully acknowledges the support of the Elizabeth and Thomas Plott Chair Endowment in Gerontology at the David Geffen School of Medicine at the University of California, Los Angeles.

Funding/Support: This study was supported by National Institutes of Health grants 5R21MH080258, P01-AG024831, AG13308, P50AG16570, MH/AG58156, MH52453, AG10123, and M01-RR00865; the United States Department of Energy (contract DE-FC03-87-ER60615); the General Clinical Research Centers; the Fran and Ray Stark Foundation Fund for Alzheimer's Disease Research; the McMahan Family Charitable Foundation; the Ahmanson Foundation; the Parlow-Solomon Professorship at the David Geffen School of Medicine at the University of California, Los Angeles; the Elizabeth and Thomas Plott Chair Endowment in Gerontology; and the Judith Olenick Elgart Fund for Research on Brain Aging. No company provided support of any kind for this study.

Additional Contributions: Emma Rhodes, MA, provided assistance in the final editing and technical assistance in preparation of the manuscript.

REFERENCES

1. Alexopoulos GS. Depression in the elderly. *Lancet*. 2005;365(9475):1961-1970.
2. Rajkowska G, Miguel-Hidalgo JJ, Wei J, Dilley G, Pittman SD, Meltzer HY, Overholser JC, Roth BL, Stockmeier CA. Morphometric evidence for neuronal and glial prefrontal cell pathology in major depression. *Biol Psychiatry*. 1999;45(9):1085-1098.
3. Kumar A, Bilker W, Jin Z, Udupa J. Atrophy and high intensity lesions: complementary neurobiological mechanisms in late-life major depression. *Neuropsychopharmacology*. 2000;22(3):264-274.
4. Alexopoulos GS, Meyers BS, Young RC, Campbell S, Silbersweig D, Charlson M. "Vascular depression" hypothesis. *Arch Gen Psychiatry*. 1997;54(10):915-922.
5. Ballmaier M, Narr KL, Toga AW, Elderkin-Thompson V, Thompson PM, Hamilton L, Haroon E, Pham D, Heinz A, Kumar A. Hippocampal morphology and distinguishing late-onset from early-onset elderly depression. *Am J Psychiatry*. 2008;165(2):229-237.
6. Ballmaier M, Toga AW, Blanton RE, Sowell ER, Lavretsky H, Peterson J, Pham D, Kumar A. Anterior cingulate, gyrus rectus, and orbitofrontal abnormalities in elderly depressed patients: an MRI-based parcellation of the prefrontal cortex. *Am J Psychiatry*. 2004;161(1):99-108.
7. Krishnan KRR, Hays JC, Blazer DG. MRI-defined vascular depression. *Am J Psychiatry*. 1997;154(4):497-501.
8. Qiu WQ, Sun X, Selkoe DJ, Mwamburi DM, Huang T, Bhadela R, Bergethon P, Scott TM, Summergrad P, Wang L, Rosenberg I, Folstein M. Depression is associated with low plasma Aβ42 independently of cardiovascular disease in the homebound elderly. *Int J Geriatr Psychiatry*. 2007;22(6):536-542.
9. Pomara N, Doraiswamy PM, Willoughby LM, Roth AE, Mulsant BH, Sidtis JJ, Mehta PD, Reynolds CF, Pollock BG. Elevation in plasma Aβ42 in geriatric depression: a pilot study. *Neurochem Res*. 2006;31(3):341-349.
10. Pomara N, Sidtis J. Possible therapeutic implication of Aβ disturbances in depression. *Int J Geriatr Psychiatry*. 2007;22(9):931-932.
11. Sun X, Steffens DC, Au R, Folstein M, Summergrad P, Yee J, Rosenberg I, Mwamburi DM, Qiu WQ. Amyloid-associated depression: a prodromal depression of Alzheimer disease? *Arch Gen Psychiatry*. 2008;65(5):542-550.
12. Devanand DP, Sano M, Tang M-X, Taylor S, Gurland BJ, Wilder D, Stern Y, Mayeux R. Depressed mood and the incidence of Alzheimer's disease in the elderly living in the community. *Arch Gen Psychiatry*. 1996;53(2):175-182.

13. Kumar A, Ajilore O, Kepe V, Barrio JR, Small G. Mood, cognition and in vivo protein imaging: the emerging nexus in clinical neuroscience. *Int J Geriatr Psychiatry*. 2008;23(6):555-563.
14. Ownby RL, Crocco E, Acevedo A, John V, Loewenstein D. Depression and risk for Alzheimer disease: systematic review, meta-analysis, and meta-regression analysis. *Arch Gen Psychiatry*. 2006;63(5):530-538.
15. Chen P, Ganguli M, Mulsant BH, DeKosky ST. The temporal relationship between depressive symptoms and dementia: a community-based prospective study. *Arch Gen Psychiatry*. 1999;56(3):261-266.
16. Wilson RS, Barnes LL, Mendes de Leon CF, Aggarwal NT, Schneider JS, Bach J, Pilat J, Beckett LA, Arnold SE, Evans DA, Bennett DA. Depressive symptoms, cognitive decline, and risk of AD in older persons. *Neurology*. 2002;59(3):364-370.
17. Green RC, Cupples LA, Kurz A, Auerbach S, Go R, Sadovnick D, Duara R, Kukull WA, Chui H, Edeki T, Griffith PA, Friedland RP, Bachman D, Farrer L. Depression as a risk factor for Alzheimer disease: the MIRAGE Study. *Arch Neurol*. 2003;60(5):753-759.
18. Alexopoulos GS, Meyers BS, Young RC, Mattis S, Kakuma T. The course of geriatric depression with "reversible dementia": a controlled study. *Am J Psychiatry*. 1993;150(11):1693-1699.
19. Kral VA, Emery OB. Long-term follow-up of depressive pseudodementia of the aged. *Can J Psychiatry*. 1989;34(5):445-446.
20. Bassuk SS, Berkman LF, Wypij D. Depressive symptomatology and incident cognitive decline in an elderly community sample. *Arch Gen Psychiatry*. 1998;55(12):1073-1081.
21. Geerlings MI, Schoevers RA, Beekman AT, Jonker C, Deeg DJ, Schmand B, Adèr HJ, Bouter LM, Van Tilburg W. Depression and risk of cognitive decline and Alzheimer's disease: results of two prospective community-based studies in The Netherlands. *Br J Psychiatry*. 2000;176:568-575.
22. McKhann G, Drachman D, Folstein M, Katzman R, Price D, Stadlan EM; NINCDS-ADRDA Work Group. Clinical diagnosis of Alzheimer's disease: report of the NINCDS-ADRDA Work Group under the auspices of Department of Health and Human Services Task Force on Alzheimer's Disease. *Neurology*. 1984;34(7):939-944.
23. Price JL, Morris JC. Tangles and plaques in nondemented aging and "preclinical" Alzheimer's disease. *Ann Neurol*. 1999;45(3):358-368.
24. Braak H, Braak E. Neuropathological staging of Alzheimer-related changes. *Acta Neuropathol*. 1991;82(4):239-259.
25. Shoghi-Jadid K, Small GW, Agdeppa ED, Kepe V, Ercoli LM, Siddarth P, Read S, Satyamurthy N, Petric A, Huang S-C, Barrio JR. Localization of neurofibrillary tangles and beta-amyloid plaques in the brains of living patients with Alzheimer disease. *Am J Geriatr Psychiatry*. 2002;10(1):24-35.
26. Verhoeff NPLG, Wilson AA, Takeshita S, Trop L, Hussey D, Singh K, Kung HF, Kung M-P, Houle S. In-vivo imaging of Alzheimer disease beta-amyloid with [¹¹C]SB-13 PET. *Am J Geriatr Psychiatry*. 2004;12(6):584-595.
27. Klunk WE, Engler H, Nordberg A, Wang Y, Blomqvist G, Holt DP, Bergström M, Savitcheva I, Huang G-F, Estrada S, Ausén B, Debnath ML, Barletta J, Price JC, Sandell J, Lopresti BJ, Wall A, Koivisto P, Antoni G, Mathis CA, Långström B. Imaging brain amyloid in Alzheimer's disease with Pittsburgh Compound-B. *Ann Neurol*. 2004;55(3):306-319.
28. Shin J, Lee S-Y, Kim S-H, Kim Y-B, Cho S-B. Multitracer PET imaging of amyloid plaques and neurofibrillary tangles in Alzheimer's disease. *Neuroimage*. 2008;43(2):236-244.
29. Tolboom N, van der Flier WM, Yaqub M, Boellaard R, Verwey NA, Blankenstein MA, Windhorst AD, Scheltens P, Lammertsma AA, van Berckel BNM. Relationship of cerebrospinal fluid markers to ¹¹C-PiB and ¹⁸F-FDDNP binding. *J Nucl Med*. 2009;50(9):1464-1470.
30. Small GW, Kepe V, Ercoli LM, Siddarth P, Bookheimer SY, Miller KJ, Lavretsky H, Burggren AC, Cole GM, Vinters HV, Thompson PM, Huang S-C, Satyamurthy N, Phelps ME, Barrio JR. PET of brain amyloid and tau in mild cognitive impairment. *N Engl J Med*. 2006;355(25):2652-2663.
31. Morris JC, Roe CM, Grant EA, Head D, Storandt M, Goate AM, Fagan AM, Holtzman DM, Mintun MA. Pittsburgh compound B imaging and prediction of progression from cognitive normality to symptomatic Alzheimer disease. *Arch Neurol*. 2009;66(12):1469-1475.
32. Petersen RC. Mild cognitive impairment as a diagnostic entity. *J Intern Med*. 2004;256(3):183-194.
33. Nelson ND, Siddarth P, Kepe V, Scheibel KE, Huang SC, Barrio J, Small GW. Positive emission tomography of brain β -amyloid and tau levels in adults with Down syndrome. *Arch Neurol*. 2011;68(6):768-774.
34. Lavretsky H, Siddarth P, Kepe V, Ercoli LM, Miller KJ, Burggren AC, Bookheimer SY, Huang S-C, Barrio JR, Small GW. Depression and anxiety symptoms are associated with cerebral FDDNP-PET binding in middle-aged and older nondemented adults. *Am J Geriatr Psychiatry*. 2009;17(6):493-502.
35. Ercoli LM, Siddarth P, Kepe V, Miller KJ, Huang S-C, Cole GM, Lavretsky H, Bookheimer SY, Kim J, Phelps ME, Barrio JR, Small GW. Differential FDDNP PET patterns in nondemented middle-aged and older adults. *Am J Geriatr Psychiatry*. 2009;17(5):397-406.
36. Merrill D, Siddarth P, Ercoli L, Burggren A, Kepe V, Miller K, Kim J, Lavretsky H, Thompson PS, Huang S-C, Bookheimer S, Barrio J, Small G. Vascular risk and PET of brain amyloid and tau in persons without dementia. Paper presented at: 49th Annual Meeting of the American College of Neuropsychopharmacology; December 6, 2010; Miami Beach, FL.
37. Panza F, Frisardi V, Capurso C, D'Introno A, Colacicco AM, Imbimbo BP, Santamato A, Vendemiale G, Seripa D, Pilotto A, Capurso A, Solfrizzi V. Late-life depression, mild cognitive impairment, and dementia: possible continuum? *Am J Geriatr Psychiatry*. 2010;18(2):98-116.
38. Ballmaier M, Kumar A, Thompson PM, Narr KL, Lavretsky H, Estanol L, DeLuca H, Toga AW. Localizing gray matter deficits in late-onset depression using computational cortical pattern matching methods. *Am J Psychiatry*. 2004;161(11):2091-2099.
39. Andreescu C, Butters MA, Begley A, Rajji T, Wu M, Meltzer CC, Reynolds CF III, Aizenstein H. Gray matter changes in late life depression—a structural MRI analysis. *Neuropsychopharmacology*. 2008;33(11):2566-2572.
40. Kumar A, Gupta RC, Albert Thomas M, Alger J, Wyckoff N, Hwang S. Biophysical changes in normal-appearing white matter and subcortical nuclei in late-life major depression detected using magnetization transfer. *Psychiatry Res*. 2004;130(2):131-140.
41. Gunning-Dixon FM, Hoptman MJ, Lim KO, Murphy CF, Klimstra S, Latoussakis V, Majcher-Tascio M, Hrabe J, Ardekani BA, Alexopoulos GS. Macromolecular white matter abnormalities in geriatric depression: a magnetization transfer imaging study. *Am J Geriatr Psychiatry*. 2008;16(4):255-262.
42. Hamilton M. A rating scale for depression. *J Neurol Neurosurg Psychiatry*. 1960;23:56-62.
43. Folstein MF, Folstein SE, McHugh PR. "Mini-Mental State": a practical method for grading the cognitive state of patients for the clinician. *J Psychiatr Res*. 1975;12(3):129-138.
44. Liu J, Kepe V, Žabjek A, Petrič A, Padgett HC, Satyamurthy N, Barrio JR. High-yield, automated radiosynthesis of 2-(1-[2-[¹⁸F]fluoroethyl)(methylamino)-2-naphthyl]ethylidene)malononitrile (¹⁸F)FDDNP) ready for animal or human administration. *Mol Imaging Biol*. 2007;9(1):6-16.
45. Kepe V, Barrio JR, Huang S-C, Ercoli L, Siddarth P, Shoghi-Jadid K, Cole GM, Satyamurthy N, Cummings JL, Small GW, Phelps ME. Serotonin 1A receptors in the living brain of Alzheimer's disease patients. *Proc Natl Acad Sci U S A*. 2006;103(3):702-707.
46. Logan J, Fowler JS, Volkow ND, Wang G-J, Ding Y-S, Alexoff DL. Distribution volume ratios without blood sampling from graphical analysis of PET data. *J Cereb Blood Flow Metab*. 1996;16(5):834-840.
47. Talairach J, Tournoux P. *Co-planar Stereotaxic Atlas of the Human Brain: 3-Dimensional Proportional System: An Approach to Cerebral Imaging*. New York, NY: Thieme Medical Publishers; 1988.
48. Bender R, Lange S. Adjusting for multiple testing—when and how? *J Clin Epidemiol*. 2001;54(4):343-349.
49. Small GW, Siddarth S, Kepe V, Ercoli LM, Lavretsky H, Miller KJ, Burggren AC, Bookheimer SY, Huang S-C, Barrio JR. PET of brain amyloid and tau predicts and tracks future neurodegeneration and cognitive decline in middle-aged and older adults. Paper presented at: 48th Annual Meeting of the American College of Neuropsychopharmacology; December 9, 2009; Hollywood, FL.
50. Taylor WD, MacFall JR, Payne ME, McQuoid DR, Provenza JM, Steffens DC, Krishnan KRR. Late-life depression and microstructural abnormalities in dorsolateral prefrontal cortex white matter. *Am J Psychiatry*. 2004;161(7):1293-1296.
51. Alexopoulos GS, Kiosses DN, Choi SJ, Murphy CF, Lim KO. Frontal white matter microstructure and treatment response of late-life depression: a preliminary study. *Am J Psychiatry*. 2002;159(11):1929-1932.
52. Taylor WD, Züchner S, McQuoid DR, Payne ME, MacFall JR, Steffens DC, Speer MC, Krishnan KR. The brain-derived neurotrophic factor VAL66MET polymorphism and cerebral white matter hyperintensities in late-life depression. *Am J Geriatr Psychiatry*. 2008;16(4):263-271.
53. van Oijen M, Hofman A, Soares HD, Koudstaal PJ, Breteler MMB. Plasma $A\beta_{1-40}$ and $A\beta_{1-42}$ and the risk of dementia: a prospective case-cohort study. *Lancet Neurol*. 2006;5(8):655-660.
54. Mayeux R, Honig LS, Tang MX, Manly J, Stern Y, Schupf N, Mehta PD. Plasma $A\beta_{40}$ and $A\beta_{42}$ and Alzheimer's disease: relation to age, mortality, and risk. *Neurology*. 2003;61(9):1185-1190.
55. Graff-Radford NR, Crook JE, Lucas J, Boeve BF, Knopman DS, Ivnik RJ, Smith GE, Younkin LH, Petersen RC, Younkin SG. Association of low plasma $A\beta_{42}/A\beta_{40}$ ratios with increased imminent risk for mild cognitive impairment and Alzheimer disease. *Arch Neurol*. 2007;64(3):354-362.
56. Pomara N, Murali Doraiswamy P. Does increased platelet release of $A\beta$ peptide contribute to brain abnormalities in individuals with depression? *Med Hypotheses*. 2003;60(5):640-643.
57. Kita Y, Baba H, Maeshima H, Nakano Y, Suzuki T, Arai H. Serum amyloid β protein in young and elderly depression: a pilot study. *Psychogeriatrics*. 2009;9(4):180-185.
58. Blasko I, Kemmler G, Jungwirth S, Wichart I, Krampla W, Weissgram S, Jellinger KA, Tragl KH, Fischer P. Plasma amyloid beta-42 independently predicts both late-onset depression and Alzheimer disease. *Am J Geriatr Psychiatry*. 2010;18(11):973-982.
59. Selkoe DJ. The ups and downs of $A\beta$. *Nat Med*. 2006;12(7):758-759.
60. Casoli T, Di Stefano G, Giorgetti B, Grossi Y, Ballestri M, Fattoretti P, Bertoni-Freddari C. Release of β -amyloid from high-density platelets: implications for Alzheimer's disease pathology. *Ann N Y Acad Sci*. 2007;1096(1):170-178.
61. DeMattos RB, Bales KR, Cummins DJ, Paul SM, Holtzman DM. Brain to plasma amyloid- β efflux: a measure of brain amyloid burden in a mouse model of Alzheimer's disease. *Science*. 2002;295(5563):2264-2267.
62. Chen M, Inestrosa NC, Ross GS, Fernandez HL. Platelets are the primary source of amyloid β -peptide in human blood. *Biochem Biophys Res Commun*. 1995;213(1):96-103.
63. Butters MA, Klunk WE, Mathis CA, Price JC, Ziolkowski SK, Hoge JA, Tsopelas ND, Lopresti BJ, Reynolds CF III, DeKosky ST, Meltzer CC. Imaging Alzheimer pathology in late-life depression with PET and Pittsburgh Compound-B. *Alzheimer Dis Assoc Disord*. 2008;22(3):261-268.