

Brain Gray Matter Deficits at 33-Year Follow-up in Adults With Attention-Deficit/Hyperactivity Disorder Established in Childhood

Erika Proal, PhD; Philip T. Reiss, PhD; Rachel G. Klein, PhD; Salvatore Mannuzza, PhD; Kristin Gotimer, MPH; Maria A. Ramos-Olagastgi, PhD; Jason P. Lerch, PhD; Yong He, PhD; Alex Zijdenbos, PhD; Clare Kelly, PhD; Michael P. Milham, MD, PhD; F. Xavier Castellanos, MD

Context: Volumetric studies have reported relatively decreased cortical thickness and gray matter volumes in adults with attention-deficit/hyperactivity disorder (ADHD) whose childhood status was retrospectively recalled. We present, to our knowledge, the first prospective study combining cortical thickness and voxel-based morphometry in adults diagnosed as having ADHD in childhood.

Objectives: To test whether adults with combined-type childhood ADHD exhibit cortical thinning and decreased gray matter in regions hypothesized to be related to ADHD and to test whether anatomic differences are associated with a current ADHD diagnosis, including persistent vs remitting ADHD.

Design: Cross-sectional analysis embedded in a 33-year prospective follow-up at a mean age of 41.2 years.

Setting: Research outpatient center.

Participants: We recruited probands with ADHD from a cohort of 207 white boys aged 6 to 12 years. Male comparison participants (n=178) were free of ADHD in childhood. We obtained magnetic resonance images in 59 probands and 80 comparison participants (28.5% and 44.9% of the original samples, respectively).

Main Outcome Measures: Whole-brain voxel-based morphometry and vertexwise cortical thickness analyses.

Results: The cortex was significantly thinner in ADHD probands than in comparison participants in the dorsal attentional network and limbic areas (false discovery rate < 0.05, corrected). In addition, gray matter was significantly decreased in probands in the right caudate, right thalamus, and bilateral cerebellar hemispheres. Probands with persistent ADHD (n=17) did not differ significantly from those with remitting ADHD (n=26) (false discovery rate < 0.05). At uncorrected $P < .05$, individuals with remitting ADHD had thicker cortex relative to those with persistent ADHD in the medial occipital cortex, insula, parahippocampus, and prefrontal regions.

Conclusions: Anatomic gray matter reductions are observable in adults with childhood ADHD, regardless of the current diagnosis. The most affected regions underpin top-down control of attention and regulation of emotion and motivation. Exploratory analyses suggest that diagnostic remission may result from compensatory maturation of prefrontal, cerebellar, and thalamic circuitry.

Arch Gen Psychiatry. 2011;68(11):1122-1134

VOLUMETRIC STUDIES IN CHILDREN with attention-deficit/hyperactivity disorder (ADHD) have consistently found global reductions of total brain volume, with the prefrontal cortex, anterior and posterior cingulate cortex, basal ganglia, cerebellum, and parietotemporal regions particularly affected relative to typical development in healthy children.¹⁻⁴ These findings are consistent with a model of ADHD as a disorder of frontal-striatal-cerebellar circuitry. The diagnosis of ADHD requires onset in childhood, but persistence of ADHD into adulthood is now well documented.^{4,5} This longitudinal course combined with smaller brain vol-

umes in children with ADHD have raised questions about brain development into adulthood.

A sparse literature on brain anatomy in adults with ADHD also reports decreased volumes in the orbitofrontal cortex,⁶ anterior cingulate cortex (ACC),^{7,8} dorsolateral prefrontal cortex,⁷ superior frontal cortex, and cerebellum.⁹ Complementary analyses of cortical thickness¹⁰ reveal overall decreased cortical thickness in children¹⁰⁻¹³ and adults with ADHD, with reductions in ACC, medial frontal regions, and parietotemporo-occipital cortex.¹¹⁻¹³ Recently, Almeida et al¹⁴ found cortical thinning in the right frontal lobe of children, adolescents, and adults with ADHD.

Author Affiliations are listed at the end of this article.

Investigations of structural brain abnormalities in adults, for want of a better method, have relied on adults' retrospective recall of their childhood status.^{6-9,15-19} The documented inaccuracies of such reports²⁰ highlight the advantage of assessing brain anatomy in individuals with established childhood-onset ADHD prospectively followed up into adulthood. In addition, clinical ADHD remits in a substantial proportion of individuals followed up into adulthood^{21,22}; however, to our knowledge, the neurobiological mechanisms of remission have not been previously examined in middle adulthood.

We report cortical thickness and voxel-based morphometry (VBM) analyses in the largest sample to date of adults with childhood ADHD diagnoses (mean age, 8.3 years) consistent with *DSM-IV*. Follow-up assessments occurred at the mean ages of 18.4, 25.0, and 41.2 years (18FU, 25FU, and 41FU, respectively). At the 18FU, a comparison group free of childhood ADHD and matched for age, sex, ethnicity, and childhood social class was recruited.^{21,23-26} Systematic diagnostic assessments at each follow-up were conducted by interviewers blinded to history and group membership. At the 41FU, we conducted anatomic brain magnetic resonance imaging (MRI) in probands with childhood ADHD and a comparison group. We performed analyses based on childhood diagnosis and current diagnostic status in adulthood. Our primary aims were (1) to test whether adults with a childhood diagnosis of combined-type ADHD (probands), relative to the comparison group, exhibit cortical thinning and decreased gray matter (GM) volume in regions hypothesized to be related to ADHD^{11-13,17} and (2) to assess whether anatomic differences are associated with a current ADHD diagnosis.

METHODS

PARTICIPANTS

The ADHD group originally included 207 white boys aged 6 to 12 years who were referred to a research clinic from 1970 to 1977 (mean age, 8.3 years). Briefly, they were referred by schools because of behavioral problems and had elevated parent and teacher ratings of hyperactivity, an IQ of at least 85, and a diagnosis of hyperkinetic reaction of childhood.^{27,28} Children with a pattern of aggressive or antisocial behavior were excluded to rule out comorbid conduct disorder. Further details of proband characteristics appear in previous publications.^{26,29} These participants underwent assessment at mean (SD) ages of 18.4 (1.3), 25.0 (1.3), and 41.2 (2.7) years. Comparison male participants (n=178) were recruited at the 18FU. Medical center pediatric medical records were reviewed for children undergoing routine physical examinations from 1970 through 1977 at 6 through 12 years of age, group matched for the probands' race, childhood socioeconomic status, and geographical residence. Parents of suitable children (by then adolescents) were telephoned, informed of the study, and recruited, conditional on parent interest and no reported teacher complaints about their child's behavior in elementary school. The refusal rate was low (about 5%).

41FU ASSESSMENT

On average, 33 years after the initial childhood diagnosis, clinical data were obtained for 135 male probands (65.5% of the original sample, 70.3% of those living) and 136 male comparison participants (76.4% of those recruited in adolescence, 78.6%

Table 1. Derivation of MRI Sample

	No. (%) of Participants	
	ADHD Male Probands	Male Comparison Participants
Initial sample	207 (100.0)	178 (100.0)
Unable to locate	21 (10.1)	20 (11.2)
Deceased	15 (7.2)	5 (2.8)
Incarcerated	6 (2.9)	1 (0.6)
Refused MRI	43 (20.8)	34 (19.1)
No evaluation before termination of funding	29 (14.0)	22 (12.4)
Subtotal available for scan	93 (44.9)	96 (53.9)
MRI exclusions		
Size, too large for scanner	17 (8.2)	6 (3.4)
Claustrophobic	7 (3.4)	3 (1.7)
Metal contraindications	3 (1.4)	1 (0.6)
Failed scan quality criteria	7 (3.4)	6 (3.4)
Total With Usable Data	59 (28.5)	80 (44.9)

Abbreviations: ADHD, attention-deficit/hyperactivity disorder; MRI, magnetic resonance imaging.

of those living). Major *DSM-IV* disorders and multiple aspects of function were assessed for the interval from the 25FU to the 41FU by trained clinicians blinded to all antecedent data. A special interview, the Assessment of Adult Attention-Deficit/Hyperactivity Disorder, was developed for diagnosing *DSM-IV* ADHD in adults (the Instrument and a supplementary Description are available at the authors' Web site at http://www.AboutOurKids.org/Research/Research_Publications/Proal_et_al_2011). *Current ADHD* was defined as meeting *DSM-IV* criteria during the preceding 6 months. Participants were invited to take part in an anatomic MRI study. Owing to refusals and MRI exclusions (**Table 1**), we obtained MRIs in 59 ADHD probands and 80 comparison participants. Nearly all probands (57 [97%] of those scanned) were treated with methylphenidate hydrochloride in childhood from ages 6 to 12 years for an average of 2.2 years.³⁰ (eTable 1, available at the authors' Web site, gives further details of childhood medication treatment, including thioridazine hydrochloride.²⁶) All participants provided written informed consent as approved by the New York University Langone School of Medicine institutional review board.

To test whether cortical thickness differed as a function of current ADHD, we subdivided probands into the following 3 subgroups: (1) those who met diagnostic criteria for *DSM-IV* ADHD at the 41FU (persistent ADHD group; 17 participants, including 7 with predominantly inattentive, 6 with predominantly hyperactive/impulsive, and 4 with combined-type ADHD); (2) those who did not (remitting ADHD group; 26 participants); and (3) those diagnosed as having ADHD not otherwise specified (ADHD-NOS group; 16 participants) (see the supplementary Methods available at the authors' Web site). The comparison group was dichotomized into individuals who did not meet criteria for any type of ADHD (non-ADHD comparison group; 57 participants) and those who were diagnosed with ADHD-NOS (comparison group with ADHD; 23 participants). Although all probands and all comparison participants were included in initial vertexwise and VBM analyses, subgroup analyses focused on current diagnostic status. Accordingly, probands and comparison participants with current ADHD-NOS, which is not well-defined and did not differ between groups (16 of 59 [27%] and 23 of 80 [29%], respectively), were excluded from subgroup analyses.

IMAGING

We obtained 41 anatomic T1-weighted images in 20 ADHD probands and 21 comparison participants using a scanner with an 8-channel head coil (3T Siemens Trio; Siemens Medical Solutions USA Inc, Malvern, Pennsylvania) and 98 scans in 39 ADHD probands and 59 comparison participants using a scanner with a single-channel head coil (3T Siemens Allegra; Siemens Medical Solutions USA Inc). Proportions did not differ significantly across scanners, ($\chi^2=0.96$, $P=.33$), with the following parameters: repetition time, 2100 milliseconds; flip angle, 12°; slice thickness, 1.5 mm; inversion time, 1100 milliseconds; matrix, 192 × 256; and field of view, 172.5 mm. The only parameter that differed was echo time, which was 3.87 milliseconds on the Trio scanner and 3.90 milliseconds on the Allegra scanner.

Structural MRIs were preprocessed through the fully automated CIVET–Montreal Neurological Institute (MNI) pipeline.^{31–34} The initial preprocessing step was to mask MRI native images using an automated brain extraction method.³⁵ Data were corrected for nonuniformity artifacts and registered to stereotactic space (MN152) using a 9-parameter linear transformation. Voxelwise tissue type classification was performed using a neural network classifier followed by a partial volume estimation step.^{33,36}

For VBM, the classified tissue maps were blurred with a gaussian kernel of 10 mm full width at half maximum. Cortical thickness measures were assessed using a fully automated algorithm that defines the distances between a set of vertices at the white matter (WM) surface and then expands outward to find the intersection with GM to generate surface meshes that represent WM and GM interfaces.³⁷ A total of 40 962 linked vertices were calculated per hemisphere. Each individual cortical thickness map was blurred using a 30-mm surface-based diffusion-smoothing kernel to reduce noise while preserving anatomic location, as this method produces less volumetric blurring than the equivalent gaussian kernel.³⁸

STATISTICAL ANALYSES

Global Cortical Thickness

We obtained a single global cortical thickness value for each participant by averaging across all 81 924 vertices. Linear regression models controlled for age at the time of imaging and for the scanner model (Trio vs Allegra).

Vertexwise and VBM Analyses

Following the study aims, group analyses tested for regional differences in cortical thickness and GM density between (1) all adults with a childhood diagnosis of combined-type ADHD and all comparison groups; (2) persistent ADHD vs the non-ADHD comparison group; (3) remitting ADHD vs the non-ADHD comparison group; and (4) participants with persistent vs those with remitting ADHD. For each comparison, we regressed cortical thickness at each of 81 924 vertices or whole-brain GM density on group, controlling for age at the time of imaging and for the scanner model. The software package *mmi.cortical.statistics* (Brain Imaging Centre, MNI; <http://www.bic.mni.mcgill.ca>) for the R environment³⁹ was used for cortical thickness analyses, and the FMRIB Software Library (available at <http://www.fmrib.ox.ac.uk>) tool *Feat*, for VBM. Results were thresholded using a false discovery rate (FDR) of 0.05.^{40,41} Maps of *t* statistics for group effects on cortical thickness at each vertex or GM density at each voxel were projected onto an average brain template revealing clusters that differed significantly between groups. We retained clusters comprising at least 50 contiguous vertices for cortical thickness⁴² and 5 voxels for VBM.

Region-Based Analyses of Cortical Thickness and VBM

To test whether childhood or current ADHD was associated with significant differences in specific regions, we performed post hoc region-of-interest–based analyses. For each participant, we computed the mean cortical thickness or GM density within each cluster exhibiting significant (FDR < 0.05) group differences in primary analyses by averaging across all vertices or voxels within each cluster. We then compared the diagnostic subgroups of probands (participants with persistent and those with remitting ADHD) and the comparison group without current ADHD, Bonferroni corrected for the number of clusters. For completeness, eTable 2 (available on the authors' Web site) contains means and SDs for the subgroups with current ADHD-NOS.

Exploratory Analyses of Cortical Thickness

To further investigate primary hypotheses for which no vertices with FDR of less than 0.05 were found, we reexamined subgroup differences heuristically using an uncorrected threshold of $P < .05$ with a cluster threshold of 50 vertices.⁴² Because of significant between-group differences in IQ, we confirmed cortical thickness results by also adjusting for IQ.

RESULTS

Table 1 summarizes the derivation of the sample. A larger proportion of comparison participants (80 of 178 [44.9%] originally enrolled participants) than probands (59 of 207 [28.5%]) had analyzable MRIs. This discrepancy reflects a significantly higher rate of unavoidable factors in probands (55 of 207 [26.6%]) (ie, deaths, incarcerations, and MRI exclusions) than in comparison participants (22 of 178 [12.4%]) ($\chi^2=12.08$; $P < .001$). By contrast, rates of refusal and failure to schedule or to locate study participants did not differ significantly (93 of 207 probands [44.9%] vs 76 of 178 comparison participants [42.7%]). Accordingly, results are based on anatomic images from 59 ADHD probands and 80 comparison participants.

We compared diagnoses and demographic information at the 18FU of participants who underwent scanning and those who did not (data were available for 57 of 59 probands and for all 80 comparison participants; see eTable 3, available at the authors' Web site). Within the proband and comparison groups, individuals who did and did not undergo scanning did not differ significantly on prevalence of ADHD, antisocial personality disorder, mood or anxiety disorders, any *DSM-III* disorders, age at referral, IQ, socioeconomic status, or Teacher Connors Hyperactivity Factor score. However, probands undergoing scanning had significantly higher rates of alcohol and nonalcohol substance use disorder and any substance use disorder than did probands who did not undergo scanning (see eTable 3, available at the authors' Web site).

DEMOGRAPHICS

Probands and comparison participants did not differ significantly in age at the time of imaging or in lifetime prevalence of substance abuse or dependence (**Table 2**). As expected, probands and comparison participants differed

Table 2. Demographic Data

Characteristic ^a	Mean (SD)		<i>t</i> Statistic	2-Tailed <i>P</i> Value
	ADHD Male Probands (n=59)	Male Comparison Participants (n=80)		
Age at follow-up, y	41.1 (2.7)	41.3 (3.1)	0.51	.61
Socioeconomic status at follow-up ^b	3.37 (1.1)	2.48 (1.0)	5.01	.001
Educational attainment ^c	13.5 (2.4)	15.6 (2.3)	5.31	.001
WAIS full-scale IQ at 18FU ^d	104 (13)	113 (13)	3.58	.001
WASI full-scale IQ at 41FU ^e	101 (13)	110 (15)	3.42	.001
Global Assessment Scale rating ^f	63.4 (12.5)	71.4 (10.5)	4.05	.001

Abbreviations: ADHD, attention-deficit/hyperactivity disorder; WAIS, Wechsler Adult Intelligence Scale; WASI, Wechsler Abbreviated Scale of Intelligence; 18FU, 18-year follow-up; 41FU, 41-year follow-up.

^aAll ADHD probands and comparison participants were white.

^bCalculated by means to the Hollingshead and Redlich scale (1958), based on the participant's education and occupation.

^cIndicates highest grade completed.

^dObtained for 39 of the 59 probands (66%) and all comparison participants.

^eObtained for 54 of the 59 probands (92%) and 73 of the 80 comparison participants (91%).

^fGlobal Assessment Scale⁴³ rating was completed by the blinded clinician who conducted the mental status and diagnostic assessments. The scale ranges from 0 to 100; higher ratings indicate better functioning, and values between 61 and 70 indicate some mild symptoms or some difficulty in social or occupational functioning.

significantly in IQ in childhood and 41FU assessments (see eTable 5, available at the authors' Web site, for demographics of subgroups based on current diagnosis and for current substance use and comorbid diagnoses).

GLOBAL CORTICAL THICKNESS

Surfacewide mean cortical thickness was significantly lower in probands (n=59) than in comparison participants (n=80) (mean [SD], 3.18 [0.11] and 3.24 [0.11] mm, respectively; $P < .001$ in regression controlling for age and scanner; Cohen $d = 0.54$). At the 41FU, probands with persistent ADHD differed significantly from the non-ADHD comparison group (3.14 [0.13] and 3.25 [0.10] mm, respectively; $P < .001$; Cohen $d = 1.02$). The remitting ADHD group (3.20 [0.11] mm) also differed from the non-ADHD comparison group in overall cortical thickness ($P = .04$; Cohen $d = 0.48$). However, participants with persistent ADHD and those with remitting ADHD did not differ significantly ($P = .10$; Cohen $d = 0.51$).

VERTEXWISE ANALYSES OF CORTICAL THICKNESS

Figure 1 A displays the multiple clusters of vertices (detailed in **Table 3**) for which the cortex was significantly thinner (surfacewide $FDR < 0.05$) in ADHD probands; the largest cluster extended from the right precuneus to the precentral gyrus. Other right hemisphere clusters were located in the inferior parietal lobe, temporal pole, and insula. Left hemisphere clusters were located in the superior frontal gyrus/frontal pole, precentral gyrus, insula, temporal pole, and cuneus. There was no instance in which cortical thickness was significantly increased in probands. As shown in eFigure 1 (available at <http://www.archgenpsychiatry.com>) and eTable 6 (available at the authors' Web site), after covarying for IQ (in addition to scanner and age), significant cluster centers remained largely unchanged in location, but the clusters were less extensive.

To assess associations with current ADHD diagnosis, we performed vertexwise comparisons among the different diagnostic subgroups. The 17 individuals with persistent ADHD differed significantly from the 57 non-ADHD comparison participants in most but not all the regions identified in the initial inclusive analyses (Table 3 and Figure 1B). In addition, this analysis revealed thinner cortex related to persistent ADHD in the left medial occipital cortex and right subgenual ACC. When we used $FDR < 0.05$ as a threshold, participants with remitting ADHD (n=26) did not differ significantly from the non-ADHD comparison group; participants with persistent ADHD and those with remitting ADHD also did not differ in any region at this threshold. There were no vertices at which cortical thickness was significantly associated with lifetime or current substance abuse diagnoses, dimensional measures of substance abuse, lifetime smoking history, or thioridazine treatment, and there were no significant interactions between group and scanner for any cortical or VBM measures.

REGION-BASED ANALYSES OF CORTICAL THICKNESS

To examine potential differences associated with remission from childhood ADHD, we focused on the clusters in which ADHD probands exhibited significantly thinner cortex than comparison participants ($FDR < 0.05$). Participants with remitting ADHD and those with persistent ADHD had a thinner cortex than did those in the non-ADHD comparison group, with medium to large effect sizes. Average effect sizes between individuals with persistent ADHD and the non-ADHD comparison group (Cohen $d = 0.73$) were larger than for participants with remitting ADHD (Cohen $d = 0.52$), although all confidence intervals overlapped (data not shown); individuals with persistent ADHD and those with remitting ADHD did not differ significantly from each other in any cluster at $FDR < 0.05$ (Table 3).

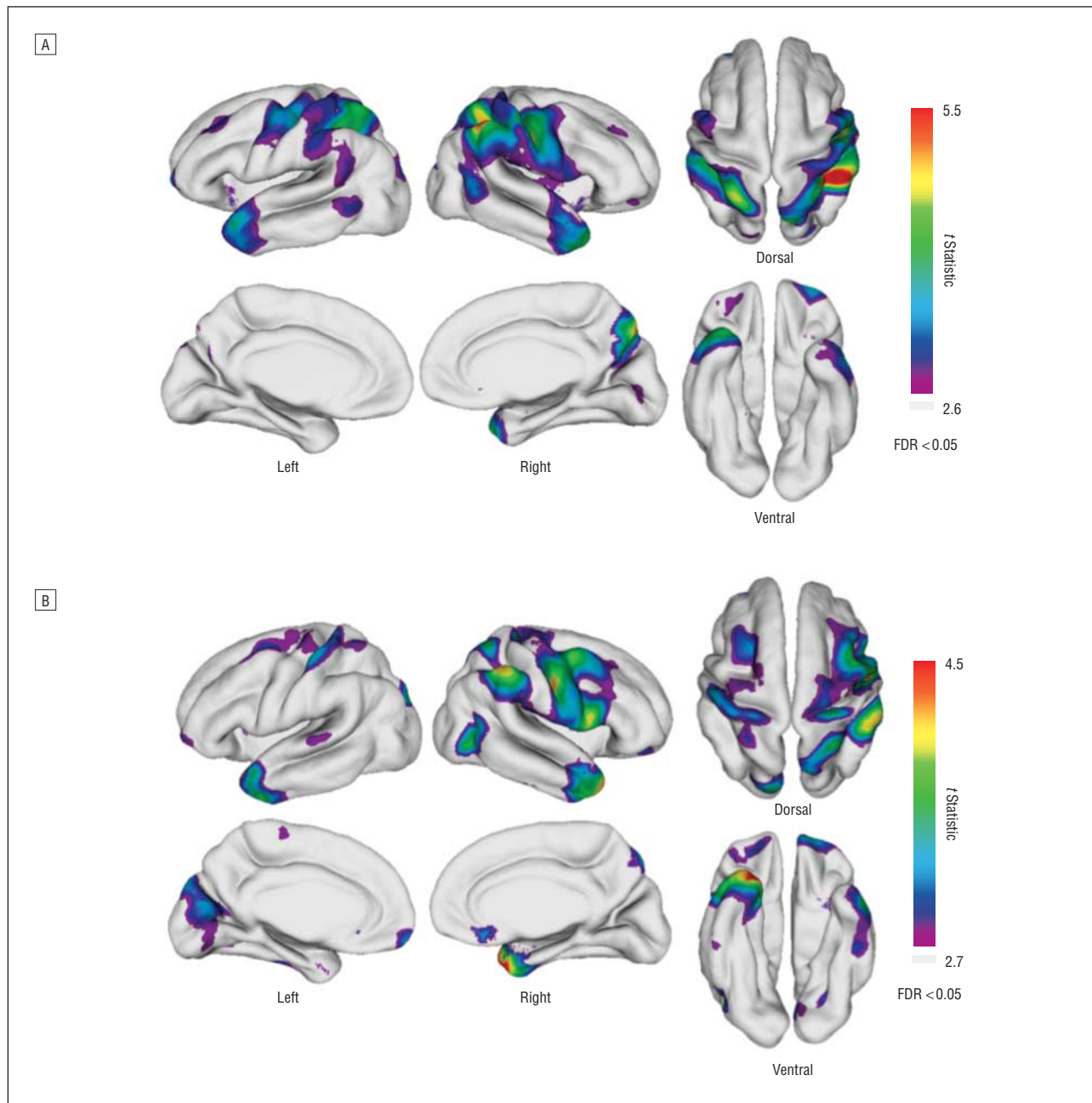


Figure 1. Maps of t statistics depict significant cortical thinning in attention-deficit/hyperactivity disorder (ADHD). A, Significant cortical thinning in the probands with ADHD ($n=59$) vs comparison participants ($n=80$). B, Significant cortical thinning in probands with persistent ADHD ($n=17$) vs the non-ADHD comparison group ($n=57$). The false discovery rate (FDR) threshold depends on the data and is different for the right and left hemispheres. The t statistics at the lowest FDR threshold are projected across each hemisphere for each comparison.

EXPLORATORY VERTEXWISE ANALYSES

When vertexwise results were thresholded at $P < .05$ (uncorrected), we observed a thinner cortex for participants with persistent ADHD vs those with remitting ADHD in the insula, bilateral temporal cortex including the right temporal pole, left occipital Brodmann area (BA) 19, orbitofrontal cortex, and medial ACC (**Figure 2**; see also eTable 7, available at the authors' Web site). There were no regions exceeding our cluster size threshold of 50 vertices in which participants with remitting ADHD exhibited thinner cortex than those with persistent ADHD.

EXPLORATORY REGION-BASED ANALYSES

In the clusters that differentiated individuals with persistent ADHD from those with remitting ADHD in exploratory vertexwise analyses, participants with persistent ADHD differed markedly from the non-ADHD comparison group (average Cohen $d=0.75$), whereas individuals with remitting ADHD did not (average Cohen $d=0.03$; $t_9=8.26$; $P < .001$). Relative to comparison participants, those with remitting ADHD had (nonsignificantly) greater cortical thickness in the left superior temporal gyrus extending to the insula and orbitofrontal

Table 3. Cortical Thickness Values for Significant Clusters for Subgroups Defined by Current ADHD Diagnostic Status in Middle Adulthood^a

Regions	MNI x, y, z Coordinates (No. of Vertices)	Groups, Mean (SD)			Comparison Group vs Persistent ADHD Group		Comparison Group vs Remitting ADHD Group		Remitting vs Persistent ADHD Groups	
		Non-ADHD Comparison Group (n=57)	Probands With Persistent ADHD (n=17)	Probands With Remitting ADHD (n=26)	P Value	ES	P Value	ES	P Value	ES
Left superior parietal, BA7	-26, -55, 68 (4290)	2.97 (0.13)	2.85 (0.17)	2.86 (0.13)	.004	0.83	<.001	0.88	.98	0.01
Left precentral gyrus, BA6	-35, 37, 36 (784)	3.35 (0.13)	3.26 (0.15)	3.26 (0.16)	.02	0.65	.006	0.67	.92	-0.03
Left superior temporal gyrus, BA38	-54, 10, -22 (915)	3.80 (0.19)	3.60 (0.23)	3.66 (0.19)	.001	0.98	.002	0.75	.40	0.26
Left frontal pole, BA10	-31, 62, -6 (638)	3.23 (0.18)	3.06 (0.18)	3.11 (0.23)	.001	0.96	.01	0.62	.45	0.24
Left cuneus, BA19	-13, -91, 35 (618)	2.78 (0.20)	2.65 (0.17)	2.73 (0.16)	.02	0.63	.32	0.23	.13	0.48
Left precuneus, BA31	-6, -65, 30 (62)	3.35 (0.20)	3.23 (0.19)	3.26 (0.15)	.03	0.62	.03	0.53	.63	0.15
Right precuneus, BA7	10, -73, 51 (1148)	3.23 (0.16)	3.12 (0.13)	3.15 (0.15)	.01	0.73	.04	0.49	.43	0.25
Right inferior parietal, BA40	49, -40, 50 (4836)	3.03 (0.14)	2.91 (0.18)	2.93 (0.14)	.007	0.77	.002	0.74	.83	0.07
Right superior temporal gyrus, BA38	30, 15, -40 (1141)	3.87 (0.27)	3.62 (0.25)	3.75 (0.22)	.001	0.96	.04	0.48	.08	0.56
Right temporal gyrus extending to insula, BA13	48, -1, -3 (315)	3.81 (0.21)	3.69 (0.24)	3.72 (0.21)	.049	0.55	.053	0.46	.75	0.10
Right precentral gyrus, BA6	58, 0, 36 (315)	3.41 (0.15)	3.27 (0.19)	3.35 (0.18)	.003	0.86	.11	0.38	.21	0.40
Right frontal pole, BA10	27, 47, 32 (98)	3.37 (0.16)	3.28 (0.17)	3.27 (0.18)	.06	0.53	.02	0.56	.91	-0.04
Right middle frontal gyrus, BA9	25, 47, -14 (130)	3.36 (0.20)	3.19 (0.18)	3.33 (0.17)	.002	0.90	.50	0.16	.01	0.83
Right occipital, BA19	27, -87, 26 (210)	2.96 (0.20)	2.86 (0.19)	2.87 (0.19)	.10	0.47	.08	0.42	.86	0.05
Right occipital, BA18	10, -80, 10 (94)	2.79 (0.20)	2.69 (0.21)	2.71 (0.19)	.08	0.49	.08	0.42	.78	0.09

Abbreviations: ADHD, attention-deficit/hyperactivity disorder; BA, Brodmann area; ES, effect size; MNI, Montreal Neurological Institute.

^aIncludes results for regions that survived false discovery rate of less than 0.05 and extent of more than 50 vertices in analyses of the entire sample (Figure 1A). The comparison group included study participants who did not meet criteria for any type of ADHD at the 41-year follow-up longitudinal assessment. P values surviving Bonferroni correction for multiple comparisons or ES > 0.50 are indicated in boldface.

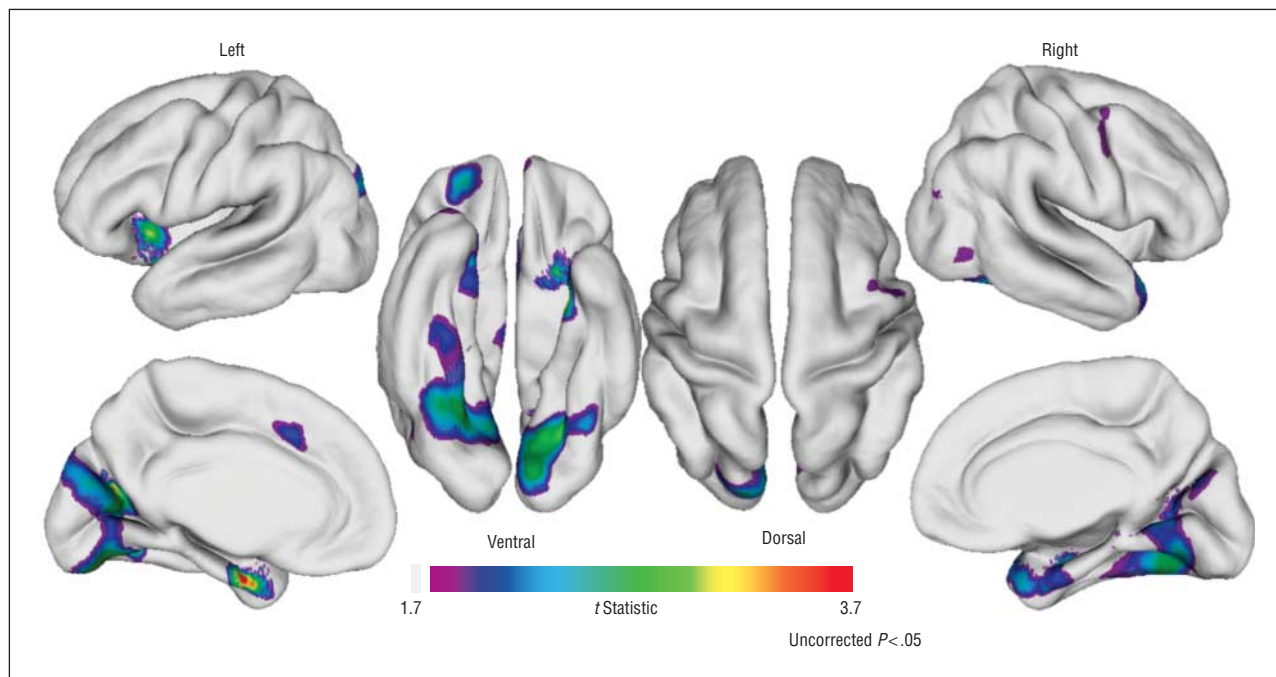


Figure 2. Exploratory uncorrected analyses ($P < .05$) reveal regions in which probands with remitting attention-deficit/hyperactivity disorder (ADHD) ($n = 27$) exhibit thicker cortex than in probands with persistent ADHD ($n = 17$). Peaks and coordinates of clusters are depicted in eTable 7 at the authors' Web site.

cortex, left parahippocampus, left ACC, and left medial occipital cortex (see eTable 7, available at the authors' Web site).

VOXEL-BASED MORPHOMETRY

As shown in **Table 4** and **Figure 3**, GM density was significantly greater ($FDR < 0.05$) for comparison par-

ticipants than for the ADHD probands in many of the same regions identified through cortical thickness analyses, as well as in subcortical regions inaccessible to cortex-based measures. **Figure 4** displays decreased GM in probands in the right caudate, right thalamus, and bilateral cerebellar hemispheres. Voxel-based morphometric analyses of diagnostic subgroups or of medication treatment in childhood with methylphenidate or thioridazine did

Table 4. Gray Matter Density Within Clusters for Subgroups Defined by Current ADHD Diagnostic Status in Mid-Adulthood^a

Regions	Maximum z Score	MNI Peak x, y, z Coordinates (No. of Voxels)	Groups, Mean (SD)			Comparison vs Persistent ADHD Groups		Comparison vs Remitting ADHD Groups		Remitting vs Persistent ADHD Groups	
			Non-ADHD Comparison Participants (n=57)	Probands With Persistent ADHD (n=17)	Probands With Remitting ADHD (n=26)	P Value	ES	P Value	ES	P Value	ES
Left superior parietal, BA7	5.30	-28, -58, 66 (1747)	0.42 (0.04)	0.39 (0.03)	0.39 (0.05)	.003	0.86	.001	0.78	.99	0
Left cerebellum	4.01	-14, -70, -34 (430)	0.57 (0.15)	0.51 (0.14)	0.56 (0.16)	.15	0.41	.82	0.05	.28	0.34
Left inferior cerebellum	3.44	-32, -42, -58 (41)	0.41 (0.17)	0.28 (0.15)	0.34 (0.18)	.009	0.74	.12	0.38	.27	0.35
Left middle temporal gyrus, BA21	3.32	-48, 10, -42 (32)	0.39 (0.10)	0.33 (0.10)	0.34 (0.11)	.048	0.56	.09	0.41	.68	0.13
Left temporo-occipital, BA37	3.50	-50, -42, -22 (17)	0.60 (0.08)	0.55 (0.09)	0.54 (0.07)	.02	0.64	.002	0.78	.72	-0.10
Brainstem extending to cerebellum	3.37	0, -44, -48 (16)	0.36 (0.14)	0.30 (0.12)	0.32 (0.11)	.10	0.46	.15	0.35	.65	0.14
Left temporoparietoprecuneus, BA35	3.33	-34, -10, -22 (13)	0.75 (0.06)	0.73 (0.06)	0.72 (0.07)	.12	0.44	.03	0.53	.73	-0.10
Left frontal pole, BA10	3.31	-16, 52, 32 (9)	0.45 (0.05)	0.43 (0.06)	0.43 (0.06)	.06	0.52	.04	0.51	.97	0.01
Right parietal postcentral, BA3 extending to BA6	4.70	48, -18, 56 (1196)	0.41 (0.04)	0.37 (0.04)	0.38 (0.05)	<.001	1.04	.003	0.72	.44	0.24
Right cerebellum	3.84	32, -60, -38 (235)	0.51 (0.17)	0.44 (0.14)	0.53 (0.17)	.15	0.41	.58	-0.10	.08	0.56
Right thalamus	3.94	4, -8, 12 (170)	0.73 (0.10)	0.70 (0.09)	0.74 (0.07)	.20	0.36	.54	-0.20	.07	0.59
Right occipital/cuneus, BA18-19	3.88	2, -76, 36 (122)	0.67 (0.05)	0.63 (0.06)	0.65 (0.05)	.005	0.79	.08	0.42	.20	0.41
Right superior frontal gyrus, BA10	4.25	12, 64, 12 (68)	0.47 (0.06)	0.45 (0.04)	0.46 (0.05)	.26	0.31	.40	0.20	.70	0.12
Right frontal lobe, BA6	3.66	12, -12, 78 (32)	0.46 (0.11)	0.41 (0.11)	0.45 (0.14)	.11	0.45	.75	0.08	.32	0.31
Right middle frontal gyrus, BA10 extending to orbitofrontal cortex, BA11	3.41	24, 38, -18 (23)	0.51 (0.06)	0.45 (0.05)	0.47 (0.06)	.001	0.96	.005	0.69	.43	0.25
Right temporal fusiform, BA36	3.23	34, -34, -26 (13)	0.63 (0.08)	0.58 (0.07)	0.60 (0.07)	.01	0.69	.06	0.45	.42	0.25
Right caudate	3.30	8, 20, -2 (5)	0.51 (0.09)	0.49 (0.07)	0.48 (0.10)	.41	0.23	.18	0.32	.72	-0.10
Right middle temporal, BA21 extending to BA38	3.16	52, 6, -32 (5)	0.55 (0.06)	0.52 (0.05)	0.51 (0.08)	.06	0.52	.009	0.63	.61	-0.20
Right middle temporal BA21 extending to BA38	5.30	46, 8, -42 (5)	0.52 (0.06)	0.51 (0.08)	0.51 (0.05)	.56	0.16	.56	0.14	.89	0.04
Anterior cingulate/limbic, BA24	3.53	0, 44, -10 (20)	0.82 (0.04)	0.79 (0.04)	0.81 (0.04)	.02	0.68	.25	0.28	.25	0.37

Abbreviations: ADHD, attention-deficit/hyperactivity disorder; BA, Brodmann area; ES, effect size; MNI, Montreal Neurological Institute.

^aIncludes results for regions that survived false discovery rate of less than 0.05 and extent of more than 5 voxels in analyses of the entire sample (Figures 3 and 4). The comparison group included participants who did not meet criteria for any type of ADHD at the 41-year follow-up longitudinal assessment. *P* values surviving Bonferroni correction for multiple comparisons or ES > 0.50 are indicated in boldface.

not yield significant results, even with more lenient thresholds (FDR ≤ 0.2).

COMMENT

In a prospective 33-year longitudinal follow-up of 59 probands (mean age, 41.2 years) with established ADHD in childhood and 80 prospectively enrolled non-ADHD comparison participants, we found an overall significant reduction in mean cortical thickness in the probands. Beyond this global difference, the greatest cortical thinning associated with childhood ADHD was located in the bilateral parietal lobes, temporal poles, insula, precentral gyri, frontal poles, and right precuneus. No cortical region was significantly thicker in probands than in comparison participants. Although less sensitive,⁴⁴ VBM also revealed significantly decreased GM in probands vs comparison participants in the right precentral, bilateral parietal, left temporal, and right cuneus. In addition, VBM detected decreased GM in probands in the caudate, thalamus, and cerebellar hemispheres.

With respect to current adult diagnosis, probands with persistent ADHD differed the most from those in the non-ADHD comparison group in the same cortical regions identified in our primary analyses, as well as in additional clusters in the left medial occipital cortex and subgenual ACC. Probands with remitting ADHD did not dif-

fer significantly from those with persistent ADHD when analyses were corrected for full-brain comparisons. In exploratory uncorrected analyses, probands with persistent ADHD exhibited reduced cortical thickness relative to those with remitting ADHD in the bilateral medial occipital lobes, temporal lobes extending to the insula, and left parahippocampus.

Our results extend previous volumetric and cortical thickness findings in ADHD. First, consistent with the decreased total cerebral volume in ADHD,²⁻⁴ our observation of reduced global cortical thickness in probands with ADHD confirms previous reports.^{12,13,17} Furthermore, although we found less frontal and prefrontal cortical thinning in ADHD than were found in previous studies,^{11-14,17,45} we confirmed a thinner cortical mantle in the occipitoparietal,^{11,12,17} temporal cortex, and precentral regions^{12,13} in ADHD. In subcortical analyses, we also confirmed anatomic abnormalities in the caudate,^{3,46,47} thalamus,^{48,49} and cerebellum³ in ADHD.

Studies of cortical thickness in adults with ADHD have focused on specific regions associated with executive function and attentional control.^{50,51} Makris et al⁸ selected 9 parcellation units (from 48) per hemisphere and found thinner cortex related to ADHD in the prefrontal and cingulate cortex and inferior parietal lobe, albeit without correcting for multiple comparisons. A cross-sectional study of children, adolescents, and adults found that individu-

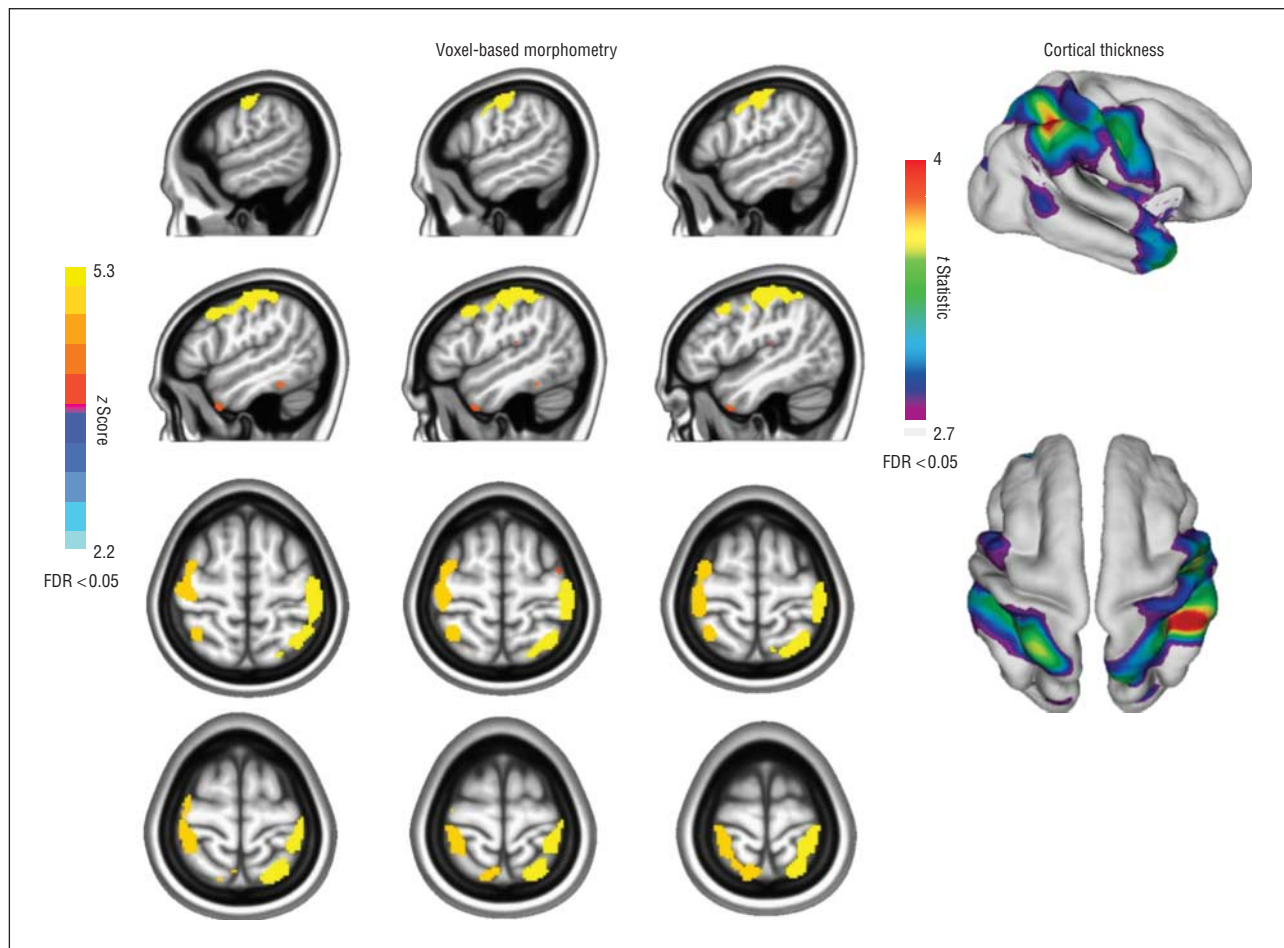


Figure 3. Comparison participants ($n=80$) exhibit greater gray matter density (left) and cortical thickness (right) in the bilateral dorsal attentional network than in probands ($n=59$) with childhood combined-type attention-deficit/hyperactivity disorder. Images are per radiological convention; thus, right is left and left is right. FDR indicates false discovery rate.

als with ADHD, regardless of age, had a significantly thinner right superior frontal cortex than controls.¹⁴ In the adults with ADHD, the specific reduction, with correction for multiple comparisons limited to the frontal lobe, was localized to BA9. In contrast, we did not find group differences in much of the prefrontal cortex but found widespread cortical thinning in the bilateral parietal-temporal cortex. We found similar results in analyses that included all participants, as well as in those limited to probands with persistent ADHD vs the non-ADHD comparison group. The latter contrasts are comparable to those of studies in adults that define group membership by current diagnostic status.^{14,17}

Studies of cortical thickness in children with ADHD are more numerous than those in adults^{11-13,28,42,52,53} and typically have examined the entire cerebrum, although nearly all (except Shaw et al¹³) report results uncorrected for multiple comparisons. Thinner cortex has been reported in children with ADHD in the prefrontal and precentral regions,^{11,13} parietal and temporal lobes,^{11,12} and inferior frontal gyrus bilaterally.⁵⁴ In our main analyses, we applied FDR full-brain correction for multiple comparisons and observed significant differences whether groups were defined by the initial childhood history or by the current adult diagnoses. We speculate that the ro-

bustness of our results reflects having established the diagnosis of ADHD in childhood as well as our medium to large sample sizes.

Broadly, our results implicate disruptions in large-scale neural systems involved in the regulation of both attention and emotion in adults with childhood ADHD. We found convincing converging anatomic evidence implicating the dorsal attentional network³¹ and distributed regions within limbic circuits that were thinner in ADHD probands than in comparison groups. Similar findings were obtained when we contrasted probands with persistent ADHD and the comparison group without ADHD. However, we failed to observe hypothesized group differences in prefrontal regions.^{1,3}

First, we found widespread thinner cortex and decreased GM density in bilateral parietal and precentral regions, overlapping areas of the dorsal attentional network. The bilateral dorsal network, which mediates goal-directed, top-down executive control processes, interacts with a right-sided ventral system (stimulus-driven, bottom-up) during attentional functioning,^{1,51} particularly in redirecting attention. The core areas constituting the dorsal attentional network include the intraparietal sulcus and the conjunction of the precentral and superior frontal sulcus (frontal eye fields),⁵¹ which were

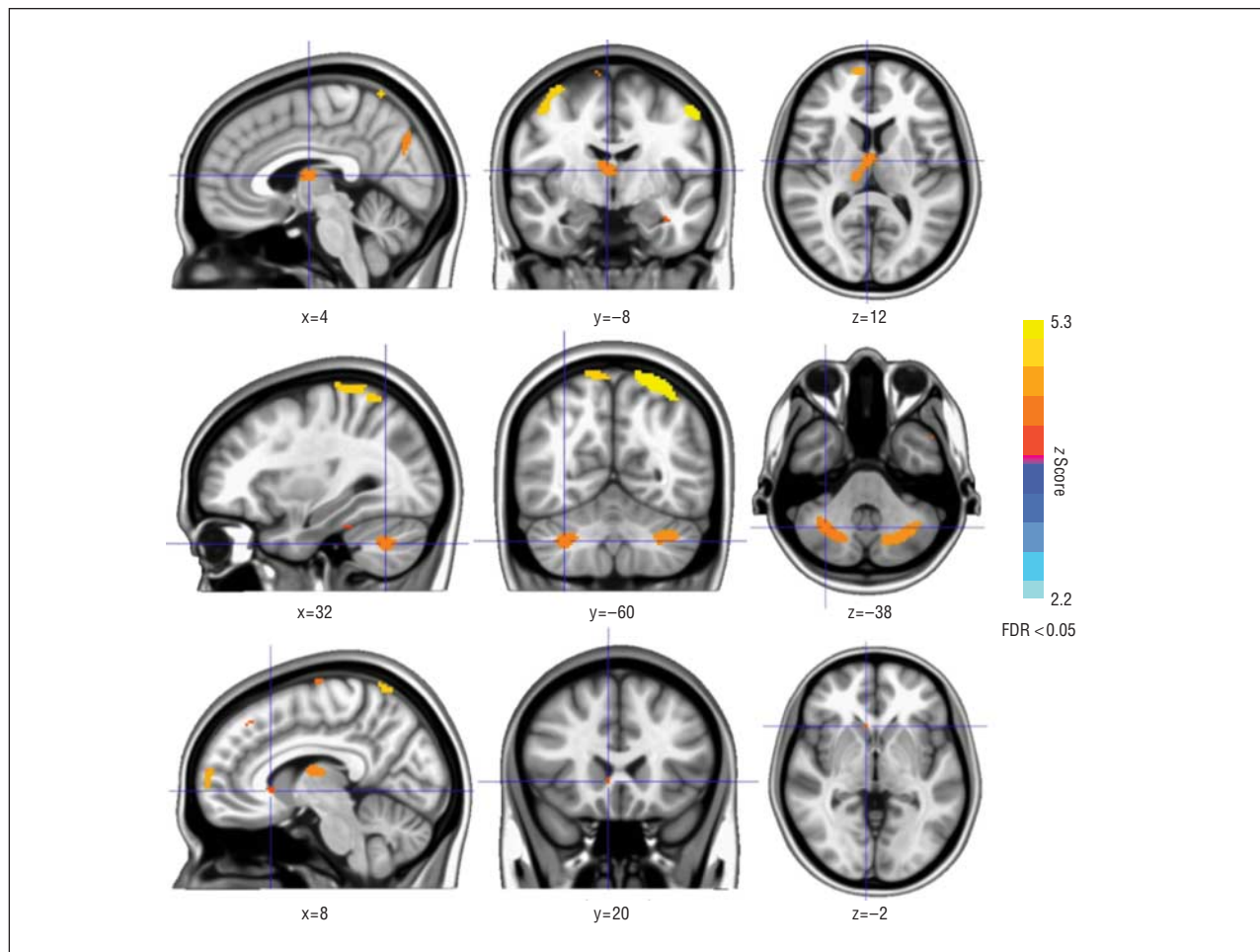


Figure 4. Voxel-based morphometry reveals that comparison participants ($n=80$) exhibit significantly greater gray matter density (false discovery rate [FDR] < 0.05) in the right ventral caudate, right thalamus, and bilateral cerebellum than in probands ($n=59$) with childhood combined-type attention-deficit/hyperactivity disorder. Images are per radiological convention; thus, right is left and left is right.

particularly affected in the ADHD probands. Strikingly, we also observed significantly thinner cortex in the precuneus and superior parietal lobe, which along with the dorsal network core regions are implicated in top-down processing of shifting of attention.⁵⁵ These findings are consistent with studies of ADHD that report abnormal patterns of activation in parietal regions⁴⁸ during working memory,⁵⁶⁻⁵⁸ attentional,⁵⁹⁻⁶¹ or response inhibition^{62,63} tasks.

We also found occipital cortical thinning in probands with persistent ADHD vs the non-ADHD comparison group. The occipital cortex has been recently found to interact with the dorsal network in maintaining attention⁵⁵ and in suppressing responses to irrelevant stimuli.^{64,65} Individuals with ADHD are easily distracted when required to ignore extraneous signals.^{66,67} Top-down control deficits when responding to irrelevant stimuli are associated with impaired working memory.^{68,69} Abnormal activation of the occipital cortex has been found in youth⁷⁰ and adults⁷¹⁻⁷³ with ADHD during working memory tasks. Similarly, in a meta-analysis⁴⁸ of functional imaging studies, children and adolescents with ADHD showed activation decreases in the left middle occipital gyrus (BA19) compared with controls. In addition, a recent VBM study in adults with ADHD

found significant bilateral reduction of GM volume only in the early visual cortex.⁷⁴

Our VBM analysis revealed cerebellar, thalamic, and striatal GM deficits in ADHD. Cerebellar involvement in ADHD is well established, with findings in children reported mostly in the vermis^{1-4,75} and in adults in the hemispheres, as in this sample.^{56,76,77} Early anatomic studies of ADHD did not specifically examine thalamic nuclei, although thalamic hypoactivation emerged in an unbiased meta-analysis.⁴⁸ Recently, several studies have identified thalamic abnormalities in children and adolescents^{49,78} and in adults with ADHD.^{60,79}

Second, our analyses revealed thinner cortex in probands, and particularly those with persistent ADHD, across multiple limbic regions, such as the temporal poles (BA38), insula (BA13), and subgenual ACC (BA25). The insula and ACC play important roles in sensorimotor, emotional, and cognitive function.^{80,81} Specifically, subgenual ACC is implicated in emotional processing and pain perception.⁸² In humans, subgenual ACC is functionally connected with multiple limbic regions, including the temporal poles⁸³ and insula.⁸⁴ In turn, the insula, along with participating in performance of demanding tasks,⁸⁵ is clearly also related to affective processing.⁸⁶ Abnormal activations in insula and subgenual

ACC were reported in a meta-analysis of ADHD functional imaging.⁴⁸

Cortical thickness studies in ADHD have downplayed findings in the temporal pole, which have been reported but not discussed.¹¹⁻¹³ The temporal pole (BA38) is classified as a paralimbic region, based on its interconnections with the amygdala and orbitofrontal cortex, and is implicated in social and emotional processes.⁸⁷ Altered activation in temporal pole is associated with deficits in face recognition⁸⁸⁻⁹⁵ and mentalizing, that is, the theory of mind.⁹⁶⁻⁹⁹ The temporal poles have been proposed as a channel for the integration of emotion and perception, playing an important role in emotional and social functions.⁸⁷

Our findings are consistent with pathophysiological models of ADHD highlighting not only cognitive executive functions (“cool” processes) but also emotional and motivational deficits (“hot” processes).¹⁰⁰ Anatomic spiraling circuits begin with emotional and motivational pathways that influence the cool cognitive processes, which in turn control motor responses.¹⁰¹ We observed thinner cortex in regions subserving emotional regulation (the temporal pole, insula, parahippocampus, and subgenual ACC) and top-down attentional regulation (the dorsal attentional network and medial occipital cortex). Furthermore, our exploratory analyses suggest that thinner cortex and diminished GM in the dorsal attentional network and limbic relay regions is related to the trait of having had ADHD in childhood, regardless of current diagnostic status.

Third, the lack of proband-comparison differences in the prefrontal cortex or the ACC was unexpected.^{7,8,16-18} To better understand possible differences between persistent and remitting ADHD, we performed uncorrected exploratory analyses. In regions in which we found suggestive differences, we observed remarkable congruence between probands with remitting ADHD and comparison groups in the left superior temporal gyrus, ACC, parahippocampus, and occipital cortical thickness as well as in thalamus and cerebellum GM density. We cannot rule out that probands with remitting ADHD may have differed from those with persistent ADHD in these regions since childhood, but the most parsimonious explanation is offered by the hypothesis that remission entails compensatory processes^{11,102} underpinned by prefrontal cortical maturation. Although we found supporting evidence of ACC and orbitofrontal involvement in diagnostic remission of ADHD, our data also suggest superior temporal, medial occipital, and thalamocerebellar involvement in remission.

Our findings must be interpreted in light of several limitations. First, despite our prospective longitudinal design, we examined brain imaging data only cross-sectionally in middle adulthood. Nevertheless, this is the largest sample of children with ADHD followed up into adulthood, obviating the unreliability of retrospective recall of childhood symptoms. In addition, we report on the largest sample to date of adults with confirmed childhood ADHD who underwent remission. We were able to analyze imaging data from only 28.5% of the original ADHD proband group and 44.9% of the original comparison participants. However, these probands and comparison participants did not differ from the original sample, and the probands studied did not differ significantly

from those excluded on nearly all clinical and demographic variables except for significantly higher rates of substance use disorders at the 18FU in probands who underwent scanning. Nevertheless, we did not observe significant relationships between brain anatomic measures and substance use disorders. Finally, as is generally the case, our probands had significantly lower IQ scores than the comparison participants in childhood or adolescence and in adulthood. The issue of whether to covary for IQ in disorders such as ADHD is not settled.¹⁰³ As shown in eFigure 1 (see also eTable 7, available at the authors' Web site), our principal findings of persistent differences in brain anatomy survived covarying for IQ even with conservative full-brain correction.

We were surprised by the rate of ADHD-NOS diagnosed in comparison participants, which was comparable to the rate in probands. We speculate that secular changes in the general public's awareness of ADHD may have contributed. Although we cannot rule out instrument-related error (see the supplementary Instrument available on the authors' Web site), the use of similar approaches did not yield high rates of ADHD symptoms in comparison participants in 2 previous blinded assessments.^{21,23} Nevertheless, analyses excluding ADHD-NOS did not alter results appreciably.

We limited study participants to white boys because the number of originally diagnosed girls with ADHD was too small for meaningful statistical comparisons. Thus, our results may not be generalizable to ADHD in women or to other racial or ethnic groups. However, this constraint avoided potential confounds from possible sex, ethnic, or socioeconomic differences. Exclusion of conduct disorder comorbidity (see the supplementary text, available on the authors' Web site) in childhood also averted confusion as to the origin of the deficits found in cortical thickness or GM density.

We cannot comment on cortical thickness or GM density in ADHD in the absence of medication treatment because all but 4 of the probands who underwent scanning were treated with methylphenidate as children. We also did not detect significant effects of childhood treatment with stimulants or thioridazine in cortical thickness or VBM analyses. Medication treatment has been reported to affect cortical thickness,⁴² although the durability of such effects is unknown, and treatment had been discontinued for all study participants for several decades.

For logistical reasons, we used 2 scanners. Fortunately, scans were approximately counterbalanced across probands and comparison participants, and there were no significant main effects or interactions related to scanner type. Secondary analyses (eFigure 2) also showed that we obtained comparable results when we examined only the 98 scans obtained on the Allegra scanner. Finally, the analyses presented herein were limited to cortical thickness and VBM; ongoing analyses will examine WM structure using diffusion tensor imaging.

CONCLUSIONS

In this first study of childhood ADHD prospectively examined in adulthood, we found thinner overall cortex

in probands with childhood ADHD that was even more pronounced in those with persistent ADHD. Beyond this global effect, we also detected significant reductions in cortex thickness in the parietal, temporal, and posterior frontal regions corresponding to the dorsal attentional network and limbic areas. These findings were largely echoed by VBM, which in addition highlighted decreased GM in the caudate. These regions underpin the top-down control of attention and the regulation of emotion and motivation and were comparably diminished in probands with remitting ADHD or persistent ADHD. Thus, these differences seem to primarily reflect the childhood diagnosis of ADHD. By contrast, probands with remitting ADHD tended to differ from those with persistent ADHD in the medial occipital cortex, temporal pole, insula, orbitofrontal cortex, parahippocampus, and frontal pole and subcortically in the cerebellum and thalamus. This supports the suggestion that symptom amelioration and diagnostic remission may result in part from compensatory maturation of frontal-thalamic-cerebellar circuits.^{102,104}

Submitted for Publication: September 13, 2010; final revision received March 3, 2011; accepted April 15, 2011.
Author Affiliations: Phyllis Green and Randolph Cowen Institute for Pediatric Neuroscience (Drs Proal, Reiss, Ramos-Olagastgi, Kelly, Milham, and Castellanos and Ms Gotimer) and Anita Saltz Institute for Anxiety and Mood Disorders (Drs Klein and Mannuzza), Child Study Center, New York University Langone School of Medicine, New York, New York; Unitat Recerca en Neurociència Cognitiva, Universitat Autònoma de Barcelona, Barcelona, Spain (Dr Proal); Nathan Kline Institute for Psychiatric Research, Orangeburg, New York (Drs Reiss, Mannuzza, Milham, and Castellanos); Department of Neurosciences and Mental Health, The Hospital for Sick Children, and Department of Medical Biophysics, University of Toronto, Toronto, Ontario (Dr Lerch); State Key Laboratory of Cognitive Neuroscience and Learning, Beijing Normal University, Beijing, China (Dr He); and Biospective Inc, Montreal, Quebec (Drs He and Zijdenbos).
Correspondence: F. Xavier Castellanos, MD, Phyllis Green and Randolph Cowen Institute for Pediatric Neuroscience, Child Study Center, New York University Langone School of Medicine, 215 Lexington Ave, 14th Floor, New York, NY 10016 (francisco.castellanos@nyumc.org).

Financial Disclosure: None reported.

Previous Presentations: This study was presented at the 16th Meeting of the Organization for Human Brain Mapping; June 9, 2010; Barcelona, Spain; and at the Third International Congress on ADHD; May 29, 2011; Berlin, Germany.

Online-Only Material: The eFigures are available at <http://www.archgenpsychiatry.com>, and the other supplementary materials are available on the authors' Web site at http://www.AboutOurKids.org/Research/Research_Publications/Proal_et_al_2011.

Additional Contributions: We thank the participants and their families who have contributed to this research over the decades. Christine Cox, PhD, provided a careful reading of an earlier version of the manuscript. Pierre Bellec,

PhD, Yasser Aleman, PhD, and Joost Janssen, PhD, provided helpful discussions regarding methods.

REFERENCES

1. Valera EM, Faraone SV, Murray KE, Seidman LJ. Meta-analysis of structural imaging findings in attention-deficit/hyperactivity disorder. *Biol Psychiatry*. 2007; 61(12):1361-1369.
2. Castellanos FX, Lee PP, Sharp W, Jeffries NO, Greenstein DK, Clasen LS, Blumenthal JD, James RS, Ebens CL, Walter JM, Zijdenbos A, Evans AC, Giedd JN, Rapoport JL. Developmental trajectories of brain volume abnormalities in children and adolescents with attention-deficit/hyperactivity disorder. *JAMA*. 2002;288(14):1740-1748.
3. Krain AL, Castellanos FX. Brain development and ADHD. *Clin Psychol Rev*. 2006; 26(4):433-444.
4. Durston S, Hulshoff Pol HE, Schnack HG, Buitelaar JK, Steenhuis MP, Minderaa RB, Kahn RS, van Engeland H. Magnetic resonance imaging of boys with attention-deficit/hyperactivity disorder and their unaffected siblings. *J Am Acad Child Adolesc Psychiatry*. 2004;43(3):332-340.
5. Kessler RC, Adler L, Barkley R, Biederman J, Conners CK, Demler O, Faraone SV, Greenhill LL, Howes MJ, Secnik K, Spencer T, Ustun TB, Walters EE, Zaslavsky AM. The prevalence and correlates of adult ADHD in the United States: results from the National Comorbidity Survey Replication. *Am J Psychiatry*. 2006; 163(4):716-723.
6. Hesslinger B, Tebartz van Elst L, Thiel T, Haegele K, Hennig J, Ebert D. Frontal volume reductions in adult patients with attention deficit hyperactivity disorder. *Neurosci Lett*. 2002;328(3):319-321.
7. Seidman LJ, Valera EM, Makris N, Monuteaux MC, Boriel DL, Kelkar K, Kennedy DN, Caviness VS, Bush G, Aleari M, Faraone SV, Biederman J. Dorsolateral prefrontal and anterior cingulate cortex volumetric abnormalities in adults with attention-deficit/hyperactivity disorder identified by magnetic resonance imaging. *Biol Psychiatry*. 2006;60(10):1071-1080.
8. Makris N, Seidman LJ, Valera EM, Biederman J, Monuteaux MC, Kennedy DN, Caviness VS Jr, Bush G, Crum K, Brown AB, Faraone SV. Anterior cingulate volumetric alterations in treatment-naïve adults with ADHD: a pilot study. *J Atten Disord*. 2010;13(4):407-413.
9. Monuteaux MC, Seidman LJ, Faraone SV, Makris N, Spencer T, Valera E, Brown A, Bush G, Doyle AE, Hughes S, Helliesen M, Mick E, Biederman J. A preliminary study of dopamine D4 receptor genotype and structural brain alterations in adults with ADHD. *Am J Med Genet B Neuropsychiatr Genet*. 2008;147B(8):1436-1441.
10. Castellanos FX, Proal E. Location, location, and thickness: volumetric neuroimaging of attention-deficit/hyperactivity disorder comes of age. *J Am Acad Child Adolesc Psychiatry*. 2009;48(10):979-981.
11. Shaw P, Eckstrand K, Sharp W, Blumenthal J, Lerch JP, Greenstein D, Clasen L, Evans A, Giedd J, Rapoport JL. Attention-deficit/hyperactivity disorder is characterized by a delay in cortical maturation. *Proc Natl Acad Sci U S A*. 2007; 104(49):19649-19654.
12. Narr KL, Woods RP, Lin J, Kim J, Phillips OR, Del'Homme M, Caplan R, Toga AW, McCracken JT, Levitt JG. Widespread cortical thinning is a robust anatomical marker for attention-deficit/hyperactivity disorder. *J Am Acad Child Adolesc Psychiatry*. 2009;48(10):1014-1022.
13. Shaw P, Lerch J, Greenstein D, Sharp W, Clasen L, Evans A, Giedd J, Castellanos FX, Rapoport J. Longitudinal mapping of cortical thickness and clinical outcome in children and adolescents with attention-deficit/hyperactivity disorder. *Arch Gen Psychiatry*. 2006;63(5):540-549.
14. Almeida LG, Ricardo-Garcell J, Prado H, Barajas L, Fernández-Bouzas A, Avila D, Martínez RB. Reduced right frontal cortical thickness in children, adolescents and adults with ADHD and its correlation to clinical variables: a cross-sectional study. *J Psychiatr Res*. 2010;44(16):1214-1223.
15. Faraone SV, Biederman J, Feighner JA, Monuteaux MC. Assessing symptoms of attention deficit hyperactivity disorder in children and adults: which is more valid? *J Consult Clin Psychol*. 2000;68(5):830-842.
16. Makris N, Buka SL, Biederman J, Papadimitriou GM, Hodge SM, Valera EM, Brown AB, Bush G, Monuteaux MC, Caviness VS, Kennedy DN, Seidman LJ. Attention and executive systems abnormalities in adults with childhood ADHD: a DT-MRI study of connections. *Cereb Cortex*. 2008;18(5):1210-1220.
17. Makris N, Biederman J, Valera EM, Bush G, Kaiser J, Kennedy DN, Caviness VS, Faraone SV, Seidman LJ. Cortical thinning of the attention and executive function networks in adults with attention-deficit/hyperactivity disorder. *Cereb Cortex*. 2007;17(6):1364-1375.
18. Biederman J, Makris N, Valera EM, Monuteaux MC, Goldstein JM, Buka S, Boriel DL, Bandyopadhyay S, Kennedy DN, Caviness VS, Bush G, Aleari M, Hammerner P, Faraone SV, Seidman LJ. Towards further understanding of the co-

65. Mevorach C, Hodsoll J, Allen H, Shalev L, Humphreys G. Ignoring the elephant in the room: a neural circuit to downregulate salience. *J Neurosci*. 2010; 30(17):6072-6079.
66. Lijffijt M, Kenemans JL, Verbaten MN, van Engeland H. A meta-analytic review of stopping performance in attention-deficit/hyperactivity disorder: deficient inhibitory motor control? *J Abnorm Psychol*. 2005;114(2):216-222.
67. Clark L, Blackwell AD, Aron AR, Turner DC, Dowson J, Robbins TW, Sahakian BJ. Association between response inhibition and working memory in adult ADHD: a link to right frontal cortex pathology? *Biol Psychiatry*. 2007;61(12):1395-1401.
68. Zanto TP, Rubens MT, Bollinger J, Gazzaley A. Top-down modulation of visual feature processing: the role of the inferior frontal junction. *Neuroimage*. 2010; 53(2):736-745.
69. Gazzaley A, D'Esposito M. Top-down modulation and normal aging. *Ann N Y Acad Sci*. 2007;1097:67-83.
70. Durston S, Tottenham NT, Thomas KM, Davidson MC, Eigsti IM, Yang Y, Ulug AM, Casey BJ. Differential patterns of striatal activation in young children with and without ADHD. *Biol Psychiatry*. 2003;53(10):871-878.
71. Schweitzer JB, Faber TL, Grafton ST, Tune LE, Hoffman JM, Kilts CD. Alterations in the functional anatomy of working memory in adult attention deficit hyperactivity disorder. *Am J Psychiatry*. 2000;157(2):278-280.
72. Schweitzer JB, Lee DO, Hanford RB, Tagamets MA, Hoffman JM, Grafton ST, Kilts CD. A positron emission tomography study of methylphenidate in adults with ADHD: alterations in resting blood flow and predicting treatment response. *Neuropsychopharmacology*. 2003;28(5):967-973.
73. Schweitzer JB, Hanford RB, Medoff DR. Working memory deficits in adults with ADHD: is there evidence for subtype differences? *Behav Brain Funct*. 2006; 2:43. doi:10.1186/1744-9081-2-43.
74. Ahrendts J, Rusch N, Wilke M, Philippen A, Eickhoff SB, Glauche V, Perlov E, Ebert D, Hennig J, Tebarzt van Elst L. Visual cortex abnormalities in adults with ADHD: a structural MRI study [published online September 29, 2010]. *World J Biol Psychiatry*. doi:10.3109/15622975.2010.518624.
75. Castellanos FX, Giedd JN, Berquin PC, Walter JM, Sharp W, Tran T, Vaituzis AC, Blumenthal JD, Nelson J, Bastain TM, Zijdenbos A, Evans AC, Rapoport JL. Quantitative brain magnetic resonance imaging in girls with attention-deficit/hyperactivity disorder. *Arch Gen Psychiatry*. 2001;58(3):289-295.
76. Perlov E, Tebarzt van Elst L, Buechert M, Maier S, Matthies S, Ebert D, Hessleringer B, Philippen AH. H¹-MR-spectroscopy of cerebellum in adult attention deficit/hyperactivity disorder. *J Psychiatr Res*. 2010;44(14):938-943.
77. Valera EM, Spencer RM, Zeffiro TA, Makris N, Spencer TJ, Faraone SV, Biederman J, Seidman LJ. Neural substrates of impaired sensorimotor timing in adult attention-deficit/hyperactivity disorder. *Biol Psychiatry*. 2010;68(4):359-367.
78. Qiu MG, Ye Z, Li QY, Liu GJ, Xie B, Wang J. Changes of brain structure and function in ADHD children [published online December 30, 2010]. *Brain Topogr*. doi:10.1007/s10548-010-0168-4.
79. Dibbets P, Evers EA, Hurks PP, Bakker K, Jolles J. Differential brain activation patterns in adult attention-deficit hyperactivity disorder (ADHD) associated with task switching. *Neuropsychology*. 2010;24(4):413-423.
80. Pollatos O, Gramann K, Schandry R. Neural systems connecting interoceptive awareness and feelings. *Hum Brain Mapp*. 2007;28(1):9-18.
81. Craig AD. How do you feel? interoception: the sense of the physiological condition of the body. *Nat Rev Neurosci*. 2002;3(8):655-666.
82. Vogt BA, Vogt L, Farber NB, Bush G. Architecture and neurocytology of monkey cingulate gyrus. *J Comp Neurol*. 2005;485(3):218-239.
83. Margulies DS, Kelly AM, Uddin LQ, Biswal BB, Castellanos FX, Milham MP. Mapping the functional connectivity of anterior cingulate cortex. *Neuroimage*. 2007;37(2):579-588.
84. Taylor KS, Seminowicz DA, Davis KD. Two systems of resting state connectivity between the insula and cingulate cortex. *Hum Brain Mapp*. 2009;30(9): 2731-2745.
85. Eckert MA, Menon V, Walczak A, Ahlstrom J, Denslow S, Horwitz A, Dubno JR. At the heart of the ventral attention system: the right anterior insula. *Hum Brain Mapp*. 2009;30(8):2530-2541.
86. Quartz SR. Reason, emotion and decision-making: risk and reward computation with feeling. *Trends Cogn Sci*. 2009;13(5):209-215.
87. Olson IR, Plotzker A, Ezzyat Y. The enigmatic temporal pole: a review of findings on social and emotional processing. *Brain*. 2007;130(pt 7):1718-1731.
88. Mackay CE, Roberts N, Mayes AR, Downes JJ, Foster JK, Mann D. An exploratory study of the relationship between face recognition memory and the volume of medial temporal lobe structures in healthy young males. *Behav Neurol*. 1998;11(1):3-20.
89. Nakamura K, Kawashima R, Sato N, Nakamura A, Sugiura M, Kato T, Hatano K, Ito K, Fukuda H, Schormann T, Zilles K. Functional delineation of the human occipito-temporal areas related to face and scene processing: a PET study. *Brain*. September 2000;123(pt 9):1903-1912.
90. Grabowski TJ, Damasio H, Tranel D, Ponto LL, Hichwa RD, Damasio AR. A role for left temporal pole in the retrieval of words for unique entities. *Hum Brain Mapp*. 2001;13(4):199-212.
91. Dupont S. Investigating temporal pole function by functional imaging. *Epileptic Disord*. 2002;4(suppl 1):S17-S22.
92. Nelson EE, McClure EB, Monk CS, Zarahn E, Leibenluft E, Pine DS, Ernst M. Developmental differences in neuronal engagement during implicit encoding of emotional faces: an event-related fMRI study. *J Child Psychol Psychiatry*. 2003;44(7):1015-1024.
93. Tsukiura T, Namiki M, Fujii T, Iijima T. Time-dependent neural activations related to recognition of people's names in emotional and neutral face-name associative learning: an fMRI study. *Neuroimage*. 2003;20(2):784-794.
94. Griffith HR, Richardson E, Pyzalski RW, Bell B, Dow C, Hermann BP, Seidenberg M. Memory for famous faces and the temporal pole: functional imaging findings in temporal lobe epilepsy. *Epilepsy Behav*. 2006;9(1):173-180.
95. Kim JW, Kim JJ, Jeong BS, Ki SW, Im DM, Lee SJ, Lee HS. Neural mechanism for judging the appropriateness of facial affect. *Brain Res Cogn Brain Res*. 2005; 25(3):659-667.
96. Jimura K, Konishi S, Asari T, Miyashita Y. Temporal pole activity during understanding other persons' mental states correlates with neuroticism trait. *Brain Res*. 2010;1328:104-112.
97. Mier D, Lis S, Neuthe K, Sauer C, Esslinger C, Gallhofer B, Kirsch P. The involvement of emotion recognition in affective theory of mind. *Psychophysiology*. 2010;47(6):1028-1039.
98. Völlm BA, Taylor AN, Richardson P, Corcoran R, Stirling J, McKie S, Deakin JF, Elliott R. Neuronal correlates of theory of mind and empathy: a functional magnetic resonance imaging study in a nonverbal task. *Neuroimage*. 2006;29(1):90-98.
99. Moriguchi Y, Ohnishi T, Mori T, Matsuda H, Komaki G. Changes of brain activity in the neural substrates for theory of mind during childhood and adolescence. *Psychiatry Clin Neurosci*. 2007;61(4):355-363.
100. Castellanos FX, Sonuga-Barke EJ, Milham MP, Tannock R. Characterizing cognition in ADHD: beyond executive dysfunction. *Trends Cogn Sci*. 2006;10(3):117-123.
101. Haber SN. The primate basal ganglia: parallel and integrative networks. *J Chem Neuroanat*. 2003;26(4):317-330.
102. Halperin JM, Schulz KP. Revisiting the role of the prefrontal cortex in the pathophysiology of attention-deficit/hyperactivity disorder. *Psychol Bull*. 2006; 132(4):560-581.
103. Meehl P. Nuisance variables and the ex post facto design. In: Radner MWS, ed. *Analyses of Theories and Methods of Physics and Psychology*. Minneapolis: University of Minnesota Press; 1970:373-402.
104. Fassbender C, Schweitzer JB. Is there evidence for neural compensation in attention deficit hyperactivity disorder? a review of the functional neuroimaging literature. *Clin Psychol Rev*. 2006;26(4):445-465.