

Brain Anatomy and Its Relationship to Behavior in Adults With Autism Spectrum Disorder

A Multicenter Magnetic Resonance Imaging Study

Christine Ecker, MSc, PhD; John Suckling, PhD; Sean C. Deoni, PhD; Michael V. Lombardo, PhD; Ed T. Bullmore, MB, FRCPsych; Simon Baron-Cohen, PhD, FBA; Marco Catani, MD, MRCPsych; Peter Jezzard, PhD; Anna Barnes, PhD; Anthony J. Bailey, MD, PhD; Steven C. Williams, BSc, PhD; Declan G. M. Murphy, MBBS, FRCPsych, MD; for the MRC AIMS Consortium

Context: There is consensus that autism spectrum disorder (ASD) is accompanied by differences in neuroanatomy. However, the neural substrates of ASD during adulthood, as well as how these relate to behavioral variation, remain poorly understood.

Objective: To identify brain regions and systems associated with ASD in a large, well-characterized sample of adults.

Design: Multicenter case-control design using quantitative magnetic resonance imaging.

Setting: Medical Research Council UK Autism Imaging Multicentre Study (MRC AIMS), with sites comprising the Institute of Psychiatry, Kings College London; the Autism Research Centre, University of Cambridge; and the Autism Research Group, University of Oxford.

Participants: Eighty-nine men with ASD and 89 male control participants who did not differ significantly in mean age (26 and 28 years, respectively) and full-scale IQ (110 and 113, respectively).

Main Outcome Measures: (1) Between-group differences in regional neuroanatomy assessed by voxel-based morphometry and (2) distributed neural systems maximally correlated with ASD, as identified by partial least-squares analysis.

Results: Adults with ASD did not differ significantly from the controls in overall brain volume, confirming the results of smaller studies of individuals in this age group without intellectual disability. However, voxelwise comparison between groups revealed that individuals with ASD had significantly increased gray matter volume in the anterior temporal and dorsolateral prefrontal regions and significant reductions in the occipital and medial parietal regions compared with controls. These regional differences in neuroanatomy were significantly correlated with the severity of specific autistic symptoms. The large-scale neuroanatomic networks maximally correlated with ASD identified by partial least-squares analysis included the regions identified by voxel-based analysis, as well as the cerebellum, basal ganglia, amygdala, inferior parietal lobe, cingulate cortex, and various medial, orbital, and lateral prefrontal regions. We also observed spatially distributed reductions in white matter volume in participants with ASD.

Conclusions: Adults with ASD have distributed differences in brain anatomy and connectivity that are associated with specific autistic features and traits. These results are compatible with the concept of autism as a syndrome characterized by atypical neural “connectivity.”

Arch Gen Psychiatry. 2012;69(2):195-209

AUTISM SPECTRUM DISORDER (ASD) is a life-long neurodevelopmental condition affecting approximately 1% of the population^{1,2} and is characterized by a triad of symptoms in impaired social communication, social reciprocity, and repetitive/stereotypic behavior.^{3,4} There is consensus that people with ASD have differences in brain anatomy. However, the specific neural substrates of ASD, and how these relate to behavioral variation in adulthood, remain poorly understood.

Evidence that individuals with ASD have neuroanatomic abnormalities comes

from a variety of postmortem and structural neuroimaging studies.⁵⁻⁷ For example, it has been reported⁸⁻¹⁰ that people with ASD have increased brain volume and weight, which affects both gray matter and white matter. These gross anatomic differences are most prominent during early postnatal life and childhood and may be less apparent during adolescence and adulthood.¹¹⁻¹³ The suggestion that individuals with ASD also have anatomic differences in specific brain regions and systems is supported by autopsy¹⁴ and in vivo studies. For example, differences have been described in the cerebellum,¹⁵ amygdala-

Author Affiliations are listed at the end of this article.

Group Information: The members of the Medical Research Council UK Autism Imaging Multicentre Study (MRC AIMS) Consortium appear at the end of this article.

Table 1. Participant Demographics

Characteristic ^a	Mean (SD) [Range]	
	ASD Group (n = 89)	Control Group (n = 89)
Age, y	26 (7) [18-43]	28 (6) [18-43]
Full-scale IQ, WASI	110 (15) [73-135]	113 (12) [77-137]
Performance IQ, WASI ^b	107 (16) [73-138]	115 (12) [76-135]
Verbal IQ, WASI	110 (14) [77-139]	109 (13) [71-141]
ADI-R total ^c	37 (9) [20-57]	...
ADI-R Social ^c	18 (5) [9-29]	...
ADI-R Communication ^c	14 (4) [8-25]	...
ADI-R Repetitive Behavior ^c	5 (2) [2-12]	...
ADOS total ^d	10 (5) [1-23]	...
ADOS Social ^d	6 (3) [0-13]	...
ADOS Communication ^d	3 (2) [0-7]	...
ADOS Repetitive Behavior ^d	1 (1) [0-6]	...
AQ ^e	30 (8) [4-46]	15 (6) [3-34]

Abbreviations: ADI-R, Autism Diagnostic Interview–Revised; ADOS, Autism Diagnostic Observation Schedule; AQ, Autism Spectrum Quotient; ASD, autism spectrum disorder; WASI, Wechsler Abbreviated Scale of Intelligence.

^aThere were no significant differences between the ASD and control groups in age, full-scale IQ, or verbal IQ at $P < .05$ (2-tailed).

^bThere was a significant difference in performance IQ ($P < .01$).

^cInformation was available for all 89 individuals with ASD. The following cutoff scores were used: ADI-R Social, greater than 10; Communication, greater than 8; and Repetitive Behavior, greater than 3.

^dCommunication plus Social Interaction total score; information was available for 86 individuals with ASD, using a cutoff score of 7.

^eInformation was available for 86 individuals with ASD and for all 89 control participants; 2 individuals with ASD failed to reach the cutoff in the social domain by 1 point, and 8 individuals with ASD failed to reach the cutoff in the repetitive behavior domain by 1 point.

hippocampal complex,^{11,16-18} frontotemporal regions,^{16,17,19} and caudate nucleus.^{13,20} There is also preliminary evidence that anatomic differences are associated with variation in clinical symptoms. For instance, abnormalities in the (1) Broca and Wernicke areas have been related to impaired social communication and language²¹; (2) frontotemporal regions and amygdala have been associated with abnormalities in socioemotional processing²²⁻²⁴; and (3) orbitofrontal cortex and caudate nucleus (ie, frontostriatal system)^{13,25} may be linked to repetitive and stereotyped behaviors. These studies were important first steps and add weight to the suggestion that people with ASD have differences in brain anatomy that underpin symptoms.

However, our understanding of the putative relationship between ASD and the anatomy of specific brain regions has been hampered by nonreplication of findings. For example, the sizes of the cerebellum and amygdala have been variously reported^{12,15,26-29} to be normal, smaller, and larger. This variability probably arises because most studies were of relatively small, heterogeneous samples that differed in several key respects within and across participant groups (eg, diagnostic criteria, IQ, age, and the image analysis methods). Also, the investigation of a neural systems condition such as ASD requires a spatially unbiased analytical approach, such as commonly used mass-univariate approaches (eg, voxel-based morphometry [VBM]³⁰), which rely on conservative statistical thresholds mandated by the large number of voxels compared

between groups. Hence, large sample sizes of well-characterized individuals are required to reliably detect subtle and spatially diffuse differences in brain anatomy. Furthermore, spatially unbiased multivariate (ie, multi-voxel) approaches may complement VBM in characterizing brain abnormalities associated with ASD at the systems level.³¹⁻³³ Finally, most studies of ASD understandably have focused on children. However, this means that we know relatively little about the large population of adults with ASD who are increasingly receiving a diagnosis.

For this reason, we carried out a multicenter study on a large, well-characterized sample to test the primary hypothesis that adults with ASD have abnormalities in brain anatomy that differentiate them from adults serving as controls. On the basis of the literature reviewed herein, we predicted that individuals with ASD are significantly different from control individuals in a large-scale neural network comprising (1) the frontothalamic-striatal system,^{22,25} (2) the frontotemporal circuitry,^{23,34} and (3) the frontocerebellar network.¹³ Regional between-group differences were investigated using a traditional VBM approach. To identify large-scale gray matter systems (comprising multiple voxels) maximally associated with ASD, we used the statistical method of partial-least squares analysis. Last, we tested the subsidiary hypothesis that differences in regional gray matter volume are associated with variation in specific autistic symptoms.

METHODS

PARTICIPANTS

Eighty-nine male right-handed adults with ASD and 89 matched neurotypical male controls aged 18 to 43 years were recruited by advertisement and subsequently assessed at 1 of 3 collaborating autism research centers in the United Kingdom that make up the Medical Research Council UK Autism Imaging Multicentre Study (MRC AIMS) Consortium: the Institute of Psychiatry, Kings College London; the Autism Research Centre, University of Cambridge; and the Autism Research Group, University of Oxford. Approximately equal ratios of cases to controls were recruited at each site: London, 41:41; Cambridge, 30:32; and Oxford, 18:16.

Exclusion criteria for all participants included a history of major psychiatric disorder, head injury, genetic disorder associated with autism (eg, fragile X syndrome and tuberous sclerosis), or any other medical condition affecting brain function (eg, epilepsy). We excluded potential participants who were abusing drugs (including alcohol) and individuals taking antipsychotic medication, mood stabilizers, or benzodiazepines. All participants with ASD were diagnosed according to *International Statistical Classification of Diseases, 10th Revision (ICD-10)* research criteria confirmed using the Autism Diagnostic Interview–Revised (ADI-R³⁵) to ensure that all participants with ASD met the criteria for childhood autism. All cases of ASD reached ADI-R algorithm cutoff values in the 3 domains of impaired reciprocal social interaction, communication, and repetitive behaviors and stereotyped patterns, although failure to reach cutoff in one of the domains by one point was permitted (see **Table 1** for details).

Current symptoms were assessed using the Autism Diagnostic Observation Schedule (ADOS³⁶) but were not used as inclusion criteria. We also assessed autistic traits in both case and control participants, using the Autism Spectrum Quotient.³⁷ Overall

intellectual ability was assessed using the Wechsler Abbreviated Scale of Intelligence.³⁸ All participants fell within the high-functioning range on the spectrum defined by a full-scale IQ higher than 70. The investigated sample included individuals with high-functioning autism (34 individuals; history of delayed language acquisition after 36 months) and Asperger syndrome (55 individuals; phrase speech earlier than 36 months).

All participants gave informed written consent in accordance with ethics approval by the National Research Ethics Committee, Suffolk, England.

MAGNETIC RESONANCE IMAGING DATA ACQUISITION

All participants were scanned with contemporary magnetic resonance imaging (MRI) scanners operating at 3-T and fitted with an 8-channel receive-only radio frequency head coil (GE Medical Systems HDx, Department of Radiology, University of Cambridge; GE Medical Systems HDx, Centre for Neuroimaging Sciences, Institute of Psychiatry, Kings College London; and Siemens Medical Systems Trim Trio, FMRIB Centre [Oxford Centre for Functional Magnetic Resonance Imaging of the Brain], University of Oxford). A specialized acquisition protocol using quantitative imaging (driven equilibrium single-pulse estimation of T1) was used to ensure standardization of structural MRI scans across the 3 scanner platforms. This protocol has previously been validated and extensively described elsewhere³⁹ (see eAppendix and eTable; <http://www.archgenpsychiatry.com>).

TISSUE SEGMENTATION

The T1-weighted images derived from the quantitative T1 maps (see eAppendix) were processed (FSL, version 4.0; <http://www.fmrib.ox.ac.uk/fsl>). Extracerebral tissues were removed (Brain Extraction Tool; University of Oxford⁴⁰), and maps of partial volume estimates of gray and white tissue occupancy were calculated (FMRIB's Automated Segmentation Tool; University of Oxford⁴⁰). All gray and white matter images were then nonlinearly registered to the stereotactic coordinate system of the Montreal Neurological Institute (MNI), using FNIRT (<http://fsl.fmrib.ox.ac.uk/fsl/fnirt/>). Results for linearly registered images can be found in eFigures 1 and 2. To account for inter-subject misregistration, the partial volume estimate maps were smoothed with a 3-dimensional gaussian kernel, with an SD of 4 mm. Total tissue volumes were calculated by summing the partial volumes estimates multiplied by the voxel volume across the entire brain. Between-group differences in global brain measures were examined using independent samples *t* tests.

GROUP DIFFERENCES IDENTIFIED BY MULTIPLE HYPOTHESIS TESTING

Voxelwise statistical testing was undertaken using commercial software (CamBA, version 2.3.0; <http://www-bmu.psychiatry.cam.ac.uk>). For tissue partial volume estimates (y_i), the main effect of group, coded by G_i , was estimated by regression of a general linear model at each intracerebral voxel (i) in MNI space, with center (C_i) as categorical, fixed-effects factor and total tissue volume (V_i) as covariates:

$$y_i = \beta_0 + \beta_1 G_i + \beta_2 C_i + \beta_3 V_i + \epsilon_i,$$

with ϵ as the residual error. Between-group differences were estimated from the coefficient β_1 normalized by the corresponding standard error. Permutation testing was used to assess statistical significance, and regional relationships were tested at the level of voxel clusters. Full details of the inference procedure are given elsewhere⁴¹ (see also, eAppendix).

GROUP DIFFERENCES IDENTIFIED BY PARTIAL LEAST-SQUARES ANALYSIS

To confirm by independent analysis the gray matter and white matter systems distinguishing ASD and control groups, we used the statistical technique of partial least-squares (PLS).⁴² For implementation, we used PLSGUI software (<http://www.rotman-baycrest.on.ca/pls/>), which has been extensively described.^{31,43,44} A permutation test ($n=500$) was used to evaluate the association (denoted by d) between regional gray and white matter volume and group membership. Brain systems strongly correlated with group membership were visualized by thresholding the correlations at each voxel at an arbitrary level, $|r_i| > 0.15$ and a minimum cluster size of 75 voxels (see eAppendix for details).

RELATING BEHAVIORAL VARIATION TO BRAIN ANATOMY

The relationships between regional anatomic abnormalities and domains of symptom severity were explored using Pearson correlation coefficients. Within the ASD group, we examined correlations between gray matter within regions showing a significant between-group difference and the 3 domains of the ADI-R measuring past symptoms at ages 4 to 5 years and the total ADOS scores (communication + social interaction) of current symptom severity.

RESULTS

PARTICIPANT DEMOGRAPHICS

There were no significant differences (2-tailed) between the ASD and control groups with regard to age ($t_{176} = -1.72, P = .07$) or full-scale IQ ($t_{176} = -1.82, P = .09$). However, the groups differed significantly in performance IQ ($t_{176} = -3.82, P < .001$). Also, as expected, in line with previous studies, there was a significant group difference in Autism Spectrum Quotient ($t_{173} = 13.91, P < .001$).

GLOBAL BRAIN MEASURES

There were no significant group differences in total volume of brain, gray matter, and white matter (**Table 2**). Using the Levene test, we found no evidence of heterogeneity of variance in total brain volume ($F_{176} = 2.53, P = .61$), gray matter volume ($F_{176} = 0.01, P = .93$), or white matter volume ($F_{176} = 0.32, P = .56$) (see also **Figure 1**). Within the control group (but not the ASD group), total white matter volume decreased significantly with age ($r_{87} = -0.22, P = .02$). However, there were no significant age-related between-group differences in global brain measures.

BETWEEN-GROUP DIFFERENCES IN REGIONAL GRAY MATTER (VBM)

The voxelwise comparison of gray matter volume between groups revealed significant differences in 4 extensive clusters (permutation test significance, $P = .004$, **Table 3**). Compared with controls, individuals with ASD had a significantly greater (excess) volume in bilateral anterior temporal regions (approximate Brodmann area

Table 2. Global Brain Volumes

Volume, L	Mean (SD)		t_{176}	P Value
	ASD Group	Control Group		
Total brain	1.24 (0.09)	1.26 (0.08)	-1.0	.27
Total GM	0.62 (0.07)	0.63 (0.07)	-0.8	.42
Total WM	0.62 (0.03)	0.63 (0.03)	-1.2	.22

Abbreviations: ASD, autism spectrum disorder; GM, gray matter; WM, white matter.

[BA] 20/21; **Figure 2A**), including the superior temporal pole, the middle and inferior temporal gyrus, and extensions into the posterior and left anterior insula, left caudate, and putamen. Clusters of excess volume were also found in the dorsolateral prefrontal cortex (ie, middle frontal gyrus) and the dorsal precentral and postcentral gyrus (BA2/3/6/8/40, **Figure 2B**).

In addition, individuals with ASD had significantly less gray matter volume in a large cluster located in the occipital lobe and medial parietal cortex (BA17-19/30-31/37; **Figure 2C**), including the inferior, middle, and superior occipital gyrus; posterior cingulate/precuneus; and cuneus, as well as lingual gyrus and parts of the posterior fusiform gyrus.

We did not observe any significant relationships between age and gray matter volume in clusters of significant group differences, whether considering all participants or each group separately.

BETWEEN-GROUP DIFFERENCES IN REGIONAL WHITE MATTER (VBM)

There were 4 clusters of significant white matter decreases in people with ASD relative to the control individuals (permutation test significance, $P = .005$; **Figure 3** and **Table 4**). The decreased white matter volume could broadly be allocated to the (1) corticospinal and cerebellar tracts; (2) frontal connections, including the uncinate fasciculus and the fronto-occipital fasciculus; (3) internal capsule comprising descending frontostriatal and thalamocortical ascending projections; and (4) arcuate fasciculus connecting the Broca and Wernicke areas.

DIFFERENCES IN NEURAL SYSTEMS (PLS)

The PLS analysis revealed a significant correlation between group membership (ASD vs controls) and gray matter and white matter volume ($d = 48.82$, permutation test, $P = .002$). As expected, the anatomic map of voxels significantly positively and negatively correlated with group membership was highly spatially distributed (**Figure 4**). In the positively correlated system (**Table 5**), ASD was associated with increased gray matter volume. This network comprised similar regions of bilateral excess gray matter, as reported in the subsection, "Between-Group Differences in Regional Gray Matter (VBM)" for the voxelwise comparison plus a set of structures including the cerebellum, inferior parietal lobe, anterior and mid-cingulate cortex, supplementary motor area, and dorsal and ventral medial prefrontal cortex.

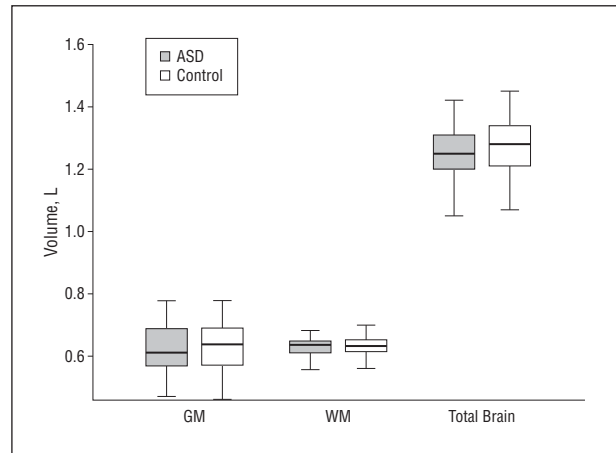


Figure 1. Box plots of global brain measures across the autism spectrum disorder (ASD) and control groups for total gray matter (GM), total white matter (WM), and total brain volume. The horizontal line near the middle of each box indicates the median, while the top and bottom borders of the box mark the 25th and 75th percentiles, respectively. The whiskers above and below the box mark the range of the distribution (maximum and minimum, respectively).

In the negatively correlated system, ASD was associated with reduced gray matter volume. In addition to regions of gray matter deficit, also reported with for the voxelwise comparison, this system included bilateral cerebellum, lateral orbitofrontal cortex, left dorsolateral prefrontal cortex (BA8), right supramarginal gyrus (BA40), and left globus pallidus extending into the amygdala.

The anatomic PLS map of white matter voxels significantly correlated with group membership was similar to the regions of white matter deficit identified by the voxelwise comparison (see the eAppendix and eFigures 3 and 4 for details).

CORRELATION BETWEEN BEHAVIORAL VARIATION AND BRAIN ANATOMY

Within the ASD group, there were significant negative correlations between the occipital cluster, where individuals with ASD displayed a significant decrease in gray matter volume, and higher scores in both the ADI-R social ($r = -0.24$, $P = .01$) and communication ($r = -0.24$, $P = .01$) domains (**Table 6**). We also observed a significant negative correlation between the repetitive domain of the ADI-R and gray matter volume of the left frontal cluster ($r = -0.18$, $P = .04$). Thus, individuals with more severe autistic symptoms in these domains at the age of 4 to 5 years displayed significantly larger gray matter deficits in the occipital lobe, whereas larger gray matter excesses in the frontal lobe were associated with more severe repetitive symptoms. However, correlations were significant at a threshold uncorrected for multiple comparisons and should hence be interpreted as trends.

Within the ASD group, a significant positive correlation was observed between the social domain of the ADI-R and gray matter increases in the left temporal cluster ($r = 0.23$, $P = .01$) (**Figure 5**). These data indicate that individuals with greater social difficulties at a young age display an increase in temporal gray matter volume. No significant correlations were found between volume and any of the ADOS domain scores.

Table 3. Significant Differences in Gray Matter Volume in Individuals With ASD vs Control Participants (VBM)

Cluster ^{a,b}	Region	BA	Hemisphere	MNI Coordinates, mm			Maximal ^b
				x	y	z	
ASD > Control							
1. Right anterior temporal cluster Centroid: 38, 4, -26 Maximal: -3.82	Inferior temporal gyrus	21	R	66	-16	-22	-2.93
	Middle temporal gyrus	21	R	58	-4	-14	-3.44
	Superior temporal gyrus	38	R	38	4	-26	-3.82
	Fusiform gyrus	20	R	62	-16	-30	-3.40
	Parahippocampal gyrus	...	R	36	0	-24	-2.46
2. Left anterior temporal cluster Centroid: -32, -28, 6 Maximal: -4.86	Insula	...	R	40	-18	-8	-3.18
	Inferior temporal gyrus	21	L	-52	-6	-26	-2.35
	Middle temporal gyrus	21	L	-58	-22	-16	-3.93
	Superior temporal gyrus	38	L	-42	4	-26	-3.86
	Fusiform gyrus	20	L	-42	-2	-28	-3.14
	Parahippocampal gyrus	...	L	-34	-6	-18	-2.83
	Inferior frontal gyrus	47	L	-34	32	-2	-3.29
	Putamen	...	L	-20	18	-6	-4.16
	Caudate nucleus	...	L	-10	16	-10	-3.05
	Thalamus	...	L	-24	-26	8	-2.57
	Insula	...	L	-40	-22	0	-3.64
3. Right dorsolateral prefrontal cluster Centroid: 44, -22, 50 Maximal: -3.81	Postcentral gyrus	40	L	-56	-24	24	-2.57
	Middle frontal gyrus	6	R	50	-2	42	-3.07
	Precentral gyrus	3	R	44	-20	50	-3.77
	Postcentral gyrus	2	R	44	-22	50	-3.81
4. Right dorsolateral prefrontal cluster Centroid: -38, -18, 50 Maximal: -3.99	Inferior parietal lobule	40	R	54	-34	40	-2.85
	Middle frontal gyrus	8	L	-22	22	48	-2.79
		8	L	-20	28	46	-3.48
		8	L	-16	32	44	-3.00
	Precentral gyrus	3	L	-38	-18	50	-4.00
	Postcentral gyrus	3	L	-34	-22	50	-3.54
ASD < Control							
1. Occipital/medial parietal cluster Centroid: 18, -92, -10 Maximal: 4.94	Inferior temporal gyrus	37	R	52	-62	-16	2.46
	Middle temporal gyrus	19	R	40	-84	22	3.29
	Cerebellum/declive	...	R	30	-84	-24	2.99
	Fusiform gyrus (posterior)	19	R	28	-84	-18	3.19
	Lingual gyrus	18	R	18	-92	-10	4.95
	Inferior occipital gyrus	18	L	-34	-94	-10	3.95
		18	R	38	-98	-2	4.08
	Cuneus	17	R	12	-96	2	4.56
	Precuneus	31	R	0	-68	16	3.35
	Posterior cingulate	30	R	6	-72	12	3.87
	Superior occipital gyrus	19	R	40	-86	22	3.07

Abbreviations: ASD, autism spectrum disorder; BA, Brodmann area; ellipses, not applicable; L, left; MNI, Montreal Neurological Institute; R, right; VBM, voxel-based morphometry.

^aCluster coordinates are listed at maximal test statistic.

^bMaximal values are statistical test parameters.

COMMENT

We report results from what we believe to be the first large-scale multicenter MRI study to investigate the neuroanatomy of ASD in a well-characterized sample of men meeting the ADI-R research diagnostic criteria for childhood autism. In this sample, men with ASD did not differ significantly from those in the control group on global volume measures but displayed regionally specific differences in gray matter and white matter volume. Individuals with ASD showed increased gray matter in the anterior temporal and dorsolateral prefrontal regions but decreased gray matter volume in the occipital and medial parietal regions. In addition, the large-scale gray matter systems associated with ASD in adults comprised the cingulate gyrus, supplementary motor area, basal gan-

glia, amygdala, inferior parietal lobule, and cerebellum, as well as dorsolateral prefrontal, lateral orbitofrontal, and dorsal and ventral medial prefrontal cortices. Variation in gray matter volume correlated with specific symptom domains within the ASD group. Furthermore, we found that ASD in adults was accompanied by spatially distributed reductions in regional white matter volume. Our findings support the suggestion that regional neuroanatomic abnormalities in ASD persist into adulthood and are linked to specific autistic symptoms.

TOTAL BRAIN VOLUME IN ASD DURING ADULTHOOD

We first found that high-functioning individuals with ASD do not have an increase in overall brain volume

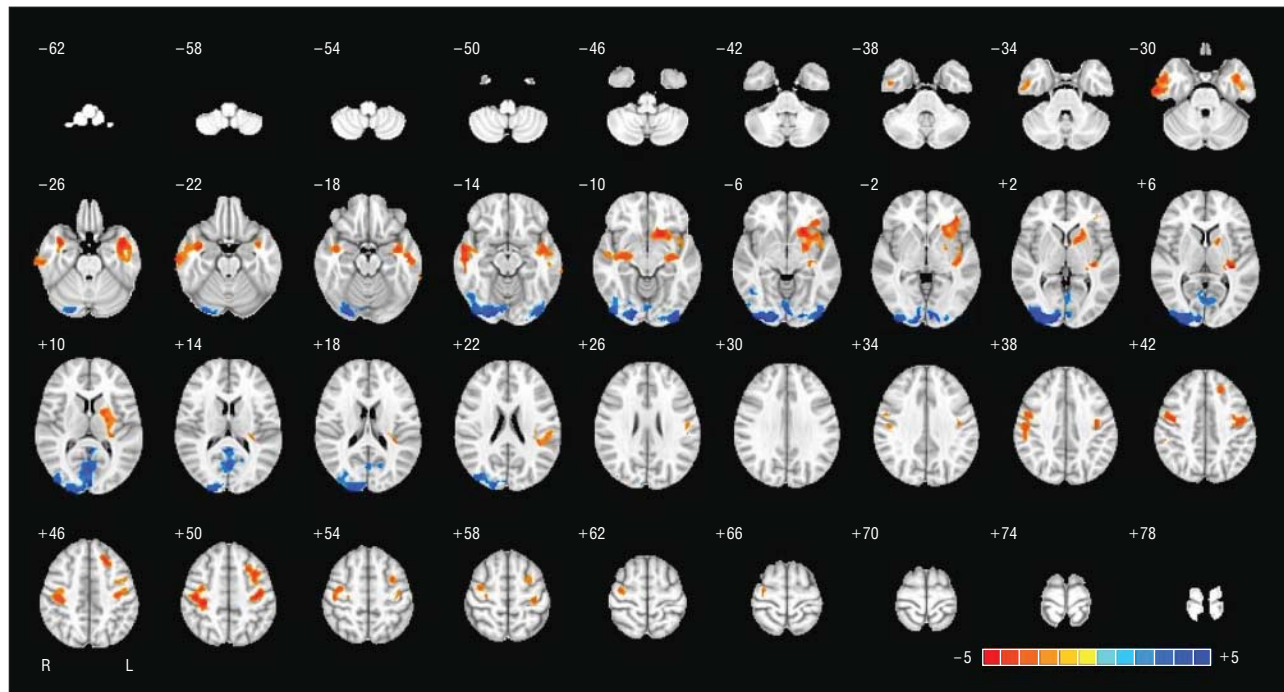


Figure 2. Brain map (voxel-based morphometry) of significant gray matter differences in autism spectrum disorder (ASD) ($P=.004$). Relative excesses in gray matter volume in adults with ASD compared with control participants are displayed in orange/red for temporal cluster and frontal cluster; deficits are displayed in blue for occipital cluster. The maps are oriented with the left side of the brain shown on the left side of each panel. The z-coordinates for each axial section in the standard space of Montreal Neurological Institute coordinates are reported in millimeters. L indicates left; R, right. The numbers at each end of the color key are given in t values.

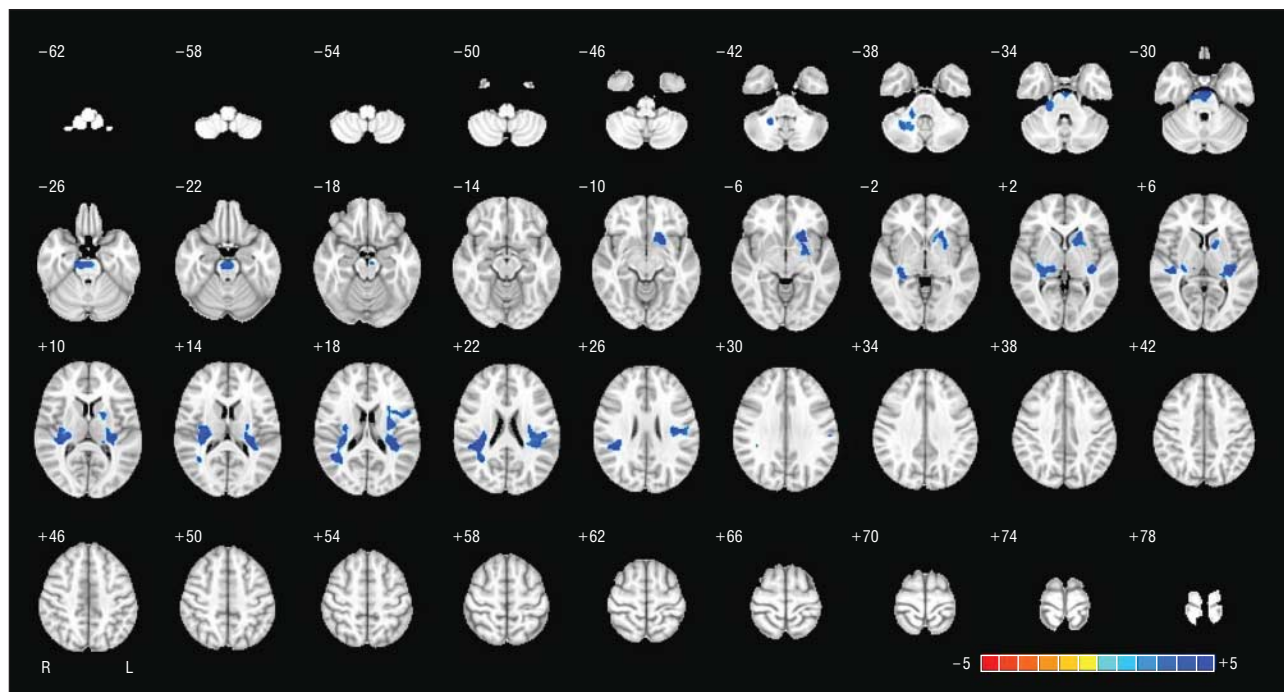


Figure 3. Brain map (voxel-based morphometry) of significant white matter differences in autism spectrum disorder (ASD) ($P=.005$). Relative deficits in white matter volume in adults with ASD compared with control individuals are displayed in blue; no excesses were observed. The maps are oriented with the left side of the brain shown on the left side of each panel. The z-coordinates for each axial section in the standard space of Montreal Neurological Institute coordinates are reported in millimeters. L indicates left; R, right. The numbers at each end of the color key are given in t values.

during adulthood. This is consistent with the notion that the abnormality in total brain size reported by others during early postnatal life “normalizes” by later life. In typical development, total brain volume pla-

teaus at approximately age 13 years and starts to decrease in early adulthood.⁴⁶ However, the neurodevelopmental trajectory for total brain volume is atypical in ASD, with an increased rate of macrocephaly⁴⁷

Table 4. Significant Differences in White Matter Volume in Individuals With ASD vs Control Participants (VBM)

Cluster ^a	Tract-Specific Label	Nearest Gray Matter Label	BA	Hemisphere
ASD < Control				
1. Centroid: -4, -18, -20 Maximal: 3.22	Corticospinal tract	Cerebellar tonsil	...	R
	Corticoponto-cerebellar tract	Culmen	...	
2. Centroid -20, 18, -6 Maximal: 3.95	Uncinate fasciculus Inferior fronto-occipital fasciculus Anterior thalamic projections	Inferior frontal gyrus	...	L
		Extranuclear	...	
		Caudate nucleus	...	
		Lentiform nucleus	...	
		Anterior cingulate	...	
3. Centroid 38, -38, 22 Maximal: 4.03	Arcuate fasciculus	Clastrum	...	R
		Middle temporal gyrus	27	
		Superior temporal gyrus	22	
		Subgyral	13	
		Lateral ventricle	13	
		Extranuclear	27	
		Caudate	...	
		Lentiform nucleus	...	
		Thalamus	...	
		Insula	...	
		Clastrum	13	
		Transverse temporal gyrus	...	
4. Centroid -34, -26, 6 Maximal: 4.28	Arcuate fasciculus	Inferior parietal lobule	41	L
		Superior temporal gyrus	13	
		Subgyral	13	
		Inferior frontal gyrus	44	
		Extranuclear	...	
		Lentiform nucleus	...	
		Thalamus	...	
		Insula	13	
		Clastrum	...	
		Transverse temporal gyrus	41	
Postcentral gyrus	40			
Inferior parietal lobule	40			

Abbreviations: ASD, autism spectrum disorder; BA, Brodmann area; ellipses, not applicable; L, left; R, right; VBM, voxel-based morphometry.

^aCluster coordinates are listed for cluster centroids; tract-specific labels correspond to regions of >90% overlap with white matter atlas⁴⁵; gray matter labels closest to the cluster of significant white matter difference.

accompanied by a larger brain volume⁴⁸ and/or more rapid brain growth than in healthy individuals during early postnatal life.^{9,49} This initial “overgrowth” in infants with ASD may then be followed by a deceleration during later childhood⁵⁰ so that no differences in total brain volume are expected during adulthood. Such abnormal brain enlargement is disproportionately accounted for by a relatively larger increase in total white matter than gray matter,⁵¹ with each displaying a differential growth trajectory. Although total gray matter volume reaches a peak before adulthood, white matter continues on a linear upward trend during adolescence.⁵² Our study is therefore consistent with the proposal that total brain volume and its 2 constituents (ie, gray matter and white matter) have normalized by later life, and hence agrees with some (but not all) studies of whole brain volume in people with ASD during adolescence¹¹ and adulthood.^{12,13} Furthermore, there were no significant between-group differences in age-related effects on total brain volume. These results suggest that, in adulthood, global brain measures are unaffected in individuals with ASD without intellectual disability.

REGIONAL INCREASES IN GRAY MATTER VOLUME

In contrast to earlier development, when most of the neuroanatomic differences may be related to global differences, most of the differences in ASD in adults appear to be linked to specific neural systems. Local differences in neuroanatomy were initially investigated with VBM. We found that people with ASD displayed significant differences in the anatomy of a number of brain regions. One region with significantly increased gray matter volume was the anterior temporal lobe (overlapping with the superior temporal pole). Left-hemisphere increases in this region were correlated with increased social, but not repetitive or communicative, symptom severity observed on the ADI-R. Prior studies have detected gray matter differences in this area across childhood,³³ adolescence,³⁴ and young adulthood.^{16,22} In addition, the temporal pole has attracted much attention as being integral for high-level social cognitive processes, such as mentalizing or theory of mind⁵⁴ and semantic processing.⁵⁵ Autism studies using functional MRI suggest that the recruit-

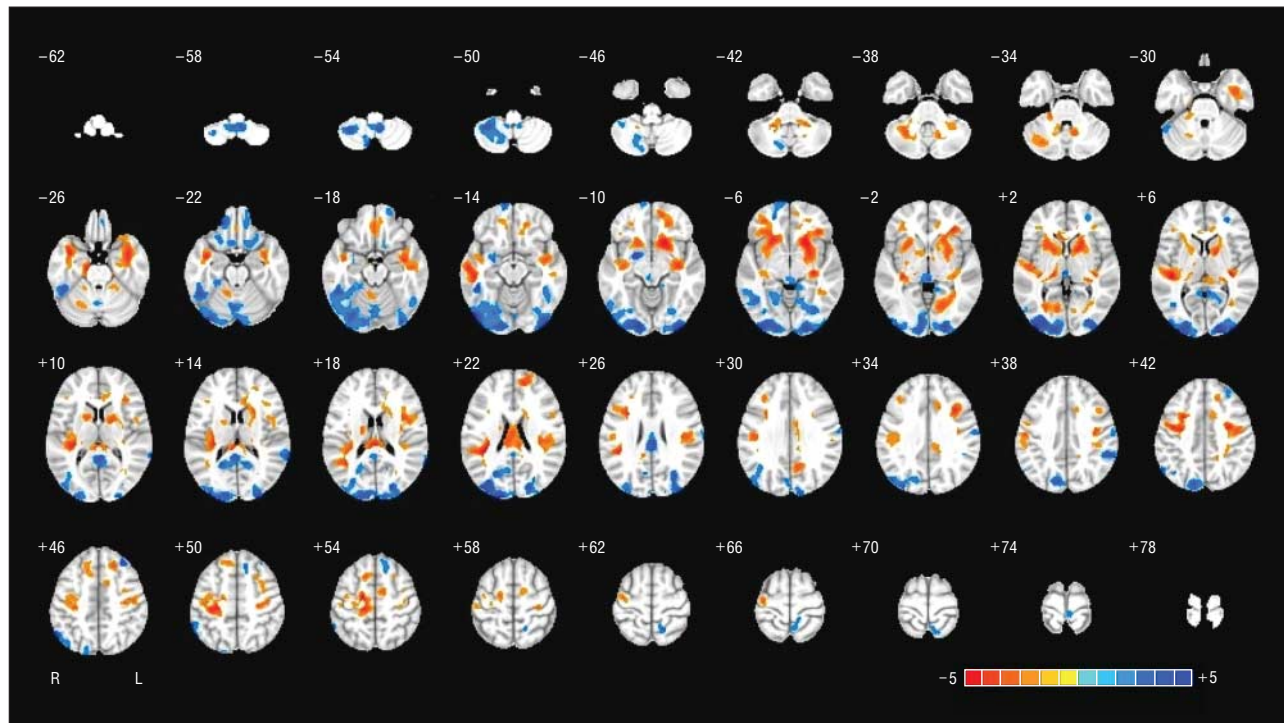


Figure 4. Brain map (partial least-squares analysis) illustrating regions where gray matter volume was associated with group membership. Orange/red regions indicate areas with a positive association between gray matter volume and autism spectrum disorder (ASD) (ie, ASD > control); blue regions indicate brain systems of decreased gray matter volume in the ASD group. The maps are oriented with the right side of the brain shown on the left side of each panel. The z-coordinates for each axial section in the standard space of Montreal Neurological Institute coordinates are reported in millimeters. The numbers at each end of the color key are given in *t* values.

ment of anterior temporal lobe/temporal pole is atypical across social cognitive tasks with mentalizing demands such as irony processing,⁵⁶ emotional introspection,⁵⁷ attributing mental states to geometric shapes⁵⁸ as well as language tasks with semantic demands,⁵⁹ and stimulus-oriented processing.⁶⁰ Therefore, this finding further corroborates the important role of anterior temporal regions in mediating autism-related impairments, specifically in the social domain, during adulthood.

We also observed increased gray matter volume in the dorsolateral prefrontal cortex and the dorsal precentral and postcentral gyrus. Prior research reported that people with ASD have differences in frontal lobe neuronal integrity,⁶¹ function,⁶²⁻⁶⁴ anatomy,^{22,34,65,66} and connectivity.¹⁷ In addition, dorsolateral prefrontal cortex and precentral and postcentral gyrus have been reported as atypical in ASD, tapping a variety of “control” processes, such as overcoming prepotent motor responses,⁶⁷ visually guided saccades, smooth pursuit⁶⁸ and saccade inhibition,⁶⁹ fine motor sequencing, and visuomotor learning.^{70,71} These areas are part of a general hierarchical cognitive control network^{72,73} and are particularly important for executive function in ASD.

Given that there may be delay in frontal lobe maturation,⁷⁴ in addition to being implicated in executive dysfunction in autism, such frontal abnormalities may underpin some of the impairments in the repetitive behavior domain.^{25,75} In this study, we found that the volume of the left dorsolateral prefrontal cluster covaried with the severity of symptoms in the repetitive domain of the ADI-R in the ASD group. This result agrees with previous neu-

roimaging studies suggesting that abnormalities in frontostriatal-thalamic circuitry mediating some of the repetitive behaviors typically found in ASD may overlap with mediating symptoms observed in people with obsessive-compulsive disorder.^{22,25,31,76} We also found significant volumetric differences in the basal ganglia and thalamus in our sample of men with ASD, which substantiates these previous observations. Our results therefore add to increasing evidence that individuals with ASD have abnormalities in frontostriatal systems extending into adulthood and that structural abnormalities in frontal regions are related to the severity of ritualistic repetitive behavior observed in ASD.

REGIONAL DECREASES IN GRAY MATTER VOLUME

Individuals with ASD had a significant decrease in gray matter volume in a large cluster located in the occipital and medial parietal regions. In addition, variation in this cluster was associated with the severity of social and communication symptoms in ASD. These results are consistent with the role of medial parietal regions such as the posterior cingulate cortex/precuneus in mentalizing, theory of mind, emotion, and projection processes critical for social development.⁷⁷⁻⁷⁹ Increasing MRI evidence in autism has also been reported for both functional and anatomic differences in the occipital cortex.^{16,34,80,81} For example, hyperactivation (ASD > controls) of low-level visual cortices overlapping with our VBM result has been observed across a variety of tasks tapping visuospatial (eg,

Table 5. Anatomic Details for Brain Systems Where GM Volume Was Positively or Negatively Correlated With Group Membership (PLS)

Region	BA	Hemisphere	MNI Coordinates, mm			<i>r</i> ^a
			x	y	z	
Positive Correlations Between GM Volume and Group Membership (ASD > Control)						
Cerebellar tonsil		L	-34	-52	-40	0.21
		R	36	-50	-40	0.18
Superior temporal gyrus	38	L	-40	0	-22	0.32
	38	R	38	4	-22	0.21
Parahippocampal gyrus		L	-36	-2	-24	0.16
		R	32	-12	-24	0.17
Fusiform gyrus (anterior)	20	L	-40	-10	-28	0.16
	20	R	46	-10	-30	0.20
Middle temporal gyrus	21	L	-56	-34	-16	0.21
	21	R	54	-22	-16	0.20
Ventral medial prefrontal cortex	10	L	-4	42	-18	0.18
Supplementary motor area	6	L	-10	-18	54	0.21
	6	R	6	-4	54	0.18
Dorsal medial prefrontal cortex	8	L	-4	30	50	0.16
Inferior frontal gyrus	10	L	-42	50	-4	0.16
Caudate nucleus		L	-12	20	-8	0.20
		R	12	20	-8	0.20
Insular cortex	13	L	-42	-14	-8	0.20
		R	42	-18	-8	0.17
Lingual gyrus	18	L	-12	-70	2	0.25
	18	R	10	-74	2	0.15
Thalamus		L	-14	-18	4	0.20
Inferior parietal lobe	40	L	-52	-40	26	0.16
	40	R	54	-26	26	0.16
Precentral gyrus	44	R	52	6	8	0.15
	4	R	40	-18	54	0.16
	4	L	-38	-12	54	0.18
Postcentral gyrus	3	R	38	-20	50	0.21
	3	L	-34	-24	50	0.22
Mid-cingulate cortex	23/24	L	0	-16	32	0.17
Anterior cingulate cortex		R	12	38	-6	0.16

Negative Correlations Between GM Volume and Group Membership (ASD < Control)						
Cerebellum		L	-38	-46	-48	-0.25
Inferior occipital gyrus	18	R	32	-94	0	-0.16
		L	-36	-96	0	-0.24
Middle occipital gyrus	19	L	-30	-82	24	-0.26
		R	30	-86	24	-0.27
Superior occipital gyrus	19	L	-40	-80	34	-0.17
Fusiform gyrus (posterior)	37	R	50	-62	-18	-0.19
		L	-52	-52	-20	-0.22
Lingual gyrus	17-19	R	10	-100	-6	-0.17
		L	-16	-100	-6	-0.17
Posterior cingulate	29	R	6	-56	12	-0.17
Cingulate gyrus		L	0	-12	28	-0.26
Cuneus	19	L	-6	-78	38	-0.21
Postcentral gyrus	3	R	62	-12	34	-0.21
Supramarginal gyrus	40	R	64	-42	38	-0.19
Superior temporal gyrus	22	R	66	-50	16	-0.20
Lateral orbitofrontal cortex	10	L	-14	68	-12	-0.19
Middle frontal gyrus	8	R	30	36	46	-0.19
Globus pallidus/amygdala		L	-18	0	-10	-0.30

Abbreviations: ASD, autism spectrum disorder; BA, Brodmann area; GM, gray matter; L, left; MNI, Montreal Neurological Institute; PLS, partial least-squares; R, right.

^aStrength of association between group membership and GM volume at cluster centroid.

motion processing, embedded figures, visuospatial learning, matrix reasoning, and stimulus-oriented processing)^{71,82-88} and language processing (eg, lexical decision and text comprehension with visual imagery demands).^{59,89} Thus, one possible explanation for en-

hanced perceptual function in some individuals with autism may be linked to structural variation of cortices processing bottom-up information. Some studies^{90,91} have also suggested that neuroanatomic abnormalities in the visual cortex may at least partially contribute to some of

Table 6. Correlation Coefficients Between Significant Gray Matter Clusters and Diagnostic Measures

Cluster	ADI-R Social (n = 89)	ADI-R Communication (n = 89)	ADI-R Repetitive Behavior (n = 89)	ADI-R Total (n = 89)	ADOS Total (n = 86)
1. Right temporal	0.15	0.18	-0.08	0.12	0.04
2. Left temporal	0.23 ^a	0.09	-0.09	0.15	0.08
3. Right frontal	0.08	-0.03	-0.08	0.01	0.08
4. Left frontal	0.24	-0.19	-0.18 ^a	-0.04	0.03
5. Occipital	-0.24 ^a	-0.24 ^a	-0.01	-0.25 ^a	-0.03

Abbreviations: ADI-R, Autism Diagnostic Interview–Revised; ADOS, Autism Diagnostic Observation Schedule.

^aSignificant correlation at $P < .05$ (uncorrected for multiple comparisons); there were no significant correlations between regional volumes and ADOS subscales.

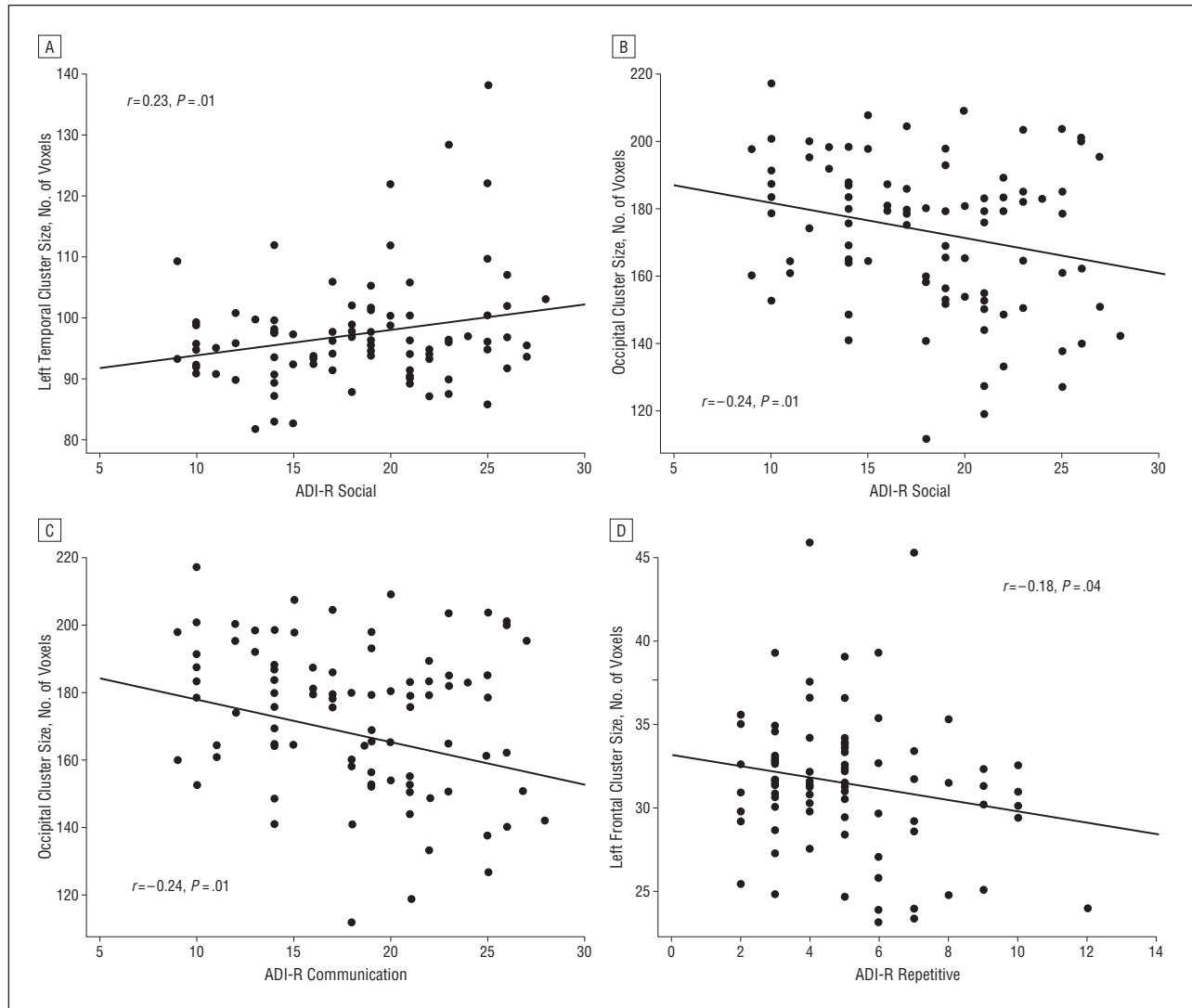


Figure 5. Scatterplots of the relationships between regional gray matter volumes in clusters of significant between-group difference and autistic symptom domains measured by the Autism Diagnostic Interview–Revised (ADI-R) in the autism spectrum disorder (ASD) group. A, Correlation between the temporal cluster (ASD > control) and symptoms in the social domain. B, Correlation between occipital cluster (ASD < control) and symptoms in the social domain. C, Correlation between occipital cluster (ASD < control) and symptoms in the communication domain. D, Correlation between frontal cluster (ASD > control) and symptoms in the repetitive domain.

the characteristic social abnormalities in ASD. Poor processing of eye gaze and facial expression, for instance, relies heavily on primary visual processes, which, if impaired, may have significant detrimental effects on the ability to communicate socially.⁹² Our study therefore sug-

gests that the medial parietal and occipital cortex are key brain structures in ASD and that structural variations in this region may be related to enhanced visuospatial processing, perceptual function, and/or social-communication deficits.

GRAY MATTER SYSTEMS ASSOCIATED WITH ASD

Autistic spectrum disorder is a highly heterogeneous disorder with multifactorial etiologic characteristics.⁹³ More recent theoretical models therefore suggest the need to consider ASD as a disorder of several large-scale neurocognitive networks.⁹³⁻⁹⁶ Regional or voxel-level analytic methods may, however, not be optimal for detecting differences that are theoretically expected at a more distributed level. Subsequent to VBM, we therefore used a multi-voxel approach (PLS)^{31,42-44} to identify gray matter systems maximally correlated with ASD.

Partial least-squares analysis revealed a spatially distributed network of regions where gray matter volume was highly correlated with ASD. This pattern included regions detected by the voxelwise approach but also identified an additional set of network components such as the cerebellum; and dorsolateral, orbital, and ventral medial prefrontal cortex, and limbic regions, such as the cingulate cortex and amygdala. All these network components have been reported,^{13,22,34,97} and some have been related to symptoms. For example, differences in limbic regions have been linked to impairments in socioemotional processing and face processing⁹⁸⁻¹⁰⁰; the medial prefrontal cortex is critical for typically developing social cognition and empathy^{101,102} and has also been linked to atypical mentalizing or theory of mind^{103,104} and self-referential cognition in ASD.^{105,106} These regions should hence be considered part of the wider neural systems mediating autistic symptoms and traits.

Notably, PLS analysis identified networks of positive and negative associations with group membership, often in close spatial proximity (eg, within the cerebellum). This further supports the notion that our results do not reflect global differences in neuroanatomy but indicate subtle and spatially distinct networks of regions implicated in adults with ASD. Given the composition of the sample, these neural systems likely reflect the end result of atypical cortical development of gray matter rather than represent the primary neuropathologic characteristics of the condition, which is best investigated in younger age groups. Large longitudinal studies are therefore required to disentangle the effects of pathologic factors and brain maturation in ASD, as well as to isolate which neuroanatomic changes are primary and which are secondary to the condition (eg, via compensatory mechanisms).

WHITE MATTER DIFFERENCES IN ASD

The neuroanatomic differences observed for gray matter were accompanied by spatially distributed reductions in white matter volume. White matter abnormalities have been reported in individuals with ASD. For example, studies found that people with ASD have significant differences in white matter volume^{17,23,107} and microstructural integrity as measured by diffusion tensor MRI.¹⁰⁸⁻¹¹² Furthermore, it has been reported^{113,114} that individuals with ASD undergo abnormal postnatal white matter development. Such prior reports mostly highlight significant increases in white matter during early childhood, which may precede the abnormal pattern of

growth in gray matter.⁵¹ Similar to other investigators,^{34,115} however, we found that during adulthood, individuals with ASD predominantly displayed a pattern of regional white matter reductions. This discrepancy could be caused by differences in neurodevelopmental trajectories of white matter between groups, although large longitudinal data sets would be required to further elucidate such age \times group interactions.

White matter deficits in ASD have often been interpreted as one of the neurobiologic foundations of "atypical connectivity" theories in autism.^{93,96} Disconnection syndromes are generally defined as disorders of higher function resulting from a "disconnecting" breakdown of associative connections through white matter lesions.^{116,117} More specifically, it has been suggested that in ASD, higher-order association areas typically connected to the frontal lobe are atypically connected (ie, both underconnectivity and overconnectivity) during development^{118,119} and that people with ASD have pervasive core processing deficits resulting from a "developmental disconnection syndrome." For example, it has been reported⁹⁵ that functional connectivity of medial temporal lobe structures is abnormal in people with Asperger syndrome during fearful face processing. There is also evidence that anatomic underconnectivity between frontal and parietal areas affects executive functioning and is accompanied by abnormalities in connecting fibers, including the corpus callosum,⁹⁴ and differences in the neurodevelopmental trajectory of white matter in ASD on the global and regional level.^{8,113,120} Our findings support the notion that adults with ASD have atypical connectivity (in white matter volume) in addition to local differences in gray matter volume. Thus, although it is difficult to link specific cognitive functions to white matter deficits, altered brain connectivity, together with the structural alterations within specific gray matter regions, may explain some of the behavioral features observed in ASD.

METHODOLOGIC CONSIDERATIONS

Our study raises a number of methodologic issues. First, we investigated neuroanatomy in a sample of high-functioning men, using the ADI-R as a diagnostic tool, which is not representative of all individuals on the autism spectrum. The ADI-R rather than ADOS scores were chosen as exclusion criteria because current symptoms assessed in adult samples can often be masked by coping strategies developed as the person ages and can also be alleviated by treatments/interventions (eg, social skills training). Hence, it is not uncommon for individuals to meet ADI-R but not ADOS diagnostic criteria during adulthood. Our sample therefore represents a subpopulation of the autistic phenotype, and results should be interpreted in light of this. In addition, we did not distinguish between putative subtypes of ASD (eg, high-functioning autism and Asperger syndrome). Evidence¹²¹ suggests that, by adulthood, these groups are largely indistinguishable clinically or cognitively. However, the extent to which these groups differ at the level of brain anatomy is unknown and requires investigation.

Second, a multicenter design was used for MRI data acquisition to overcome single-site recruitment limita-

tions. A recently developed acquisition protocol that standardizes structural MRI data across multiple platforms and acquisition parameters was used.³⁹ Such quantitative imaging¹²²⁻¹²⁴ holds a number of advantages over conventional qualitative T1-weighted imaging because it not only minimizes intersite variance but also offers improved signal-to-noise contrast. In addition, intersite effects were accounted for in the statistical model.^{125,126} Therefore, the detected between-group differences cannot be fully explained by these limitations.

Finally, the voxelwise analysis has inherent limitations. For instance, cortical volume comprises 2 sub-components (cortical thickness and surface area), which in turn have different cellular components and developmental determinants.¹²⁷ Research is needed to determine which specific aspects of the cortical morphologic characteristics are causing the observed differences in tissue concentration, as well as how these relate to autistic symptoms.

In summary, our results suggest that adults with ASD do not have a significant increase in overall brain volume, but they do have regional differences in brain anatomy, which are correlated with specific autistic symptoms. We also found that ASD is associated with distributed abnormalities of both gray matter and white matter volume in cortical and subcortical systems, and this is compatible with the concept of autism as a brain connectivity/underconnectivity syndrome.

Submitted for Publication: January 14, 2011; final revision received June 3, 2011; accepted July 15, 2011.

Author Affiliations: Department of Forensic and Neurodevelopmental Sciences (Drs Ecker, Deoni, Catani, and Murphy) and Centre for Neuroimaging Sciences (Dr Williams), Institute of Psychiatry, King's College London, London, England; Brain Mapping Unit (Drs Suckling, Bullmore, and Barnes), Autism Research Centre (Drs Lombardo and Baron-Cohen), and Department of Psychiatry (Drs Suckling, Lombardo, Bullmore, Baron-Cohen, and Barnes), University of Cambridge, Cambridge, England; and FMRIB Centre (Oxford Centre for Functional Magnetic Resonance Imaging of the Brain) (Dr Jezzard) and Oxford Autism Research Group, Department of Psychiatry (Dr Bailey), University of Oxford, Oxford, England.

Correspondence: Christine Ecker, MSc, PhD, Department of Forensic and Neurodevelopmental Sciences, Campus PO Box 50, Institute of Psychiatry, De Crespigny Park, London SE5 8AF, England (christine.ecker@kcl.ac.uk). **The MRC AIMS Consortium:** Anthony J. Bailey, MD, PhD; Simon Baron-Cohen, PhD, FBA; Patrick Bolton; Ed T. Bullmore, MB, FRCPsych; Sarah Carrington, PhD; Bishmadev Chakrabarti, PhD; Eileen M. Daly; Sean C. Deoni, PhD; Christine Ecker, MSc, PhD; Francesca Happé, PhD; Julian Henty, PhD; Peter Jezzard, PhD; Patrick Johnston, PhD; Derek K. Jones, PhD; Meng-Chuan Lai, PhD; Michael V. Lombardo, PhD; Anya Madden; Diane Mullins, MD; Clodagh M. Murphy, MD; Declan G. M. Murphy; Greigg Pasco; Susan Sadek; Debbie Spain; Rose Stewart; John Suckling, PhD; Sally Wheelwright; and Steven C. Williams, PhD.

Financial Disclosure: Dr Bullmore is employed half-time by GlaxoSmithKline and holds GlaxoSmithKline shares.

Funding/Support: This work was undertaken by the AIMS Consortium funded by the MRC UK (G0400061).

Online-Only Material: The eAppendix, eTable, and eFigures are available at <http://www.archgenpsychiatry.com>.

Additional Contributions: Local principal investigators included Drs Murphy, Bullmore, Baron-Cohen, and Bailey. We are grateful to the individuals who agreed to undergo MRI and who gave their time so generously to this study.

REFERENCES

- Baird G, Simonoff E, Pickles A, Chandler S, Loucas T, Meldrum D, Charman T. Prevalence of disorders of the autism spectrum in a population cohort of children in South Thames: the Special Needs and Autism Project (SNAP). *Lancet*. 2006;368(9531):210-215.
- Baron-Cohen S, Scott FJ, Allison C, Williams J, Bolton P, Matthews FE, Brayne C. Prevalence of autism-spectrum conditions: UK school-based population study. *Br J Psychiatry*. 2009;194(6):500-509.
- Gillberg C. Autism and related behaviours. *J Intellect Disabil Res*. 1993;37(pt 4):343-372.
- Wing L. The autistic spectrum. *Lancet*. 1997;350(9093):1761-1766.
- Toal F, Murphy DG, Murphy KC. Autistic-spectrum disorders: lessons from neuroimaging. *Br J Psychiatry*. 2005;187:395-397.
- Amaral DG, Schumann CM, Nordahl CW. Neuroanatomy of autism. *Trends Neurosci*. 2008;31(3):137-145.
- Stanfield AC, McIntosh AM, Spencer MD, Philip R, Gaur S, Lawrie SM. Towards a neuroanatomy of autism: a systematic review and meta-analysis of structural magnetic resonance imaging studies. *Eur Psychiatry*. 2008;23(4):289-299.
- Courchesne E, Karns CM, Davis HR, Ziccardi R, Carper RA, Tigue ZD, Chisum HJ, Moses P, Pierce K, Lord C, Lincoln AJ, Pizzo S, Schreibman L, Haas RH, Akshoomoff NA, Courchesne RY. Unusual brain growth patterns in early life in patients with autistic disorder: an MRI study. *Neurology*. 2001;57(2):245-254.
- Hazlett HC, Poe M, Gerig G, Smith RG, Provenzale J, Ross A, Gilmore J, Piven J. Magnetic resonance imaging and head circumference study of brain size in autism: birth through age 2 years. *Arch Gen Psychiatry*. 2005;62(12):1366-1376.
- Piven J, Arndt S, Bailey J, Andreasen N. Regional brain enlargement in autism: a magnetic resonance imaging study. *J Am Acad Child Adolesc Psychiatry*. 1996;35(4):530-536.
- Aylward EH, Minshew NJ, Field K, Sparks BF, Singh N. Effects of age on brain volume and head circumference in autism. *Neurology*. 2002;59(2):175-183.
- Hallahan B, Daly EM, McAlonan G, Loth F, O'Brien F, Robertson D, Hales S, Murphy C, Murphy KC, Murphy DG. Brain morphometry volume in autistic spectrum disorder: a magnetic resonance imaging study of adults. *Psychol Med*. 2009;39(2):337-346.
- McAlonan GM, Daly E, Kumari V, Critchley HD, van Amelsvoort T, Suckling J, Simmons A, Sigmundsson T, Greenwood K, Russell A, Schmitz N, Happe F, Howlin P, Murphy DG. Brain anatomy and sensorimotor gating in Asperger's syndrome. *Brain*. 2002;125(pt 7):1594-1606.
- Bailey A, Luthert P, Dean A, Harding B, Janota I, Montgomery M, Rutter M, Lantos P. A clinicopathological study of autism. *Brain*. 1998;121(pt 5):889-905.
- Courchesne E, Yeung-Courchesne R, Press GA, Hesselink JR, Jernigan TL. Hypoplasia of cerebellar vermal lobules VI and VII in autism. *N Engl J Med*. 1988;318(21):1349-1354.
- Abell F, Krams M, Ashburner J, Passingham R, Friston K, Frackowiak R, Happé F, Frith U. The neuroanatomy of autism: a voxel-based whole brain analysis of structural scans. *Neuroreport*. 1999;10(8):1647-1651.
- McAlonan GM, Cheung V, Cheung C, Suckling J, Lam GY, Tai KS, Yip L, Murphy DG, Chua SE. Mapping the brain in autism: a voxel-based MRI study of volumetric differences and intercorrelations in autism. *Brain*. 2005;128(pt 2):268-276.
- Saitoh O, Karns CM, Courchesne E. Development of the hippocampal formation from 2 to 42 years: MRI evidence of smaller area dentata in autism. *Brain*. 2001;124(pt 7):1317-1324.

19. Bolton PF, Griffiths PD. Association of tuberous sclerosis of temporal lobes with autism and atypical autism. *Lancet*. 1997;349(9049):392-395.
20. Sears LL, Vest C, Mohamed S, Bailey J, Ranson BJ, Piven J. An MRI study of the basal ganglia in autism. *Prog Neuropsychopharmacol Biol Psychiatry*. 1999;23(4):613-624.
21. Redcay E. The superior temporal sulcus performs a common function for social and speech perception: implications for the emergence of autism. *Neurosci Biobehav Rev*. 2008;32(1):123-142.
22. Rojas DC, Peterson E, Winterrowd E, Reite ML, Rogers SJ, Tregellas JR. Regional gray matter volumetric changes in autism associated with social and repetitive behavior symptoms *BMC Psychiatry*. 2006;6:56. doi:10.1186/1471-244X-6-56.
23. Boddart N, Chabane N, Gervais H, Good CD, Bourgeois M, Plumet MH, Barthélémy C, Mouren MC, Artiges E, Samson Y, Brunelle F, Frackowiak RS, Zilbovicius M. Superior temporal sulcus anatomical abnormalities in childhood autism: a voxel-based morphometry MRI study. *Neuroimage*. 2004;23(1):364-369.
24. Allison T, Puce A, McCarthy G. Social perception from visual cues: role of the STS region. *Trends Cogn Sci*. 2000;4(7):267-278.
25. Langen M, Durston S, Staal WG, Palmén SJ, van Engeland H. Caudate nucleus is enlarged in high-functioning medication-naïve subjects with autism. *Biol Psychiatry*. 2007;62(3):262-266.
26. Aylward EH, Minshew NJ, Goldstein G, Honeycutt NA, Augustine AM, Yates KO, Barta PE, Pearson GD. MRI volumes of amygdala and hippocampus in non-mentally retarded autistic adolescents and adults. *Neurology*. 1999;53(9):2145-2150.
27. Piven J, Saliba K, Bailey J, Arndt S. An MRI study of autism: the cerebellum revisited. *Neurology*. 1997;49(2):546-551.
28. Haznedar MM, Buchsbaum MS, Wei TC, Hof PR, Cartwright C, Bienstock CA, Hollander E. Limbic circuitry in patients with autism spectrum disorders studied with positron emission tomography and magnetic resonance imaging. *Am J Psychiatry*. 2000;157(12):1994-2001.
29. Howard MA, Cowell PE, Boucher J, Brooks P, Mayes A, Farrant A, Roberts N. Convergent neuroanatomical and behavioural evidence of an amygdala hypothesis of autism. *Neuroreport*. 2000;11(13):2931-2935.
30. Ashburner J, Friston KJ. Why voxel-based morphometry should be used. *Neuroimage*. 2001;14(6):1238-1243.
31. Menzies L, Achard S, Chamberlain SR, Fineberg N, Chen CH, del Campo N, Sahakian BJ, Robbins TW, Bullmore E. Neurocognitive endophenotypes of obsessive-compulsive disorder. *Brain*. 2007;130(pt 12):3223-3236.
32. Ecker C, Rocha-Rego V, Johnston P, Mourao-Miranda J, Marquand A, Daly EM, Brammer MJ, Murphy C, Murphy DG; MRC AIMS Consortium. Investigating the predictive value of whole-brain structural MR scans in autism: a pattern classification approach. *Neuroimage*. 2010;49(1):44-56.
33. Ecker C, Marquand A, Mourao-Miranda J, Johnston P, Daly EM, Brammer MJ, Maltezos S, Murphy CM, Robertson D, Williams SC, Murphy DG. Describing the brain in autism in five dimensions—magnetic resonance imaging—assisted diagnosis of autism spectrum disorder using a multiparameter classification approach. *J Neurosci*. 2010;30(32):10612-10623.
34. Waiter GD, Williams JH, Murray AD, Gilchrist A, Perrett DI, Whiten A. A voxel-based investigation of brain structure in male adolescents with autistic spectrum disorder. *Neuroimage*. 2004;22(2):619-625.
35. Lord C, Rutter M, Le Couteur A. Autism Diagnostic Interview—Revised: a revised version of a diagnostic interview for caregivers of individuals with possible pervasive developmental disorders. *J Autism Dev Disord*. 1994;24(5):659-685.
36. Lord C, Rutter M, Goode S, Heemsbergen J, Jordan H, Mawhood L, Schopler E. Autism diagnostic observation schedule: a standardized observation of communicative and social behavior. *J Autism Dev Disord*. 1989;19(2):185-212.
37. Baron-Cohen S, Wheelwright S, Skinner R, Martin J, Clubley E. The autism-spectrum quotient (AQ): evidence from Asperger syndrome/high-functioning autism, males and females, scientists and mathematicians. *J Autism Dev Disord*. 2001;31(1):5-17.
38. Wechsler D. *Wechsler Abbreviated Scale of Intelligence (WASI)*. San Antonio, TX: Harcourt Assessment; 1999.
39. Deoni SC, Williams SC, Jezzard P, Suckling J, Murphy DG, Jones DK. Standardized structural magnetic resonance imaging in multicentre studies using quantitative T1 and T2 imaging at 1.5 T. *Neuroimage*. 2008;40(2):662-671.
40. Smith SM. Fast robust automated brain extraction. *Hum Brain Mapp*. 2002;17(3):143-155.
41. Bullmore ET, Suckling J, Overmeyer S, Rabe-Hesketh S, Taylor E, Brammer MJ. Global, voxel, and cluster tests, by theory and permutation, for a difference between two groups of structural MR images of the brain. *IEEE Trans Med Imaging*. 1999;18(1):32-42.
42. McIntosh AR, Bookstein FL, Haxby JV, Grady CL. Spatial pattern analysis of functional brain images using partial least squares. *Neuroimage*. 1996;3(3, pt 1):143-157.
43. McIntosh AR, Lobaugh NJ. Partial least squares analysis of neuroimaging data: applications and advances. *Neuroimage*. 2004;23(suppl 1):S250-S263.
44. Lobaugh NJ, West R, McIntosh AR. Spatiotemporal analysis of experimental differences in event-related potential data with partial least squares. *Psychophysiology*. 2001;38(3):517-530.
45. Thiebaut de Schotten M, Ffytche DH, Bizzi A, Dell'Acqua F, Allin M, Walshe M, Murray R, Williams SC, Murphy DG, Catani M. Atlas location, asymmetry and inter-subject variability of white matter tracts in the human brain with MR diffusion tractography. *Neuroimage*. 2011;54(1):49-59.
46. Lenroot RK, Gogtay N, Greenstein DK, Wells EM, Wallace GL, Clasen LS, Blumenthal JD, Lerch J, Zijdenbos AP, Evans AC, Thompson PM, Giedd JN. Sexual dimorphism of brain developmental trajectories during childhood and adolescence. *Neuroimage*. 2007;36(4):1065-1073.
47. Lainhart JE, Bigler ED, Bocian M, Coon H, Dinh E, Dawson G, Deutsch CK, Dunn M, Estes A, Tager-Flusberg H, Folstein S, Hepburn S, Hyman S, McMahon W, Minshew N, Munson J, Osann K, Ozonoff S, Rodier P, Rogers S, Sigman M, Spence MA, Stodgell CJ, Volkmar F. Head circumference and height in autism: a study by the Collaborative Program of Excellence in Autism. *Am J Med Genet A*. 2006;140(21):2257-2274.
48. Lainhart JE, Piven J, Wzorek M, Landa R, Santangelo SL, Coon H, Folstein SE. Macrocephaly in children and adults with autism. *J Am Acad Child Adolesc Psychiatry*. 1997;36(2):282-290.
49. Redcay E, Courchesne E. When is the brain enlarged in autism? a meta-analysis of all brain size reports. *Biol Psychiatry*. 2005;58(1):1-9.
50. Courchesne E, Carper R, Akshoomoff N. Evidence of brain overgrowth in the first year of life in autism. *JAMA*. 2003;290(3):337-344.
51. Herbert MR, Ziegler DA, Deutsch CK, O'Brien LM, Lange N, Bakardjiev A, Hodgson J, Adrien KT, Steele S, Makris N, Kennedy D, Harris GJ, Caviness VS Jr. Dissociations of cerebral cortex, subcortical and cerebral white matter volumes in autistic boys. *Brain*. 2003;126(pt 5):1182-1192.
52. Giedd JN, Blumenthal J, Jeffries NO, Castellanos FX, Liu H, Zijdenbos A, Paus T, Evans AC, Rapoport JL. Brain development during childhood and adolescence: a longitudinal MRI study. *Nat Neurosci*. 1999;2(10):861-863.
53. Kwon H, Ow AW, Pedatella KE, Lotspeich LJ, Reiss AL. Voxel-based morphometry elucidates structural neuroanatomy of high-functioning autism and Asperger syndrome. *Dev Med Child Neurol*. 2004;46(11):760-764.
54. Frith U, Frith CD. Development and neurophysiology of mentalizing. *Philos Trans R Soc Lond B Biol Sci*. 2003;358(1431):459-473.
55. Patterson K, Nestor PJ, Rogers TT. Where do you know what you know? the representation of semantic knowledge in the human brain. *Nat Rev Neurosci*. 2007;8(12):976-987.
56. Wang AT, Lee SS, Sigman M, Dapretto M. Neural basis of irony comprehension in children with autism: the role of prosody and context. *Brain*. 2006;129(pt 4):932-943.
57. Silani G, Bird G, Brindley R, Singer T, Frith C, Frith U. Levels of emotional awareness and autism: an fMRI study. *Soc Neurosci*. 2008;3(2):97-112.
58. Castelli F, Frith C, Happé F, Frith U. Autism, Asperger syndrome and brain mechanisms for the attribution of mental states to animated shapes. *Brain*. 2002;125(pt 8):1839-1849.
59. Gaffrey MS, Kleinhans NM, Haist F, Akshoomoff N, Campbell A, Courchesne E, Müller RA. Atypical participation of visual cortex during word processing in autism: an fMRI study of semantic decision [published correction appears in *Neuropsychologia*. 2007;45(11):2644]. *Neuropsychologia*. 2007;45(8):1672-1684.
60. Gilbert SJ, Bird G, Brindley R, Frith CD, Burgess PW. Atypical recruitment of medial prefrontal cortex in autism spectrum disorders: an fMRI study of two executive function tasks. *Neuropsychologia*. 2008;46(9):2281-2291.
61. Murphy DG, Critchley HD, Schmitz N, McAlonan G, Van Amelsvoort T, Robertson D, Daly E, Rowe A, Russell A, Simmons A, Murphy KC, Howlin P. Asperger syndrome: a proton magnetic resonance spectroscopy study of brain. *Arch Gen Psychiatry*. 2002;59(10):885-891.
62. Baron-Cohen S, Ring HA, Wheelwright S, Bullmore ET, Brammer MJ, Simmons A, Williams SC. Social intelligence in the normal and autistic brain: an fMRI study. *Eur J Neurosci*. 1999;11(6):1891-1898.
63. Critchley HD, Daly EM, Bullmore ET, Williams SC, Van Amelsvoort T, Robertson DM, Rowe A, Phillips M, McAlonan G, Howlin P, Murphy DG. The functional neuroanatomy of social behaviour: changes in cerebral blood flow when people with autistic disorder process facial expressions. *Brain*. 2000;123(pt 11):2203-2212.
64. Schmitz N, Daly E, Murphy D. Frontal anatomy and reaction time in Autism. *Neurosci Lett*. 2007;412(1):12-17.
65. Bauman ML, Kemper TL. Neuroanatomic observations of the brain in autism: a review and future directions. *Int J Dev Neurosci*. 2005;23(2-3):183-187.

66. Carper RA, Courchesne E. Localized enlargement of the frontal cortex in early autism. *Biol Psychiatry*. 2005;57(2):126-133.
67. Solomon M, Ozonoff SJ, Ursu S, Ravizza S, Cummings N, Ly S, Carter CS. The neural substrates of cognitive control deficits in autism spectrum disorders. *Neuropsychologia*. 2009;47(12):2515-2526.
68. Takarae Y, Minshew NJ, Luna B, Sweeney JA. Atypical involvement of frontostriatal systems during sensorimotor control in autism. *Psychiatry Res*. 2007;156(2):117-127.
69. Agam Y, Joseph RM, Barton JJ, Manoach DS. Reduced cognitive control of response inhibition by the anterior cingulate cortex in autism spectrum disorders. *Neuroimage*. 2010;52(1):336-347.
70. Mostofsky SH, Powell SK, Simmonds DJ, Goldberg MC, Caffo B, Pekar JJ. Decreased connectivity and cerebellar activity in autism during motor task performance. *Brain*. 2009;132(pt 9):2413-2425.
71. Müller RA, Pierce K, Ambrose JB, Allen G, Courchesne E. Atypical patterns of cerebral motor activation in autism: a functional magnetic resonance study. *Biol Psychiatry*. 2001;49(8):665-676.
72. Badre D, Hoffman J, Cooney JW, D'Esposito M. Hierarchical cognitive control deficits following damage to the human frontal lobe. *Nat Neurosci*. 2009;12(4):515-522.
73. Koehlin E, Ody C, Kouneiher F. The architecture of cognitive control in the human prefrontal cortex. *Science*. 2003;302(5648):1181-1185.
74. Zilbovicius M, Garreau B, Samson Y, Remy P, Barthélémy C, Syrota A, Lelord G. Delayed maturation of the frontal cortex in childhood autism. *Am J Psychiatry*. 1995;152(2):248-252.
75. Aron AR, Behrens TE, Smith S, Frank MJ, Poldrack RA. Triangulating a cognitive control network using diffusion-weighted magnetic resonance imaging (MRI) and functional MRI. *J Neurosci*. 2007;27(14):3743-3752.
76. Langen M, Schnack HG, Nederveen H, Bos D, Lahuis BE, de Jonge MV, van Engeland H, Durrstorf S. Changes in the developmental trajectories of striatum in autism. *Biol Psychiatry*. 2009;66(4):327-333.
77. Lombardo MV, Chakrabarti B, Bullmore ET, Wheelwright SJ, Sadek SA, Suckling J, Baron-Cohen S; MRC AIMS Consortium. Shared neural circuits for mentalizing about the self and others. *J Cogn Neurosci*. 2010;22(7):1623-1635.
78. Saxe R, Powell LJ. It's the thought that counts: specific brain regions for one component of theory of mind. *Psychol Sci*. 2006;17(8):692-699.
79. Buckner RL, Carroll DC. Self-projection and the brain. *Trends Cogn Sci*. 2007;11(2):49-57.
80. Samson F, Mottron L, Soulières I, Zeffiro TA. Enhanced visual functioning in autism: an ALE meta-analysis. *Hum Brain Mapp*. 2011;(Apr):4. doi:10.1002/hbm.21307.
81. Hyde KL, Samson F, Evans AC, Mottron L. Neuroanatomical differences in brain areas implicated in perceptual and other core features of autism revealed by cortical thickness analysis and voxel-based morphometry. *Hum Brain Mapp*. 2010;31(4):556-566.
82. Brieber S, Herpertz-Dahlmann B, Fink GR, Kamp-Becker I, Remschmidt H, Konrad K. Coherent motion processing in autism spectrum disorder (ASD): an fMRI study. *Neuropsychologia*. 2010;48(6):1644-1651.
83. Damarla SR, Keller TA, Kana RK, Cherkassky VL, Williams DL, Minshew NJ, Just MA. Cortical underconnectivity coupled with preserved visuospatial cognition in autism: evidence from an fMRI study of an embedded figures task. *Autism Res*. 2010;3(5):273-279.
84. Malisza KL, Clancy C, Shiloff D, Foreman D, Holden J, Jones C, Paulson K, Summers R, Yu CT, Chudley AE. Functional evaluation of hidden figures object analysis in children with autistic disorder. *J Autism Dev Disord*. 2011;41(1):13-22.
85. Manjaly ZM, Bruning N, Neufang S, Stephan KE, Brieber S, Marshall JC, Kamp-Becker I, Remschmidt H, Herpertz-Dahlmann B, Konrad K, Fink GR. Neurophysiological correlates of relatively enhanced local visual search in autistic adolescents. *Neuroimage*. 2007;35(1):283-291.
86. Ring HA, Baron-Cohen S, Wheelwright S, Williams SC, Brammer M, Andrew C, Bullmore ET. Cerebral correlates of preserved cognitive skills in autism: a functional MRI study of embedded figures task performance. *Brain*. 1999;122(pt 7):1305-1315.
87. Sahyoun CP, Belliveau JW, Soulières I, Schwartz S, Mody M. Neuroimaging of the functional and structural networks underlying visuospatial vs linguistic reasoning in high-functioning autism. *Neuropsychologia*. 2010;48(1):86-95.
88. Soulières I, Dawson M, Samson F, Barbeau EB, Sahyoun CP, Strangman GE, Zeffiro TA, Mottron L. Enhanced visual processing contributes to matrix reasoning in autism. *Hum Brain Mapp*. 2009;30(12):4082-4107.
89. Kana RK, Keller TA, Cherkassky VL, Minshew NJ, Just MA. Sentence comprehension in autism: thinking in pictures with decreased functional connectivity. *Brain*. 2006;129(pt 9):2484-2493.
90. Hadjikhani N, Joseph RM, Snyder J, Tager-Flusberg H. Anatomical differences in the mirror neuron system and social cognition network in autism. *Cereb Cortex*. 2006;16(9):1276-1282.
91. Pelphrey KA, Mack PB, Song A, Güzeldere G, McCarthy G. Faces evoke spatially differentiated patterns of BOLD activation and deactivation. *Neuroreport*. 2003;14(7):955-959.
92. Lahaie A, Mottron L, Arguin M, Berthiaume C, Jemel B, Saumier D. Face perception in high-functioning autistic adults: evidence for superior processing of face parts, not for a configural face-processing deficit. *Neuropsychology*. 2006;20(1):30-41.
93. Geschwind DH, Levitt P. Autism spectrum disorders: developmental disconnection syndromes. *Curr Opin Neurobiol*. 2007;17(1):103-111.
94. Just MA, Cherkassky VL, Keller TA, Kana RK, Minshew NJ. Functional and anatomical cortical underconnectivity in autism: evidence from an fMRI study of an executive function task and corpus callosum morphometry. *Cereb Cortex*. 2007;17(4):951-961.
95. Welchew DE, Ashwin C, Berkouk K, Salvador R, Suckling J, Baron-Cohen S, Bullmore E. Functional disconnectivity of the medial temporal lobe in Asperger's syndrome. *Biol Psychiatry*. 2005;57(9):991-998.
96. Belmonte MK, Allen G, Bechel-Mitchener A, Boulanger LM, Carper RA, Webb SJ. Autism and abnormal development of brain connectivity. *J Neurosci*. 2004;24(42):9228-9231.
97. Mostofsky SH, Powell SK, Simmonds DJ, Goldberg MC, Caffo B, Pekar JJ. Decreased connectivity and cerebellar activity in autism during motor task performance. *Brain*. 2009;132(pt 9):2413-2425.
98. Palmen SJ, Hulshoff Pol HE, Kemner C, Schnack HG, Sitskoorn MM, Appels MC, Kahn RS, Van Engeland H. Brain anatomy in non-affected parents of autistic probands: a MRI study. *Psychol Med*. 2005;35(10):1411-1420.
99. Nicolson R, DeVito TJ, Vidal CN, Sui Y, Hayashi KM, Drost DJ, Williamson PC, Rajakumar N, Toga AW, Thompson PM. Detection and mapping of hippocampal abnormalities in autism. *Psychiatry Res*. 2006;148(1):11-21.
100. Schumann CM, Hamstra J, Goodlin-Jones BL, Lotspeich LJ, Kwon H, Buonocore MH, Lammers CR, Reiss AL, Amaral DG. The amygdala is enlarged in children but not adolescents with autism; the hippocampus is enlarged at all ages. *J Neurosci*. 2004;24(28):6392-6401.
101. Blakemore SJ. The social brain in adolescence. *Nat Rev Neurosci*. 2008;9(4):267-277.
102. Lombardo MV, Barnes JL, Wheelwright SJ, Baron-Cohen S. Self-referential cognition and empathy in autism. *PLoS One*. 2007;2(9):e883. doi:10.1371/journal.pone.0000883.
103. Castelli F, Frith C, Happé F, Frith U. Autism, Asperger syndrome and brain mechanisms for the attribution of mental states to animated shapes. *Brain*. 2002;125(pt 8):1839-1849.
104. Wang AT, Lee SS, Sigman M, Dapretto M. Reading affect in the face and voice: neural correlates of interpreting communicative intent in children and adolescents with autism spectrum disorders. *Arch Gen Psychiatry*. 2007;64(6):698-708.
105. Lombardo MV, Chakrabarti B, Bullmore ET, Sadek SA, Pasco G, Wheelwright SJ, Suckling J, Baron-Cohen S; MRC AIMS Consortium. Atypical neural self-representation in autism. *Brain*. 2010;133(pt 2):611-624.
106. Kennedy DP, Courchesne E. Functional abnormalities of the default network during self- and other-reflection in autism. *Soc Cogn Affect Neurosci*. 2008;3(2):177-190.
107. Cheung C, Chua SE, Cheung V, Khong PL, Tai KS, Wong TK, Ho TP, McAlonan GM. White matter fractional anisotropy differences and correlates of diagnostic symptoms in autism. *J Child Psychol Psychiatry*. 2009;50(9):1102-1112.
108. Alexander AL, Lee JE, Lazar M, Boudos R, DuBray MB, Oakes TR, Miller JN, Lu J, Jeong EK, McMahon WM, Bigler ED, Lainhart JE. Diffusion tensor imaging of the corpus callosum in autism. *Neuroimage*. 2007;34(1):61-73.
109. Barnea-Goraly N, Kwon H, Menon V, Eliez S, Lotspeich L, Reiss AL. White matter structure in autism: preliminary evidence from diffusion tensor imaging. *Biol Psychiatry*. 2004;55(3):323-326.
110. Catani M, Jones DK, Daly E, Embiricos N, Deeley Q, Pugliese L, Curran S, Robertson D, Murphy DG. Altered cerebellar feedback projections in Asperger syndrome. *Neuroimage*. 2008;41(4):1184-1191.
111. Pugliese L, Catani M, Ameis S, Dell'Acqua F, Thiebaut de Schotten M, Murphy C, Robertson D, Deeley Q, Daly E, Murphy DG. The anatomy of extended limbic pathways in Asperger syndrome: a preliminary diffusion tensor imaging tractography study. *Neuroimage*. 2009;47(2):427-434.
112. Bloemen OJ, Deeley Q, Sundram F, Daly EM, Barker GJ, Jones DK, van Amelsvoort TA, Schmitz N, Robertson D, Murphy KC, Murphy DG. White matter integrity in Asperger syndrome: a preliminary diffusion tensor magnetic resonance imaging study in adults. *Autism Res*. 2010;3(5):203-213.
113. Herbert MR, Ziegler DA, Makris N, Filipek PA, Kemper TL, Normandin JJ, Sand-

- ers DN, Kennedy DN, Caviness VS Jr. Localization of white matter volume increase in autism and developmental language disorder. *Ann Neurol*. 2004; 55(4):530-540.
114. Ben Bashat D, Kronfeld-Duenias V, Zachor DA, Ekstein PM, Hendler T, Tarrasch R, Even A, Levy Y, Ben Sira L. Accelerated maturation of white matter in young children with autism: a high b value DWI study. *Neuroimage*. 2007;37(1): 40-47.
 115. Ke X, Tang T, Hong S, Hang Y, Zou B, Li H, Zhou Z, Ruan Z, Lu Z, Tao G, Liu Y. White matter impairments in autism, evidence from voxel-based morphometry and diffusion tensor imaging. *Brain Res*. 2009;1265:171-177.
 116. Wernicke C. *Der Aphasische Symptomkomplex*. Breslau, Poland: Cohn & Weigert; 1874.
 117. Catani M, ffytche DH. The rises and falls of disconnection syndromes. *Brain*. 2005;128(pt 10):2224-2239.
 118. Frith C. Is autism a disconnection disorder? *Lancet Neurol*. 2004;3(10):577. doi:10.1016/S1474-4422(04)00875-0.
 119. Courchesne E, Pierce K. Why the frontal cortex in autism might be talking only to itself: local over-connectivity but long-distance disconnection. *Curr Opin Neurobiol*. 2005;15(2):225-230.
 120. Keller TA, Kana RK, Just MA. A developmental study of the structural integrity of white matter in autism. *Neuroreport*. 2007;18(1):23-27.
 121. Howlin P. Outcome in high-functioning adults with autism with and without early language delays: implications for the differentiation between autism and Asperger syndrome. *J Autism Dev Disord*. 2003;33(1):3-13.
 122. Deoni SC. High-resolution T1 mapping of the brain at 3T with driven equilibrium single pulse observation of T1 with high-speed incorporation of RF field inhomogeneities (DESPOT1-HIFI). *J Magn Reson Imaging*. 2007;26(4):1106-1111.
 123. Deoni SC. Transverse relaxation time (T2) mapping in the brain with off-resonance correction using phase-cycled steady-state free precession imaging. *J Magn Reson Imaging*. 2009;30(2):411-417.
 124. Breger RK, Wehrli FW, Charles HC, MacFall JR, Haughton VM. Reproducibility of relaxation and spin-density parameters in phantoms and the human brain measured by MR imaging at 1.5 T. *Magn Reson Med*. 1986;3(5):649-662.
 125. Suckling J, Barnes A, Job D, Brennan D, Lymer K, Dazzan P, Marques TR, MacKay C, McKie S, Williams SR, Williams SC, Lawrie S, Deakin B. Power calculations for multicenter imaging studies controlled by the false discovery rate. *Hum Brain Mapp*. 2010;31(8):1183-1195.
 126. Suckling J, Barnes A, Job D, Brennan D, Lymer K, Dazzan P, Marques TR, MacKay C, McKie S, Williams SC, Deakin B, Lawrie S. The Neuro/PsyGRID calibration experiment: identifying sources of variance and bias in multicentre MRI studies [published online March 21, 2011]. *Hum Brain Mapp*. doi:10.1002/hbm.21210.
 127. Rakic P. Defects of neuronal migration and the pathogenesis of cortical malformations. *Prog Brain Res*. 1988;73:15-37.

Correction

Error in Text. In the Art and Images in Psychiatry article titled "Chauvet Cave: *The Panel of Horses*," published in the September 2011 issue of the *Archives* (2011; 68[9]:869-870), the text was incorrect in stating that only a single laboratory performed the radiocarbon dating of samples from the Chauvet cave. There are 80 radiocarbon datings. Several laboratories have been involved in the dating of the Chauvet cave, and an interlaboratory comparison in 2007 carried out on charcoal from the cave involved 4 labs whose results (29 dates) are consistent with Aurignacian dating.¹

1. Cuzange MT, Delque-Kolic E, Goslar T, Grootes PM, Higham T, Kaltnecker E, Nadeau MJ, Oberlin C, Paterne M, van der Plicht J, Ramsey CB, Valladas H, Clottes J, Geneste JM. Radiocarbon intercomparison program for Chauvet Cave. *Radiocarbon*. 2007;49(2): 339-347.