

Progressive Cortical Change During Adolescence in Childhood-Onset Schizophrenia

A Longitudinal Magnetic Resonance Imaging Study

Judith L. Rapoport, MD; Jay N. Giedd, MD; Jonathan Blumenthal, MA; Susan Hamburger, MA, MS; Neal Jeffries, PhD; Tom Fernandez; Rob Nicolson, MD; Jeff Bedwell; Marge Lenane, MSW; Alex Zijdenbos, PhD; Tomás Paus, MD, PhD; Alan Evans, PhD

Background: Adolescence provides a window to examine regional and disease-specific late abnormal brain development in schizophrenia. Because previous data showed progressive brain ventricular enlargement for a group of adolescents with childhood-onset schizophrenia at 2-year follow-up, with no significant changes for healthy controls, we hypothesized that there would be a progressive decrease in volume in other brain tissue in these patients during adolescence.

Methods: To examine cortical change, we used anatomical brain magnetic resonance imaging scans for 15 patients with childhood-onset schizophrenia (defined as onset of psychosis by age 12 years) and 34 temporally yoked, healthy adolescents at a mean (SD) age of 13.17 (2.73) years at initial baseline scan and 17.46 (2.96) years at follow-up scan. Cortical gray and white matter volumes were obtained with an automated analysis system that classifies brain tissue into gray matter, white matter, and cerebrospinal fluid and separates the cortex into anatomically defined lobar regions.

Results: A significant decrease in cortical gray matter

volume was seen for healthy controls in the frontal (2.6%) and parietal (4.1%) regions. For the childhood-onset schizophrenia group, there was a decrease in volume in these regions (10.9% and 8.5%, respectively) as well as a 7% decrease in volume in the temporal gray matter. Thus, the childhood-onset schizophrenia group showed a distinctive disease-specific pattern (multivariate analysis of variance for change \times region \times diagnosis: $F, 3.68$; $P = .004$), with the frontal and temporal regions showing the greatest between-group differences. Changes in white matter volume did not differ significantly between the 2 groups.

Conclusions: Patients with very early-onset schizophrenia had both a 4-fold greater decrease in cortical gray matter volume during adolescence and a disease-specific pattern of change. Etiologic models for these patients' illness, which seem clinically and neurobiologically continuous with later-onset schizophrenia, must take into account both early and late disruptions of brain development.

Arch Gen Psychiatry. 1999;56:649-654

From the Child Psychiatry Branch, National Institute of Mental Health (Drs Rapoport, Giedd, and Nicolson, Messrs Blumenthal, Fernandez, and Bedwell, and Mss Hamburger and Lenane), and Biometry Branch, National Institute of Neurological Disorders and Stroke (Dr Jeffries), Bethesda, Md; and the Montreal Neurological Institute, McGill University, Montreal, Quebec (Drs Zijdenbos, Paus, and Evans).

THE neurodevelopmental hypothesis of schizophrenia suggests that a brain "lesion" is present early in life but does not manifest itself until late adolescence or early adulthood.¹⁻³ Compelling clinical support for this model comes from numerous demonstrations of subtle but consistent abnormalities in cognitive and behavioral development noted years before the onset of psychosis.⁴⁻⁶ In addition, the postmortem neuropathological findings in schizophrenia can be viewed as consistent with an early nonprogressive event.²

The lack of progressive change in longitudinal brain imaging studies of patients with adult-onset schizophrenia is also cited as support for the "fixed-lesion" neurodevelopmental hypothesis. Of the 5 prospective longitudinal anatomi-

cal brain magnetic resonance imaging (MRI) studies of adult-onset schizophrenia that compared patients with temporally yoked controls, only 2 found greater progression for their schizophrenic group as a whole.⁷⁻⁹ Others found either no progression¹⁰ or evidence of progression for only a subgroup.^{11,12}

Childhood-onset schizophrenia (COS) (defined as onset of psychosis by age 12 years) is a rare, usually severe manifestation of the disorder that has been shown to be continuous with the adult-onset disorder with respect to clinical and neurobiological characteristics, including brain MRI pattern.¹³⁻¹⁶ There is also continuity in the pattern of associated risk factors, such as early developmental language and speech abnormalities years before the onset of psychosis,¹⁷ cytogenetic abnormalities,¹⁸ and various psychopatho-

SUBJECTS AND METHODS

Subjects included 15 children and adolescents who had been recruited to the National Institute of Mental Health study of COS. Recruiting and diagnostic methods have been described elsewhere.²⁶⁻²⁸ Briefly, children were sought via national recruiting who met unmodified *DSM-III-R* criteria for schizophrenia, with onset of psychotic symptoms by age 12 years. From more than 1000 referrals, approximately 250 patients and their families were screened in person, using both clinical examination and structured interviews over a daylong evaluation. The clinical diagnosis of schizophrenia for this group showed good reliability.²⁷ Fifty-four patients received the diagnosis of COS; 47 had participated in the study at the time of this report. As patients were also participating in a clozapine treatment trial,²⁸ they were refractory to treatment with typical neuroleptics.

All subjects returned at regular intervals, at which time clinical reevaluation and MRI follow-up scans were carried out.

Of the 47 subjects studied to date, valid baseline scans could not be obtained for 2. Of the remaining 45, 28 had returned for at least 1 follow-up scan; 18 were rescanned after 3 to 5 years while they were still in adolescence, and 3 of these 18 had 1 scan each that could not be processed by the automated system. Most of the remaining subjects who had not been rescanned were not yet due for their 4-year (approximate) follow-up scan. Thus, only 3 eligible cases were truly unavailable to our team for MRI reevaluation. The 15 cases in the present study did not differ significantly with respect to any clinical or demographic measure from the remainder of the sample.

A temporally yoked, age- and sex-matched healthy control group of 46 adolescents was selected by a systematic evaluation process²⁹; 34 with processable scans served as the contrast group for this report. Controls were free of lifetime medical or psychiatric disorders as determined by

clinical examination and standardized interview. Psychiatric illness in a first-degree relative was also exclusionary. The combined groups had a mean (SD) age of 13.17 (2.73) years at the time of initial scan, and returned after 4.28 (0.63) years for follow-up scans. Characteristics of patients and control subjects at baseline and follow-up scan are shown in **Table 1**.

As shown in Table 1, patients were severely ill, with a mean \pm SD age of onset of psychotic symptoms at 10.3 ± 2.0 years. The patient group received a considerable amount of medication prior to initial scan, and at follow-up, all but 2 were taking medication. The scan intervals did not differ for the 2 groups. Moreover, while at first scan, the medications were primarily typical neuroleptics, at follow-up, 11 of the 15 patients were receiving atypical neuroleptics, with 2 receiving both a typical and an atypical agent. All met the criteria for schizophrenia (4 were in remission while taking clozapine) at the follow-up scan. None of these young subjects had a history of substance abuse. Thus, while patients were matched for age, sex, and time of scan, they differed significantly with respect to ethnicity, socioeconomic status, IQ score, exposure to medication, and weight at follow-up scan.

The study was approved by the National Institute of Mental Health Institutional Review Board. Parents gave written consent, and minor volunteers and patients gave verbal assent for this study.

MRI ACQUISITION AND ANALYSIS

All images were acquired on the same 1.5-T Signa scanner (General Electric, Milwaukee, Wis) located at the National Institutes of Health Clinical Center, Bethesda, Md. A 3-dimensional spoiled gradient-recalled echo in the steady-state sequence designed to optimize discrimination between gray matter, white matter, and cerebrospinal fluid was used to acquire 124 contiguous 1.5-mm-thick slices

logic conditions, including schizophrenia and/or "spectrum" disorders, smooth-pursuit eye movement abnormalities, and/or cognitive abnormalities in the close relatives of the COS patients.^{14,19}

An ongoing National Institute of Mental Health study of COS included brain MRI rescans at regular intervals as part of the follow-up examination. A previous report documented an increase in brain ventricular volume between mean ages 14 and 16 years for this group that was more striking and consistent than that reported for adult-onset cases.²⁰ The study also found a trend for differential decrease in total brain volume for adolescents with schizophrenia, but regional cortical volumes were not examined.

The present report is of regional cortical gray and white matter volumes for a group of patients with COS scanned at initial contact (mean age, 13.9 years) and at 3- to 5-year follow-up (mean age, 18.1 years). To carry out this examination, an automated segmentation system developed at the Montreal Neurological Institute, Montreal, Quebec, was used.²¹⁻²⁵ Because of our earlier brain ventricular data and the smaller total brain and temporal lobe volumes with greater loss of gray matter characteristic of adults with schizophrenia, we hypoth-

esized that there would be commensurate differential changes in other brain tissue, including cortical gray matter, with patients with COS showing a greater and more regionally selective decline than seen for healthy controls.

RESULTS

Both absolute baseline and follow-up scan values and percentage change for total and regional gray and white volumes are shown in **Table 2** for COS patients and healthy controls.

WITHIN-GROUP CHANGE

For the 34 healthy controls, there was a significant (1.3%) decrease in total cerebral volume that was accounted for by a decrease in gray matter volume (1.98%) ($t = 2.12$, $P = .04$). As seen in Table 2, the regional gray matter changes also showed a statistically significant selective regional pattern (MANOVA Wilks λ : $F, 19.1$; $P < .001$), with the greatest change in the frontal and parietal gray matter and the smallest change in the occipital and temporal gray matter regions.

in the axial plane and 124 contiguous 2.0-mm-thick slices in the coronal plane. Imaging parameters were as follows: time to echo, 5 milliseconds; time to repeat, 24 milliseconds; flip angle, 45°; acquisition matrix, 256 × 192; number of excitations, 1; and field of view, 24 cm.

Three vitamin E capsules, 1 placed in the meatus of each ear and 1 taped to the left lateral inferior orbital ridge, were used to standardize head placement across individuals. The vitamin E capsules showed up brightly on the scans, and an axial-localizing sequence was acquired to assess whether the 3 capsules were visible in the same axial plane. This served to ensure brain coverage and minimize partial volume losses. If this criterion was not met the subject's head was repositioned. The subject's nose was aligned at the 12-o'clock position to assist standardization within the axial plane. Foam padding was placed around the head to minimize scanner noise and help steady the head position. Subjects were scanned in the evening to promote natural sleep. Sedation with chloral hydrate (0.5-2.0 g) or lorazepam (0.5-2.0 mg) was used for 20% of the COS subjects. No controls were sedated.

Gray matter, white matter, and cerebrospinal fluid segmentation was performed via a 3-part automated image analysis process.^{21-25,31} First, the images are corrected for regional intensity nonuniformities resulting from magnetic field inhomogeneities inherent in the image acquisition process. Next, the images are transformed to a standardized stereotactic (Talairach) space using a 9-parameter linear process.²¹ The images are then registered in a non-linear way to a template brain for which anatomical regions have been manually defined. The nonlinear registration of each subject's MRI with the anatomically defined template brain allows each voxel to be assigned a tissue type and an anatomical structure of which it is a part.^{22,23,32}

The lobar boundaries were defined as in a standard atlas.³³ The central sulcus was used to separate the frontal lobe from the parietal lobe, which was bounded inferiorly

by the lateral fissure and a line extending the lateral fissure to the occipital lobe. The temporal lobe was bounded superiorly by the lateral fissure and an extension of the lateral fissure to the occipital lobe. The occipital lobe was bounded by a curved line extending from the parieto-occipital fissure to the temporo-occipital incisure.

This information was merged with information from an artificial neural network classification technique that assigns a gray matter, white matter, or cerebrospinal fluid designation based on voxel intensity.

STATISTICAL ANALYSIS

Demographic characteristics of patients and controls were compared using *t* tests or χ^2 tests where appropriate.

Subtracting the baseline MRI value from the follow-up value and then dividing by the baseline measurement value created change scores for total and regional gray and white matter. These percentage change scores were then used in all statistical analyses. Group differences were examined with 1-way analysis of variance (ANOVA), repeated-measures ANOVA, or multivariate ANOVA (MANOVA) using the Wilks λ result. Post hoc testing determined significant differences.

For the control group, regional regression slopes for individual change over time were examined, using absolute values of the region, in relation to sex, socioeconomic status, and the Wechsler Intelligence Scale for Children Vocabulary and Block Design scores. For the patients with schizophrenia, these slopes were examined in relation to sex, ethnicity, age of onset, weight gain while taking neuroleptics, and neuroleptic exposure (typical and atypical separately). The results were expressed as standard regression β coefficients.

The SPSS 9.0 statistical package for Windows (SPSS Inc, Chicago, Ill) was used for all analyses, with a 2-tailed α level of .05.

For the 15 COS patients, there was a significant (5.5%) decrease in total cerebral volume that was accounted for by a decrease in gray matter (8.0%). The regional gray matter change also differed selectively for COS patients (MANOVA Wilks λ : *F*, 11.2; *P* = .001), with 7% to 10% decreases for frontal, parietal, and temporal gray matter volume and no significant change in the occipital region.

BETWEEN-GROUP COMPARISONS

As shown in Table 2, the percentage change differed strikingly between the groups for gray matter, with the COS group showing an exaggerated and unique pattern (MANOVA Wilks λ : *F*, 3.72; *P* = .002 overall; *F*, 3.68; *P* = .004 for regional × diagnosis interaction). The diagnostic differences were most striking for temporal (*P* < .001) and frontal (*P* = .001) gray matter volumes. There was no significant difference between the groups with respect to white matter change.

The disease-specific change in brain development is seen most clearly in the **Figure**, showing the difference in the percentage and pattern of decline between the COS and healthy control groups.

CLINICAL AND DEMOGRAPHIC RELATIONSHIPS

Boys had more robust decreases in gray matter than did girls (*P* = .05), and this difference was more pronounced for the COS group (ANOVA: *F*, 4.09; *P* = .05 for diagnosis × sex). For the healthy controls, there was no significant relationship between full-scale IQ score, socioeconomic status, or ethnicity and slope of change for any region. For the COS group, those with higher baseline Brief Psychiatric Rating Scale scores had a greater rate of volume decrease for temporal, parietal, and frontal gray matter (*t*, 2.6-3.5; *P* < .01). There was no significant relationship between weight gain or drug exposure and slope for any region. Further clinically relevant analyses were precluded by missing data and small sample size.

COMMENT

Within a 4-year mid-adolescent period, a significant decline in cortical gray matter volume was seen for the healthy controls. The frontal gray and white matter and parietal gray matter volumes decreased, while white matter volumes in the parietal temporal and occipital regions increased. These data support previous cross-

Table 1. Demographic Data for Patients With Childhood-Onset Schizophrenia and Healthy Controls*

	Patients (n = 15)		Controls (n = 34)		Diagnosis at Baseline, <i>t</i> Test	<i>P</i>
	Baseline	Follow-up	Baseline	Follow-up		
Age, y† (range)	13.9 ± 2.3 (9.2-17.9)	18.1 ± 2.7 (13.3-23.3)	12.8 ± 2.9 (8.2-17.8)	17.2 ± 3.1 (11.8-21.8)	1.66	.21
Follow-up interval, y† (range)	4.2 ± 0.7 (3.1-5.5)		4.3 ± 0.6 (3.1-5.4)		0.79	.38
Male/female, No.	6/9		17/17		0.42‡	.52
White/black/other, No.	5/7/3		33/0/1		25.03‡	<.001
SES†§	76.0 ± 34.5		32.2 ± 14.5		39.82	<.001
Height, cm†	160.8 ± 8.6	167.9 ± 8.1	156.9 ± 16.8	169.2 ± 11.1	0.68	.42
Weight, kg†	58.0 ± 14.3	81.3 ± 21.5	46.8 ± 14.5	62.2 ± 11.7	6.27	.02
Right-handed/left-handed/mixed, No.	11/3/1		30/4/0		3.04‡	.22
WISC Block Design score†	6.2 ± 2.8		14.4 ± 2.8		78.04	<.001
WISC Vocabulary score†	4.5 ± 3.4		14.0 ± 2.0		128.17	<.001
Full-scale IQ score†	70.4 ± 12.9		124.5 ± 12.9		135.88	<.001
Familial schizophrenia/spectrum disorders, No. (%)	7 (47)					
Age at onset of psychosis, y†	10.3 ± 2.0					
Motor or speech abnormalities, No. (%)	10 (67)					
Atypical neuroleptics, No.	4		11¶			
BPRS score†	53 ± 10	38 ± 9#				
SANS score†	68 ± 19	53 ± 29#				
SAPS score†	56 ± 17	26 ± 18#				

*SES indicates socioeconomic status; WISC, Wechsler Intelligence Scale for Children; BPRS, Brief Psychiatric Rating Scale; SANS, Scale for Assessment of Negative Symptoms; and SAPS, Scale for Assessment of Positive Symptoms.

†Values are mean ± SD.

‡ χ^2 analysis.

§Rated using the Hollingshead 2-factor index.³⁰

||The estimated full-scale IQ score for 26 subjects was used; IQ scores were not available for 5 patients.

¶Two additional patients were given both typical and atypical neuroleptics.

#Follow-up BPRS, SANS, and SAPS scores were missing for 2 patients.

Table 2. Anatomical Brain Magnetic Resonance Imaging Measures and Percentage Changes at Baseline and 3- to 5-Year Follow-up During Adolescence for Patients With Childhood-Onset Schizophrenia and Healthy Controls*

Region	Patients (n = 15)†			Controls (n = 34)†			Diagnosis	
	Baseline	Follow-up	Percentage Change, %‡	Baseline	Follow-up	Percentage Change, %‡	<i>F</i> _{4,44}	<i>P</i>
Gray and white matter	1050.91 ± 140.17	990.12 ± 121.71	-5.53 ± 5.15	1116.34 ± 117.00	1103.81 ± 127.33	-1.19 ± 3.25	12.81	.001
Gray matter§	666.72 ± 106.02	608.99 ± 82.88	-8.01 ± 8.17	725.10 ± 68.50	710.43 ± 71.78	-1.99 ± 4.67	5.79	.001
Frontal lobe	203.83 ± 33.30	180.27 ± 26.77	-10.92 ± 9.15¶	226.53 ± 20.35	219.26 ± 20.88	-3.11 ± 5.39		
Parietal lobe	109.55 ± 17.44	99.54 ± 14.28	-8.51 ± 8.51#	121.49 ± 11.48	116.36 ± 12.55	-4.24 ± 4.72		
Temporal lobe	173.39 ± 29.52	160.25 ± 24.65	-7.02 ± 7.68¶	183.11 ± 17.98	183.58 ± 17.44	0.42 ± 5.47		
Occipital lobe	60.46 ± 11.99	59.32 ± 10.05	-0.74 ± 11.90	65.50 ± 9.54	67.67 ± 11.12	3.52 ± 10.66		
White matter§	384.19 ± 40.95	381.14 ± 46.06	-0.83 ± 4.98	391.24 ± 57.24	393.38 ± 62.30	0.45 ± 3.21	0.78	.54
Frontal lobe	143.12 ± 15.94	137.20 ± 16.46	-4.05 ± 6.06	148.86 ± 22.06	145.55 ± 23.16	-2.28 ± 4.32		
Parietal lobe	76.27 ± 7.63	76.60 ± 8.08	0.55 ± 6.24	77.13 ± 11.18	79.00 ± 12.51	2.31 ± 3.92		
Temporal lobe	80.15 ± 10.78	80.87 ± 11.92	0.91 ± 5.42	80.54 ± 12.22	83.24 ± 13.43	3.32 ± 4.49		
Occipital lobe	34.83 ± 5.28	35.21 ± 5.56	1.32 ± 7.62	33.31 ± 6.58	34.25 ± 7.12	2.88 ± 7.83		

*Values are mean ± SD.

†Values are in cubic centimeters.

‡Values were calculated as follows: ((follow-up - baseline)/baseline) × 100.

§Multivariate analysis of variance was used for gray matter vs white matter: *F*_{4,44}, 6.23; *P* = .004.

||Post hoc results for diagnostic differences: *P* = .003.

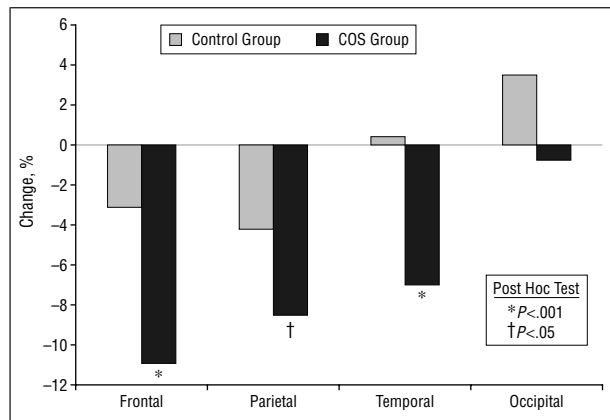
¶Post hoc results for diagnostic differences: *P* = .001.

#Post hoc results for diagnostic differences: *P* = .04.

sectional studies of clinically referred children and adolescents³⁴ and healthy prescreened controls,³⁵ which found age-related decreases in cortical gray matter.³⁵ Most recently, Sowell et al^{36,37} found similar and striking age-related decreases in frontal and parietal gray matter for 35 healthy children and adolescents for whom statistical mapping of subtraction images was carried out. Brain regions do not normally mature in parallel, and the re-

gional changes seen here are more robust than generally seen in young adults.¹²

These longitudinal data for middle and late adolescence show that frontocortical gray matter volume is decreasing. While it is tempting to ascribe these developmental brain changes to peripubertal events, this is clearly not the case. Evidence from cross-sectional studies,^{29,34,35,38,39} shows that the trend for decrease in gray mat-



Change in regional cortical gray matter volumes during adolescence (between mean ages 13 and 18 years) by brain magnetic resonance imaging for healthy volunteers ($n = 34$) and patients with childhood-onset schizophrenia (COS) ($n = 15$) (multivariate analysis of variance for gray matter volume by diagnosis: $F, 3.68; P = .004$).

ter volume and continued myelination occurs across a wide age range. Previous postmortem^{40,41} data also show decreases in occipital cortex volume during the first decade of life.

The adolescents with schizophrenia showed an exaggerated pattern of brain changes similar in part to that of the controls, with a significantly more robust decrease in volume for the frontal and parietal gray matter and no significant change in occipital gray matter. The significant decrease in temporal lobe volume was, however, unique to the schizophrenic group. The selective regional decline in frontal and temporal gray matter is consistent with the MRI findings in adult-onset schizophrenia, for which the greatest regional difference is found in the frontal and temporal areas.⁴² These data are also consistent with evidence suggesting that abnormalities in frontal and temporal lobe connectivity underlie the symptoms of schizophrenia.⁴³ Thus, a specific pattern in keeping with MRI findings for adults with schizophrenia develops across the adolescent years. The presumed changes underlying this differential progression would include excessive synaptic and dendritic pruning, and probably also trophic glial and vascular decreases, compatible with the neuropathological findings of Selemon et al,⁴⁴ Rajkowska et al,⁴⁵ and Selemon and Goldman-Rakic⁴⁶ showing increased neuronal density and possible trophic glial changes in the schizophrenic cortex.

Adolescence is a period of marked change in brain anatomy and metabolism.⁴⁷⁻⁴⁹ Because neuropathological observations of normal development are based on very meager data sets since death during childhood and adolescence of otherwise healthy individuals is rare, brain MRI studies provide a unique and noninvasive way to study brain development in healthy children.²⁹ This study extends our earlier cross-sectional data with the first longitudinal brain MRI study of healthy adolescents; surprisingly robust changes are seen during this limited period between ages 13 and 18 years.

This study of diagnostic differences in brain development is limited by many factors. The samples are not matched for socioeconomic status, race, IQ score, or exposure to neuroleptic medication. Moreover, several COS

patients were switched to therapy with newer atypical antipsychotics at follow-up. In addition, COS patients represent a severely ill, treatment-refractory population; "episodes" of illness were virtually unknown and fluctuations in clinical state were regrettably few. Thus, it might be argued that these differences in progression reflect the course of a subgroup of subjects with poor outcomes described in previous studies of patients with adult-onset schizophrenia. This seems unlikely, however, given that as our patients reach their early adult years, the rate of ventricular enlargement slows and does not differ from that of healthy controls.⁵⁰ Thus, the lack of progression seen in most studies of adult patients was also observed in our subjects after they passed through adolescence.

In theory, the late progressive brain changes might reflect some unique interaction between adolescent brain development and the illness, including stress and drastically altered environmental exposure and/or treatments, not seen in schizophrenia at other ages. This possibility cannot be addressed by these data. An ongoing longitudinal MRI study of our patients' siblings may shed further light on a familial genetic basis for these progressive events. It is unlikely, however, that the patients' differential weight gain affected our findings; after age was taken into account, neither weight nor body mass index was significantly related to any brain measure or to these progressive changes.

The differential changes seen in our COS patients are not directly relevant to the issue of "triggers" for psychosis. Our patients had a mean age of onset of psychotic symptoms of 10.3 years (Table 1), while their mean age at first scan was 14 years. These data do, however, indirectly support models of schizophrenia postulating^{51,52} later abnormalities of brain development.

Finally, this study does not undermine the neurodevelopmental model of schizophrenia. In fact, the early developmental histories of our group show more striking impairments in language and motor development than reported for patients with adult-onset schizophrenia. However, it is already evident that genes known to influence prenatal brain development may also play a role in later maturation.⁵³ These findings do indicate that etiologic models of schizophrenia, whether genetic or environmental, need to take into account both early and late neurodevelopmental events.

Accepted for publication March 30, 1999.

Reprints: Judith L. Rapoport, MD, Child Psychiatry Branch, National Institute of Mental Health, Bldg 10, Room 3N202, 10 Center Dr, MSC 1600, Bethesda, MD 20892-1600 (e-mail: rapoport@helix.nih.gov).

REFERENCES

- Weinberger DR. Implications of normal brain development for the pathogenesis of schizophrenia. *Arch Gen Psychiatry*. 1987;44:660-669.
- Weinberger D. From neuropathology to neurodevelopment. *Lancet*. 1995;346:552-557.
- Murray R. Neurodevelopmental schizophrenia: the rediscovery of dementia praecox. *Br J Psychiatry*. 1994;165:6-12.
- Jones P, Rodgers B, Murray R, Marmot, M. Child developmental risk factors for adult schizophrenia in the British 1946 birth cohort. *Lancet*. 1994;344:1398-1402.

5. Done D, Crow T, Johnstone E, Sacker A. Childhood antecedents of schizophrenia and affective illness: social adjustment at ages 7 and 11. *BMJ*. 1994;309:699-703.
6. Walker E, Lewine R. Predictions of adult onset schizophrenia from childhood home movies of the parents. *Am J Psychiatry*. 1990;147:1052-1056.
7. Mathalon DH, Sullivan EV, Lim KO, Pfefferbaum A. Longitudinal analysis of MRI brain volumes in schizophrenia. *Schizophr Res*. 1997;24:152.
8. DeLisi LE, Tew W, Xie S, Hoff AL, Sakuma M, Kushner M, Lee G, Shadlock K, Smith AM, Grimson R. A prospective follow-up study of brain morphology and cognition in first-episode schizophrenic patients: preliminary findings. *Biol Psychiatry*. 1995;38:349-360.
9. DeLisi LE, Sakuma M, Tew W, Kushner M, Hoff AL, Grimson R. Schizophrenia as a chronic active brain process: a study of progressive brain structural change subsequent to the onset of schizophrenia. *Psychiatry Res*. 1997;74:129-140.
10. DeLisi LE, Stritzke P, Riordan H, Holan V, Boccio A, Kushner M, McClelland J, Van Eyl O, Anand A. The timing of brain morphological changes in schizophrenia and their relationship to clinical outcome. *Biol Psychiatry*. 1992;31:241-254.
11. Nair TR, Christensen JD, Kingsbury SJ, Kumar NG, Terry WM, Garver DL. Progression of cerebroventricular enlargement and the subtyping of schizophrenia. *Psychiatry Res*. 1997;74:141-150.
12. Gur RE, Cowell P, Turetsky BI, Gallacher F, Cannon T, Bilker W, Gur RC. A follow-up magnetic resonance imaging study of schizophrenia: relationship of neuroanatomical changes to clinical and neurobehavioral measures. *Arch Gen Psychiatry*. 1998;55:145-152.
13. Asarnow J. Annotation: childhood onset schizophrenia. *J Child Psychol Psychiatry*. 1994;35:1345-1371.
14. Asarnow R, Brown W, Strandburg R. Children with a schizophrenic disorder: neurobehavioral studies. *Eur Arch Psychiatry Clin Neurosci*. 1995;245:70-79.
15. Frazier JA, Giedd JN, Hamburger SD, Albus KE, Kaysen D, Vaituzis AC, Rajapakse JC, Lenane MC, McKenna K, Jacobsen LK, Gordon CT, Breier A, Rapoport J. Brain anatomic magnetic resonance imaging in childhood-onset schizophrenia. *Arch Gen Psychiatry*. 1996;53:617-624.
16. Jacobsen L, Rapoport J. Childhood-onset schizophrenia: implications of clinical and neurobiological research. *J Child Psychol Psychiatry*. 1998;39:101-113.
17. Alagband-Rad J, McKenna K, Gordon C, Albus K, Hamburger S, Rumsey J, Lenane M, Rapoport J. Childhood onset schizophrenia: the severity of premorbid course. *J Am Acad Child Adolesc Psychiatry*. 1995;43:1273-1283.
18. Kumra S, Wiggs E, Krasnewich D, Meck J, Smith A, Bedwell J, Fernandez T, Jacobsen L, Rapoport J. Association of sex chromosome anomalies with childhood onset psychotic disorder. *J Am Acad Child Adolesc Psychiatry*. 1998;37:292-296.
19. Nicolson R, Rapoport J. Childhood-onset schizophrenia: what can it teach us? In: Rapoport J, ed. *Childhood Onset of Adult Psychopathology: Clinical and Research Advances*. Washington, DC: American Psychiatric Press Inc. In press.
20. Rapoport JL, Giedd J, Kumra S, Jacobsen L, Smith A, Lee P, Nelson J, Hamburger S. Childhood-onset schizophrenia: progressive ventricular change during adolescence. *Arch Gen Psychiatry*. 1997;54:897-903.
21. Collins DL, Neelin P, Peters TM, Evans AC. Automatic 3D intersubject registration of MR volumetric data in standardized Talairach space. *J Comput Assist Tomogr*. 1994;18:192-205.
22. Collins DL, Holmes C, Peters TM, Evans AC. Automatic 3D segmentation of neuroanatomical structures from MRI. *Hum Brain Mapping*. 1995;3:190-208.
23. Zijdenbos A, Evans A, Riah F, Sled J, Chui H-C, Kollokian, V. Automatic quantification of multiple sclerosis lesion volume using stereotaxic space. In: Hohne KH, Kikinis R, eds. *Proceedings of the Fourth International Conference on Visualization in Biomedical Computing (VBC)*. New York, NY: Springer Publishing Co Inc; 1996:439-448.
24. Evans AC, Collins DL, Holmes CJ. Automatic 3D regional MRI segmentation and statistical probability anatomy maps. In: Uemura K, Jones T, Lassen NA, Kanno I, eds. *Quantification of Brain Function: Tracer Kinetics and Image Analysis in Brain PET*. New York, NY: Excerpta Medica; 1995:123-130.
25. Sled JG, Zijdenbos AP, Evans AC. A non-parametric method for automatic correction of intensity non-uniformity in MRI data. *IEEE Trans Med Imaging*. 1998;17:87-97.
26. Gordon CT, Frazier JA, McKenna K, Giedd J, Zemetkin A, Zahn, T, Hommer D, Hong W, Kaysen D, Albus KE. Childhood-onset schizophrenia: an NIMH study in progress. *Schizophr Bull*. 1994;20:697-712.
27. McKenna K, Gordon CT, Lenane M, Kaysen D, Fahey K, Rapoport J. Looking for childhood onset schizophrenia: the first 71 cases screened. *J Am Acad Child Adolesc Psychiatry*. 1994;33:636-644.
28. Kumra S, Frazier JA, Jacobsen LK, McKenna K, Gordon CT, Lenane MC, Hamburger SD, Smith AK, Albus KE, Alagband-Rad J, Rapoport JL. Childhood-onset schizophrenia: a double-blind clozapine-haloperidol comparison. *Arch Gen Psychiatry*. 1996;53:1090-1097.
29. Giedd JN, Snell JW, Lange N, Rajapakse JC, Casey BJ, Kozuch PL, Vaituzis AC, Vauss YC, Hamburger SD, Kaysen D, Rapoport JL. Quantitative magnetic resonance imaging of human brain development: ages 4-18. *Cereb Cortex*. 1996;6:551-560.
30. Hollingshead AB. *Four Factor Index of Social Status*. New Haven, Conn: Yale University Department of Sociology;1975.
31. Collins DL, Evans AC. Animal: validation and applications of non-linear registration-based segmentation. *Int J Pattern Recognition Artif Intell*. 1997;11:1271-1294.
32. Zijdenbos A, Forghani R, Evans AC. Automatic quantification of MS lesions in 3D MRI brain data sets: validation of INSECT. In: Delp S, Wells WM, Colchester A, eds. *Medical Image Computing and Computer-Assisted Intervention—MICCAI '98: First International Conference, Cambridge, MA, USA, October 11-13, 1998, Proceedings*. New York, NY: Springer-Verlag NY Inc; 1998:439-448.
33. Duvernoy HM. *The Human Brain: Surface, Three-Dimensional Sectional Anatomy With MRI and Blood Supply*. New York, NY: Springer-Verlag NY Inc; 1995:3-15.
34. Pfefferbaum A, Mathalon DH, Sullivan EV, Rawles JM, Zipursky RB, Kim KO. A quantitative magnetic resonance imaging study of changes in brain morphology from infancy to late adulthood. *Arch Neurol*. 1994;51:874-887.
35. Reiss A, Abrams M, Singer H, Ross J, Denckla M. Brain development, gender, and IQ in children: a volumetric imaging study. *Brain*. 1996;119:1763-1774.
36. Sowell E, Thompson P, Holmes C, Jernigan TR, Barth R, Naravan S, Toga A. Statistical parametric mapping of structural brain changes between childhood and adolescence. Presented as poster 123.4 at: 28th Annual Meeting of the Society for Neurosciences; November 7-12, 1998; Los Angeles, Calif.
37. Sowell E, Jernigan T. Further MRI evidence of late brain maturation: limbic volume increases and changing asymmetries during childhood and adolescence. *Dev Neuropsychol*. In press.
38. Benes F, Turtle M, Khan Y, Farol P. Myelination of a key relay zone in the hippocampal formation occurs in the human brain during childhood, adolescence, and adulthood. *Arch Gen Psychiatry*. 1994;51:477-484.
39. Jernigan T, Tallal P. Late childhood changes in brain morphology observable with MRI. *Dev Med Child Neurol*. 1990;32:379-385.
40. Huttenlocher P, DeCourten C. The development of synapses in striate cortex of man. *Hum Neurobiol*. 1987;6:1-9.
41. Sauer B, Kammradt I, Krauthausen G, Kretschmann H, Lange H, Wingert F. Qualitative and quantitative development of the visual cortex in man. *J Comp Neurol*. 1983;214:441-450.
42. Cannon TD, van Erp TG, Huttunen M, Lonnqvist J, Salonen O, Valanne L, Poutanen VP, Standertskjold-Nordenstam CG, Gur RE, Yan M. Regional gray matter, white matter, and cerebrospinal fluid distributions in schizophrenic patients, their siblings, and controls. *Arch Gen Psychiatry*. 1998;55:1084-1091.
43. Weinberger D, Berman K, Suddath R, Torrey E. Evidence of dysfunction of a prefrontal-limbic network in schizophrenia: a magnetic resonance imaging and regional cerebral blood flow study of discordant monozygotic twins. *Am J Psychiatry*. 1992;149:890-897.
44. Selemon LD, Rajkowska G, Goldman-Rakic PS. Abnormally high neuronal density in the schizophrenic cortex: a morphometric analysis of prefrontal area 9 and occipital area 17. *Arch Gen Psychiatry*. 1995;52:805-818.
45. Rajkowska G, Selemon LD, Goldman-Rakic PS. Neuronal and glial somal size in the prefrontal cortex: a postmortem morphometric study of schizophrenia and Huntington disease. *Arch Gen Psychiatry*. 1998;55:215-224.
46. Selemon LD, Goldman-Rakic PS. The reduced neuropil hypothesis: a circuit-based model of schizophrenia. *Biol Psychiatry*. 1999;45:17-25.
47. Huttenlocher PR. Synaptic density in human frontal cortex—developmental changes and effects of aging. *Brain Res*. 1979;163:195.
48. Huttenlocher PR, Dabholkar AS. Regional differences in synaptogenesis in human cerebral cortex. *J Comp Neurol*. 1997;387:167-178.
49. Chugani H, Phelps M, Mazziotta JC. Positron emission tomography study of human brain functional development. *Ann Neurol*. 1987;22:487-497.
50. Giedd J, Jeffries N, Nicolson R, Hamburger SD, Nelson J, Vaituzis AC, Lenane M, Rapoport JL. Differential progression of MRI ventricular and temporal lobe structure during adolescence for childhood onset schizophrenics. *Biol Psychiatry*. In press.
51. Feinberg I. Schizophrenia: caused by a fault in programmed synaptic elimination during adolescence? *J Psychiatr Res*. 1982;17:317-334.
52. Feinberg I, Thode HC Jr, Chugani HT, March JD. Gamma distribution model describes maturational curves for delta wave amplitudes, cortical metabolic rate and synaptic density. *J Theor Biol*. 1990;142:149-161.
53. Irwin SA, Swain RA, Christian FA, Chakravarti A, Galvez R, Greenough WT. Behavioral alteration of fragile X mental retardation protein expression. Presented as poster 171.7 at: 28th Annual Meeting of the Society for Neurosciences; November 7-12, 1998; Los Angeles, Calif.