

Brain Volume Changes in First-Episode Schizophrenia

A 1-Year Follow-up Study

Wiepke Cahn, MD; Hilleke E. Hulshoff Pol, PhD; Elleke B. T. E. Lems, MS; Neeltje E. M. van Haren, MS; Hugo G. Schnack, PhD; Jeroen A. van der Linden, MD; Patricia F. Schothorst, MD, PhD; Herman van Engeland, MD, PhD; René S. Kahn, MD, PhD

Background: Imaging studies of patients with schizophrenia have demonstrated that brain abnormalities are largely confined to decreases in gray matter volume and enlargement of the lateral and third ventricles. Global gray matter volume has been reported to progressively decrease in childhood-onset and chronic schizophrenia. Global gray matter volumes have not been examined longitudinally in patients with first-episode schizophrenia. One would expect global gray matter to decrease progressively, particularly in first-episode patients, because clinical deterioration is greatest in the early stages of the disease.

Methods Patients with first-episode schizophrenia who had taken antipsychotic medication for 0 to 16 weeks ($n=34$) and matched healthy comparison subjects ($n=36$) were included in the study. For all subjects, magnetic resonance imaging scans of the whole brain were obtained at inclusion and after 1 year (mean [SD], 12.7 [1.1] months). Outcome was measured 2 years after inclusion. To compare morphological changes over time be-

tween patients and healthy comparison subjects, multiple repeated-measures analyses of variance were conducted with intracranial volume as a covariate. Outcome and cumulative antipsychotic medication were related to changes in patients' brain volumes.

Results: Total brain volume (-1.2%) and gray matter volume of the cerebrum (-2.9%) significantly decreased and lateral ventricle volume significantly increased (7.7%) in patients. The decrease in global gray matter volume significantly correlated with outcome and, independently of that, with higher cumulative dosage of antipsychotic medication.

Conclusions: The loss of global gray matter in schizophrenia is progressive, occurs at an early stage of the illness, and is related to the disease process and antipsychotic medication.

Arch Gen Psychiatry. 2002;59:1002-1010

BRAIN IMAGING studies have consistently demonstrated brain abnormalities in patients with schizophrenia.¹ These changes are largely confined to decreases in gray matter volumes and enlargement of the lateral and third ventricles.^{2,3} Although the origin of schizophrenia is still unknown, schizophrenia has recently been considered to result in part from abnormalities in neurodevelopment. The neurodevelopmental theories of schizophrenia^{4,5} are based on neurocognitive⁶ and motor problems⁷ observed in high-risk children and the apparent lack of progression in brain abnormalities over the course of the illness according to computed tomography⁸⁻¹² (but see Kemali et al¹³) and magnetic resonance imaging (MRI) studies.¹⁴ Some studies report that enlarged ventricles and decreases in brain volumes are already present at disease onset, which is consis-

tent with the notion of a neurodevelopmental origin for the brain abnormalities found in schizophrenia.¹⁵

However, schizophrenia has long been thought to be a progressive or degenerative, not developmental, disorder. Indeed, Kraepelin¹⁶ considered progressive clinical deterioration to be the hallmark of the disorder, naming it dementia praecox to reflect this particular aspect. Lately, others have reemphasized that the decline in functioning in schizophrenia is an important clue to its pathogenesis and that the brain abnormalities in schizophrenia could be expected to reflect this clinical progression.¹⁷⁻²⁰ If brain changes progress over time, one would expect the changes to be particularly pronounced in the first (symptomatic) years of the schizophrenic illness because it is then that the most rapid clinical changes, including deterioration in functioning, are seen.^{21,22} Indeed, it has been suggested that the 5 years after the first psychotic episode are char-

From the Department of Psychiatry, University Medical Center Utrecht, Utrecht, the Netherlands.

Table 1. Demographic Data for 34 Patients With First-Episode Schizophrenia and 36 Healthy Controls*

Characteristic	Patients	Controls	t or χ^2 Test	P Value
Sex, No. of subjects				
Male	29	30	$\chi^2 = 0.05$.82
Female	5	6		
Handedness, No. of subjects				
Right	31	31	$\chi^2 = 2.23$.33
Left	2	5		
Mixed	1	0		
Age, mean \pm SD (range), y	26.2 \pm 5.31 (19-37)	24.5 \pm 5.8 (17-40)	t = -1.23	.22
Weight, mean \pm SD (range), kg, T0	73.0 \pm 12.2 (52-100)	76.1 \pm 11.4 (57-100)	t = 1.11	.27
Height, mean \pm SD (range), cm, T0	177.2 \pm 9.0 (160-193)	184.1 \pm 7.5 (170-199)	t = 3.49	<.001
Parental educational level, mean \pm SD, y	13.47 \pm 3.24	14.03 \pm 2.56	t = 0.80	.43
Education, mean \pm SD, y	11.50 \pm 2.72	12.28 \pm 3.05	t = 1.13	.26
MRI interval, mean \pm SD, mo	12.85 \pm 1.15	12.44 \pm 0.94	t = -1.61	.11

*T0 indicates baseline; MRI, magnetic resonance imaging.

acterized by the largest decline in functioning, followed by a relatively stable clinical period.²³ Significantly, recent longitudinal imaging studies have reported that brain abnormalities increase over time in patients with schizophrenia.^{17,24-36}

A few longitudinal MRI studies have examined brain structures in first-episode patients and their changes over time.^{17,24,25,30,31,34,35} Volume decreases in the total brain,¹⁷ frontal lobe,³⁰ right cerebellum,¹⁷ and superior temporal gyrus³⁴ (but see Keshavan et al³¹) have been reported, as have increases in ventricular volume,¹⁷ at least in a subgroup of poor-outcome patients.³⁵ Moreover, changes may be caused by decreases in focal gray matter, as suggested by findings in the superior temporal gyrus.³⁴

In patients with chronic schizophrenia, prospective studies using computed tomography and MRI have found that lateral ventricle volume increases^{26,29,36} and temporal and frontal lobe gray matter volume decreases³⁶ over time. Global gray matter volume has only been examined prospectively in childhood-onset schizophrenia. A progressive decline in gray matter volume has been found in this rare form of the disorder.³² Thus, longitudinal imaging studies suggest that neurodegenerative processes or progressive abnormalities in neurodevelopment can not be dismissed as possible pathogenic mechanisms in schizophrenia.¹⁷⁻²⁰

Progressive brain volume changes in schizophrenia may be related to outcome. However, results have been inconsistent. A relationship among poor outcome, increases in ventricle volume,^{26,29,35} and decreases in regional gray matter volume³⁶ has been reported. In contrast, other studies failed to find a relationship between brain changes and outcome^{17,24,25} or even reported an inverse relationship.³⁰

Antipsychotic medication may also influence brain volume changes over time. A larger cumulative dosage of antipsychotic medication was related to progressive decreases in frontal lobe volume in patients with first-episode schizophrenia.^{30,37,38} In patients with chronic³⁰ or childhood-onset³² schizophrenia no such relationship was found. One study of first-episode schizophrenia reported an inverse relationship between antipsychotic medication and progressive ventricular changes,

suggesting that antipsychotic medication could prevent pathologic ventricular enlargement.³⁵

No study has examined global gray matter volumes prospectively in first-episode schizophrenia. Therefore, we examined global gray matter volumes in the MRIs of 34 patients with first-episode schizophrenia at baseline and after 1 year. To control for the brain volume changes observed in normal aging,³⁹⁻⁴³ patients were compared with 36 carefully matched healthy subjects. Healthy comparison subjects were scanned twice at the same interval as patients. The Camberwell Assessment of Need (CAN) was used to assess outcome, and the cumulative dosage of antipsychotic medication was calculated.

METHODS

SUBJECTS

Patients with first-episode schizophrenia (n = 34), recruited from the First-Episode Schizophrenia Research Program at the University Medical Center Utrecht, Utrecht, the Netherlands, and healthy comparison subjects (n = 36) were included in the study (**Table 1**). All subjects provided written informed consent prior to participation. For all subjects, MRI scans of the whole brain were obtained at inclusion (T0) and after 1 year (T1) (scan interval, mean [SD], 12.7 [1.1] months).

At baseline, all subjects were physically healthy and did not have a history of head injury or a diagnosis of drug or alcohol abuse or dependence. At 1-year's follow-up, all subjects remained physically healthy.

At inclusion, patients were assessed with the Comprehensive Assessment of Symptoms and History⁴⁴ by 2 trained raters who independently determined the diagnosis and achieved consensus afterward. The onset of prodromal symptoms and the duration of untreated psychosis was measured by a shortened version of the Interview for the Retrospective Assessment of the Onset of Schizophrenia.⁴⁵ Severity of illness was measured with the Positive and Negative Syndrome Scale (PANSS).⁴⁶ Of the 34 patients, 24 had never received antipsychotic medication. The remaining 10 patients had been prescribed antipsychotics for less than 16 weeks before the first scan (T0).

At T1, all 34 patients were reassessed for diagnosis and severity of illness using the Comprehensive Assessment of Symptoms and History and the PANSS; 29 patients then met DSM-IV

Table 2. Clinical Data for 34 Patients With First-Episode Schizophrenia*

Characteristic	T0	T1	T2
<i>DSM-IV</i> diagnosis, No. of patients			
Schizophrenia	23	29	...
Schizoaffective	2	5	...
Schizophreniform	7
Psychotic episode, not otherwise specified	2
Prodromal phase, mo	37.8 ± 51.3
Psychosis, mo	17.2 ± 30.3
Duration of hospitalization between the 2 scans, d	78.9 ± 72.5
PANSS positive symptoms	17.0 ± 4.8	12.9 ± 4.5	...
PANSS negative symptoms	17.9 ± 6.3	15.67 ± 5.2	...
PANSS psychopathology	35.6 ± 10.2	29.0 ± 6.7	...
Total antipsychotic medication (cumulative lifetime in haloperidol equivalents), mg	65.9 ± 157.6	2077.5 ± 962.7	...
Total CAN scale score	0.3 ± 0.2

*Data are given as mean ± SD unless otherwise indicated. T0 indicates baseline; T1, 1 year after study inclusion; T2, 2 years after study inclusion; PANSS, Positive and Negative Syndrome Scale; CAN, Camberbell Assessment of Need; and ellipses, not applicable.

criteria for schizophrenia, and 5 patients met criteria for schizoaffective disorder. The number of days spent in the hospital between T0 and T1 was recorded and used as a measure of 1-year outcome. In addition, every patient was monitored carefully for the amount and type of medication prescribed between T0 and T1. Patients were prescribed typical (n=5) or atypical (n=15) antipsychotics, and a number of patients (n=14) were prescribed typical and atypical antipsychotics, although not simultaneously, at various times during the first year of follow-up. To calculate the cumulative dosage of typical antipsychotics, a table from the Dutch National Health Service was used to derive the haloperidol equivalents.⁴⁷ For atypical antipsychotics, the respective pharmaceutical companies suggested how to convert the dosage into haloperidol equivalents (clozapine, 40:1; olanzapine, 2.5:1; risperidone, 1:1; sulpiride, 170:1; quetiapine, 50:1; and sertindole, 2:1).

Two years after inclusion (T2), 29 of 34 patients continued in this study; 5 patients dropped out (4 refused further participation, and 1 could not be traced). The 2-year outcome was measured with the CAN.⁴⁸ With this instrument, 22 individual domains of clinical and social needs (eg, psychotic symptoms, physical health, accommodation, and intimate relationships) are assessed on a 3-point scale (no need, met need, and unmet need) by interviewing the treating mental health professional (for all clinical data, see **Table 2**).

Healthy comparison subjects were carefully matched for sex, age, parental education, and handedness. They were all screened with the Schedule for Affective Disorders and Schizophrenia–Lifetime Version and fulfilled criteria for “never mentally ill.” At T1, healthy comparison subjects were reassessed with the same procedure. They all remained physically and mentally healthy.

MRI PROCEDURES AND MEASUREMENTS

Magnetic resonance images were acquired with a Philips NT scanner (Philips Medical Systems, Best, the Netherlands) operating at 1.5 T. A T1-weighted 3-dimensional fast field echo (FFE) scan (echo time [TE], 4.6 milliseconds; repetition time [TR], 30 milliseconds; flip angle, 30°; and field of view, 256 mm) with 160 to 180 contiguous coronal 1.2-mm slices and a T2-weighted dual-echo turbo spin-echo scan (TE1, 14 milliseconds; TE2, 80 milliseconds; TR, 6350 milliseconds; flip angle, 90°; and field of view, 256 mm) with 120 contiguous coronal 1.6-mm slices of the whole head were used for the quantitative measurements. In addition, a

T2-weighted dual-echo turbo spin-echo scan (TE1, 9 milliseconds; TE2, 100 milliseconds; TR, 2200 milliseconds; flip angle, 90°; and field of view, 250 mm) with 17 axial 5-mm slices and a 1.2-mm gap of the whole head was acquired for clinical neurodiagnostic evaluation. Processing was done on the neuroimaging computer network of the Department of Psychiatry, University Medical Center Utrecht, which includes Hewlett Packard (Palo Alto, Calif) Unix 9000 workstations, a server, and Pentium III–equipped personal computers. Prior to quantitative assessments, 10 images were randomly chosen and cloned for interrater reliability purposes determined by the intraclass correlation coefficient. All images were coded to ensure blindness for subject identification and diagnosis; scans were put into Talairach frame (no scaling)⁴⁹ and corrected for inhomogeneities in the magnetic field.⁵⁰ Intracranial, total brain, cerebral gray and white matter, lateral ventricle, third ventricle, and cerebellum volumes were then automatically measured with histogram analysis algorithms and a series of mathematical morphological operators to connect all voxels of interest.^{51–53} Intracranial volume was segmented on the dual-contrast turbo spin-echo scans (second echo). Using mathematical morphological operators the intracranial volumes were segmented automatically, with the foramen magnum being used as the inferior boundary. The dual-contrast turbo spin-echo scans and the intracranial region segmentations on them were registered to the 3-dimensional FFE images using a mutual information maximization algorithm.⁵¹ The 3-dimensional FFE images were masked with the binary intracranial volumes. This was done to remove tissues such as extracranial fat. Total brain volumes were segmented on the T1-weighted scans and contained gray and white matter tissue only. Gray and white matter segmentation was done based on intensity histogram shape analysis of the 3-dimensional FFE images and had been calibrated and validated on a set of 80 human brain images.⁵² In lateral ventricle segmentation, automatic decision rules bridged connections that were not detectable and prevented “leaking” into cisterns. The third ventricle was limited by coronal slices that clearly showed the anterior and posterior commissures; the upper boundary was a plane through the plexus choroideus ventriculi tertii in the midsagittal slice perpendicular to this slice. The cerebellum was limited by the tentorium cerebelli and the brainstem. All images were checked after the measurements and corrected manually, if necessary. The interrater reliability of the measurements, determined

Table 3. Anatomic Brain Magnetic Resonance Imaging Measurements for 34 Patients With First-Episode Schizophrenia and 36 Healthy Controls at Baseline and 1 Year*

Brain Volumes	MANCOVA, Group × Time		ANCOVA, Mean ± SD, cm ³							
	F	P Value	T0				T1			
			Patients	Controls	F	P Value	Patients	Controls	F	P Value
Cranium	1.74	.19	1493.2 ± 22.0	1533.7 ± 34.9	1.74	.19	1492.2 ± 26.9	1537.8 ± 36.2	2.09	.15
Total brain	25.64	<.001	1318.7 ± 109.3	1347.2 ± 114.2	0.29	.59	1303.2 ± 114.0	1360.5 ± 113.0	4.41	.04
Gray matter	20.55	<.001	685.6 ± 52.1	693.2 ± 56.8	0.37	.55	665.8 ± 57.8	700.8 ± 52.8	5.70	.02
White matter	0.01	.92	474.0 ± 62.4	490.3 ± 69.2	0.07	.80	476.4 ± 59.5	492.2 ± 65.8	0.22	.64
Cerebellum	0.18	.68	144.9 ± 11.9	149.7 ± 11.7	1.39	.24	146.2 ± 12.6	151.2 ± 12.3	1.34	.25
Lateral ventricle	11.58	.001	14.5 ± 6.5	14.4 ± 9.9	0.96	.33	15.7 ± 7.5	14.4 ± 10.4	2.94	.09
Third ventricle	2.83	.10	0.9 ± 0.4	0.6 ± 0.3	11.51	.01	0.9 ± 0.34	0.6 ± 0.3	21.54	<.001

*T0 indicates baseline; T1, 1 year after study inclusion; MANCOVA, multiple repeated-measures analysis of covariance; and ANCOVA, 1-way analysis of covariance.

by the intraclass correlation coefficient and based on 10 brains, was 0.95 and higher.

STATISTICAL ANALYSES

Brain volume measurements and clinical data were normally distributed. To examine whether brain volumes changed more in patients with first-episode schizophrenia than in the healthy comparison subjects during the 1-year follow-up, multiple repeated-measures analyses of covariance (MANCOVA) with intracranial volume as a covariate were conducted with total brain, cerebellum, gray and white matter of the cerebrum (total brain, excluding cerebellum and brainstem), and lateral and third ventricles as dependent variables and group (patients or healthy comparison subjects) and time (T0 or T1) as independent variables. To examine whether changes in brain asymmetry occurred over 1 year in patients compared with healthy comparison subjects, a MANCOVA was performed with total brain, gray and white matter, and lateral ventricles as dependent variables and group, time, and side (left or right) as independent variables (group × time × side interaction). In case of a significant finding, post hoc paired *t* tests were conducted separately for patients and healthy comparison subjects.

To assess the effect of diagnosis, the same analysis was performed excluding patients with a diagnosis of schizoaffective disorder at T1. Moreover, to examine the effect of prior antipsychotic medication use, the same analysis was conducted with only patients who had never received antipsychotic medication prior to the first scan.

To assess whether brain volumes of patients with first-episode schizophrenia differed from healthy comparison subjects at baseline (scan T0), 1-way analysis of covariance (ANCOVA) was performed with the different brain volumes as dependent variables and group as the independent variable. Intracranial brain volume served as the covariate. To assess whether brain volumes after 1 year (T1) differed between the groups, the same analysis was conducted.

To quantify changes in brain volumes, volumes at T0 were subtracted from volumes at T1 (brain volumes, T1 - T0). To quantify change in positive symptoms and negative symptoms over 1 year, baseline PANSS scores were subtracted from follow-up PANSS scores (PANSS T1 - PANSS T0). To examine associations among brain volume changes (significant T1 - T0 values only), clinical variables (prodromal phase, duration of untreated psychosis, and PANSS T1 - PANSS T0 scores) outcome (duration of hospitalization, T0 - T1), CAN scores (professional perspective scores), and cumulative antipsychotic medication (T0 - T1) in patients, Pearson product-moment

correlations were calculated with intracranial volume as a covariate. To control for baseline scores the same analyses were done with T0 scores added as a covariate.

Exploratory analyses were performed to assess the effect of different types of antipsychotic medication (atypical, typical, or clozapine) on brain morphology using Pearson product-moment correlations. The Statistical Product and Service Solutions statistical package for Windows, version 9.0 (SPSS Inc, Chicago, Ill) was used for these analyses, with a 2-tailed α level of .05.

To control for scanner software upgrades, the same analyses were conducted with the date of the scan added as a covariate.

RESULTS

DEMOGRAPHIC DATA

As seen in Table 1, patients and healthy comparison subjects did not significantly differ with regard to sex, handedness, age, weight, parental education, and scan interval. Although not matched for education, they did not differ from healthy comparison subjects on years of education.

Patients and healthy comparison subjects did significantly differ in height, but because intracranial volume was used as a covariate, the results presented here are uncontrolled for height. However, results did not change when height was used as a covariate.

BRAIN VOLUME CHANGES

Differences Between and Within Groups Over Time

Significant group × time interactions were found for total brain ($F_{1,67} = 25.64$; $P < .001$), gray matter of cerebrum ($F_{1,67} = 20.55$; $P < .001$), and lateral ventricle ($F_{1,67} = 11.58$; $P = .001$) volumes (Table 3). No significant interaction effects of group × time × side were found for any of these measurements. Changes in volume (scan T1 - scan T0) for total brain, gray matter, and lateral ventricles are provided in Figure 1. When patients with a schizoaffective disorder were excluded, the results did not change, except for a significant increase in third ventricle volume over time ($F_{1,62} = 4.89$; $P = .03$). Including only pa-

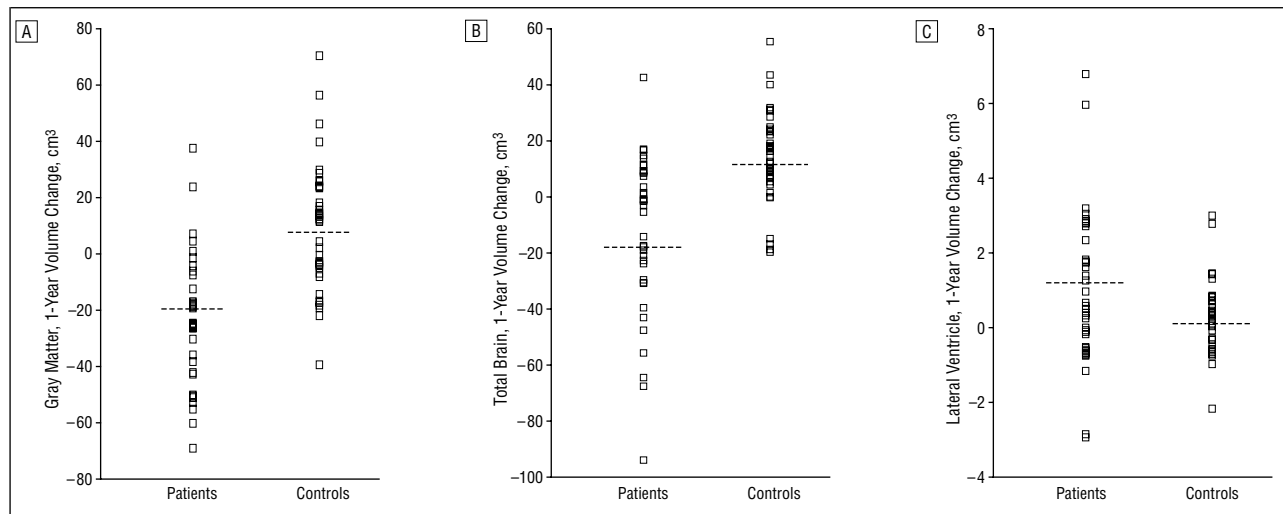


Figure 1. Change during 1 year in gray matter (A), total brain (B), and lateral ventricle (C) volumes of patients with schizophrenia and healthy controls.

tients who had not taken antipsychotics did not change the results, except for another significant increase in third ventricle volume ($F_{1,57}=10.89$; $P=.002$).

In patients, paired t tests (scan T0 vs scan T1) revealed a significant decrease in total brain ($t_{33}=-3.15$; $P=.004$) and gray matter ($t_{33}=-4.65$; $P<.001$) and an increase in lateral ventricle volume ($t_{33}=3.23$; $P=.003$) over 1 year. In healthy comparison subjects, a significant increase in total brain was found over time ($t_{35}=4.76$; $P<.001$). The results did not change when the date of scanning was added as a covariate.

Differences Between Groups at Both Time Points

At the T0 scan, third ventricle volume was significantly larger in patients than in healthy comparison subjects ($F_{2,67}=11.51$; $P=.01$). No other group effects for the different brain volumes were found at scan T0. At scan T1, total brain volume ($F_{2,67}=4.41$; $P=.04$) and cerebral gray matter volume ($F_{2,67}=5.70$; $P=.02$) were found to be smaller in patients compared with healthy comparison subjects. At scan T1, a nonsignificant trend was present for larger lateral ventricles in patients ($F_{2,67}=2.94$; $P=.09$). Third ventricle volumes remained significantly larger in patients at scan T1 ($F_{2,67}=21.54$; $P<.001$). No significant group \times side interaction effects were found for any of these measures at T0 and T1.

Correlations With Clinical Variables and Outcome

Decreases in cerebral gray matter volume over 1 year correlated with 2-year outcomes in patients as measured with the CAN ($r_{26}=-0.50$; $P=.007$). The CAN scores also correlated with decreases in total brain volume ($r_{26}=-0.39$; $P=.04$) and increases in lateral ventricle volume ($r_{26}=0.61$; $P=.001$) (**Figure 2**). No associations were found with duration of prodromal phase, duration of untreated psychosis, change in symptom severity (PANSS T1 – PANSS T0), days spent in the hospital during the first year of treatment, or any of the significant brain volume changes between T0 and T1. The results did not change when the baseline scores were included as a covariate.

Correlations With Antipsychotic Medication

Decreases in cerebral gray matter volume over time correlated significantly with cumulative dose of antipsychotic medication between T0 and T1 ($r_{31}=-0.45$; $P=.009$) (**Figure 3**). This finding was not related to a specific type of antipsychotic medication (atypical, typical, or clozapine). Cumulative antipsychotic medication did not significantly correlate with CAN score ($r_{26}=0.12$; $P=.57$).

COMMENT

This longitudinal study compared brain volume changes in 34 patients with first-episode schizophrenia with those of 36 healthy comparison subjects over a 1-year period. Volumes of total brain, gray and white matter, cerebellum, and lateral and third ventricles were measured. Our main finding is that global gray matter volume significantly declined and lateral ventricle volume increased over this 1-year period in patients compared with healthy comparison subjects. Moreover, these volume changes were significantly related to outcome and, independently of that, to cumulative antipsychotic medication used over the first year of treatment. White matter volume was not different between the 2 groups. Third ventricle volume did not significantly increase over time, but it was already enlarged at baseline. Our findings strongly suggest that gray matter loss is progressive, occurs in the early stages of schizophrenia, and is related to both antipsychotic medication use and outcome.

To our knowledge, no other study has examined global gray matter volume in first-episode schizophrenia during 1 year. Our finding of a progressive global gray matter decrease is consistent with studies of patients with chronic³⁶ and childhood-onset³² schizophrenia. In these studies, gray matter changes were examined over an average of 2 to 4 years, whereas our study examined global gray matter changes during the first year of treatment. The progressive decrease in total brain volume is in concordance with 1 previous longitudinal study of first-episode schizophrenia.¹⁷ In that study, in addition to the finding of decreased total brain volume, an increase in

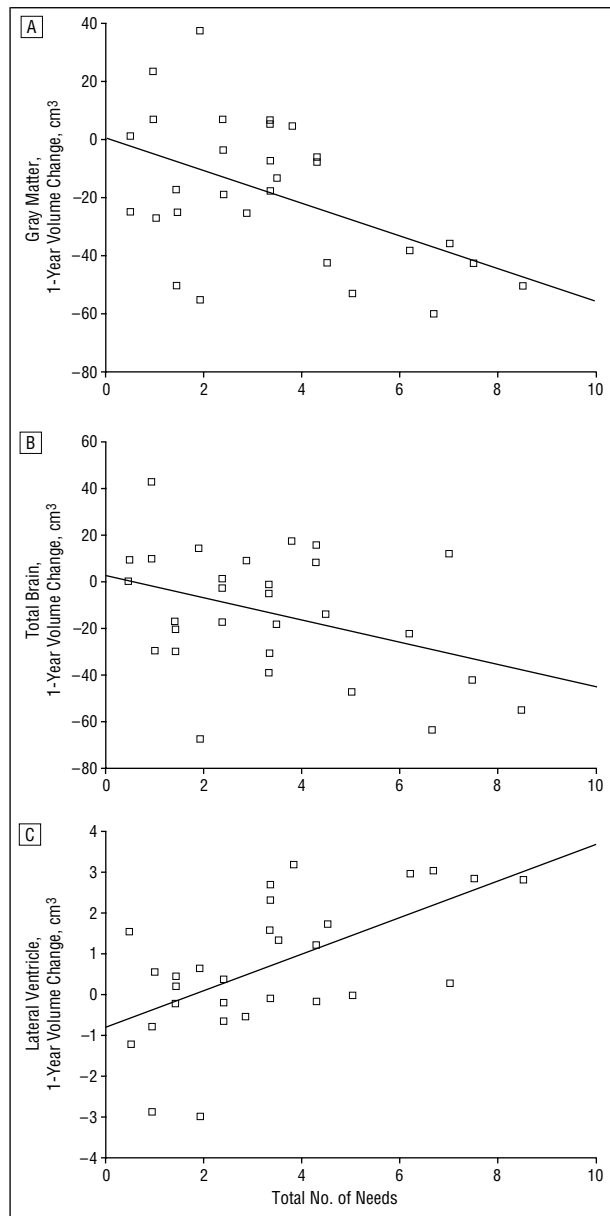


Figure 2. Change during 1 year in gray matter (A), total brain (B), and lateral ventricle (C) volumes and total number of needs, as measured by the Camberwell Assessment of Need,⁴⁸ in patients with schizophrenia.

left lateral ventricle volume was reported. In our sample, a bilateral increase in ventricle volume was found over time. Our finding of total brain volume decreases differs from a first-episode study examining patients for an average of 18 months,³⁵ in which no progressive change in total brain volume was found. In that study, the number of healthy comparison subjects included was small, and the healthy comparison subjects were also older than the patients. Interestingly, however, progressive ventricular enlargement was found in patients with poor outcomes. Similarly, total brain volume did not decline in another study examining 40 patients with schizophrenia (first-episode and chronic) for 2 years.³⁰ Nevertheless, patients did show a more rapid decline in left hemisphere volume compared with the healthy comparison subjects.

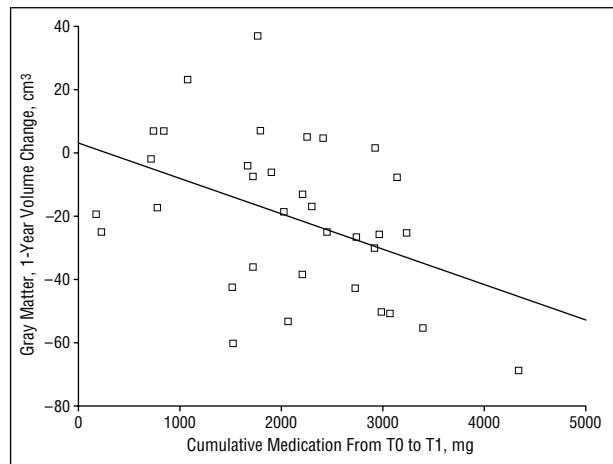


Figure 3. Change in gray matter volume and cumulative dosage of antipsychotic medication from baseline (T0) to 1 year after study inclusion (T1) in patients with schizophrenia.

In the present study, positive and negative symptoms, as rated with the PANSS, were not found to be associated with the changes in brain volumes over time. Associations between symptoms and progressive brain volume changes have been inconsistently reported. Our study is in agreement with some studies^{17,24,25,29} but not with others,^{27,30,35} including those specifically designed to examine gray matter volumes over time.^{27,36} These inconsistencies could be the result of different groups being examined (ie, patients with chronic vs first-episode vs childhood-onset schizophrenia) or the use of different rating scales. Moreover, it has also been suggested that changes in mental state might affect brain volume measurements.⁵⁴ Thus, the differences between this and other studies could be secondary to differences in patients' mental states.

Duration of hospitalization was not found to be associated with brain volume changes over time. This is consistent with 1 study in patients with first-episode schizophrenia¹⁷ but not with another.²⁴ The latter study reported an inverse relationship between duration of hospital stay and ventricular volume because a greater ventricular volume change was found to be associated with a shorter amount of time spent in the hospital. The failure to find an association was also in contrast to a study in patients with chronic schizophrenia that reported an association between a decrease in prefrontal gray matter and total duration of hospitalization.³⁶ In fact, hospitalization may not be a good outcome measure in patients with (first-episode) schizophrenia. Severity of illness is by no means the only reason why patients with schizophrenia are hospitalized or continue to be hospitalized. Factors such as comorbidity,^{55,56} family involvement,⁵⁶ and the availability of regional care services⁵⁷ have an effect on the length of the hospital stay.

Clinical severity and hospitalization may not adequately reflect outcome.^{58,59} This study measured outcome using the CAN, which is known to be a valid and reliable instrument across countries⁶⁰ for assessing the social and clinical needs of people with severe mental illness⁴⁸ and may better reflect long-term disabilities in patients with schizophrenia.⁶¹ In this study, 1-year changes

in volumes of total brain, gray matter, and lateral ventricles were significantly correlated with outcome after 2 years, suggesting that brain volume changes are related to the disease process.

Independent of the association between outcome and progressive gray matter changes, an association was found between higher cumulative dosage of antipsychotic medication and gray matter volume decreases. We did not find an association between gray matter decreases and various types of antipsychotic medication. However, a type II error cannot be excluded because the subject groups were small, especially in the typical antipsychotic medication group ($n=5$). The finding of an association between progressive gray matter change and cumulative antipsychotic medication has not been reported previously in patients with schizophrenia (no such relationship was found in patients with childhood-onset schizophrenia³²). Although it has been suggested that antipsychotics might prevent pathological ventricular enlargement,^{17,24,25,35} it has also been documented that antipsychotics produce morphological changes, most clearly in the striatum,⁶²⁻⁶⁴ with atypical antipsychotics decreasing and typical antipsychotics increasing caudate nucleus volume. Moreover, progressive decreases in frontal lobe volumes in first-episode patients have been associated with higher dosage of antipsychotic medication.^{30,37,38} Indeed, that we did not find differences in brain volumes (except for third ventricle enlargement) between patients and healthy comparison subjects at baseline, which is in disagreement with other studies examining global gray matter in first-episode schizophrenia,^{65,66} could be because most patients were never exposed to antipsychotic medication. Interestingly, third ventricle enlargement has also been found in the healthy siblings of patients with schizophrenia,^{67,68} suggesting that this finding may be related to a genetic vulnerability for schizophrenia. Thus, the progressive brain abnormalities that occur during and after the first psychotic episode can be related to the disease process itself, as is reflected in its relationship with outcome, but also in part to the use of antipsychotic medication.

Our results strongly suggest that progressive brain abnormalities occur in the early (symptomatic) stages of schizophrenia. A recent meta-analysis has shown an overall reduction of about 4% in gray matter volume in patients with schizophrenia.¹ In this study, the 2.9% decrease in gray matter volume on MRIs is suggestive of an active process of neuronal shrinkage or loss occurring in the first year of the disease. Although it is difficult to compare across studies, the relatively large decline of almost 3% in the first year of treatment suggests that the greatest decline in gray matter takes place in the early phase of the disease. Despite the fact that schizophrenia is heterogeneous in its course,⁶⁹ the finding of a relatively large decrease in gray matter volume early in the disease is consistent with clinical evidence. In schizophrenia, a deterioration in functioning starts within the first few months after the appearance of psychotic symptoms, possibly already in the prodromal stage.^{23,70} Moreover, most rehospitalizations cluster within the first 2 years after the first admission,^{71,72} which suggests that the disease is most active during this time period.

An underlying neurodegenerative process in schizophrenia has long been disputed. The lack of fibrillary gliosis in postmortem studies of the schizophrenic cortex was the primary argument against it.¹⁸ Currently, it is believed that the absence of gliosis does not necessarily preclude schizophrenia from being a neurodegenerative disorder because gliosis is not always demonstrable or permanent after neural injury.⁷³ Possibly, psychosis itself could be "toxic" through abnormal excitatory amino acid neurotransmission in glutamatergic systems.⁷⁴ Indeed, increased glutamatergic activity has been suggested to cause cellular damage and death through excitotoxic effects.⁷⁵ Additionally, antipsychotics may have a neurotoxic effect and cause a decrease in neuronal density in the striatum and prefrontal cortex,⁷⁶ although it is unlikely that these subtle changes in neurotransmitters and their systems, due to the disease itself and/or antipsychotic medication, would be sufficient to trigger gliosis or show other signs of ongoing neurodegeneration in the postmortem brain.⁷⁷ Excessive neuronal apoptosis could possibly cause the progressive changes found in schizophrenia.⁷⁸ Apoptosis does not lead to inflammation or necrosis and subsequently gliosis.^{79,80} Interestingly, haloperidol by itself may also cause cortical cell death through apoptosis.⁸¹ Other processes resulting in atrophy, such as abnormal neurite pruning,⁸² have also been proposed in relation to the progressive changes found in schizophrenia.⁷³ Therefore, in this study, the gray matter decreases found on MRI over 1 year could be explained by either (programmed) cell death and/or atrophy.

The increased total brain volume in the healthy comparison group was surprising because the findings of cross-sectional studies conducted in healthy subjects suggest that decreases in total brain volume begin in early adolescence.³⁹⁻⁴¹ This could be an artifact of the scan procedure or a measurement error. However, this is the first prospective imaging study over 1 year in young healthy adults. A prospective study of healthy children, including adolescents aged 22 years and older, suggested decreases in some but increases in other areas (occipital lobe) of gray matter.⁸³ Moreover, evidence is accumulating that white matter increases into the fifth decade of life, which suggests that the adult brain is in a constant state of change.⁴³

There are limitations to this study. First, a selection bias may have affected the results. This is reflected in the patients and healthy comparison subjects having similar years of education at baseline. One could speculate that this may have contributed to the failure to find baseline morphological differences, except for third ventricle enlargement, between patients and healthy comparison subjects. Indeed, gray matter volume has been reported to be related to IQ.⁸⁴ Second, because this study only examined overall changes in global gray matter volume, some brain areas such as the subcortical and limbic structures may contribute more to the effect than others. Third, there was a preponderance of men in the sample. Although the sample was small, women with schizophrenia lost less gray matter volume (-1.6%) than did men (-3%). Other limitations concern antipsychotic medication, such as the use of different types of medication, the lack of standardized haloperidol equiva-

lents for atypical antipsychotics, and inclusion of 10 patients who were not antipsychotic naive.

In summary, the gray matter decrease of nearly 3% in patients with schizophrenia during their first year of treatment, which is associated with outcome and cumulative antipsychotic medication, suggests that the loss of gray matter in patients with schizophrenia is progressive, occurs at an early stage of the illness, and is related to the disease process and antipsychotics.

Submitted for publication June 4, 2001; final revision received March 25, 2002; accepted March 26, 2002.

This study was presented as a poster at the International Congress on Schizophrenia Research, Whistler, British Columbia, May 2, 2001.

Corresponding author and reprints: Wiepke Cahn, MD, Department of Psychiatry, University Medical Center Utrecht, Heidelberglaan 100, 3584 CX Utrecht, the Netherlands (e-mail: w.cahn@psych.azu.nl).

REFERENCES

1. Wright IC, Rabe-Hesketh S, Bullmore ET. Meta-analysis of regional brain volumes in schizophrenia. *Am J Psychiatry*. 2000;157:16-25.
2. Lawrie SM, Abukmeil SS. Brain abnormality in schizophrenia: a systematic and quantitative review of volumetric magnetic resonance imaging studies. *Br J Psychiatry*. 1998;172:110-120.
3. Shenton ME, Dickey CC, Frumin M, McCarley RW. A review of MRI findings in schizophrenia. *Schizophr Res*. 2001;49:1-52.
4. Pilowsky LS, Kerwin RW, Murray RM. Schizophrenia: a neurodevelopmental perspective. *Neuropsychopharmacology*. 1993;9:83-91.
5. Weinberger DR. On the plausibility of "the neurodevelopmental hypothesis" of schizophrenia. *Neuropsychopharmacology*. 1996;14:1S-11S.
6. Erlenmeyer-Kimling L. Neurobehavioral deficits in offspring of schizophrenic parents: liability indicators and predictors of illness. *Am J Med Genet*. 2000;97:65-71.
7. Walker EF, Savoie T, Davis D. Neuromotor precursors of schizophrenia. *Schizophr Bull*. 1994;20:441-451.
8. Nasrallah HA, Olson SC, Jacoby CG. Cerebral ventricular enlargement in schizophrenia. *Arch Gen Psychiatry*. 1986;43:157-159.
9. Illowsky BP, Juliano DM, Weinberger DR. Stability of CT scan findings in schizophrenia: results of an 8 year follow-up study. *J Neurol Neurosurg Psychiatry*. 1988;51:209-213.
10. Vita A, Sacchetti E, Cazzullo CL. Brain morphology in schizophrenia: a 2- to 5-year CT scan follow-up study. *Acta Psychiatr Scand*. 1988;78:618-621.
11. Sponheim SR, Iacono WG, Beiser M. Stability of ventricular size after the onset of psychosis in schizophrenia. *Psychiatry Res*. 1991;40:21-29.
12. Vita A, Giobbio GM, Dieci M, Garbarini M, Morganti C, Comazzi M, Invernizzi G. Stability of cerebral ventricular size from the appearance of the first psychotic symptoms to the later diagnosis of schizophrenia. *Biol Psychiatry*. 1994;35:960-962.
13. Kemali D, Maj M, Salvati A. Ventricles to brain ratio in schizophrenia: a controlled follow-up study. *Biol Psychiatry*. 1989;26:753-756.
14. Degreef G, Ashtari M, Wu HW, Borenstein M, Geisler S, Lieberman J. Follow-up MRI study in first episode schizophrenia. *Schizophr Res*. 1991;5:204-206.
15. McCarley RW, Wible CG, Frumin M, Hirayasu Y, Levitt JJ, Fischer IA, Shenton ME. MRI anatomy of schizophrenia. *Biol Psychiatry*. 1999;45:1099-1119.
16. Kraepelin E. *Dementia Praecox and Paraphrenia*. Edinburgh, Scotland: E & S Livingstone; 1919.
17. DeLisi LE, Sakuma M, Tew W, Kushner M, Hoff AL, Grimson R. Schizophrenia as a chronic active brain process: a study of progressive brain structural change subsequent to the onset of schizophrenia. *Psychiatry Res*. 1997;74:129-140.
18. Woods BT. Is schizophrenia a progressive neurodevelopmental disorder? toward a unitary pathogenetic mechanism. *Am J Psychiatry*. 1998;155:1661-1670.
19. Lieberman JA. Is schizophrenia a neurodegenerative disorder? a clinical and neurobiological perspective. *Biol Psychiatry*. 1999;46:729-739.
20. DeLisi LE. Defining the course of brain structural change and plasticity in schizophrenia. *Psychiatry Res*. 1999;92:1-9.
21. Fenton WS, McGlashan TH. Natural history of schizophrenia subtypes, II: positive and negative symptoms and long-term course. *Arch Gen Psychiatry*. 1991;48:978-986.
22. van der Heiden W, Häfner H. The epidemiology of onset and course of schizophrenia. *Eur Arch Psychiatry Clin Neurosci*. 2000;250:292-303.
23. Davidson L, McGlashan TH. The varied outcomes of schizophrenia. *Can J Psychiatry*. 1997;42:34-43.
24. DeLisi LE, Stritzke P, Riordan H, Holan V, Boccio A, Kushner M, McClelland J, Van Eyl O, Anand A. The timing of brain morphological changes in schizophrenia and their relationship to clinical outcome [published erratum appears in *Biol Psychiatry*. 1992;31:1172]. *Biol Psychiatry*. 1992;31:241-254.
25. DeLisi LE, Tew W, Xie S, Hoff AL, Sakuma M, Kushner M, Lee G, Shedlack K, Smith AM, Grimson R. A prospective follow-up study of brain morphology and cognition in first-episode schizophrenic patients: preliminary findings. *Biol Psychiatry*. 1995;38:349-360.
26. Nair TR, Christensen JD, Kingsbury SJ, Kumar NG, Terry WM, Garver DL. Progression of cerebroventricular enlargement and the subtyping of schizophrenia. *Psychiatry Res*. 1997;74:141-150.
27. Rapoport JL, Giedd J, Kumra S, Jacobsen L, Smith A, Lee P, Nelson J, Hamburger S. Childhood-onset schizophrenia: progressive ventricular change during adolescence. *Arch Gen Psychiatry*. 1997;54:897-903.
28. Jacobsen LK, Giedd JN, Castellanos FX, Vaituzis AC, Hamburger SD, Kumra S, Lenane MC, Rapoport JL. Progressive reduction of temporal lobe structures in childhood-onset schizophrenia. *Am J Psychiatry*. 1998;155:678-685.
29. Davis KL, Buchsbaum MS, Shihabuddin L, Spiegel-Cohen J, Metzger M, Frecska E, Keefe RS, Powchik P. Ventricular enlargement in poor-outcome schizophrenia. *Biol Psychiatry*. 1998;43:783-793.
30. Gur RE, Cowell P, Turetsky BI, Gallacher F, Cannon T, Bilker W, Gur RC. A follow-up magnetic resonance imaging study of schizophrenia: relationship of neuroanatomical changes to clinical and neurobehavioral measures. *Arch Gen Psychiatry*. 1998;55:145-152.
31. Keshavan MS, Haas GL, Kahn CE, Aguilar E, Dick EL, Schooler NR, Sweeney JA, Pettegrew JW. Superior temporal gyrus and the course of early schizophrenia: progressive, static, or reversible? *J Psychiatr Res*. 1998;32:161-167.
32. Rapoport JL, Evans A. Progressive cortical change during adolescence in childhood-onset schizophrenia. *Arch Gen Psychiatry*. 1999;56:649-654.
33. Giedd JN, Jeffries NO, Rapoport JL. Childhood-onset schizophrenia: progressive brain changes during adolescence. *Biol Psychiatry*. 1999;46:892-898.
34. Hirayasu Y, Shenton ME, McCarley RW. Progressive change in posterior superior temporal gyrus in schizophrenia [abstract]. *Biol Psychiatry*. 1999;45:117S.
35. Lieberman J, Chakos M, Wu H, Alvir J, Hoffman E, Robinson D, Bilder R. Longitudinal study of brain morphology in first episode schizophrenia. *Biol Psychiatry*. 2001;49:487-499.
36. Mathalon DH, Sullivan EV, Lim KO, Pfefferbaum A. Progressive brain volume changes and the clinical course of schizophrenia in men: a longitudinal magnetic resonance imaging study. *Arch Gen Psychiatry*. 2001;58:148-157.
37. Madsen AL, Keidling N, Karle A, Esbjerg S, Hemmingsen R. Neuroleptics in progressive structural brain abnormalities in psychiatric illness [letter]. *Lancet*. 1998;352:784-785.
38. Madsen AL, Karle A, Rubin P, Cortsen M, Andersen HS, Hemmingsen R. Progressive atrophy of the frontal lobes in first-episode schizophrenia: interaction with clinical course and neuroleptic treatment. *Acta Psychiatr Scand*. 1999;100:367-374.
39. Pfefferbaum A, Mathalon DH, Lim KO. A quantitative MRI study of changes in brain morphology from infancy to late adulthood. *Arch Neurol*. 1994;51:874-887.
40. Steen RG, Ogg RJ, Reddick WE, Kingsley PB. Age-related changes in the pediatric brain: quantitative MR evidence of maturational changes during adolescence. *AJNR Am J Neuroradiol*. 1997;18:819-828.
41. Courchesne E, Chisum HJ, Press GA. Normal brain development and aging: quantitative analysis of in vivo MRI in healthy volunteers. *Radiology*. 2000;216:672-682.
42. Jernigan TL, Archibald SL, Fennema-Notestine C, Gamst AC, Stout JC, Bonner J, Hesselink JR. Effects of age on tissues and regions of the cerebrum and cerebellum. *Neurobiol Aging*. 2001;22:581-594.
43. Bartzokis G, Beckson M, Lu PH, Muechterlein KH, Edwards N, Mintz J. Age-related changes in frontal and temporal lobe volumes in men: a magnetic resonance imaging study. *Arch Gen Psychiatry*. 2001;58:461-465.
44. Andreasen NC, Arndt S. The Comprehensive Assessment of Symptoms and History (CASH): an instrument for assessing diagnosis and psychopathology. *Arch Gen Psychiatry*. 1992;49:615-623.
45. Häfner H, Riecher-Rössler A, Hambrecht M, Maurer K, Meissner S, Schmidtke A, van der Heiden W. IRAOS: an instrument for the assessment of onset and early course of schizophrenia. *Schizophr Res*. 1992;6:209-223.
46. Kay SR, Fiszbein A, Opler LA. The Positive and Negative Syndrome Scale (PANSS) for schizophrenia. *Schizophr Bull*. 1987;13:261-276.
47. Commissie Farmaceutische Hulp van het College voor Zorgverzekeringen. *Farmacotherapeutisch Kompas* [in Dutch]. Amstelveen, the Netherlands: Commissie Farmaceutische Hulp van het College voor Zorgverzekeringen; 2000.

48. Phelan M, Slade M, Hayward P. The Camberwell Assessment of Need: the validity and reliability of an instrument to assess the needs of people with severe mental illness. *Br J Psychiatry*. 1995;167:589-595.
49. Talairach J, Tournoux P. *Co-planar Stereotaxic Atlas of the Human Brain: 3-Dimensional Propositional System: An Approach to Cerebral Imaging*. New York, NY: Thieme Medical Publishers; 1988.
50. Sled JG, Zijdenbos AP, Evans AC. A nonparametric method for automatic correction of intensity nonuniformity in MRI data. *IEEE Trans Med Imaging*. 1998;17:87-97.
51. Maes F, Collignon A, Vandermeulen D, Marchal G, Suetens P. Multimodality image registration by maximization of mutual information. *IEEE Trans Med Imaging*. 1997;16:187-198.
52. Schnack HG, Hulshoff Pol HE, Baare WF, Staal WG, Viergever MA, Kahn RS. Automated separation of gray and white matter from MR images of the human brain. *Neuroimage*. 2001;13:230-237.
53. Schnack HG, Hulshoff Pol HE, Baare WF, Viergever MA, Kahn RS. Automatic segmentation of the ventricular system from MR images of the human brain. *Neuroimage*. 2001;14:95-104.
54. Garver DL, Nair TR, Christensen JD, Holcomb JA, Kingsbury SJ. Brain and ventricle instability during psychotic episodes of the schizophrenias. *Schizophr Res*. 2000;44:11-23.
55. Huntley DA, Cho DW, Christman J, Csernansky JG. Predicting length of stay in an acute psychiatric hospital. *Psychiatr Serv*. 1998;49:1049-1053.
56. Olsson M, Mechanic D, Boyer CA, Hansell S, Walkup J, Weiden PJ. Assessing clinical predictions of early rehospitalization in schizophrenia. *J Nerv Ment Dis*. 1999;187:721-729.
57. Sytema S, Burgess P. Continuity of care and readmission in two service systems: a comparative Victorian and Groningen case-register study. *Acta Psychiatr Scand*. 1999;100:212-219.
58. Carpenter WT, Bartko JJ, Strauss JS, Hawk AB. Signs and symptoms as predictors of outcome: a report from the International Pilot Study of Schizophrenia. *Am J Psychiatry*. 1978;135:940-944.
59. Carpenter WT, Strauss JS. The prediction of outcome in schizophrenia, IV: eleven-year follow-up of the Washington IPSS cohort. *J Nerv Ment Dis*. 1991;179:517-525.
60. Wijngaarden B, Schene AH, McCrone P. Caregiving in schizophrenia: development, internal consistency and reliability of the involvement evaluation questionnaire (BES). *Br J Psychiatry*. 2000;177:S21-S27.
61. Lasalvia A, Ruggeri M, Mazzi MA, Dall'Agnola RB. The perception of needs for care in staff and patients in community-based mental health services. The South-Verona Outcome Project 3. *Acta Psychiatr Scand*. 2000;102:366-375.
62. Chakos MH, Lieberman JA, Alvir J, Bilder R, Ashtari M. Caudate nuclei volumes in schizophrenic patients treated with typical antipsychotics or clozapine. *Lancet*. 1995;345:456-457.
63. Westmoreland P, Nopoulos P, Andreasen NC, Heckel D, Arndt S. Caudate size in first episode neuroleptic naive schizophrenia patients measuring using an artificial neural network. *Soc Biol Psychiatry*. 1999;46:712-720.
64. Scheepers FE, Gispens de Wied CC, Hulshoff Pol HE, Kahn RS. Effect of clozapine on caudate nucleus volume in relation to symptoms of schizophrenia. *Am J Psychiatry*. 2001;158:644-646.
65. Lim KO, Tew W, Kushner M, Chow K, Matsumoto B, DeLisi LE. Cortical gray matter volume deficit in patients with first-episode schizophrenia. *Am J Psychiatry*. 1996;153:1548-1553.
66. Zipursky RB, Lambe EK, Kapur S, Mikulis DJ. Cerebral gray matter volume deficits in first episode psychosis. *Arch Gen Psychiatry*. 1998;55:540-546.
67. Seidman LJ, Faraone SV, Goldstein JM, Goodman JM, Kremen WS, Toomey R, Tourville J, Kennedy D, Makris N, Caviness VS, Tsuang MT. Thalamic and amygdala-hippocampal volume reductions in first-degree relatives of patients with schizophrenia: an MRI-based morphometric analysis. *Biol Psychiatry*. 1999;46:941-954.
68. Staal WG, Hulshoff Pol HE, Schnack HG, Hoogendoorn MLC, Kahn RS. Structural brain abnormalities in patients with schizophrenia and their healthy siblings. *Am J Psychiatry*. 2000;157:416-421.
69. Carpenter WT, Schooler NR, Wise SS, Goldman H, Goldstein MJ, Hogarty GE, Jeste D, Kane JM, Klerman GL, Liberman RP, Paul SM, Robinson DS, Spring B, Stahl SM, Tamminga CA. Treatment, services, and environmental factors. *Schizophr Bull*. 1988;14:427-437.
70. Häfner H, Löffler W, Maurer K, Hambrecht M, van der Heiden W. Depression, negative symptoms, social stagnation, and social decline in the early course of schizophrenia. *Acta Psychiatr Scand*. 1999;100:105-118.
71. Eaton WW, Bilker W, Haro JM, Herrman H, Mortensen PB, Freeman H, Burgess P. Long-term course of hospitalization for schizophrenia, part II: change with passage of time. *Schizophr Bull*. 1992;18:229-241.
72. Eaton WW, Mortensen PB, Herrman H, Freeman H, Bilker W, Burgess P, Wooff K. Long-term course of hospitalization for schizophrenia, part I: risk for rehospitalization. *Schizophr Bull*. 1992;18:217-228.
73. Harrison PJ. The neuropathology of schizophrenia: a critical review of the data and their interpretation. *Brain*. 1999;122(pt 4):593-624.
74. Olney JW, Farber NB. Glutamate receptor dysfunction and schizophrenia. *Arch Gen Psychiatry*. 1995;52:998-1007.
75. McEwen BS, Magarinos AM. Stress effects on morphology and function of the hippocampus. *Ann N Y Acad Sci*. 1997;821:271-284.
76. Harrison PJ. The neuropathological effects of antipsychotic drugs. *Schizophr Res*. 1999;40:87-99.
77. Horton K, Forsyth CS, Sibtain N, Ball S, Bruton CJ, Royston MC, Roberts GW. Ubiquitination as a probe for neurodegeneration in the brain in schizophrenia: the prefrontal cortex. *Psychiatry Res*. 1993;48:145-152.
78. Margolis RL, Chuang DM, Post RM. Programmed cell death: implications for neuropsychiatric disorders. *Biol Psychiatry*. 1994;35:946-956.
79. Vaux DL. Toward an understanding of the molecular mechanisms of physiological cell death. *Proc Natl Acad Sci U S A*. 1993;90:786-789.
80. Bredesen DE. Neural apoptosis. *Ann Neurol*. 1995;38:839-851.
81. Noh JS, Kang HJ, Kim EY, Sohn S, Chung YK, Kim SU, Gwag BJ. Haloperidol-induced neuronal apoptosis: role of p38 and c-Jun-NH(2)-terminal protein kinase. *J Neurochem*. 2000;75:2327-2334.
82. Feinberg I. Schizophrenia: caused by a fault in programmed synaptic elimination during adolescence? *J Psychiatr Res*. 1982;17:319-334.
83. Giedd JN, Blumenthal J, Jeffries NO, Castellanos FX, Liu H, Zijdenbos A, Paus T, Evans AC, Rapoport JL. Brain development during childhood and adolescence: a longitudinal MRI study. *Nat Neurosci*. 1999;2:861-863.
84. Andreasen NC, Flaum M, Swayze V, O'Leary DS, Alliger R, Cohen G, Ehrhardt J, Yuh WT. Intelligence and brain structure in normal individuals. *Am J Psychiatry*. 1993;150:130-134.