

Early-Life Stress Induces Long-term Morphologic Changes in Primate Brain

Simona Spinelli, PhD; Svetlana Chefer, PhD; Stephen J. Suomi, PhD; J. Dee Higley, PhD; Christina S. Barr, VMD, PhD; Elliot Stein, PhD

Context: Traumatic experiences in early childhood are associated with increased risk of developing stress-related disorders, which are linked to structural brain abnormalities. However, it is unclear whether these volumetric brain changes are present before disease onset or reflect the consequences of disease progression.

Objective: To identify structural abnormalities in the nonhuman primate brain that may predict increased risk of stress-related neuropsychiatric disorders in human beings.

Design: Rhesus monkeys were divided into 2 groups at birth: a group raised with their mothers and other juvenile and adult animals (mother reared) and a group raised with 3 age-matched monkeys only (peer reared) for the first 6 months of life. Anatomical brain images were acquired in juvenile male and female rhesus monkeys using magnetic resonance imaging.

Setting: National Institutes of Health Animal Center in Poolesville, Maryland.

Subjects: Twenty-eight rhesus monkeys (*Macaca mulatta*) aged 24 to 30 months were used for the study.

Main Outcome Measures: Volumetric measures of the anterior cingulate cortex, medial prefrontal cortex, hippocampus, corpus callosum, and cerebellar vermis were compared between mother-reared (n=15) and peer-reared animals (n=13).

Results: Compared with mother-reared monkeys, we found an enlarged vermis, dorsomedial prefrontal cortex, and dorsal anterior cingulate cortex in peer-reared monkeys without any apparent differences in the corpus callosum and hippocampus.

Conclusions: Peer-rearing during infancy induces enlargement in stress-sensitive brain regions. These changes may be a structural phenotype for increased risk of stress-related neuropsychiatric disorders in human beings.

Arch Gen Psychiatry. 2009;66(6):658-665

Author Affiliations: Laboratory of Clinical and Translational Studies, National Institute on Alcohol Abuse and Alcoholism (Drs Spinelli and Barr), Neuroimaging Research Branch, National Institute on Drug Abuse (Drs Chefer and Stein), and Laboratory of Comparative Ethology, National Institute of Child Health and Human Development (Dr Suomi), National Institutes of Health and Human Services, Bethesda, Maryland; and Department of Psychology, Brigham Young University, Provo, Utah (Dr Higley). Dr Spinelli is now with Developmental Cognitive Neurology, Kennedy Krieger Institute, The Johns Hopkins School of Medicine, Baltimore, Maryland.

TRAUMATIC EXPERIENCES during early childhood have been consistently associated with increased risk of developing stress-related neuropsychiatric disorders later in life including depression, anxiety, and substance abuse.^{1,2} Brain-imaging studies have demonstrated morphologic changes in healthy adults exposed to early-life stress,³ children exposed to abuse,⁴ and children and adults with maltreatment-related post-traumatic stress disorders (PTSDs).^{5,6} These findings suggest that regional brain abnormalities may be present before the onset of disease and, thus, are a risk factor for subsequent stress-related neuropsychiatric disorders. However, retrospective clinical studies can be difficult to interpret because of the variety of experiences that can be considered traumatic, differences in the timing and intensity of the stressors, and the unknown effects of medications. Moreover, the long-term effects of stress exposure may be delayed or ex-

pressed only when the vulnerable brain system reaches maturation.⁷ It is, therefore, important to clearly define and control for the type and duration of the stressor and for the developmental stage during stress exposure and at the time of brain measurement to clarify whether the reported brain abnormalities were present before illness onset or reflect the consequences of disease progression.

Evidence from human and preclinical studies indicates that the hippocampus (HC), cerebellum (CB), prefrontal cortex (PFC), and corpus callosum (CC) are particularly susceptible to stress.² These brain regions have a long period of post-natal development, relatively high levels of glucocorticoid receptors (GRs), and, in the case of the HC, some degree of post-natal neurogenesis that may contribute to their vulnerability to stress.^{2,8,9}

Not only are these brain regions vulnerable to stress together with many of their prominent connections, including the anterior cingulate cortex (ACC), but they also

have been implicated in emotional regulation and stress reactivity,¹⁰⁻¹² which suggests a risk factor for stress-related neuropsychiatric disorders later in life. In support of this conjecture, decreased volume of both the rostral ACC (rACC) and dorsal ACC (dACC) has been found in adults exposed to early-life stress,^{3,13} and reduced HC volume has been demonstrated in adults exposed to chronic stress.¹⁴ Further, CB vermis (CBV) abnormalities have been reported in adults who were abused during childhood,¹⁵ and a smaller CC is found in neglected children.^{4,16}

Results of preclinical studies and studies in human beings have shown that early-life stress induces both acute and long-term dysregulation of the hypothalamic-pituitary-adrenal (HPA) axis¹⁷ and the serotonin (5-hydroxytryptamine) system.¹⁸ Dysfunctions of both systems have been widely implicated in mood and anxiety disorders,¹⁹ and the 2 systems have reciprocal influences.²⁰ Together, these data suggest that abnormal brain development after early-life stress may, at least in part, be related to dysregulation of the HPA axis and the serotonin system.

The objective of the present study was to determine whether exposure to an adverse environment during infancy leads to long-term morphologic changes in vulnerable brain structures in nonhuman primates. Comparative studies have shown a high degree of homology between the human and nonhuman primate brain, especially in PFC regions.²¹ Further, compared with rodents, primate PFC and CB exhibit higher levels of GRs,²² which highlights the importance of using nonhuman primates reared in a well-controlled environment to model the consequences of early-life stress on human brain development.

We acquired anatomical brain images in juvenile rhesus monkeys that were reared either with their mothers and social group (mother reared [MR]) or with 3 infants of about the same age (peer reared [PR]). Peer-rearing is an established model of early-life adversity that alters the HPA axis and the serotonin system and induces high levels of anxiety throughout development to adulthood.²³⁻²⁹

We hypothesized that stress-sensitive brain regions including the medial PFC (mPFC, which includes the rACC), dACC, HC, CBV, and CC would be smaller in juvenile PR monkeys compared with MR monkeys. To control for the specificity of any changes in the prefrontal regions, the posterior part of the cingulate cortex (PCC) and the entire prefrontal lobe (PFL) were also measured. Because peer-rearing induces long-term changes in the HPA axis and the serotonin system,^{25,27,28} we hypothesized that baseline activity of the HPA axis and the serotonin system at the time of the study would be related to regional structural changes. Thus, plasma levels of cortisol and cerebrospinal fluid (CSF) levels of the main serotonin metabolite, 5-hydroxyindoleacetic acid (5-HIAA), were determined.

METHODS

SUBJECTS

Twenty-eight rhesus monkeys (*Macaca mulatta*) aged 23 to 32 months were used for the study. The monkeys, representing 2 birth cohorts, were born and housed at the National Institutes

of Health Animal Center in Poolesville, Maryland. The animals were randomly divided at birth into 2 groups, which resulted in different social and rearing experiences early in life. The MR monkeys (n=15; 7 male and 8 female) were reared for the first 6 months of life with their biological or cross-fostered mothers (n=4) and fathers in social groups consisting of 8 to 12 adult females (about half of which had same-aged infants) and 2 adult males. The PR monkeys (n=13; 7 female and 6 male) were separated from their mothers and housed in an incubator for the first 14 days of life. From days 14 to 37, they were placed alone in a nursery cage and provided a blanket and a terry cloth-covered rocking surrogate. At 37 days of age, they were placed in a cage with 3 other same-age monkeys with whom they had continuous access. The PR condition deprives animals of parental input and the opportunity to learn appropriate social behaviors and context during early development and is considered a model for early-life stress. Both rearing conditions are described in detail elsewhere.³⁰ After 6 months, PR and MR monkeys were raised together in a large social group that included adult, juvenile, and infant monkeys until the time of the study. At the time of the study, the rhesus monkeys were aged 24 to 32 years, a range considered to correspond to age 6 to 8 years in children.³¹ The animals were transported in groups of 4 to the National Institute on Drug Abuse, where they were housed in pairs for about 1 month during which magnetic resonance imaging data were acquired. Paired housing allowed social interactions with familiar animals and, thus, limited the stress of the new environment. Protocols were approved by the institutional Animal Care and Use Committee of the National Institute on Alcohol Abuse and Alcoholism, the National Institute on Drug Abuse, and the National Institute of Child Health and Human Development, National Institutes of Health and Human Services.

NEUROCHEMICAL SAMPLING AND ANALYSES

One week before shipment, CSF and blood samples were collected from each monkey. Blood samples, 2 mL, were drawn from the femoral vein, and CSF samples, 2 mL, were obtained via cisternal puncture, both using intramuscularly administered anesthesia (ketamine hydrochloride, 10 mg/kg). The CSF sample data from 2 female monkeys (1 MR and 1 PR) were not analyzed because of contamination. All samples were collected between 11:30 AM and 2:30 PM, within 15 minutes of the investigator's entrance to the housing facility for capture and sampling. Cisternal CSF samples were immediately aliquoted into polypropylene tubes and frozen in liquid nitrogen. Blood samples were placed on wet ice and centrifuged at 4°C for 20 minutes. Then the plasma was aliquoted and frozen in liquid nitrogen. The CSF and plasma samples were stored at -80°C until assay. The plasma cortisol level was assessed using a commercially available radioimmunoassay kit (tkco5, Coat-a-Count; Siemens Healthcare Diagnostics, Deerfield, Illinois). Simultaneous determination of 5-HIAA in CSF was performed with high-performance liquid chromatography using electrochemical detection as previously described.²⁴

BRAIN IMAGE ACQUISITION AND ANALYSES

Each monkey was initially anesthetized using intramuscularly administered ketamine, 10 mg/kg. Anesthesia was maintained throughout the study with continuous infusion of intravenously administered propofol, 30 to 50 mg/kg/h. An individually molded thermoplastic face mask was secured to a custom-made monkey head holder to reduce head movement during scanning. Vital signs were monitored continuously during the study.

Images were acquired using a 3.0-T scanner (Allegra; Siemens Medical Solutions, Inc, Malvern, Pennsylvania). The parameters for the 3-dimensional, T1-weighted magnetization-prepared rapid gradient-echo acquisition were as follows: repetition time/echo time/inversion time, 2500/3.49/1000 ms; 1 slab of 224 sections, 0.60-mm section thickness, 0.30-mm spacing, 8°-flip angle, 256 × 256-pixel acquisition matrix, and 4 signals acquired. The acquisition was run at 4 excitations using dual-surface coils (Nova Medical, Inc, Wilmington, Massachusetts). The 3-dimensional slab was placed over the entire brain, centered, and angled on the anteroposterior commissures line.

Image processing was performed with Analyze 7.5 (Biomedical Imaging Resource, Mayo Foundation, Rochester, Minnesota). For manual tracings of the regions of interest (ROIs), T1-weighted images were converted to cubic voxel dimensions of 0.39 mm. All images were oriented in a standardized oblique plane to eliminate any bias in section angle. In the standardized orientation, the transaxial plane was parallel to the anteroposterior commissures line and perpendicular to the interhemispheric fissure.

ANATOMICAL SUBDIVISIONS

The ROIs were defined using the atlas of Saleem and Logothetis³² and were measured by 1 rater blinded to subject sex and rearing condition; a second independent rater (S.C.) performed identical measurements to establish reliability and accuracy of the measurement, which was calculated for every ROI on each brain side. The minimum value for interrater and intrarater reliability, calculated as intraclass correlation coefficients, was 0.89 to 0.97, respectively. Manual tracing for the PFC, cingulate cortex (CingC), and HC were performed in the coronal plane, edited in the sagittal or axial planes, and re-edited in the coronal view; the CC and CBV were drawn using the midsagittal view, and the intracranial volumes (ICVs) were traced on the axial view.

The ICVs were calculated by tracing each axial section, excluding the skull and the dura. A semiautomated, threshold-based, region-growing algorithm was used to outline the brain in each axial section. The ICV was defined and subsequently measured as all gray and white matter tissues and CSF volumes in both hemispheres, including part of the midbrain. The inferior border of the pons was chosen for demarcation because it is readily and reliably identifiable on monkey brain images.³³

ROI DEFINITIONS

The CingC ROI (**Figure 1A** and **B**) comprised the entire CingC above the CC. The coronal section containing the initial appearance of the genu of the CC was selected as the anterior boundary, and the posterior boundary was the last coronal section containing the most posterior part of the splenium of the CC. The CingC was divided further into 2 subregions, the dACC and the posterior part of the CingC (PCC). The posterior border of the dACC was defined on the coronal view as the section previous to that in which the arcuate hypothalamic nucleus was apparent. The subsequent section marked the anterior border of the PCC (**Figure 1A**, vertical line).

The PFL volume was traced on coronal sections (**Figure 1C**) in each hemisphere separately and included all gray and white matter tissue up to the most anterior coronal section containing gray matter. The posterior boundary was the coronal section before the initial appearance of the genu of CC.³⁴ The mPFC (**Figure 1D**) in each hemisphere was defined as the gray matter located along the medial wall of the PFL, with the posterior boundary based on the PFL tracing. Because of the diffi-

culty in distinguishing the boundaries between gray and white matter in the most anterior sections, the anterior boundary was defined in the coronal view as the 10th section posterior to the first coronal section containing only gray matter. In 1 animal, the mPFC could not be traced because of image artifacts. In addition, to better characterize the mPFC subdivision that included the rostral ACC, we excluded the most ventral part from the measurement and analyzed the dorsomedial part (dmPFC).³⁴ Therefore, the mPFC was divided further into dorsal and ventral subdivisions by tracing a horizontal line parallel to the edge of the splenium of the CC on the coronal and sagittal views (**Figure 1E**). This line marked the first axial section (without the appearance of splenium) to be included in the ventral subdivision of the mPFC. The PCC and PFL volumes were measured to enable control of the specificity of our results in the mPFC and the dACC.

The HC (**Figure 1F** and **G**) on each brain side was measured on coronal sections in an anteroposterior direction. The most anterior coronal section used for the analyses was defined on the sagittal section where the HC length was maximal and the rostral end of the HC was present at the most anterior point. The most posterior section was identified as a section in which the HC first appeared adjacent to the trigone of the lateral ventricle.³³ Two 0.6-mm sections anterior to this location were excluded from the determination of the HC volume because of lack of reliable boundaries for differentiating the amygdala from the HC. Volume measurements were performed using a region-drawing technique that relies on gray and white matter segmentation. Compared with other methods, such as the Cavalieri method,³⁵ which still requires identification of landmarks clearly visible on a T1-weighted magnetic resonance image, the region-drawing technique used is more time consuming. A stereologic approach eliminates the need to draw regions on each magnetic resonance imaging section and is free from mathematical bias. Nevertheless, manual segmentation is a highly reliable and reproducible method for volumetric measurements. Moreover, comparison between the results obtained using the 2 methods reveal that both yield high repeatability and precision.³⁶

For the CC analysis (**Figure 1E**), the midsagittal area of the CC was measured in its entirety and, based on its length, was divided further into 3 equal subdivisions: the anterior CC including the genu, rostrum, and the rostral body; the middle CC including the anterior and posterior midbodies; and the posterior CC including the isthmus and splenium.³⁷ Because the CC was often difficult to define using the midsagittal section, the adjacent section in the right hemisphere was used. The subregion analyses were conducted based on previous findings in children with PTSD related to maltreatment⁵ and in rhesus monkeys reared in isolation³⁸ that showed that the middle or posterior part of the CC was more affected.

The CBV (**Figure 1H**) was drawn from the midsagittal section.³⁹ When the ROI was defined as an area rather than a volume, we normalized the measured area by dividing the square root of the area by the cubic root of the ICV to bring all measures to the same geometric dimensionality.³⁷

DATA ANALYSES

Commercially available software (StatView 5.0.1; SAS Institute, Inc, Cary, North Carolina) was used for all statistical analyses. The Kolmogorov-Smirnov normality test was used to ensure the normal distribution of each measurement. To assess the effects of rearing condition and sex on each ROI, 2-way analysis of variance was conducted with rearing condition (MR or PR) and sex (male or female) as independent variables. When ROIs were measured in both hemispheres, repeated-measures

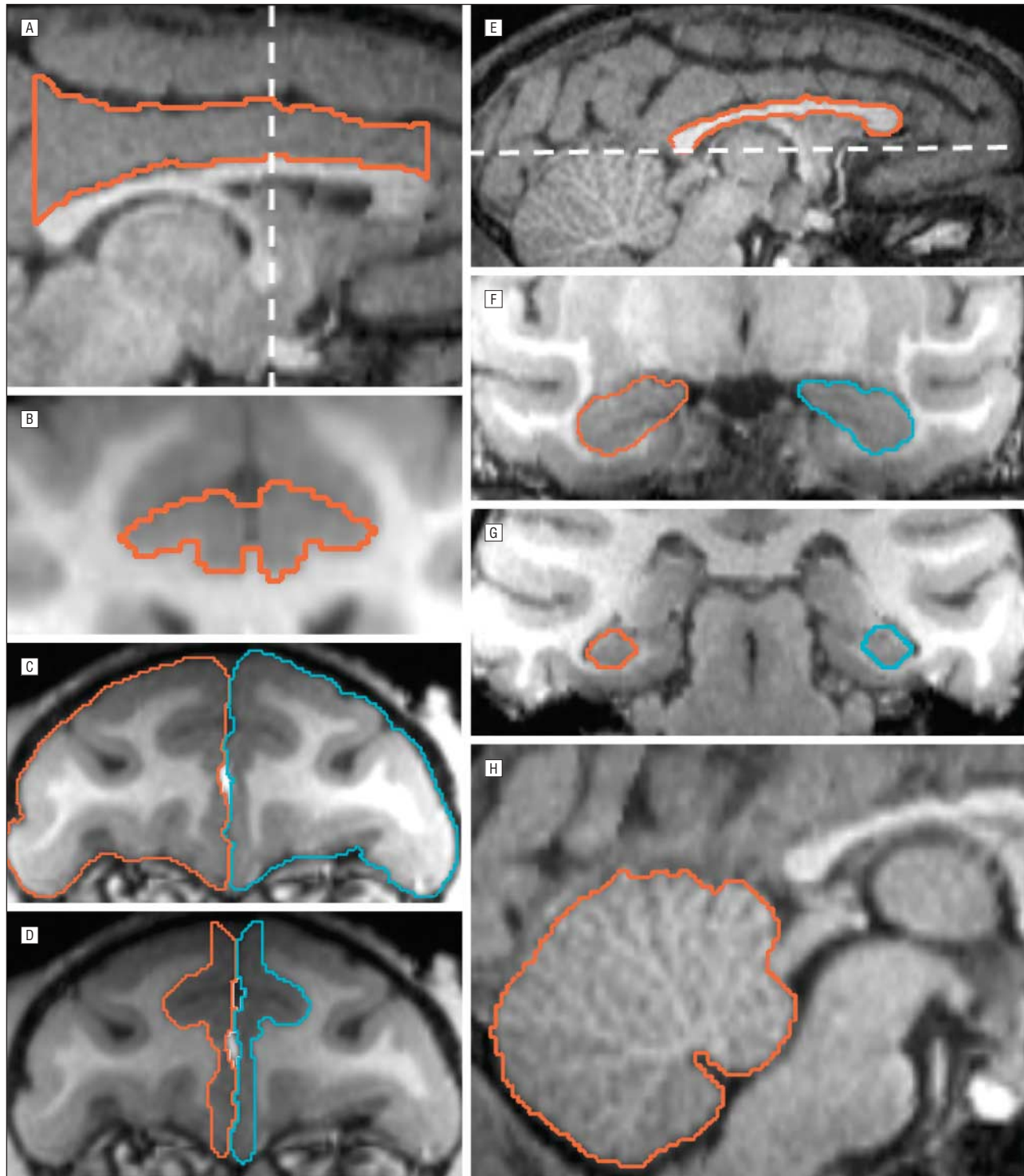


Figure 1. Representative T1-weighted magnetic resonance images in 2-year-old rhesus monkeys illustrate the region-of-interest boundaries used to trace regional volumes. Sagittal (A) and coronal (B) views of the cingulate cortex. The vertical dashed line on the sagittal view indicates the division of the cingulate cortex into the dorsal anterior cingulate cortex and the posterior cingulate cortex. Coronal views of the prefrontal lobe (C) and the medial prefrontal cortex (D). Sagittal views of the corpus callosum (E) and the cerebellum vermis (H). E, The dashed line indicates the ventral boundary of the more dorsal prefrontal cortex. Coronal views of anterior (F) and posterior (G) sections of the hippocampus. Sagittal views of the corpus callosum (E) and cerebellum vermis (H). Right site, orange tracing line; left site, blue tracing line.

analysis of variance with hemisphere was used as the within-subject variable. The Pearson correlation (R) was used to investigate the relationship between ROI volumes and baseline levels of 5-HIAA and cortisol. Effects of rearing condition and sex on baseline levels of 5-HIAA and cortisol, in addition to

ICV, weight, and age, were assessed using 2-way analysis of variance. All data are given as mean (SEM), with significance testing set as 2-tailed analysis with $\alpha = .05$. Correction for multiple comparisons was not applied; however, P values for each statistical analysis are provided.

Table 1. Physiologic Data in MR and PR Monkeys

Variable	Mean (SEM)		
	MR Monkeys	PR Monkeys	Statistical Analysis
Age, mo	27.40 (0.90)	26.39 (0.33)	$F_{1,24}=0.89$; $P>.35$
Weight, kg	3.61 (0.13)	3.44 (0.09)	$F_{1,24}=0.96$; $P>.33$
Cortisol, $\mu\text{g/dL}$	33.02 (1.22)	34.62 (1.80)	$F_{1,24}=0.43$; $P>.23$
5-HIAA, pmol/mL	268.18 (16.18)	241.28 (13.85)	$F_{1,24}=1.51$; $P>.51$

Abbreviations: 5-HIAA, 5-hydroxyindoleacetic acid; MR, mother reared; PR, peer reared.
SI conversion factor: To convert cortisol to nanomoles per liter, multiply by 27.588.

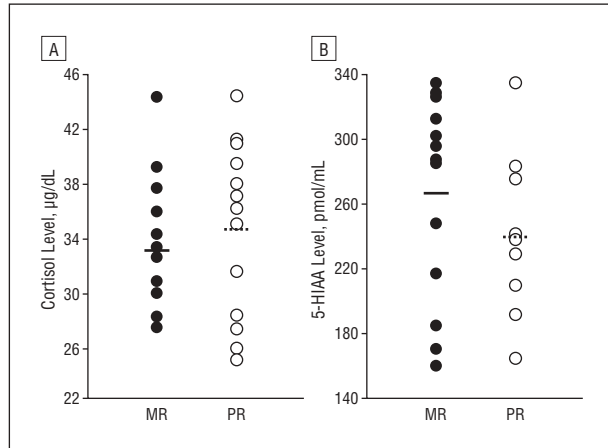


Figure 2. Cortisol (A) and 5-hydroxyindoleacetic acid (5-HIAA) (B) scatterplots of individual monkeys in the mother-reared (MR) and peer-reared (PR) groups, with means plotted as horizontal lines. To convert cortisol to nanomoles per liter, multiply by 27.588.

RESULTS

PHYSIOLOGIC CHARACTERISTICS

We found no sex or rearing differences in age ($P>.17$ and $P>.35$, respectively), weight ($P>.29$ and $P>.33$), baseline plasma cortisol concentration ($P>.42$ and $P>.51$), or CSF 5-HIAA concentration ($P>.62$ and $P>.23$) (**Table 1** and **Figure 2**).

BRAIN ANATOMICAL MEASURES

Peer-rearing did not affect total ICV ($P>.49$; **Table 2**), although as expected, male rhesus monkeys had larger mean (SEM) brain volumes (97 097.75 [1828.03] mm^3) compared with female monkeys (87 190.06 [1510.26] mm^3) ($F_{1,24}=17.76$; $P<.001$). Because of this sex difference in ICV, regional volume data were normalized to individual ICV.

Cingulate Cortex

The PR monkeys had larger dACC volumes compared with the MR monkeys ($F_{1,24}=4.46$; $P<.05$; **Table 2**). As expected, there was no effect of rearing on either PCC ($P>.79$; **Table 2**) or sex effects (dACC, $P>.26$; PCC, $P>.72$).

Prefrontal Cortex

The mPFC analyses showed a rearing \times sex \times hemisphere interaction ($F_{1,23}=4.91$; $P<.04$); however, separate analyses for each hemisphere did not demonstrate any significant effect of rearing (right, $P>.15$; left, $P>.19$) or sex (right, $P>.88$; left, $P>.96$). Further analyses of the dorsal subdivision of the mPFC showed greater dmPFC size in PR monkeys compared with MR monkeys ($F_{1,23}=6.92$; $P<.02$; **Table 2**). There was also a rearing \times sex \times hemisphere interaction ($F_{1,23}=5.12$; $P<.04$); therefore, separate analyses for each hemisphere were conducted. In both the right ($F_{1,23}=6.37$; $P<.02$) and left ($F_{1,23}=6.88$; $P<.02$) hemispheres, PR monkeys exhibited greater dmPFC, although there was no effect of sex (right, $P>.20$; left, $P>.22$).

Analyses of the PFL showed a smaller size of this region in the right hemisphere compared with the left hemisphere ($F_{1,24}=11.41$; $P<.003$; **Table 2**). There was also a rearing \times sex \times hemisphere interaction ($F_{1,24}=7.24$; $P<.02$); however, separate analyses for each hemisphere revealed no effect of rearing (right, $P>.47$; left, $P>.77$) or sex (right, $P>.98$; left, $P>.68$).

Hippocampus

Rearing condition and sex did not influence HC volume ($P>.47$ and $P>.57$, respectively) (**Table 2**), although the right HC was larger than the left ($F_{1,24}=15.41$; $P<.001$).

Cerebellar Vermis

The PR monkeys exhibited a larger CBV area compared with the MR monkeys ($F_{1,24}=14.33$; $P<.001$; **Table 2**); however, there was no effect of sex in this area ($P>.11$).

Corpus Callosum

There was a significant main effect of subregions ($F_{2,48}=179.82$; $P<.001$) and sex ($F_{1,24}=4.87$; $P<.04$) on CC volume. Separate analyses for each subregion showed larger middle CC ($F_{1,24}=5.28$; $P<.04$) and posterior CC ($F_{1,24}=9.37$; $P<.01$) in female compared with male animals but no difference in the anterior CC ($P>.53$). The total CC area and studied CC subregions were not affected by rearing condition ($P>.87$; **Table 2**).

CORRELATION WITH BASELINE PLASMA CORTISOL AND CSF 5-HIAA CONCENTRATIONS

We found a significant correlation between the right dmPFC volume and 5-HIAA levels ($R=0.40$; $P<.05$; **Table 3**). However, correlation between the left dmPFC volume and 5-HIAA levels did not reach significance ($P>.06$). None of the other volumes measured correlated with baseline cortisol or 5-HIAA concentrations.

COMMENT

Our data demonstrate that PR, a well-established model of early-life stress in nonhuman primates, has long-term consequences on morphologic brain development.

Table 2. Normalized and Absolute Volumes of Brain Areas Measured in MR and PR Groups

Brain Area	Mean (SEM)				Absolute Volume Difference, %	Statistical Analyses for Normalized Values
	Normalized Volume ^a		Absolute Volume, mm ³			
	MR Monkeys	PR Monkeys	MR Monkeys	PR Monkeys		
ICV	91 121.10 (1904.22)	92 561.94 (2413.57)	1.61	...
dACC	5.29 (0.13)	5.74 (0.17)	481.98 (15.84)	531.71 (21.87)	10.32	$F_{1,24}=4.46; P<.05$
PCC	10.81 (0.27)	10.93 (0.22)	984.99 (32.91)	1011.61 (34.23)	2.70	$F_{1,24}=0.07; P>.79$
Right mPFC	7.59 (0.14)	7.99 (0.23)	692.13 (19.16)	741.37 (23.37)	7.11	$F_{1,23}=2.20; P>.15$
Left mPFC	7.53 (0.14)	7.90 (0.23)	685.99 (18.90)	734.04 (23.87)	7.00	$F_{1,23}=1.87; P>.19$
Right dmPFC	6.12 (0.13)	6.64 (0.18)	557.97 (16.43)	616.35 (16.78)	10.46	$F_{1,23}=6.37; P<.02$
Left dmPFC	6.15 (0.12)	6.67 (0.16)	560.57 (15.4)	618.74 (16.93)	10.38	$F_{1,23}=6.88; P<.02$
Right PFL	35.31 (0.50)	36.13 (0.91)	3218.09 (80.31)	3336.38 (100.03)	3.68	$F_{1,24}=0.52; P>.47$
Left PFL	36.42 (0.50)	36.68 (0.81)	3317.83 (79.04)	3393.01 (109.48)	2.27	$F_{1,24}=0.08; P>.77$
Right HC	5.31 (0.11)	5.18 (0.12)	481.66 (8.45)	479.28 (16.06)	-0.49	$F_{1,24}=0.48; P>.49$
Left HC	5.16 (0.10)	5.04 (0.12)	467.77 (6.90)	465.82 (13.44)	-0.42	$F_{1,24}=0.52; P>.47$
CC	125.21 (1.20)	125.28 (1.81)	31.79 (0.82)	32.21 (1.15)	1.32	$F_{1,24}=0.03; P>.87$
CBV	254.66 (2.09)	264.43 (1.56)	131.99 (2.31)	142.93 (2.66)	8.29	$F_{1,24}=14.33; P<.01$

Abbreviations: CBV, cerebellar vermis; CC, corpus callosum; dACC, dorsal anterior cingulate cortex; dmPFC, dorsomedial prefrontal cortex; ellipses, data not available; HC, hippocampus; ICV, intracranial volume; mPFC, medial prefrontal cortex; MR, mother reared; PCC, posterior cingulate cortex; PFL, prefrontal lobe; PR, peer reared.

^aNormalized values were calculated as region-of-interest volume/ICV. The CBV and CC were defined as areas rather than volumes; therefore, data were normalized by dividing the square root of the area by the cubic root of the ICV to bring all measures to the same geometric dimensionality.³⁶ All normalized values were multiplied by 1000.

That the data were collected several months after cessation of the stress exposure, when the monkeys were still juveniles, enabled us to investigate (1) the long-term consequences of stress on brain morphologic features and (2) brain abnormalities that are present independent of the influence of hormonal changes that occur during and after adolescence. In 2-year-old rhesus monkeys exposed to such an adverse environment during infancy, we observed an increase in size in the dorsal part of the mPFC, the dACC, and the CBV but no difference in the CC and HC volumes. There were also no changes in PCC, PFL, or ICV size, which suggests that the reported changes were not the consequence of a generalized abnormal brain development but were specific effects on brain regions particularly vulnerable to early-life stress exposure.

The primary finding of the present study is increased dmPFC and dACC volumes in PR monkeys compared with MR animals. Because the dmPFC measure included the rostral part of the anterior CingC, these data suggest that the entire ACC might have been sensitive to early-life stress exposure. In support of the specificity of this result, we found no differences in the PCC.

Previous findings in human beings report reduced rACC volume in healthy subjects exposed to early-life stress³ and reduced dACC in adults with abuse-related PTSD.¹³ However, recent data demonstrate an increased volume of the middle inferior PFC gray matter (including the rACC) in pediatric PTSD,³⁴ which support our findings in nonhuman primates and suggest that developmental differences may be important.

On a cellular level, the abnormal ACC development could be mediated by several processes including altered neuronal organization, increased number or size of neurons or synapses, or nonneuronal changes involving the glia. Molecular changes in the ACC have been found in children and adolescents with maltreatment-related PTSD,⁴⁰ in adults with PTSD,⁴¹ and in monkeys

Table 3. Correlation Between Normalized Volumes and Baseline 5-HIAA and Cortisol Levels

Brain Area	Cortisol, µg/dL	5-HIAA, pmol/mL
dACC	$R=0.18; P>.35$	$R=0.16; P>.44$
Right dmPFC	$R=0.01; P>.97$	$R=0.40; P<.05$
Left dmPFC	$R=0.12; P>.54$	$R=0.37; P>.06$
CBV	$R=0.25; P>.19$	$R=0.01; P>.97$

Abbreviations: CBV, cerebellar vermis; dACC, dorsal anterior cingulate cortex; dmPFC, dorsomedial prefrontal cortex; 5-HIAA, 5-hydroxyindoleacetic acid.

SI conversion factor: To convert cortisol to nanomoles per liter, multiply by 27.588.

reared under variable foraging demand during infancy.⁴² These magnetic resonance spectroscopy studies report a decreased *N*-acetyl aspartate-creatine ratio, which suggests neuronal or axonal loss. However, increased choline-creatine and myoinositol-creatine ratios in the ACC have also been found in PTSD.⁴³ Because myoinositol is considered a marker for glial cells, Seedat et al⁴³ suggest that in PTSD alterations in glial cells occur and may precede the decrease in *N*-acetyl aspartate. Even though structural magnetic resonance imaging studies are unable to address specific mechanisms that underlie brain volume increases, these findings suggest that glial cell abnormalities might have an important role in the increased ACC volume reported herein.

Numerous studies in human beings have reported diminished HC volume in patients with mood and anxiety disorders compared with healthy control individuals, and antidepressant treatments increase adult hippocampal neurogenesis.⁸ In the present study, we found no HC differences as a function of early-life rearing history.

However, findings from rodent studies revealed that early-life stress may not have an immediate effect on the

HC but induces changes over time that become manifest only in later phases of development.⁴⁴ Consistent with the delayed effects of stress on HC volume, decreased HC volume has been observed in adults but not in children.^{5,6} Moreover, no changes in the HC were reported in 18-month-old male rhesus monkeys raised in isolation for the first year of life.³⁸ Thus, it is possible that anatomical effects not evident in our 2-year-old cohort may be detected at a later stage in development.

Another brain area that was proposed to be sensitive to the effects of early-life stress exposure was the CBV. Similar to the changes reported in the dmPFC and dACC, an increase in CBV area was seen in PR monkeys compared with MR monkeys. It should be mentioned that, like the HC, CBV has a protracted period of postnatal ontogeny and high density of GRs and may, therefore, be particularly vulnerable to the effects of stress hormones.^{2,22} Imaging studies have described vermal abnormalities in resting blood flow in adults exposed to abuse during childhood,¹⁵ and the role of the CBV in emotional regulation and anxiety is supported by evidence from case studies of various cerebellar disorders.¹² Our findings in combination with the data described support the hypothesis that early-life stress exerts deleterious effects on the development of the CBV, which suggests that the CB in general may have an important role in mood and anxiety disorders.

We found no difference between PR and MR animals in any of the CC measures. In contrast, previous findings showed a reduced CC size in 18-month-old male rhesus monkeys reared in isolation for the first year of life.³⁸ It is possible that CC changes were present 6 months earlier in development but that they were not detectable in 2-year-old rhesus monkeys. Another explanation could be that a longer period of stress exposure is necessary to induce these changes. However, white matter measurements in both studies were restricted to the CC and, thus, provide limited information about changes in connectivity between and within hemispheres. Because cognitive and emotional regulation relies on interactions between and within multiple brain networks rather than activity within single brain regions, further investigations using diffusion tensor imaging and functional connectivity analyses may provide a better understanding of how early-life stress influences the neural circuits of anxiety and stress.

Several maturational processes, including synaptogenesis, synaptic pruning, myelination, and in some regions, neurogenesis, contribute to postnatal brain development. By influencing the levels of neurohormones, neurotransmitters, and neurotrophic factors, chronic stress leads to adverse brain development.¹ Although PR did not affect baseline levels of 5-HIAA and cortisol in juvenile monkeys in our study, it is possible that more subtle changes occurred in specific brain regions. In support of this hypothesis, we found a correlation between 5-HIAA levels and the right dmPFC volume, which suggests a relationship between serotonin levels and dmPFC development. However, because the 5-HIAA level in the CSF reflects the net result of several processes in the brain including serotonin synthesis, release, and reuptake and does not provide information about specific regional changes, future studies will be important to clarify this finding.

There are several limitations to the present study. It is likely that the limited number of animals available led to a reduced statistical power to investigate rearing by sex interactions or correlations with physiologic measures (eg, the correlation between left dmPFC size and 5-HIAA did not reach the level of statistical significance). In addition, we did not correct for multiple comparisons. Therefore, our findings should be considered preliminary, and future studies will be necessary to confirm these results. Future investigations should also include behavioral measures of stress reactivity and anxiety, which would add important information about the functional consequences of the observed structural changes.

In summary, there is evidence that PR, a model of early-life stress exposure in nonhuman primates, has long-term consequences on brain development. Increased volume of the dmPFC, dACC, and CBV were identified in juvenile rhesus monkeys, which suggests that these brain regions may be particularly sensitive to exposure to an adverse environment during infancy. Together, our data suggest that enlarged dmPFC, dACC, and CBV may be a structural phenotype during childhood for increased risk of developing stress-related neuropsychiatric disorders in human beings.

Submitted for Publication: June 4, 2008; final revision received October 27, 2008; accepted December 2, 2008.

Correspondence: Simona Spinelli, PhD; Developmental Cognitive Neurology, Kennedy Krieger Institute, The Johns Hopkins School of Medicine, 707 N Broadway, Baltimore, MD 21205 (spinellis@kennedykrieger.org).

Financial Disclosure: None reported.

Funding/Support: This study was supported by the Intramural Research Programs of the National Institute on Alcohol Abuse and Alcoholism, the National Institute on Drug Abuse, and the National Institute of Child Health and Human Development.

Additional Contributions: Eric Singley, BS, Stephen Lindell, MS, and Melanie Schwandt, PhD, collected and analyzed physiologic data; Eliscia Smith, BA, assisted with magnetic resonance imaging; and Dan Stein, MD, PhD, provided insightful comments on an early draft of the manuscript.

REFERENCES

1. De Bellis MD. The psychobiology of neglect. *Child Maltreat*. 2005;10(2):150-172.
2. Teicher MH, Andersen SL, Polcari A, Anderson CM, Navalta CP, Kim DM. The neurobiological consequences of early stress and childhood maltreatment. *Neurosci Biobehav Rev*. 2003;27(1-2):33-44.
3. Cohen RA, Grieve S, Hoth KF, Paul RH, Sweet L, Tate D, Gunstad J, Stroud L, McCaffery J, Hitsman B, Niaura R, Clark CR, McFarlane A, Bryant R, Gordon E, Williams LM. Early life stress and morphometry of the adult anterior cingulate cortex and caudate nuclei [published correction appears in *Biol Psychiatry*. 2006;60(9):1023]. *Biol Psychiatry*. 2006;59(10):975-982.
4. Teicher MH, Dumont NL, Ito Y, Vaituzis C, Giedd JN, Andersen SL. Childhood neglect is associated with reduced corpus callosum area. *Biol Psychiatry*. 2004;56(2):80-85.
5. De Bellis MD, Keshavan MS, Shifflett H, Iyengar S, Beers SR, Hall J, Moritz G. Brain structures in pediatric maltreatment-related posttraumatic stress disorder: a sociodemographically matched study. *Biol Psychiatry*. 2002;52(11):1066-1078.
6. Woon FL, Hedges DW. Hippocampal and amygdala volumes in children and adults

- with childhood maltreatment-related posttraumatic stress disorder: a meta-analysis. *Hippocampus*. 2008;18(8):729-736. doi:10.1002/hipo.20437.
7. Gluckman PD, Hanson MA. Living with the past: evolution, development, and patterns of disease. *Science*. 2004;305(5691):1733-1736.
 8. Banasr M, Duman RS. Regulation of neurogenesis and gliogenesis by stress and antidepressant treatment. *CNS Neurol Disord Drug Targets*. 2007;6(5):311-320.
 9. Herman JP, Ostrander MM, Mueller NK, Figueiredo H. Limbic system mechanisms of stress regulation: hypothalamo-pituitary-adrenocortical axis. *Prog Neuropsychopharmacol Biol Psychiatry*. 2005;29(8):1201-1213.
 10. Bush G, Luu P, Posner MI. Cognitive and emotional influences in anterior cingulate cortex. *Trends Cogn Sci*. 2000;4(6):215-222.
 11. Liberzon I, Martis B. Neuroimaging studies of emotional responses in PTSD. *Ann N Y Acad Sci*. 2006;1071:87-109.
 12. Schmahmann JD, Weilburg JB, Sherman JC. The neuropsychiatry of the cerebellum: insights from the clinic. *Cerebellum*. 2007;6(3):254-267.
 13. Kitayama N, Quinn S, Bremner JD. Smaller volume of anterior cingulate cortex in abuse-related posttraumatic stress disorder. *J Affect Disord*. 2006;90(2-3):171-174.
 14. Gianaros PJ, Jennings JR, Sheu LK, Greer PJ, Kuller LH, Matthews KA. Prospective reports of chronic life stress predict decreased grey matter volume in the hippocampus. *Neuroimage*. 2007;35(2):795-803.
 15. Anderson CM, Teicher MH, Polcari A, Renshaw PF. Abnormal T2 relaxation time in the cerebellar vermis of adults sexually abused in childhood: potential role of the vermis in stress-enhanced risk for drug abuse. *Psychoneuroendocrinology*. 2002;27(1-2):231-244.
 16. De Bellis MD, Keshavan MS. Sex differences in brain maturation in maltreatment-related pediatric posttraumatic stress disorder. *Neurosci Biobehav Rev*. 2003;27(1-2):103-117.
 17. De Bellis MD, Baum AS, Birmaher B, Keshavan MS, Eccard CH, Boring AM, Jenkins FJ, Ryan ND. AE Bennett Research Award: Developmental traumatology, part I: biological stress systems. *Biol Psychiatry*. 1999;45(10):1259-1270.
 18. Vázquez DM, Eskandari R, Zimmer CA, Levine S, López JF. Brain 5-HT receptor system in the stressed infant rat: implications for vulnerability to substance abuse. *Psychoneuroendocrinology*. 2002;27(1-2):245-272.
 19. Gordon JA, Hen R. The serotonergic system and anxiety. *Neuromolecular Med*. 2004;5(1):27-40.
 20. Lowry CA. Functional subsets of serotonergic neurones: implications for control of the hypothalamic-pituitary-adrenal axis. *J Neuroendocrinol*. 2002;14(11):911-923.
 21. Preuss TM. Evolutionary specialization of primate brain systems. In: Ravosa MJ, Dagosto M, eds. *Primate Origins: Developments in Primatology: Progress and Prospects*. New York, NY: Springer US; 2007:625-675.
 22. Sánchez MM, Young LJ, Plotsky PM, Insel TR. Distribution of corticosteroid receptors in the rhesus brain: relative absence of glucocorticoid receptors in the hippocampal formation. *J Neurosci*. 2000;20(12):4657-4668.
 23. Barr CS, Newman TK, Shannon C, Parker C, Dvoskin RL, Becker ML, Schwandt M, Champoux M, Lesch KP, Goldman D, Suomi SJ, Higley JD. Rearing condition and rh5-HTTLPR interact to influence limbic-hypothalamic-pituitary-adrenal axis response to stress in infant macaques. *Biol Psychiatry*. 2004;55(7):733-738.
 24. Erickson K, Gabry KE, Lindell S, Champoux M, Schulkin J, Gold P, Suomi SJ, Higley JD. Social withdrawal behaviors in nonhuman primates and changes in neuroendocrine and monoamine concentrations during a separation paradigm [published correction appears in *Dev Psychobiol*. 2005;47(2):196-197]. *Dev Psychobiol*. 2005;46(4):331-339.
 25. Fahlke C, Lorenz JG, Long J, Champoux M, Suomi SJ, Higley JD. Rearing experiences and stress-induced plasma cortisol as early risk factors for excessive alcohol consumption in nonhuman primates. *Alcohol Clin Exp Res*. 2000;24(5):644-650.
 26. Higley JD, Hasert MF, Suomi SJ, Linnoila M. Nonhuman primate model of alcohol abuse: effects of early experience, personality, and stress on alcohol consumption. *Proc Natl Acad Sci U S A*. 1991;88(16):7261-7265.
 27. Higley JD, Suomi SJ, Linnoila M. A longitudinal assessment of CSF monoamine metabolite and plasma cortisol concentrations in young rhesus monkeys. *Biol Psychiatry*. 1992;32(2):127-145.
 28. Shannon C, Schwandt ML, Champoux M, Shoaf SE, Suomi SJ, Linnoila M, Higley JD. Maternal absence and stability of individual differences in CSF 5-HIAA concentrations in rhesus monkey infants. *Am J Psychiatry*. 2005;162(9):1658-1664.
 29. Spinelli S, Schwandt ML, Lindell SG, Newman TK, Heilig M, Suomi SJ, Higley JD, Goldman D, Barr CS. Association between the recombinant human serotonin transporter linked promoter region polymorphism and behavior in rhesus macaques during a separation paradigm. *Dev Psychopathol*. 2007;19(4):977-987.
 30. Shannon C, Champoux M, Suomi SJ. Rearing condition and plasma cortisol in rhesus monkey infants. *Am J Primatol*. 1998;46(4):311-321.
 31. Malkova L, Heuer E, Saunders RC. Longitudinal magnetic resonance imaging study of rhesus monkey brain development. *Eur J Neurosci*. 2006;24(11):3204-3212.
 32. Saleem KS, Logothetis NK. *A Combined MRI and Histology Atlas of the Rhesus Monkey Brain in Stereotaxic Coordinates*. London, England: Academic Press; 2007.
 33. Lyons DM, Yang C, Sawyer-Glover AM, Moseley ME, Schatzberg AF. Early life stress and inherited variation in monkey hippocampal volumes. *Arch Gen Psychiatry*. 2001;58(12):1145-1151.
 34. Richert KA, Carrion VG, Karchemskiy A, Reiss AL. Regional differences of the prefrontal cortex in pediatric PTSD: an MRI study. *Depress Anxiety*. 2006;23(1):17-25.
 35. Joelving FC, Billeskov R, Christensen JR, West M, Pakkenger B. Hippocampal neuron and glial cell numbers in Parkinson's disease: a stereological study. *Hippocampus*. 2006;16(10):826-833.
 36. Sheline YI, Black KJ, Lin DY, Christensen GE, Gado MH, Brunsten BS, Vannier MW. Stereological MRI volumetry of the frontal lobe. *Psychiatry Res*. 1996;67(3):203-214.
 37. Phillips KA, Sherwood CC, Lilak AL. Corpus callosum morphology in capuchin monkeys is influenced by sex and handedness. *PLoS ONE*. 2007;2(8):e792. doi: 10.1371/journal.pone.0000792.
 38. Sánchez MM, Hearn EF, Do D, Rilling JK, Herndon JG. Differential rearing affects corpus callosum size and cognitive function of rhesus monkeys. *Brain Res*. 1998;812(1-2):38-49.
 39. Mostofsky SH, Mazzocco MM, Aakalu G, Warsofsky IS, Denckla MB, Reiss AL. Decreased cerebellar posterior vermis size in fragile X syndrome: correlation with neurocognitive performance. *Neurology*. 1998;50(1):121-130.
 40. De Bellis MD, Keshavan MS, Spencer S, Hall J. N-Acetylaspartate concentration in the anterior cingulate of maltreated children and adolescents with PTSD. *Am J Psychiatry*. 2000;157(7):1175-1177.
 41. Ham BJ, Chey J, Yoon SJ, Sung Y, Jeong DU, Ju Kim S, Sim ME, Choi N, Choi IG, Renshaw PF, Lyoo IK. Decreased N-acetyl-aspartate levels in anterior cingulate and hippocampus in subjects with post-traumatic stress disorder: a proton magnetic resonance spectroscopy study. *Eur J Neurosci*. 2007;25(1):324-329.
 42. Mathew SJ, Shungu DC, Mao X, Smith EL, Perera GM, Kegeles LS, Perera T, Lisanby SH, Rosenblum LA, Gorman JM, Coplan JD. A magnetic resonance spectroscopic imaging study of adult nonhuman primates exposed to early-life stressors. *Biol Psychiatry*. 2003;54(7):727-735.
 43. Seedat S, Videen JS, Kennedy CM, Stein MB. Single voxel proton magnetic resonance spectroscopy in women with and without intimate partner violence-related posttraumatic stress disorder. *Psychiatry Res*. 2005;139(3):249-258.
 44. Andersen SL, Teicher MH. Delayed effects of early stress on hippocampal development. *Neuropsychopharmacology*. 2004;29(11):1988-1993.