ORIGINAL ARTICLE

# Regional Brain Volume in Depression and Anxiety Disorders

*Marie-José van Tol, MSc; Nic J. A. van der Wee, MD, PhD; Odile A. van den Heuvel, MD, PhD; Marjan M. A. Nielen, PhD; Liliana R. Demenescu, MSc; André Aleman, PhD; Remco Renken, PhD; Mark A. van Buchem, MD, PhD; Frans G. Zitman, MD, PhD; Dick J. Veltman, MD, PhD*

**Context:** Major depressive disorder (MDD), panic disorder, and social anxiety disorder are among the most prevalent and frequently co-occurring psychiatric disorders in adults and may have, at least in part, a common etiology.

**Objective:** To identify the unique and shared neuroanatomical profile of depression and anxiety, controlling for illness severity, medication use, sex, age of onset, and recurrence.

**Design:** Cross-sectional study.

**Setting:** Netherlands Study of Depression and Anxiety.

**Participants:** Outpatients with MDD (n=68), comorbid MDD and anxiety (n=88), panic disorder, and/or social anxiety disorder without comorbid MDD (n=68) and healthy controls (n=65).

**Main Outcome Measures:** Volumetric magnetic resonance imaging was conducted for voxel-based morphometry analyses. We tested voxelwise for the effects of diagnosis, age at onset, and recurrence on gray matter density. Post hoc, we studied the effects of use of medication, illness severity, and sex.

**Results:** We demonstrated lower gray matter volumes of the rostral anterior cingulate gyrus extending into the dorsal anterior cingulate gyrus in MDD, comorbid MDD and anxiety, and anxiety disorders without comorbid MDD, independent of illness severity, sex, and medication use. Furthermore, we demonstrated reduced right lateral inferior frontal volumes in MDD and reduced left middle/superior temporal volume in anxiety disorders without comorbid MDD. Also, patients with onset of depression before 18 years of age showed lower volumes of the subgenual prefrontal cortex.

**Conclusions:** Our findings indicate that reduced volume of the rostral-dorsal anterior cingulate gyrus is a generic effect in depression and anxiety disorders, independent of illness severity, medication use, and sex. This generic effect supports the notion of a shared etiology and may reflect a common symptom dimension related to altered emotion processing. Specific involvement of the inferior frontal cortex in MDD and lateral temporal cortex in anxiety disorders without comorbid MDD, on the other hand, may reflect disorder-specific symptom clusters. Early onset of depression is associated with a distinct neuroanatomical profile that may represent a vulnerability marker of depressive disorder.

*Arch Gen Psychiatry. 2010;67(10):1002-1011*

Major depressive disorder (MDD), panic disorder (PD), generalized anxiety disorder (GAD), and social anxiety disorder (SAD) are among the most prevalent and most frequently co-occurring psychiatric disorders in adults. Estimations of the comorbidity of depression and anxiety range from 10% to more than 50%.[1-4] Therefore, it has been suggested that depression and anxiety have a similar etiology; they also respond to the same treatment strategies.[3] The comorbid condition of depression and anxiety (CDA), however, may differ from MDD in clinical course and characteristics because it has been associated with worse outcome[1,2,4-6] and more severe psychopathology.[4,6,7] Also, the onset of anxiety often precedes the onset of the first depressive episode.[8] However, in studies investigating the neurobiology of depression and anxiety, comorbidity is rarely explicitly studied.

Major depressive disorder has frequently been associated with stress system dysregulation, as reflected by abnormal hypothalamus-pituitary-adrenal axis function,[9] of which the glucocorticoid cortisol is an end product. An abnormal glucocorticoid response has been associated with volumetric changes in the hippocampus, amygdala, and prefrontal cortex in animal studies.[10] These brain structures are rich in glucocorticoid receptors and are therefore a potential target for the putative neurotoxic action of excess glucocorticoids. However, altered volumes of the hippocampus, amygdala, and prefrontal regions are likely to result from other patho-

**Author Affiliations** are listed at the end of this article.



©2010 American Medical Association. All rights reserved.
Downloaded From: http://archpsyc.jamanetwork.com/ on 04/24/2017

genetic mechanisms as well because abnormal cortisol levels have not been consistently found in MDD.[11]

A number of neuroimaging studies of MDD in humans have shown altered gray matter volumes in structures related to hypothalamus-pituitary-adrenal axis function, emotion perception, and regulation, ie, the hippocampus,[12-17] amygdala,[16,18,19] striatum,[20] medial prefrontal cortex,[12,16,21] and anterior cingulate gyrus (ACC).[22-28] Most studies have reported decreased volumes in these structures,[29] although findings have not been wholly consistent.[13,17,21,25,27,29-35] Importantly, only few studies have explicitly controlled for anxiety comorbidity, although morphometric changes have also been identified in anxiety disorders.[36,37] Whereas volumetric studies in SAD and GAD have been rare, studies in PD have fairly consistently found altered volumes in the amygdala,[38-40] insular cortex,[38,41] dorsomedial prefrontal cortex,[38] and ACC.[38,41,42] In addition, altered brainstem,[42,43] orbitofrontal cortex,[39,44] and superior temporal volumes[39,45] have been implicated in the neuropathology of PD. However, results of these studies may have been similarly confounded by the presence of comorbid depression.[41,42] In summary, volumetric studies appear to indicate specific involvement of the hippocampus in depression, the insular cortex and superior temporal areas in anxiety disorders, and prefrontal and amygdalar areas in both depression and anxiety disorders. However, to our knowledge, the unique and common neuroanatomical profile of depression and anxiety has not been studied yet.

In this cross-sectional study, we investigated the shared and unique neuroanatomical profile of depression and anxiety, controlling for the effects of illness severity, use of selective serotonin reuptake inhibitors (SSRIs), and sex as potential confounders.[46] We also investigated the effects of recurrence of depression and age at onset, reflecting changes associated with prolonged illness duration[47] or increased vulnerability to depression and anxiety.[48,49] Based on previous studies, we hypothesized that patients with MDD with or without comorbid anxiety disorders (PD, SAD, and/or GAD) would show decreased volumes in the hippocampus, amygdala, ACC, and medial prefrontal cortex. In addition, we predicted decreased volumes in the ACC, amygdala, insula, and superior temporal gyrus in patients with an anxiety disorder with or without comorbid MDD.

## METHODS

### PARTICIPANTS

Participants were recruited from the Netherlands Study of Depression and Anxiety (NESDA), a large-scale, multisite, longitudinal, observational cohort study.[50] The design has been described in detail elsewhere.[50] In short, NESDA was designed to be representative of those with depressive and anxiety disorders in different health care settings and stages of developmental history. Therefore, the sample is stratified for setting (community, primary care, and specialized mental health) and set up to include a range of psychopathology.

Of the 2981 NESDA respondents (main sample), participants aged between 18 and 57 years were asked to participate in the NESDA neuroimaging study if they met the *DSM-IV* criteria for a half-year diagnosis of MDD and/or anxiety disorder (PD, SAD, and/or GAD) or no lifetime *DSM-IV* diagnosis (ie, healthy controls). Personality disorders were not screened for and so were not used in the inclusion/exclusion criteria, although persons with known personality disorders (through information from clinics or through self-report) were not included in NESDA. Exclusion criteria for patients were the presence of axis-I disorders other than MDD, PD, SAD, or GAD and any use of psychotropic medication other than stable use of SSRIs or infrequent benzodiazepine use (ie, equivalent to 2 doses of 10 mg of oxazepam 3 times per week or use within 48 hours prior to scanning). Exclusion criteria for NESDA participants were the presence or history of major internal or neurological disorder, dependence on or recent abuse (past year) of alcohol and/or drugs, hypertension, and general magnetic resonance imaging contraindications. Diagnoses according to *DSM-IV* algorithms were established using the structured Composite International Diagnostic Interview, lifetime version 2.1,[51] given by a trained interviewer.

Controls were currently free of, and had never met criteria for, depressive or anxiety disorders or any other axis-I disorder and were not taking any psychotropic drugs.

Overall, 301 native Dutch-speaking participants (233 patients and 68 controls) were included and underwent magnetic resonance imaging in 1 of 3 participating centers: Leiden University Medical Center, Amsterdam Medical Center, and University Medical Center Groningen. The ethical review boards of each center approved this study. All participants provided written informed consent after receiving written information.

### ADDITIONAL PSYCHIATRIC MEASUREMENTS

Severity of depression and anxiety at the day of scanning was assessed using Dutch versions of the Beck Anxiety Inventory,[52] the Montgomery Åsberg Depression Rating Scale,[53] the Inventory of Depressive Symptomology,[54] and the Fear Questionaire.[55]

### IMAGE ACQUISITION

Imaging data were acquired using a Philips 3T magnetic resonance imaging system (Best, The Netherlands) located at the Leiden University Medical Center, Amsterdam Medical Center, and University Medical Center Groningen, equipped with a SENSE-8 (Leiden University Medical Center and University Medical Center Groningen) or SENSE-6 (Amsterdam Medical Center) channel head coil. For each subject, anatomical images were obtained using a sagittal 3-dimensional gradient-echo T1-weighted sequence (repetition time, 9 milliseconds, echo time, 3.5 milliseconds; matrix, $256 \times 256$; voxel size, $1 \times 1 \times 1$ mm; 170 slices; duration, 4.5 minutes).

### STATISTICAL ANALYSIS

Demographic and clinical data were analyzed using SPSS 16.0 (SPSS Inc, Chicago, Illinois). Significance was set at $P < .05$, and post hoc paired tests were Bonferroni corrected for multiple comparisons.

Imaging data were analyzed using optimized voxel-based morphometry (VBM), following diffeomorphic anatomical registration through exponentiated lie algebra (DARTEL[56]) using Statistical Parametric Mapping software (SPM5[57]) implemented in Matlab 7.1.0 (MathWorks, Natick, Massachusetts). Diffeomorphic anatomical registration through exponentiated lie (DARTEL) is a fully deformable method that is effectively unconstrained by number of degrees of freedom. It has proven good registration accuracy and has been recommended in favor of standard SPM normalization or the SPM-unified segmentation approaches for whole-brain and regional analysis without segmenting regions of interest.[58]



©2010 American Medical Association. All rights reserved.
Downloaded From: http://archpsyc.jamanetwork.com/ on 04/24/2017

Preprocessing of VBM-DARTEL included (1) manual reorientation of the images; (2) segmentation of the images into gray matter, white matter, and cerebrospinal fluid using the standard segmentation option implemented in SPM5; (3) applying the DARTEL approach for registration, normalization, and modulation, leaving the images in DARTEL space (in this approach, a DARTEL template is created based on the deformation fields that are produced during the segmentation procedure; next, all individual deformation fields were registered to this template); (4) smoothing of the gray matter and white matter images using an 8-mm full-width at half-maximum Gaussian kernel to increase signal to noise ratio and maximize comparability with published VBM studies of depression and anxiety.[2,18,28,45,59] In the resulting images, each voxel represents an absolute amount of brain volume, equivalent to the brain volume per unit prior to normalization.

Based on previous articles on volumetric differences in MDD and anxiety disorders, we set the following a priori regions of interest: hippocampus, amygdala, medial prefrontal cortex, orbitofrontal cortex, ACC, superior temporal gyrus, and insula. For the regions of interest, we set a threshold of $P<.001$, uncorrected, with an extent threshold of 50 voxels. To further protect against type 1 error, small volume correction was applied for the main comparison (effect of diagnosis) by centering a 16-mm sphere around the peak voxel. The resulting volumes of interest had to meet $P<.05$, familywise error voxel corrected, to be considered significant. For non–regions of interest, a voxel-level threshold of $P<.05$ whole-brain familywise error corrected was set a priori.

Next, data were analyzed in the context of the general linear model.[60] For our main comparison, we performed a $1 \times 4$ factorial analysis with group as a random factor over all subjects. To test for effects of depression severity, anxiety severity (Beck Anxiety Inventory and Fear Questionnaire), SSRI use, and sex, the mean voxel signals of significant clusters were calculated and exported to SPSS. To test for the effects of depression severity, we divided the MDD and CDA into 3 subgroups (remitted, mild, and moderate to severe) based on their Montgomery Åsberg Depression Rating Scale score.[61]

In addition, a whole-brain voxelwise analysis was performed in SPM to test for the effects of early (<18-year) vs late (≥18-year) onset of depressive symptoms in MDD and CDA and for onset of anxiety symptoms in CDA and anxiety disorders without comorbid MDD (ANX) compared with controls. Also, a whole-brain voxelwise analysis was performed to test for effects of recurrent depression vs a single major depressive episode in CDA and MDD.

Age, total gray matter, and center (by means of 2 dummy variables) were entered as covariates in each comparison. White matter images were only used to verify whether volume changes occurred in the same regions as gray matter volume changes. For each SPM comparison, groups were matched for age, sex, scan site, and handedness. A description of the total sample is given in the results section. A description of matching procedure and resulting samples for the additional analyses (exclusion of SSRI users, age of onset, recurrence) can be found in the eAppendix (http://www.archgenpsychiatry.com).

To achieve maximal sensitivity, optimize voxel residual smoothness estimation, and exclude false positives in non–gray matter tissue, voxelwise comparisons were masked using a comparison-specific explicit optimal threshold gray matter mask created using the Masking toolbox.[62] To preserve optimal normalization accuracy, we left the normalized, modulated, and smoothed images in DARTEL space. Therefore, coordinates are not equivalent to Montreal Neurological Institute coordinates. All regions are identified using the detailed brain atlas of Talairach and Tournoux.[63]

## RESULTS

### SAMPLE DESCRIPTIVES

Data from 10 participants were excluded because of poor image quality. In addition, data from 2 controls were excluded because they had Montgomery Åsberg Depression Rating Scale scores greater than 8.[61] We formed 4 groups based on Composite International Diagnostic Interview half-year diagnoses. Our final sample consisted of 289 subjects: 68 patients with MDD (MDD group), 88 with MDD and 1 or more comorbid anxiety disorder (CDA group: MDD and PD and/or SAD and/or GAD), 68 with 1 or more anxiety disorder (PD, SAD, and/or GAD) but no MDD (ANX group), and 65 controls.

**Table 1** lists sample characteristics. Groups were matched for sex, handedness, distribution of participants scanned over sites, and age but not on education; the MDD and CDA groups both had fewer years of education than controls (MDD: $U=1370.5$, $P<.008$; CDA: $U=1594$, $P<.008$). Furthermore, the CDA group included more SSRI users than the MDD and ANX groups. A main effect of group was found on Montgomery Åsberg Depression Rating Scale, Inventory of Depressive Symptomology, Fear Questionnaire, and Beck Anxiety Inventory score. All diagnostic groups showed higher Montgomery Åsberg Depression Rating Scale, Inventory of Depressive Symptomology, Beck Anxiety Inventory, and Fear Questionnaire total scores than controls (all $z>-4.82$; all $P<.008$). In addition, the CDA group reported higher Montgomery Åsberg Depression Rating Scale and Inventory of Depressive Symptomology scores than the MDD and ANX groups and higher Beck Anxiety Inventory scores than the MDD group (all $z>-2.9$; $P<.008$). Between the NESDA baseline interview (time 1) and the magnetic resonance imaging session (time 2), depressive symptom ratings decreased in all diagnostic groups (Inventory of Depressive Symptomology; $t>3.45$; $P<.001$). The MDD group showed an additional decrease in Beck Anxiety Inventory scores ($t_{65}=3.15$; $P=.002$). Post hoc tests showed that currently remitted and mildly depressed subgroups but not moderately or severely depressed subgroups showed lower depressive symptom scores at time 2 than at time 1. The MDD and CDA groups did not differ in age at onset of the first MDD episode, and the CDA and ANX groups did not differ in age of onset of the first anxiety disorder. Within CDA, onset of anxiety generally preceded onset of the first depressive episode ($z=-5.22$; $P<.001$).

### VBM RESULTS

Groups did not differ in total gray and white matter volumes (gray matter $F_{3,284}=0.25$; $P=.34$ and white matter $F_{3,284}=0.25$; $P=.86$). Lower regional gray matter density of the rostral ACC (Brodmann area [BA] 24b/c and BA 32; to identify the subregions of the ACC, we used the definition described by Bush et al[64]) was observed in patients compared with controls, extending into the dorsal ACC (BA 32') (**Figure**, A). Voxel-based comparison of the MDD, CDA, and ANX groups with controls showed that the ros-



©2010 American Medical Association. All rights reserved.
Downloaded From: http://archpsyc.jamanetwork.com/ on 04/24/2017

**Table 1. Clinical Characteristics of the Total Sample (n=289)**

| Characteristic | Mean (SD) | | | | *H* | *F* | *U* | $\chi^2$ | *df* | *P* Value |
|---|---|---|---|---|---|---|---|---|---|---|
| | MDD | CDA[a] | ANX[b] | HC | | | | | | |
| Sample, No. | 68 | 88 | 68 | 65 | | | | | | |
| Sex, No. | | | | | | | | | | |
| Male | 24 | 29 | 18 | 24 | | | | 1.93 | 3 | .59 |
| Female | 44 | 59 | 50 | 41 | | | | | | |
| Scan site, No. | | | | | | | | | | |
| AMC | 18 | 28 | 21 | 27 | | | | | | |
| LUMC | 26 | 35 | 20 | 26 | | | | | | |
| UMCG | 24 | 25 | 27 | 12 | | | | | | |
| Handedness | | | | | | | | | | |
| Left | 6 | 6 | 5 | 5 | | | | 9.7 | 6 | .14 |
| Right | 62 | 82 | 63 | 60 | | | | | | |
| SSRI use | | | | | | | | | | |
| Yes | 18 | 40 | 21 | 0 | | | | 6.88 | 2 | .03 |
| No | 50 | 48 | 47 | 65 | | | | | | |
| Age, y | 37.16 (10.24) | 37.27 (10.64) | 35.96 (9.45) | 40.54 (9.71) | 7.24 | | | | 3 | .07 |
| Education, y | 12.67 (2.91) | 11.62 (3.13) | 13.11 (3.21) | 14.28 (2.86) | 26.13 | | | | 3 | <.001 |
| MADRS, total score[c] | 13.01 (9.18) | 19.94 (9.16) | 10.93 (8.66) | 1.05 (1.86) | 147.73 | | | | 3 | <.001 |
| Range | 0-39 | 0-49 | 0-35 | 0-7 | | | | | | |
| Remitted | 24 | 9 | | | | | | 15.68 | 2 | <.001 |
| Mild | 25 | 35 | | | | | | | | |
| Moderate to severe | 19 | 43 | | | | | | | | |
| IDS T1, total score | 27.68 (9.96) | 33.02 (11.51) | 22.79 (11.91) | 5.14 (3.51) | 150 | | | | 3 | <.001 |
| IDS T2, total score | 19.85 (11.86) | 29.49 (11.16) | 19.26 (10.81) | 3.79 (3.58) | 144.01 | | | | 3 | <.001 |
| Range | 1-57 | 5-57 | 4-49 | 0-17 | | | | | | |
| BAI T1, total score | 11.68 (8.86) | 18.41 (9.10) | 15.22 (9.9) | 1.89 (3.11) | 137.33 | | | | 3 | <.001 |
| BAI T2, total score | 8.95 (8.2) | 18.23 (8.97) | 14.12 (9.60) | 2.19 (2.57) | 125.30 | | | | 3 | <.001 |
| Range | 0-50 | 1-46 | 0-42 | 0-10 | | | | | | |
| FQ, total score | 21.1 (15.39) | 36.35 (19.09) | 37.17 (20.48) | 9.05 (7.71) | 44.41 | | | | 3 | <.001 |
| Range | 0-79 | 6-88 | 3-84 | 0-29 | | | | | | |
| Interval between T1 and T2, d | 71.4 (59.1) | 57.9 (49.5) | 69.9 (33.2) | 63.7 (28.8) | | 1.47 | | | 3 | .22 |
| Age at onset, y | | | | | | | | | | |
| MDD | 25.62 (10.36) | 23.40 (11.38) | | | | | 2505.5 | | | .13 |
| ANX | | 17.67 (10.27) | 15.47 (11.27) | | | | 2156 | | | .20 |
| Recurrence of MDD | | | | | | | | | | |
| Single episode | 29 | 39 | | | | | | | | |
| Recurrent | 39 | 49 | | | | | | | | |
| ANX diagnosis | | | | | | | | | | |
| Lifetime | 21 | 87 | 68 | 0 | | | | | | |
| Past year | 9 | 87 | 68 | 0 | | | | | | |
| MDD diagnosis | | | | | | | | | | |
| Lifetime | 68 | 87 | 37 | 0 | | | | | | |
| Past year | 68 | 87 | 4 | 0 | | | | | | |
| Total volume, mL | | | | | | | | | | |
| GM | 728.7 (67.64) | 729.98 (75.11) | 739.98 (76.95) | 725.48 (76.58) | | .48 | | | 3.285 | .70 |
| WM | 486.12 (63) | 500.81 (64.76) | 493.99 (64.38) | 489.19 (63.66) | | .78 | | | 3.285 | .78 |

Abbreviations: AMC, Amsterdam Medical Center; ANX, anxiety without MDD; BAI, Beck Anxiety Inventory; CDA, comorbid MDD and anxiety; FQ, Fear Questionnaire; GM, gray matter; *H*, Kruskal-Wallis nonparametric multiple sample test; HC, healthy controls; IDS, Inventory of Depressive Symptomatology; LUMC, Leiden University Medical Center; MADRS, Montgomery Åsberg Depression Rating Scale; MDD, major depressive disorder; SSRI, selective serotonin reuptake inhibitor; T1, baseline measurement; T2, magnetic resonance imaging measurement; *U*, Mann-Whitney nonparametric 2-sample test; UMCG, University Medical Center Groningen; WM, white matter.

[a] Seventeen patients had MDD and generalized anxiety disorder (GAD); 17, MDD and panic disorder (PD); 9, MDD, PD, and GAD; 9, MDD and social anxiety disorder (SAD); 15, MDD, SAD, and GAD; 12, MDD, PD, and SAD; 9, MDD, PD, SAD, and GAD.

[b] Twenty patients had PD; 2, PD and GAD; 25, SAD; 3, SAD and GAD; 14, PD and SAD; 4, PD, SAD, and GAD (of which 18 had PD without agoraphobia; 22, PD with agoraphobia).

[c] Remitted depressive scores indicate an MADRS score of 0 to 8; mild, 9 to 18; and moderate to severe, greater than 19.

tral/dorsal ACC reduction was most robust in the CDA group and was borderline significant in the MDD and ANX groups (MDD: x=0, y=32, z=−11; $z$=2.99; $P$=.001; ANX: x=0, y=41, z=1; $z$=3.08; $P$=.001). Gray matter results are listed in **Table 2**. The region surrounding the rostral/dorsal ACC gray matter reductions showed white matter volumetric reductions as well (Table 2).

Furthermore, in the MDD group, gray matter volume reductions in the right inferior frontal gyrus were observed (Figure, B). The ANX group showed less left middle/superior temporal gyrus volume compared with controls (Figure, C). In both regions, white matter reductions were observed as well. The reverse contrasts (MDD, CDA, and ANX groups > controls) did not reveal significant clusters.



©2010 American Medical Association. All rights reserved.
Downloaded From: http://archpsyc.jamanetwork.com/ on 04/24/2017

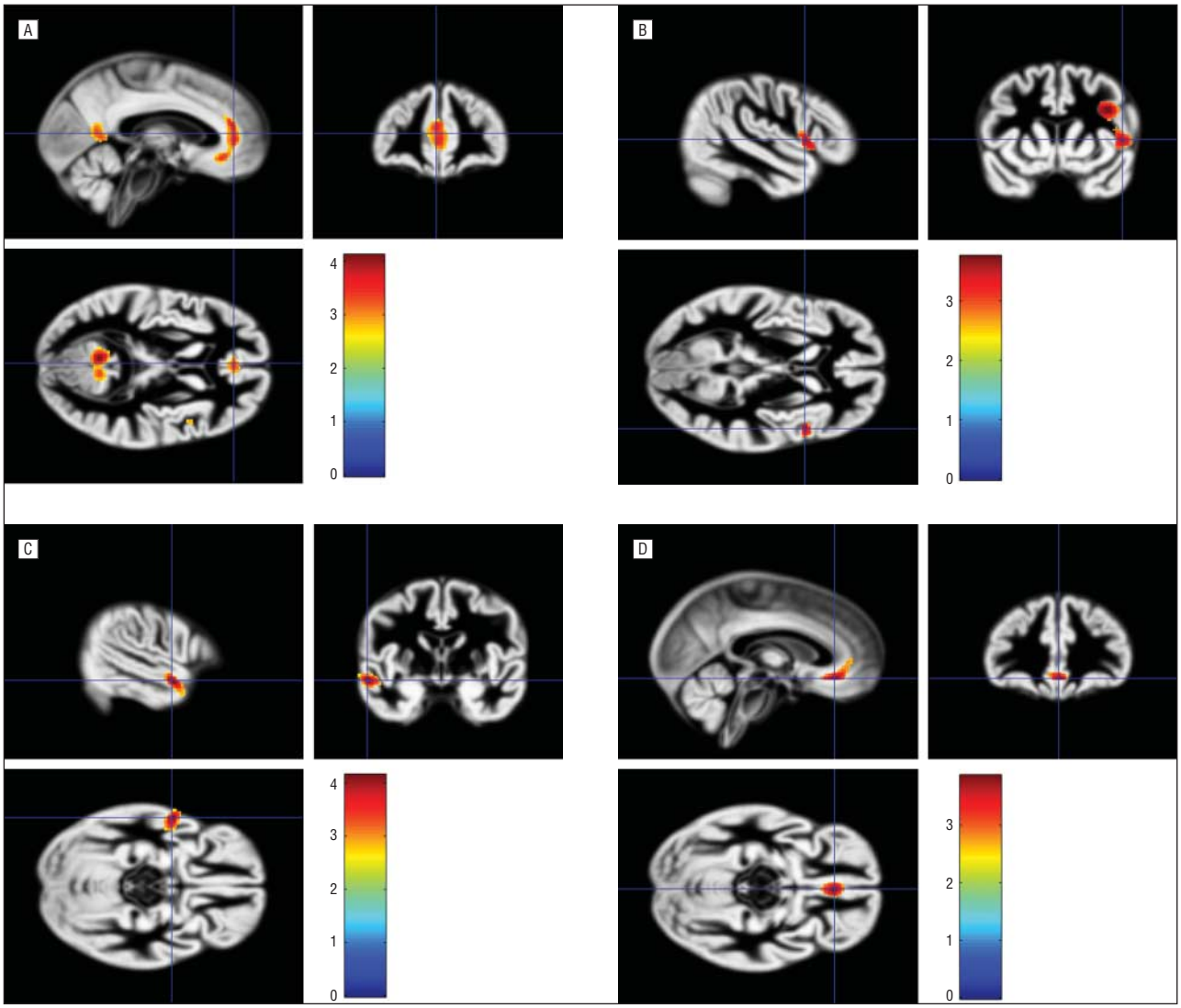


**Figure.** Effects of voxel-based comparisons. A, The main effect of diagnosis showing gray matter reductions in the rostral and dorsal anterior cingulate gyrus in patients compared with controls. B, The lower right inferior frontal gyrus volume is shown in patients with major depressive disorder (MDD) compared with controls. C, The lower right middle/superior temporal gyrus volume is shown in patients with anxiety disorders without comorbid MDD compared with controls. D, Patients with MDD (MDD and comorbid MDD and anxiety) with onset of the first depressive episode before 18 years of age are characterized by lower subgenual orbitofrontal cortex volumes than controls. All effects are displayed at $P<.005$, uncorrected.

## EFFECTS OF ILLNESS SEVERITY, SEX, AND SSRI USE

Analysis with SPSS showed that the dorsal/rostral ACC gray matter reduction occurred in all diagnostic groups relative to controls (all $P<.05$, Bonferroni corrected), whereas the right inferior frontal gyrus and left middle superior temporal gyrus gray matter volume reductions were specific to the MDD and ANX groups, respectively ($P<.05$, Bonferroni corrected).

No effect of depressive state was observed within group on ACC (MDD: $F_{2,66}=0.98$, $P=.38$; CDA: $F_{2,80}=0.09$, $P=.91$) or inferior frontal gyrus volume within MDD ($F_{2,67}=2.14$, $P=.13$). Adding Beck Anxiety Inventory and Fear Questionnaire scores to these models did not change these results (rostral/dorsal ACC MDD: $F_{2,64}=0.51$, $P=.61$; CDA: $F_{2,78}=0.1$, $P=.91$; inferior frontal gyrus $F_{2,64}=2.06$, $P=.14$).

Beck Anxiety Inventory or Fear Questionnaire scores were not predictive of rostral/dorsal ACC volume in patients (Beck Anxiety Inventory: $\beta=0.05$, $P=.22$; Fear Questionnaire: $\beta=-0.06$, $P=.1$), inferior frontal gyrus volumes in the MDD group (Beck Anxiety Inventory: $\beta=-0.02$, $P=.85$; Fear Questionnaire: $\beta=0.14$, $P=.24$), and of middle/superior temporal gyrus volumes in the ANX group (Beck Anxiety Inventory: $\beta=-0.06$, $P=.52$; Fear Questionnaire: $\beta=0.02$, $P=.86$).

No interaction of sex and diagnosis was observed in any region (rostral/dorsal ACC: $F_{3,287}=1.46$, $P=.23$; inferior frontal gyrus: $F_{3,187}=0.56$, $P=.64$; middle/superior temporal gyrus: $F_{2,287}=1.6$, $P=.19$), and omission of SSRI users from analysis did not affect the results.

## AGE AT ONSET

A voxelwise, whole-brain analysis showed that patients with early onset of depression (MDD and CDA) had lower gray matter volumes of the subgenual ACC (BA 25) extending into the medial orbitofrontal gyrus compared with controls (Table 2, Figure, D), and no effect of sex was ob-



©2010 American Medical Association. All rights reserved.
Downloaded From: http://archpsyc.jamanetwork.com/ on 04/24/2017

**Table 2. Voxel-Based Morphometry Results**

| Comparison | R/L | BA | Region | DARTEL Coordinate | | | | z Score |
|---|---|---|---|---|---|---|---|---|
| | | | | k | x | y | z | |
| **Gray Matter Group Comparisons, Including SSRI Users[a]** | | | | | | | | |
| Patients < HC | L | 24b/c/32 | Rostral anterior cingulate gyrus | 152 | 0 | 42 | 4 | 3.54 |
| | L | 32' | Dorsal anterior cingulate gyrus | | –2 | 39 | 16 | 3.52 |
| MDD < HC | R | 44 | Inferior frontal gyrus | 178 | 36 | 11 | 27 | 3.69 |
| | R | 45 | Inferior frontal gyrus | 115 | 47 | 11 | 4 | 3.56 |
| CDA < HC | R | 24b/c/32 | Rostral anterior cingulate gyrus | 83 | 2 | 42 | 6 | 3.50 |
| ANX < HC | L | 21 | Middle/superior temporal gyrus | 181 | –53 | –3 | –12 | 4.07 |
| **White Matter Group Comparisons, Including SSRI Users[b]** | | | | | | | | |
| Patients < HC | R | | Rostral anterior cingulate gyrus | 407 | 9 | 42 | 10 | 4.32[c] |
| | L | | Rostral anterior cingulate gyrus | 11 | –9 | 41 | 10 | 3.17 |
| **Gray Matter Comparisons of Early vs Late Onset of MDD in MDD and CDA[d]** | | | | | | | | |
| EO < HC | R | 25/11 | Subgenual ACC, orbitofrontal gyrus | 127 | 2 | 32 | –11 | 3.77 |

Abbreviations: ANX, anxiety without MDD; BA, Brodmann area; CDA, comorbid MDD and anxiety; DARTEL, diffeomorphic anatomical registration through exponentiated lie; HC, healthy controls; L, left; MDD, major depressive disorder; R, right; SSRI, selective serotonin reuptake inhibitor.

[a] Statistics, coordinates, and cluster sizes of the comparisons between patients (patients: MDD, CDA, and ANX) and HC. Small volume corrected at $P < .05$. Statistical Parametric Mapping smoothness: 11.2, 11.8, and 11.3 mm; 698.7 resels.

[b] Statistics, coordinates, and cluster sizes of the comparisons between patient (patients: MDD, CDA and ANX) and HC. Uncorrected at $P < .001$.

[c] SVC corrected at $P < .05$.

[d] Statistics, coordinates, and cluster sizes of the comparisons between early-onset MDD and CDA vs HC. SVC corrected at $P < .05$. Statistical Parametric Mapping smoothness: 11.2, 11.8, 11.3 mm; 690.5 resels.

served. No differences were observed in the subgenual ACC in persons with late-onset depression vs controls, and no white matter reductions occurred in this region. Also, no effect of early vs late onset of the first anxiety disorder was observed in the ANX and CDA groups.

A voxelwise, whole-brain analysis showed no effect of single vs recurrent depressive episodes in the MDD and CDA groups.

## COMMENT

In this study we investigated the neuroanatomical characteristics of depression and anxiety in a large sample of outpatients with MDD, SAD, PD, and/or GAD. We used a whole-brain, DARTEL-VBM approach, tested explicitly for the effects of comorbidity of depression and anxiety, and controlled for the effects of illness severity, SSRI use, and sex. In addition, we tested voxelwise for the effects of age at onset and recurrence of depression.

We demonstrated lower gray matter volumes of the rostral ACC, extending into the dorsal ACC, in patients with mood and/or anxiety disorders. This rostral ACC volume decrease occurred in MDD, CDA, and ANX, independent of depressive state or anxiety severity, and no effect of SSRI use or sex was observed. Also, white matter reductions occurred in the region bordering the gray matter ACC reduction. Furthermore, we demonstrated reduced right inferior frontal gyrus volumes in MDD and reduced left middle/superior temporal gyrus volume in ANX compared with controls. In addition, depressed subjects (MDD and CDA) with onset of the first depressive episode before 18 years of age showed lower volumes in the subgenual ACC, extending into the medial orbitofrontal cortex. Finally, patients with MDD or CDA with recurrent depression showed no volumetric differences compared with patients with a single episode of depression.

To our knowledge, this is the first study to examine the neuroanatomical (ie, neuroradiological) correlates of both depression and anxiety while explicitly testing for the effects of their co-occurrence. Our findings indicate that reduced ACC volume, in particular regions of the ACC that are part of the rostral-ventral affective subdivision,[64] is a generic effect in depression and anxiety disorders, present independently of depressive state or anxiety severity. This generic ACC volume reduction supports the notion of a shared etiology in depression and anxiety and may reflect a common pathophysiological mechanism related to altered emotion processing. The rostral ACC region has been found to be primarily involved in salience assessments of emotional and motivational information, while the dorsal ACC has been implicated in effortful processing,[64] motivational processes, and regulating negative mood.[65] The ventral part of the ACC (including the rostral ACC) has been associated with executive inhibition,[66] induced sadness,[67,68] and negative emotion processing[69] in both patients with MDD and controls. The volume reduction observed in this study most likely reflects loss of glial cell density and neuronal size[70] and may be the result of hypothalamus-pituitary-adrenal axis dysregulation.[11] The rostral-ventral affective subdivision of the ACC has extensive connections with the orbitofrontal cortex, amygdala, and anterior insula,[71] and therefore is an important hub in emotion perception and regulation. Also, abnormal ACC morphometry has been associated with worse outcome and/or worse treatment response in MDD.[28,72,73]

The results are in concordance with previous imaging studies demonstrating affective ACC abnormalities in depression and anxiety disorders, without consistently controlling for comorbidity.[22,24,26,38,74] Although our CDA group displayed more severe depressive and anxiety-related pathology, the 2 depressive groups were characterized by simi-



©2010 American Medical Association. All rights reserved.
Downloaded From: http://archpsyc.jamanetwork.com/ on 04/24/2017

lar rostral ACC gray matter volume reductions. Also, within groups, no associations between illness severity and ACC volume were observed. The latter finding appears to be at odds with studies reporting a negative correlation between illness severity and ACC volumes.[73,74] For example, Frodl et al,[73] in their sample of inpatients who were receiving medication, demonstrated a moderate correlation of depression severity with right but not left total ACC volume or subregions within the ACC. However, our findings are in agreement with studies that also failed to demonstrate a relation between illness severity and ACC volume,[23,27,28] as was confirmed in a recent meta-analysis.[29] In this study, we further demonstrated rostral ACC volume reductions even in (recently) remitted patients with depression, consistent with findings of abnormal rostral ACC activation following mood induction in remitted patients.[67] Finally, our negative findings regarding SSRI use on ACC volume are in agreement with work of Asami et al.[42] Recent animal studies also indicated that the neurogenesis-promoting effects of SSRIs may only be achieved in youth, not in adulthood or old age.[75,76]

In addition to our rostral ACC findings, we also demonstrated reduced right inferior frontal gyrus gray matter volumes in MDD. This finding is in agreement with earlier VBM results of both decreased inferior frontal gyrus concentration and density[31] in inpatients with MDD in which comorbid anxiety disorders were excluded as well. (Concentration here refers to the proportion of gray matter in each voxel, in which the changes in voxel size have not been accounted for, ie, the voxel value has not been modulated with the Jacobian determinant derived from the spatial normalization. This does not allow for comparison of the absolute voxel value.[77]) Data from the present study indicate that this finding is specific to patients with MDD without comorbid anxiety disorders, independent of depression severity and SSRI use. The right inferior frontal gyrus has been implicated in inhibitory processes relevant to executive performance,[66,68] selective response suppression,[78] and cognitive processes related to negative affect,[79] functions that are likely to be impaired in MDD. Therefore, reduced right inferior frontal gyrus volume may represent a neuroanatomical basis for these abnormalities. The left middle/superior temporal reduction in ANX is also in agreement with previous research[80,81] and has repeatedly been linked to the pathophysiology of PD, presumably reflecting impaired evaluation of interoceptive information[41] and altered threat processing,[82] as has been shown in functional neuroimaging studies.

Depressed subjects (MDD and CDA) with onset of the first depressive episode before 18 years of age showed lower gray matter volumes of the subgenual ACC relative to controls, extending into the medial orbitofrontal cortex, an effect that was not observed in patients with onset of the first depressive episode after 18 years of age. This finding is in line with results of Botteron and colleagues,[22] who reported subgenual ACC volume decreases in adolescent-onset MDD, although no direct comparison with late-onset MDD was made. The subgenual ACC volume reduction may represent an early neurobiological lesion resulting in increased vulnerability to depressed mood, as abnormal subgenual ACC activity during sad mood induction through autobiographical episodes, even after full remission of depression, has been proposed as a trait marker for depression.[67] Also, the subgenual ACC has been implicated in fear extinction and emotion regulation and appears to serve as a regulatory hub between the dorsolateral prefrontal cortex and amygdala, modulating responsiveness in the latter.[83] Disruption of this area may therefore lead to altered emotion processing. Finally, subgenual ACC volume reduction may reflect a genetically determined predisposition to MDD because early-onset depression is associated with increased familial risk of MDD,[84] a hypothesis that has received empirical support.[85] Moreover, Drevets et al[24] described subgenual ACC reductions in a predominantly familial MDD group in adulthood. Although it may be argued that subgenual ACC reduction merely reflects longer disease duration, this suggestion conflicts with the observed subgenual ACC reduction in the adolescent female cohort of Botteron and colleagues.[22]

In this study, we failed to demonstrate hippocampal and amygdalar volume reductions in MDD, SAD, PD, and GAD. Post hoc analyses revealed hippocampal volume reduction only at $z=2.17$ ($P=.02$, uncorrected), far below our a priori threshold, and no amygdala volume changes were observed. One may argue that VBM techniques are less sensitive to detect volumetric alterations in small structures or that nonlinear registration methods are less sensitive to pick up shape-related alterations compared with ROI segmentation approaches. However, the DARTEL-VBM approach we used has shown equal sensitivity to detect hippocampal atrophy in inpatients with depression compared with an automated region of interest segmentation approach.[86] It should be noted that postmortem studies failed to provide clear evidence of apoptosis, massive cell loss, or loss of plasticity in the human hippocampus,[87,88] although reports have been conflicting.[89] Moreover, postmortem studies have mainly included the brains of patients who committed suicide, a subgroup that may not be representative of patients with MDD. Also, most of our depressed patients, although representative of our local outpatient population, were not severely depressed and therefore did not show hippocampal atrophy. However, hippocampal reductions were also absent in our severely depressed subgroups (data not shown). In their meta-analysis, MacKinnon et al[47] showed that hippocampal atrophy is more likely to occur in pediatric or elderly samples with recurrent MDD. Therefore, decreased hippocampal volume may be considered a long-term effect of the disease process, as supported by the longitudinal findings of Frodl et al.[59] Regarding the amygdala, Hamilton et al[18] concluded in their meta-analysis that volume is dependent on medication use in MDD. However, this conclusion is not supported by our data; we did not observe amygdalar atrophy in our main analysis nor in depressed and anxious patients who did not take an SSRI.

In this study, we were unable to identify gray matter reductions outside our a priori regions of interest that survived whole-brain corrections for multiple comparisons. We did, however, observe reductions in the bilateral posterior cingulate cortex (BA 30/23; $z=4.04$; $P<.001$, uncorrected) in addition to the rostral/dorsal ACC reductions described previously in our patient groups. Because



©2010 American Medical Association. All rights reserved.
Downloaded From: http://archpsyc.jamanetwork.com/ on 04/24/2017

most imaging studies to date have focused on frontal and subcortical regions, this posterior region was not included in our a priori regions of interest. However, inclusion of the posterior cingulate cortex as a region of interest in future imaging studies will likely be useful in further unraveling the complex neurodynamics of depression and anxiety. Notably, this region has been included in the default mode network as one of the highest energy-consuming regions and has been associated with larger deactivations during emotional face processing[90] and threat processing in anxious patients.[91] The posterior cingulate cortex has shown negative connectivity with the amygdala and positive connectivity with the dorsal ACC (BA 32),[92] indicating that the posterior cingulate cortex is also involved in regulatory interactions with the amygdala, directly and via the ACC.

This study has a number of strengths. First, we were able to include large samples of patients and controls who were extensively screened and phenotyped according to the NESDA protocol; therefore, we could define subgroups of patients based on clinical comorbidity. Second, only stable SSRI use was allowed in our study, and less than half of our patients were taking antidepressant medication at the time of scanning. Consequently, we were able to control for the effects of SSRI on regional brain volume. Third, we used a whole-brain approach (VBM-DARTEL) that is rater unbiased in its segmentation process. Therefore, we did not restrict our analysis to a limited number of brain structures but were able to detect volumetric changes across the brain and to verify if gray matter changes were accompanied by white matter changes in the same region. Voxel-based methods have been found to show satisfactory correlations with manual segmentation approaches.[41,42]

Several potential limitations should also be noted. First, because the epidemiological NESDA cohort was recruited through general practitioners and outpatient clinics, we may not have been fully able to capture the most severe end of the depressive spectrum. Second, MDD and CDA differed slightly from controls in years of education. However, adding years of education as a covariate did not change the results of the main comparison; if anything, the rostral ACC volume reduction was more robust. Third, assessment of onset and recurrence of depression was based on self-report, which theoretically may have resulted in both underdiagnosis and overdiagnosis of past depression and anxiety. However, this would have biased our results to the null and therefore led to underestimation of the true associations. Fourth, although persons with identified posttraumatic stress disorder where not included in the NESDA sample, subjects were not systematically screened for it. Therefore, we tested (post hoc) for the effect of trauma on ACC volume because data regarding the experience of emotional and physical trauma were available but no effect of self-reported trauma was observed on ACC volume and no interaction with diagnosis was observed (eAppendix 2). Fifth, although similar Philips 3T systems were used at each site in this multicenter study, variability in image acquisition may have occurred owing to minor differences in hardware (receiver coil) and timing of software upgrades. However, no diagnosis × scan site bias occurred. Moreover, reliability of multiscanner VBM has been proven good.[93]

In conclusion, our results suggest a generic involvement of the ventral-rostral ACC in (comorbid) MDD, PD, and SAD, extending into the dorsal ACC that is independent of symptom severity and comorbidity status. Although our results do not directly address pathogenetic mechanisms involved in depression and anxiety, they support the notion of a shared mechanism in these disorders that may reflect impaired emotion processing and regulation, presumably through intricate connections of the ventral ACC with other limbic structures (ie, amygdala, orbitofrontal cortex, and anterior insula) that have been implicated in mood regulation models as well. Psychometric and functional imaging studies focusing on the common and distinct symptom profiles of depression and anxiety may further aid in unraveling the common and distinct phenomenological and neurobiological correlates of these disorders. In addition to this generic ACC effect, we showed disorder-specific involvement of the right inferior frontal gyrus in MDD and of the superior temporal gyrus in PD and/or SAD. Longitudinal studies and prospective studies should clarify whether these volumetric abnormalities are a result of the disease process or represent a vulnerability factor for the development of depression and anxiety in adulthood.

**Submitted for Publication:** December 16, 2009; final revision received March 14, 2010; accepted April 20, 2010.
**Author Affiliations:** Departments of Psychiatry (Drs van der Wee and Zitman and Ms van Tol) and Radiology (Dr van Buchem), Leiden University Medical Center, Leiden; Leiden Institute for Brain and Cognition, Leiden University, Leiden (Drs van der Wee and van Buchem and Ms van Tol); Departments of Psychiatry (Drs van den Heuvel, Nielen, and Veltman) and Anatomy and Neurosciences (Drs van den Heuvel and Veltman), Vrije Universiteit University Medical Center, Amsterdam; Research School of Behavioral and Cognitive Neurosciences Neuroimaging Center, University Medical Center Groningen, University of Groningen, Groningen (Drs Aleman and Renken and Ms Demenescu), the Netherlands.
**Correspondence:** Marie-José van Tol, MSc, Department of Psychiatry and Leiden Institute for Brain and Cognition, Leiden University Medical Center, C-08-Q-87, PO Box 9600, 2300 RC Leiden, the Netherlands (m.j.van_tol@lumc.nl).
**Author Contributions:** Ms van Tol had full access to all of the data in the study and takes responsibility for the integrity of the data and the accuracy of the data analysis.
**Financial Disclosure:** None reported.
**Funding/Support:** The infrastructure for the Netherlands Study of Depression and Anxiety study (http://www.nesda.nl/nl/) was supported by the Geestkracht program of the Netherlands Organisation for Health Research and Development (Health Care Research the Netherlands, Medical Science, grant No. 10-000-1002), Vrije Universiteit University Medical Center, Geestelijke GezondheidsZorg (GGS) in Geest, Arkin, Leiden University Medical Center, GGZ Rivierduinen, University Medical Center Groningen, Lentis, GGZ Friesland, GGZ Drenthe, Scientific Institute for Quality of Healthcare, Netherlands Institute for Health Services Research, and Netherlands Institute of Mental Health and Addiction (Trimbos Institute).



©2010 American Medical Association. All rights reserved.
Downloaded From: http://archpsyc.jamanetwork.com/ on 04/24/2017

**Online-Only Material:** The eAppendices are available at http://www.archgenpsychiatry.com.
**Additional Contributions:** We thank Aart Nederveen, PhD, Wouter Theeuwisse, and Thijs van Osch, PhD, for technical assistance and Brenda Penninx, PhD, for useful comments on the manuscript.

## REFERENCES

1. Gorman JM, Coplan JD. Comorbidity of depression and panic disorder. *J Clin Psychiatry*. 1996;57(suppl 10):34-43.
2. Gorman JM. Comorbid depression and anxiety spectrum disorders. *Depress Anxiety*. 1996-1997;4(4):160-168.
3. Ressler KJ, Mayberg HS. Targeting abnormal neural circuits in mood and anxiety disorders: from the laboratory to the clinic. *Nat Neurosci*. 2007;10(9):1116-1124.
4. Roy-Byrne PP, Stang PA, Wittchen HU, Ustun BE, Walters EE, Kessler RC. Lifetime panic-depression comorbidity in the National Comorbidity Survey: association with symptoms, impairment, course and help-seeking. *Br J Psychiatry*. 2000;176:229-235.
5. Bruce SE, Yonkers KA, Otto MW, Eisen JL, Weisberg RB, Pagano M, Shea MT, Keller MB. Influence of psychiatric comorbidity on recovery and recurrence in generalized anxiety disorder, social phobia, and panic disorder: a 12-year prospective study. *Am J Psychiatry*. 2005;162(6):1179-1187.
6. Rush AJ, Zimmerman M, Wisniewski SR, Fava M, Hollon SD, Warden D, Biggs MM, Shores-Wilson K, Shelton RC, Luther JF, Thomas B, Trivedi MH. Comorbid psychiatric disorders in depressed outpatients: demographic and clinical features. *J Affect Disord*. 2005;87(1):43-55.
7. Kessler RC, Chiu WT, Demler O, Merikangas KR, Walters EE. Prevalence, severity, and comorbidity of 12-month DSM-IV disorders in the National Comorbidity Survey Replication [correction appears in Arch Gen Psychiatry. 2005;62(7):709]. *Arch Gen Psychiatry*. 2005;62(6):617-627.
8. Parker G, Wilhelm K, Mitchell P, Austin MP, Roussos J, Gladstone G. The influence of anxiety as a risk to early onset major depression. *J Affect Disord*. 1999;52(1-3):11-17.
9. Belmaker RH, Agam G. Major depressive disorder. *N Engl J Med*. 2008;358(1):55-68.
10. McEwen BS. Glucocorticoids, depression, and mood disorders: structural remodeling in the brain. *Metabolism*. 2005;54(5)(suppl 1):20-23.
11. Chida Y, Steptoe A. Cortisol awakening response and psychosocial factors: a systematic review and meta-analysis. *Biol Psychol*. 2009;80(3):265-278.
12. Frodl T, Schaub A, Banac S, Charypar M, Jäger M, Kümmler P, Bottlender R, Zetzsche T, Born C, Leinsinger G, Reiser M, Möller HJ, Meisenzahl EM. Reduced hippocampal volume correlates with executive dysfunctioning in major depression. *J Psychiatry Neurosci*. 2006;31(5):316-323.
13. Lange C, Irle E. Enlarged amygdala volume and reduced hippocampal volume in young women with major depression. *Psychol Med*. 2004;34(6):1059-1064.
14. Mervaala E, Föhr J, Könönen M, Valkonen-Korhonen M, Vainio P, Partanen K, Partanen J, Tiihonen J, Viinamäki H, Karjalainen AK, Lehtonen J. Quantitative MRI of the hippocampus and amygdala in severe depression. *Psychol Med*. 2000;30(1):117-125.
15. Sheline YI, Gado MH, Kraemer HC. Untreated depression and hippocampal volume loss. *Am J Psychiatry*. 2003;160(8):1516-1518.
16. Wagner G, Koch K, Schachtzabel C, Reichenbach JR, Sauer H, Schlösser Md RG. Enhanced rostral anterior cingulate cortex activation during cognitive control is related to orbitofrontal volume reduction in unipolar depression. *J Psychiatry Neurosci*. 2008;33(3):199-208.
17. Weniger G, Lange C, Irle E. Abnormal size of the amygdala predicts impaired emotional memory in major depressive disorder. *J Affect Disord*. 2006;94(1-3):219-229.
18. Hamilton JP, Siemer M, Gotlib IH. Amygdala volume in major depressive disorder: a meta-analysis of magnetic resonance imaging studies. *Mol Psychiatry*. 2008;13(11):993-1000.
19. Sheline YI, Gado MH, Price JL. Amygdala core nuclei volumes are decreased in recurrent major depression. *Neuroreport*. 1998;9(9):2023-2028.
20. Hickie IB, Naismith SL, Ward PB, Scott EM, Mitchell PB, Schofield PR, Scimone A, Wilhelm K, Parker G. Serotonin transporter gene status predicts caudate nucleus but not amygdala or hippocampal volumes in older persons with major depression. *J Affect Disord*. 2007;98(1-2):137-142.
21. Bremner JD, Vythilingam M, Vermetten E, Nazeer A, Adil J, Khan S, Staib LH, Charney DS. Reduced volume of orbitofrontal cortex in major depression. *Biol Psychiatry*. 2002;51(4):273-279.
22. Botteron KN, Raichle ME, Drevets WC, Heath AC, Todd RD. Volumetric reduction in left subgenual prefrontal cortex in early onset depression. *Biol Psychiatry*. 2002;51(4):342-344.
23. Caetano SC, Kaur S, Brambilla P, Nicoletti M, Hatch JP, Sassi RB, Mallinger AG, Keshavan MS, Kupfer DJ, Frank E, Soares JC. Smaller cingulate volumes in unipolar depressed patients. *Biol Psychiatry*. 2006;59(8):702-706.
24. Drevets WC, Price JL, Simpson JR Jr, Todd RD, Reich T, Vannier M, Raichle ME. Subgenual prefrontal cortex abnormalities in mood disorders. *Nature*. 1997;386(6627):824-827.
25. Hastings RS, Parsey RV, Oquendo MA, Arango V, Mann JJ. Volumetric analysis of the prefrontal cortex, amygdala, and hippocampus in major depression. *Neuropsychopharmacology*. 2004;29(5):952-959.
26. Tang Y, Wang F, Xie G, Liu J, Li L, Su L, Liu Y, Hu X, He Z, Blumberg HP. Reduced ventral anterior cingulate and amygdala volumes in medication-naïve females with major depressive disorder: a voxel-based morphometric magnetic resonance imaging study. *Psychiatry Res*. 2007;156(1):83-86.
27. Vasic N, Walter H, Höse A, Wolf RC. Gray matter reduction associated with psychopathology and cognitive dysfunction in unipolar depression: a voxel-based morphometry study. *J Affect Disord*. 2008;109(1-2):107-116.
28. Yucel K, McKinnon MC, Chahal R, Taylor VH, Macdonald K, Joffe R, MacQueen GM. Anterior cingulate volumes in never-treated patients with major depressive disorder [published online ahead of print March 26, 2008]. *Neuropsychopharmacology*. 2008;33(13):3157-3163.
29. Koolschijn PC, van Haren NE, Lensvelt-Mulders GJ, Hulshoff Pol HE, Kahn RS. Brain volume abnormalities in major depressive disorder: a meta-analysis of magnetic resonance imaging studies. *Hum Brain Mapp*. 2009;30(11):3719-3735.
30. Caetano SC, Sassi R, Brambilla P, Harenski K, Nicoletti M, Mallinger AG, Frank E, Kupfer DJ, Keshavan MS, Soares JC. MRI study of thalamic volumes in bipolar and unipolar patients and healthy individuals. *Psychiatry Res*. 2001;108(3):161-168.
31. Frodl T, Koutsouleris N, Bottlender R, Born C, Jäger M, Mörgenthaler M, Scheuerecker J, Zill P, Baghai T, Schüle C, Rupprecht R, Bondy B, Reiser M, Möller HJ, Meisenzahl EM. Reduced gray matter brain volumes are associated with variants of the serotonin transporter gene in major depression. *Mol Psychiatry*. 2008;13(12):1093-1101.
32. Frodl T, Meisenzahl EM, Zetzsche T, Born C, Groll C, Jäger M, Leinsinger G, Bottlender R, Hahn K, Möller HJ. Hippocampal changes in patients with a first episode of major depression. *Am J Psychiatry*. 2002;159(7):1112-1118.
33. Frodl T, Meisenzahl EM, Zetzsche T, Born C, Jäger M, Groll C, Bottlender R, Leinsinger G, Möller HJ. Larger amygdala volumes in first depressive episode as compared to recurrent major depression and healthy control subjects. *Biol Psychiatry*. 2003;53(4):338-344.
34. Rusch BD, Abercrombie HC, Oakes TR, Schaefer SM, Davidson RJ. Hippocampal morphometry in depressed patients and control subjects: relations to anxiety symptoms. *Biol Psychiatry*. 2001;50(12):960-964.
35. Vakili K, Pillay SS, Lafer B, Fava M, Renshaw PF, Bonello-Cintron CM, Yurgelun-Todd DA. Hippocampal volume in primary unipolar major depression: a magnetic resonance imaging study. *Biol Psychiatry*. 2000;47(12):1087-1090.
36. Damsa C, Kosel M, Moussally J. Current status of brain imaging in anxiety disorders. *Curr Opin Psychiatry*. 2009;22(1):96-110.
37. Radua J, van den Heuvel OA, Surguladze S, Mataix-Cols D. Meta-analytical comparison of voxel-based morphometry studies in obsessive-compulsive disorder vs other anxiety disorders. *Arch Gen Psychiatry*. 2010;67(7):701-711.
38. Asami T, Yamasue H, Hayano F, Nakamura M, Uehara K, Otsuka T, Roppongi T, Nihashi N, Inoue T, Hirayasu Y. Sexually dimorphic gray matter volume reduction in patients with panic disorder. *Psychiatry Res*. 2009;173(2):128-134.
39. Massana G, Serra-Grabulosa JM, Salgado-Pineda P, Gastó C, Junqué C, Massana J, Mercader JM, Gómez B, Tobeña A, Salamero M. Amygdalar atrophy in panic disorder patients detected by volumetric magnetic resonance imaging. *Neuroimage*. 2003;19(1):80-90.
40. Hayano F, Nakamura M, Asami T, Uehara K, Yoshida T, Roppongi T, Otsuka T, Inoue T, Hirayasu Y. Smaller amygdala is associated with anxiety in patients with panic disorder. *Psychiatry Clin Neurosci*. 2009;63(3):266-276.
41. Uchida RR, Del-Ben CM, Busatto GF, Duran FLS, Guimarães FS, Crippa JAS, Araújo D, Santos AC, Graeff FG. Regional gray matter abnormalities in panic disorder: a voxel-based morphometry study [published online ahead of print April 15, 2008]. *Psychiatry Res*. 2008;163(1):21-29.
42. Asami T, Hayano F, Nakamura M, Yamasue H, Uehara K, Otsuka T, Roppongi T, Nihashi N, Inoue T, Hirayasu Y. Anterior cingulate cortex volume reduction in patients with panic disorder. *Psychiatry Clin Neurosci*. 2008;62(3):322-330.
43. Protopopescu X, Pan H, Tuescher O, Cloitre M, Goldstein M, Engelien A, Yang Y, Gorman J, LeDoux J, Stern E, Silbersweig D. Increased brainstem volume in panic disorder: a voxel-based morphometric study. *Neuroreport*. 2006;17(4):361-363.
44. Mohlman J, Price RB, Eldreth DA, Chazin D, Glover DM, Kates WR. The relation of worry to prefrontal cortex volume in older adults with and without general-



©2010 American Medical Association. All rights reserved.
Downloaded From: http://archpsyc.jamanetwork.com/ on 04/24/2017

ized anxiety disorder [published online ahead of print June 25, 2009]. *Psychiatry Res*. 2009;173(2):121-127.
45. Yoo HK, Kim MJ, Kim SJ, Sung YH, Sim ME, Lee YS, Song SY, Kee BS, Lyoo IK. Putaminal gray matter volume decrease in panic disorder: an optimized voxel-based morphometry study. *Eur J Neurosci*. 2005;22(8):2089-2094.
46. Campbell S, MacQueen G. An update on regional brain volume differences associated with mood disorders. *Curr Opin Psychiatry*. 2006;19(1):25-33.
47. McKinnon MC, Yucel K, Nazarov A, MacQueen GM. A meta-analysis examining clinical predictors of hippocampal volume in patients with major depressive disorder. *J Psychiatry Neurosci*. 2009;34(1):41-54.
48. MacMaster FP, Russell A, Mirza Y, Keshavan MS, Taormina SP, Bhandari R, Boyd C, Lynch M, Rose M, Ivey J, Moore GJ, Rosenberg DR. Pituitary volume in treatment-naïve pediatric major depressive disorder [published online ahead of print July 28, 2006]. *Biol Psychiatry*. 2006;60(8):862-866.
49. MacMillan S, Szeszko PR, Moore GJ, Madden R, Lorch E, Ivey J, Banerjee SP, Rosenberg DR. Increased amygdala: hippocampal volume ratios associated with severity of anxiety in pediatric major depression. *J Child Adolesc Psychopharmacol*. 2003;13(1):65-73.
50. Penninx BW, Beekman AT, Smit JH, Zitman FG, Nolen WA, Spinhoven P, Cuijpers P, De Jong PJ, Van Marwijk HW, Assendelft WJ, Van Der Meer K, Verhaak P, Wensing M, De Graaf R, Hoogendijk WJ, Ormel J, Van Dyck R; NESDA Research Consortium. The Netherlands Study of Depression and Anxiety (NESDA): rationale, objectives and methods. *Int J Methods Psychiatr Res*. 2008;17(3):121-140.
51. Robins LN, Wing J, Wittchen HU, Helzer JE, Babor TF, Burke J, Farmer A, Jablenski A, Pickens R, Regier DA, et al. The Composite International Diagnostic Interview: an epidemiologic instrument suitable for use in conjunction with different diagnostic systems and in different cultures. *Arch Gen Psychiatry*. 1988; 45(12):1069-1077.
52. Beck AT, Epstein N, Brown G, Steer RA. An inventory for measuring clinical anxiety: psychometric properties. *J Consult Clin Psychol*. 1988;56(6):893-897.
53. Montgomery SA, Asberg M. A new depression scale designed to be sensitive to change. *Br J Psychiatry*. 1979;134:382-389.
54. Rush AJ, Giles DE, Schlesser MA, Fulton CL, Weissenburger J, Burns C. The Inventory for Depressive Symptomatology (IDS): preliminary findings. *Psychiatry Res*. 1986;18(1):65-87.
55. Marks IM, Mathews AM. Brief standard self-rating for phobic patients. *Behav Res Ther*. 1979;17(3):263-267.
56. Ashburner J. A fast diffeomorphic image registration algorithm. *Neuroimage*. 2007; 38(1):95-113.
57. SPM5. http://www.fil.ion.ucl.ac.uk/spm/. Accessed July 18, 2010.
58. Yassa MA, Stark CE. A quantitative evaluation of cross-participant registration techniques for MRI studies of the medial temporal lobe. *Neuroimage*. 2009; 44(2):319-327.
59. Frodl TS, Koutsouleris N, Bottlender R, Born C, Jäger M, Scupin I, Reiser M, Möller HJ, Meisenzahl EM. Depression-related variation in brain morphology over 3 years: effects of stress? *Arch Gen Psychiatry*. 2008;65(10):1156-1165.
60. Friston KJ, Holmes AP, Poline JB, Grasby PJ, Williams SC, Frackowiak RS, Turner R. Analysis of fMRI time-series revisited. *Neuroimage*. 1995;2(1):45-53.
61. Müller MJ, Szegedi A, Wetzel H, Benkert O. Moderate and severe depression: gradations for the Montgomery-Asberg Depression Rating Scale. *J Affect Disord*. 2000;60(2):137-140.
62. Ridgway GR, Omar R, Ourselin S, Hill DLG, Warren JD, Fox NC. Issues with threshold masking in voxel-based morphometry of atrophied brains. *Neuroimage*. 2009; 44(1):99-111.
63. Talairach J, Tournoux P. *Co-Planar Stereotaxic Atlas of the Human Brain: 3-Dimensional Proportional System: An Approach to Cerebral Imaging*. New York, NY: Thieme Medical Publishers; 1988.
64. Bush G, Luu P, Posner MI. Cognitive and emotional influences in anterior cingulate cortex. *Trends Cogn Sci*. 2000;4(6):215-222.
65. Mak AK, Wong MMC, Han SH, Lee TMC. Gray matter reduction associated with emotion regulation in female outpatients with major depressive disorder: a voxel-based morphometry study. *Prog Neuropsychopharmacol Biol Psychiatry*. 2009; 33(7):1184-1190.
66. Matthews S, Simmons A, Strigo I, Gianaros P, Yang T, Paulus M. Inhibition-related activity in subgenual cingulate is associated with symptom severity in major depression. *Psychiatry Res*. 2009;172(1):1-6.
67. Liotti M, Mayberg HS, McGinnis S, Brannan SL, Jerabek P. Unmasking disease-specific cerebral blood flow abnormalities: mood challenge in patients with remitted unipolar depression. *Am J Psychiatry*. 2002;159(11):1830-1840.
68. Wang L, LaBar KS, Smoski M, Rosenthal MZ, Dolcos F, Lynch TR, Krishnan RR, McCarthy G. Prefrontal mechanisms for executive control over emotional distraction are altered in major depression. *Psychiatry Res*. 2008;163(2):143-155.
69. Shin LM, Dougherty DD, Orr SP, Pitman RK, Lasko M, Macklin ML, Alpert NM, Fischman AJ, Rauch SL. Activation of anterior paralimbic structures during guilt-related script-driven imagery. *Biol Psychiatry*. 2000;48(1):43-50.
70. Cotter D, Mackay D, Landau S, Kerwin R, Everall I. Reduced glial cell density and neuronal size in the anterior cingulate cortex in major depressive disorder. *Arch Gen Psychiatry*. 2001;58(6):545-553.
71. Devinsky O, Morrell MJ, Vogt BA. Contributions of anterior cingulate cortex to behaviour. *Brain*. 1995;118(Pt 1):279-306.
72. Chen CH, Ridler K, Suckling J, Williams S, Fu CHY, Merlo-Pich E, Bullmore E. Brain imaging correlates of depressive symptom severity and predictors of symptom improvement after antidepressant treatment. *Biol Psychiatry*. 2007;62 (5):407-414.
73. Frodl T, Jäger M, Born C, Ritter S, Kraft E, Zetzsche T, Bottlender R, Leinsinger G, Reiser M, Möller HJ, Meisenzahl E. Anterior cingulate cortex does not differ between patients with major depression and healthy controls, but relatively large anterior cingulate cortex predicts a good clinical course. *Psychiatry Res*. 2008; 163(1):76-83.
74. Yucel K, McKinnon M, Chahal R, Taylor V, Macdonald K, Joffe R, Macqueen G. Increased subgenual prefrontal cortex size in remitted patients with major depressive disorder [published online ahead of print May 21, 2009]. *Psychiatry Res*. 2009;173(1):71-76.
75. Couillard-Despres S, Wuertinger C, Kandasamy M, Caioni M, Stadler K, Aigner R, Bogdahn U, Aigner L. Ageing abolishes the effects of fluoxetine on neurogenesis. *Mol Psychiatry*. 2009;14(9):856-864.
76. Navailles S, Hof PR, Schmauss C. Antidepressant drug-induced stimulation of mouse hippocampal neurogenesis is age-dependent and altered by early life stress. *J Comp Neurol*. 2008;509(4):372-381.
77. Good CD, Johnsrude IS, Ashburner J, Henson RN, Friston KJ, Frackowiak RS. A voxel-based morphometric study of ageing in 465 normal adult human brains. *Neuroimage*. 2001;14(1 pt 1):21-36.
78. Forstmann BU, van den Wildenberg WP, Ridderinkhof KR. Neural mechanisms, temporal dynamics, and individual differences in interference control. *J Cogn Neurosci*. 2008;20(10):1854-1865.
79. Lieberman MD, Jarcho JM, Berman S, Naliboff BD, Suyenobu BY, Mandelkern M, Mayer EA. The neural correlates of placebo effects: a disruption account. *Neuroimage*. 2004;22(1):447-455.
80. Uchida RR, Del-Ben CM, Santos AC, Araújo D, Crippa JA, Guimarães FS, Graeff FG. Decreased left temporal lobe volume of panic patients measured by magnetic resonance imaging. *Braz J Med Biol Res*. 2003;36(7):925-929.
81. Vythilingam M, Anderson ER, Goddard A, Woods SW, Staib LH, Charney DS, Bremner JD. Temporal lobe volume in panic disorder: a quantitative magnetic resonance imaging study. *Psychiatry Res*. 2000;99(2):75-82.
82. Phillips ML, Young AW, Scott SK, Calder AJ, Andrew C, Giampietro V, Williams SC, Bullmore ET, Brammer M, Gray JA. Neural responses to facial and vocal expressions of fear and disgust. *Proc Biol Sci*. 1998;265(1408):1809-1817.
83. Delgado MR, Nearing KI, Ledoux JE, Phelps EA. Neural circuitry underlying the regulation of conditioned fear and its relation to extinction. *Neuron*. 2008;59 (5):829-838.
84. Jaffee SR, Moffitt TE, Caspi A, Fombonne E, Poulton R, Martin J. Differences in early childhood risk factors for juvenile-onset and adult-onset depression. *Arch Gen Psychiatry*. 2002;59(3):215-222.
85. Nolan CL, Moore GJ, Madden R, Farchione T, Bartoi M, Lorch E, Stewart CM, Rosenberg DR. Prefrontal cortical volume in childhood-onset major depression: preliminary findings. *Arch Gen Psychiatry*. 2002;59(2):173-179.
86. Bergouignan L, Chupin M, Czechowska Y, Kinkingnéhun S, Lemogne C, Le Bastard G, Lepage M, Garnero L, Colliot O, Fossati P. Can voxel based morphometry, manual segmentation and automated segmentation equally detect hippocampal volume differences in acute depression? *Neuroimage*. 2009;45(1):29-37.
87. Swaab DF, Bao AM, Lucassen PJ. The stress system in the human brain in depression and neurodegeneration. *Ageing Res Rev*. 2005;4(2):141-194.
88. Campbell S, Macqueen G. The role of the hippocampus in the pathophysiology of major depression. *J Psychiatry Neurosci*. 2004;29(6):417-426.
89. Stockmeier CA, Mahajan GJ, Konick LC, Overholser JC, Jurjus GJ, Meltzer HY, Uylings HB, Friedman L, Rajkowska G. Cellular changes in the postmortem hippocampus in major depression. *Biol Psychiatry*. 2004;56(9):640-650.
90. Gentili C, Ricciardi E, Gobbini MI, Santarelli MF, Haxby JV, Pietrini P, Guazzelli M. Beyond amygdala: Default Mode Network activity differs between patients with social phobia and healthy controls. *Brain Res Bull*. 2009;79(6):409-413.
91. Zhao XH, Wang PJ, Li CB, Hu ZH, Xi Q, Wu WY, Tang XW. Altered default mode network activity in patient with anxiety disorders: an fMRI study. *Eur J Radiol*. 2007;63(3):373-378.
92. Stein JL, Wiedholz LM, Bassett DS, Weinberger DR, Zink CF, Mattay VS, Meyer-Lindenberg A. A validated network of effective amygdala connectivity. *Neuroimage*. 2007;36(3):736-745.
93. Stonnington CM, Tan G, Klöppel S, Chu C, Draganski B, Jack CR Jr, Chen K, Ashburner J, Frackowiak RS. Interpreting scan data acquired from multiple scanners: a study with Alzheimer's disease. *Neuroimage*. 2008;39(3):1180-1185.



©2010 American Medical Association. All rights reserved.
Downloaded From: http://archpsyc.jamanetwork.com/ on 04/24/2017