

# Meta-analysis of Gray Matter Abnormalities in Autism Spectrum Disorder

## *Should Asperger Disorder Be Subsumed Under a Broader Umbrella of Autistic Spectrum Disorder?*

Esther Via, MD; Joaquim Radua, MD; Narcis Cardoner, MD, PhD; Francesca Happé, PhD; David Mataix-Cols, PhD

**Context:** Studies investigating abnormalities of regional gray matter volume in autism spectrum disorder (ASD) have yielded contradictory results. It is unclear whether the current subtyping of ASD into autistic disorder and Asperger disorder is neurobiologically valid.

**Objectives:** To conduct a quantitative meta-analysis of voxel-based morphometry studies exploring gray matter volume abnormalities in ASD, to examine potential neurobiological differences among ASD subtypes, and to create an online database to facilitate replication and further analyses by other researchers.

**Data Sources:** We retrieved studies from PubMed, ScienceDirect, Scopus, and Web of Knowledge databases between June 3, 1999, the date of the first voxel-based morphometry study in ASD, and October 31, 2010. Studies were also retrieved from reference lists and review articles. We contacted authors soliciting additional data.

**Study Selection:** Twenty-four data sets met inclusion criteria, comprising 496 participants with ASD and 471 healthy control individuals.

**Data Extraction:** Peak coordinates of clusters of regional gray matter differences between participants with

ASD and controls, as well as demographic, clinical, and methodologic variables, were extracted from each study or obtained from the authors.

**Data Synthesis:** No differences in overall gray matter volume were found between participants with ASD and healthy controls. Participants with ASD were found to have robust decreases of gray matter volume in the bilateral amygdala-hippocampus complex and the bilateral precuneus. A small increase of gray matter volume in the middle-inferior frontal gyrus was also found. No significant differences in overall or regional gray matter volumes were found between autistic disorder and Asperger disorder. Decreases of gray matter volume in the right precuneus were statistically higher in adults than in adolescents with ASD.

**Conclusions:** These results confirm the crucial involvement of structures linked to social cognition in ASD. The absence of significant differences between ASD subtypes may have important nosologic implications for the DSM-5. The publically available database will be a useful resource for future research.

*Arch Gen Psychiatry.* 2011;68(4):409-418

**Author Affiliations:** Departments of Psychosis Studies and Psychology (Drs Via, Radua, and Mataix-Cols) and Medical Research Council Social, Genetic, and Developmental Psychiatry Centre (Dr Happé), Institute of Psychiatry, King's College London, London, England; Hospital Universitari de Bellvitge–Institut d'Investigació Biomèdica de Bellvitge (IDIBELL), L'Hospitalet de Llobregat (Drs Via and Cardoner) and Benito Menni Complex Assistencial en Salut Mental, Sant Boi de Llobregat (Dr Radua), and Centro de Investigación Biomédica en Red de Salud Mental (CIBERSAM) (Drs Radua and Cardoner), Barcelona, Spain.

**A**UTISM IS A DEVELOPMENTAL disorder characterized by deficits in communication and reciprocal social interaction and a restricted, repetitive, or stereotyped pattern of behaviors, interests, and activities evident by the age of 3 years.<sup>1</sup> Autism spectrum disorder (ASD) is currently used as a broad umbrella term that includes a wide range of clinical presentations, including autistic disorder, Asperger disorder, and pervasive developmental disorder not otherwise specified.<sup>1</sup> A recent study<sup>2</sup> estimates the prevalence of ASD to be 1% in children aged 9 to 10 years, with approximately 60% of those having associated intellectual disability.

The causes of ASD are still to be fully elucidated, although it is known to have

a strong genetic component.<sup>3</sup> It is also thought to result from maturation-related changes in various brain systems. One of the most well-replicated findings in ASD is the increased total head size and brain volume.<sup>4,5</sup> This is mainly due to increased volumes in the frontal lobes and anterior temporal regions, most notably in the preschool years.<sup>6</sup>

Modern neuroimaging methods such as magnetic resonance imaging have provided important insights into the neurobiological basis for ASD.<sup>7</sup> Abnormalities in brain regions known to be important for verbal and nonverbal communication, social interaction, and executive functions, as well as related white matter tracts, have been reported.<sup>7,8</sup> However, the results of these studies have been less consistent than

expected. For example, volume increases and decreases have been reported in the amygdala, a region hypothesized to be critically involved in ASD.<sup>7,9-11</sup> These inconsistencies might exist partially because of the clinical and etiologic heterogeneity of the disorder,<sup>12</sup> as well as methodologic aspects of the studies, such as the use of manual or semiautomated region of interest (ROI) methods, which focus on a priori selected regions, thus precluding the exploration of other brain regions potentially implicated in ASD.

Fully automated, whole-brain voxel-based morphometry (VBM) methods,<sup>13,14</sup> which overcome some of the limitations of the ROI approach, provide a potentially powerful and unbiased tool to study the neural substrates of ASD. Since the advent of VBM methods, an increasing number of studies have applied them to the study of ASD, but their results have also been relatively inconsistent. These studies are often limited by relatively small sample sizes, resulting in insufficient statistical power. Voxel-based meta-analytical methods are ideal to quantify the reproducibility of neuroimaging findings and to generate insights difficult to observe in isolated studies.<sup>15,16</sup>

In this study, we searched all known published and unpublished VBM studies of gray matter in ASD and applied novel voxel-based meta-analytical methods to establish the most consistently reported abnormalities in this disorder, without the constraints of a priori hypotheses. We also examined potential differences in gray matter volume between the main subtypes of ASD, namely, autistic disorder and Asperger disorder, which remains an important nosologic issue in the DSM-5.<sup>17</sup> Specifically, draft criteria for the DSM-5 have proposed merging Asperger disorder into ASD because of the lack of solid empirical data distinguishing Asperger and high-functioning autism subgroups with regard to cause, course, and neurocognitive profile.<sup>18-20</sup> Finally, to facilitate replication and further analyses by research groups internationally, we have also developed a readily accessible online database containing all the data and methodologic details from every study included in this meta-analysis.

## METHODS

### SEARCH AND INCLUSION OF STUDIES

A literature search of articles, posters, and abstracts published from June 3, 1999, the date of the first VBM study in ASD,<sup>21</sup> through October 31, 2010, was conducted using the PubMed, ScienceDirect, Scopus, and Web of Knowledge databases. The search keywords were *autism or Asperger plus morphometry, voxel based, or voxelwise*. In addition, manual searches were conducted among the reference sections of the retrieved studies and several review studies. Any work comparing individuals with autistic disorder or Asperger disorder with healthy control individuals by means of whole-brain VBM was considered for inclusion in the meta-analysis. Studies containing duplicated data sets (ie, analyzing at least half of the sample in different works) and studies with fewer than 9 participants in the ASD group were excluded.

### DATA EXTRACTION

Data from included studies were extracted by 2 of us (E.V. and J.R.) and then compared to minimize interpretation and data

entry errors. In all but 2 studies, the corresponding authors were contacted via e-mail to obtain data not included in the original works. Meta-analysis of Observational Studies in Epidemiology guidelines<sup>22</sup> were followed in the study.

### GLOBAL DIFFERENCES IN GRAY MATTER VOLUME

Meta-analytical differences in global gray matter volumes between participants with ASD and controls were assessed using random-effects models with the Globals procedure in Signed Differential Mapping (SDM),<sup>23</sup> which uses restricted maximum-likelihood estimation, a fitting method that has been recommended instead of previous ones for its optimal balance between lack of bias and efficiency.<sup>24</sup>

### REGIONAL DIFFERENCES IN GRAY MATTER VOLUME

Regional differences in gray matter volume between participants with ASD and controls were analyzed using SDM,<sup>23</sup> a novel voxel-based meta-analytic approach that is based on and improves on other existing methods.<sup>25,26</sup> The method has been described in detail elsewhere<sup>27,28</sup> and is briefly summarized herein.

First, SDM applies a strict selection of the reported peak coordinates of gray matter differences by only including those that appear statistically significant at the whole-brain level, preferably corrected for multiple comparisons. This practice is intended to avoid biases toward liberally thresholded brain regions because it is not uncommon in neuroimaging studies that the statistical threshold for some ROIs is more liberal than for the rest of the brain. Second, a map of the differences in gray matter is separately recreated for each study. This includes limiting voxel values to a maximum to avoid biases toward studies reporting various coordinates in close proximity and reconstructing increases and decreases of gray matter in the same map. Finally, the mean map is obtained by voxel-based calculation of the mean of the study maps, weighted by the squared root of the sample size of each study so that studies with large sample sizes contribute proportionally more to the final map. The statistical significance of each voxel is assessed by standard randomization tests.<sup>27</sup>

The main analysis reported herein was complemented by several additional analyses to assess the robustness and replicability of the findings,<sup>27</sup> namely, jackknife sensitivity analyses and descriptive analyses of quartiles. The jackknife sensitivity analysis consists of iteratively repeating the same analyses excluding 1 data set at a time to establish whether the results remain significant. The analyses of quartiles describe the proportion of studies reporting changes in a particular region (ie, 25%, 50%, or 75%), regardless of *P* values.<sup>27,28</sup>

### EFFECTS OF ASD SUBTYPE AND AGE ON GLOBAL AND REGIONAL GRAY MATTER VOLUMES

Using recently developed methods,<sup>28</sup> we next regressed the global and regional gray matter differences between participants with ASD and controls from each study by ASD subtype (autistic vs Asperger disorder) and age (adult vs adolescent samples). Considering that some studies included participants with autistic disorder and participants with Asperger disorder, the diagnosis factor was coded as the percentage of participants with Asperger disorder.

The analysis of covariance (ANCOVA) of global gray matter differences returned a *Q* statistic (similar to an *F* statistic) that summarized the effects of diagnosis and age, a *z* statistic

for the difference between participants with autistic disorder and participants with Asperger disorder, and a  $z$  statistic for the difference between adolescent and adult participants with ASD. Similarly, the ANCOVA of regional gray matter differences returned a map of the regional  $Q$  statistic, a map of the gray matter volume differences between participants with autistic disorder and participants with Asperger disorder, and a separate map of the differences between adolescent and adult participants with ASD. To minimize spurious findings, this ANCOVA was limited to the brain regions with significant differences between patients and controls in the main analysis.

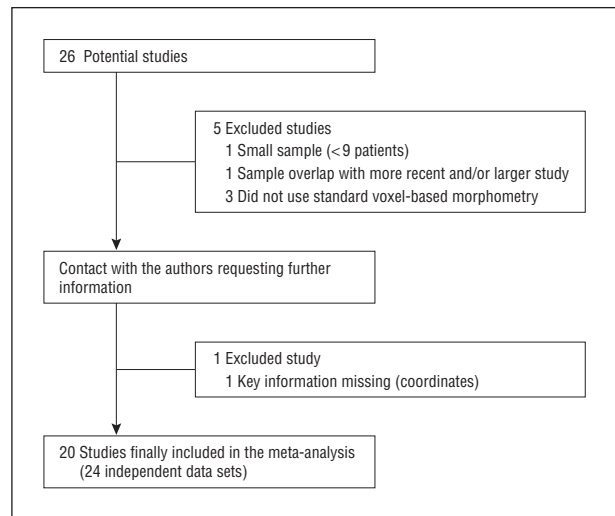
## RESULTS

### INCLUDED STUDIES AND SAMPLE CHARACTERISTICS

As shown in **Figure 1**, the search retrieved 26 potentially suitable studies. Of those studies, 1 was excluded because it included fewer than 9 participants with ASD,<sup>29</sup> 1 was excluded because of a duplicated data set,<sup>30</sup> and 3 additional studies were excluded because of incompatible methods (ie, bilateral VBM<sup>31,32</sup>—a new statistical VBM approach to identify only bilateral abnormalities in the autistic brain—and single-case analysis<sup>33</sup>). One further study<sup>34</sup> had to be excluded because it was missing information that was key for our meta-analysis (ie, peak coordinates from whole-brain analysis).

After contacting the authors, no methodologic ambiguities remained regarding the design or results of the remaining 20 studies. Therefore, 20 studies could be included in this meta-analysis, comprising 24 independent data sets (that is, comparisons between groups of participants with ASD and healthy controls). Note that some studies included more than 1 sample of participants (or data sets). Nineteen of these studies were published or accepted for publication, and 1 was an unpublished analysis within an abstract. Ten studies included adult ASD samples<sup>21,35-43</sup> and another 10 studies included adolescent ASD samples.<sup>44-53</sup>

The included studies comprised 496 participants with ASD and 471 healthy controls. Among them, 452 were adults (228 controls: mean [SD] age, 27 [9.7] years; 224 ASD patients: mean [SD] age, 28 [10.1] years, 46.4% with autistic disorder, 52.2% with Asperger disorder, 1.3% unspecified) and 515 were adolescents (243 controls: mean [SD] age, 12 [4.3] years; 272 ASD patients: mean [SD] age, 13 [4.6] years, 69.5% with autistic disorder, 19.1% with Asperger disorder, 11.4% unspecified). The ASD diagnosis was established by means of the Autism Diagnostic Interview-Revised<sup>34</sup> in 17 studies and using DSM-IV criteria in the remaining 3 studies.<sup>21,38,45</sup> As indicated in **Table 1**, no relevant differences between participants with ASD and healthy controls were found in terms of sex, age, handedness, or IQ, reflecting the group matching used in the original studies. With the exception of 1 study,<sup>44</sup> the mean IQ of the participants was greater than 70. The IQ was not reported in 3 studies.<sup>21,45,50</sup> Only 1 study<sup>35</sup> included a completely female sample. Most of the studies (75.0%) specified that neurologic or psychiatric conditions were excluded, and only 12 participants with ASD (2.4%) were known to have comorbid conditions in 2 studies.<sup>45,46</sup> Medi-



**Figure 1.** Inclusion of studies in the meta-analysis.

cation use was not often reported; across all included studies, 24 participants with ASD (4.8%) were said to be taking medication at the time of scan. More clinical and methodologic details of each of the studies can be found at <http://www.sdmproject.com/database/>.

### GLOBAL DIFFERENCES IN GRAY MATTER VOLUME

Global gray matter volume could be retrieved from 12 studies.\* No statistically significant differences in global gray matter volumes were found between participants with ASD ( $n=312$ ) and healthy controls ( $n=334$ ) (unbiased Hedges<sup>54,55</sup>  $d=0.006$ ,  $z=0.065$ ,  $P=.95$ ).

### REGIONAL DIFFERENCES IN GRAY MATTER VOLUME

Data for this analysis were obtained from all 24 data sets. As indicated in **Table 2** and **Figure 2**, participants with ASD were characterized by a significant reduction of gray matter volume in the amygdala-hippocampus complex (particularly on the right side), extending to the right claustrum. Significant reductions in gray matter volume were also found in the bilateral medial parietal cortex (precuneus, Brodmann area [BA] 7), particularly on the right side, which extended to adjacent right-sided areas: superior parietal lobule, subgyral parietal lobe, and postcentral gyrus (BA7, BA40, and BA5). Finally, a small increase in gray matter volume was found in the left middle frontal gyrus extending to the inferior frontal gyrus (BA46 and BA10).

Replicability of these results was further assessed by a jackknife sensitivity analysis consisting of the systematic exclusion of 1 study at a time. As indicated in **Table 3**, the main results were highly replicable, especially for the right amygdala-hippocampus complex, which remained significant in all the combinations of data sets. The left amygdala-hippocampus complex remained significant in all but 2 combinations of studies.

\*References 35-38, 40, 43, 46, 47, 49, 51-53.

**Table 1. Detailed Demographic and Clinical Characteristics of the 24 Data Sets Included in the Meta-analysis**

Source	Individuals With Autism						Healthy Control Individuals			
	No.	Age, Mean (SD), y	Males, %	Total IQ, Mean (SD)	Asperger Disorder, %	Autistic Disorder, %	No.	Age, Mean (SD), y	Males, %	Total IQ, Mean (SD)
Pediatric/adolescent samples										
Boddaert et al, <sup>44</sup> 2004	21	9.30 (2.20)	76	41.90 (21.30)	0	100	12	10.80 (2.70)	58	NA
Bonilha et al, <sup>45</sup> 2008	12	12.40 (4.00)	100	NA	0	100	16	13.20 (5.00)	100	NA
Brieber et al, <sup>46</sup> 2007	15	14.20 (1.90)	100	106.80 (21.40)	87	13	15	13.30 (1.80)	100	107.70 (12.70)
Freitag et al, <sup>47</sup> 2008	15	17.60 (3.60)	87	101.20 (21.20)	NA	NA	15	18.60 (1.20)	87	112.10 (18.00)
Hardan et al, <sup>48</sup> 2003	...	...	...	...	...	...	12	16.50 (8.20)	NA	109.50 (15.80)
Asperger disorder sample	12	16.40 (8.00)	NA	108.80 (13.50)	100	0	...	...	...	...
Autistic disorder sample	12	16.40 (8.20)	NA	113.40 (12.90)	0	100	...	...	...	...
Ke et al, <sup>49</sup> 2008	17	8.88 (1.96)	82	108.76 (19.07)	0	100	15	9.73 (1.67)	80	109.80 (19.22)
Kwon et al, <sup>50</sup> 2004	...	...	...	...	...	...	13	13.60 (3.10)	100	NA
Asperger disorder sample	11	13.50 (2.40)	100	NA	100	0	...	...	...	...
Autistic disorder sample	9	14.00 (3.30)	100	NA	0	100	...	...	...	...
Langen et al, <sup>51</sup> 2009	99	12.89 (4.45)	92	107.59 (13.56)	0	100	89	12.36 (4.79)	92	109.99 (12.81)
McAlonan et al, <sup>52</sup> 2008	...	...	...	...	...	...	55	10.70 (2.74)	85	>70
Asperger disorder sample	16	11.70 (2.78)	81	>70	100	0	...	...	...	...
Autistic disorder sample	17	11.40 (2.48)	82	>70	0	100	...	...	...	...
Waiter et al, <sup>53</sup> 2004	16	15.40 (2.24)	100	100.40 (21.70)	NA	NA	16	15.50 (1.60)	100	99.70 (18.30)
Adult samples										
Abell et al, <sup>21</sup> 1999	15	28.75 (6.60)	80	NA	100	0	15	25.33 (3.10)	80	NA
Craig et al, <sup>35</sup> 2007	14	37.90 (11.40)	0	103.40 (17.00)	71	29	19	35.00 (14.00)	0	111.20 (14.50)
Ecker et al, <sup>36</sup> 2010	22	27.00 (7.00)	100	104.00 (15.00)	59 <sup>a</sup>	27 <sup>a</sup>	22	28.00 (7.00)	100	111.00 (10.00)
Hyde et al, <sup>37</sup> 2010	15	22.70 (6.40)	100	100.40 (12.60)	0	100	15	19.20 (5.00)	100	106.60 (12.10)
Kosaka et al, <sup>38</sup> 2010	32	23.80 (4.20)	100	101.60 (15.60)	47	53	40	22.50 (4.30)	100	109.70 (7.90)
McAlonan et al, <sup>39</sup> 2002	17	32.00 (10.00)	NA	96.00 (15.00)	100	0	24	33.00 (7.00)	92	114.00 (14.00)
Rojas et al, <sup>40</sup> 2006	24	20.79 (10.58)	100	94.75 (20.64)	0	100	23	21.41 (10.91)	100	118.74 (11.18)
Schmitz et al, <sup>41</sup> 2006	10	38.00 (9.00)	100	105.00 (14.00)	80	20	12	39.00 (6.00)	100	106.00 (13.00)
Toal et al, <sup>42</sup> 2010	...	...	...	...	...	...	33	32.00 (9.00)	90.91	105.00 (12.00)
Asperger disorder sample	39	32.00 (12.00)	89.74	106.00 (15.00)	100	0	...	...	...	...
Autistic disorder sample	26	30.00 (8.00)	80.77	84.00 (23.00)	0	100	...	...	...	...
Wilson et al, <sup>43</sup> 2009	10	30.10 (9.18)	80	91.50 (19.67)	0	100	10	29.40 (7.91)	70	127.20 (9.00)
<b>Total</b>	<b>496</b>	<b>20.07 (10.86)</b>	<b>89</b>	<b>99.65 (21.61)</b>	<b>31</b>	<b>53</b>	<b>471</b>	<b>19.60 (10.55)</b>	<b>88</b>	<b>110.17 (13.42)</b>

Abbreviations: Ellipses, not applicable; NA, data not available.

<sup>a</sup>Missing information for 3 participants.

**Table 2. Regions Showing Statistically Significant Differences in Gray Matter Volume Between Participants With ASD and Healthy Control Individuals<sup>a</sup>**

Variable	Talairach Coordinates	SDM Value	No. of Voxels	Cluster Breakdown (No. of Voxels)
Gray matter volume decreases				
Right amygdala-hippocampus complex	28, -4, -20	-0.125	112	Right amygdala (77 voxels) Right hippocampus (13 voxels) Right claustrum (13 voxels)
Right medial parietal cortex	24, -46, 56	-0.107	97	Right superior parietal lobule BA7 and BA5 (32 voxels) Right subgyral parietal lobe BA40 and BA7 (26 voxels) Right medial parietal cortex BA7 (19 voxels) Right postcentral gyrus BA5 (14 voxels)
Left medial parietal cortex	-2, -58, 48	-0.106	66	Left medial parietal cortex BA7 (54 voxels) Right medial parietal cortex BA7 (12 voxels)
Left amygdala-hippocampus complex	-24, -22, -22	-0.103	18	Left parahippocampal gyrus BA35 (13 voxels)
Gray matter volume increase				
Left middle frontal gyrus	-36, 38, 12	0.116	15	Left middle frontal gyrus BA10 and BA46 (11 voxels) Left inferior frontal gyrus BA46 (4 voxels)

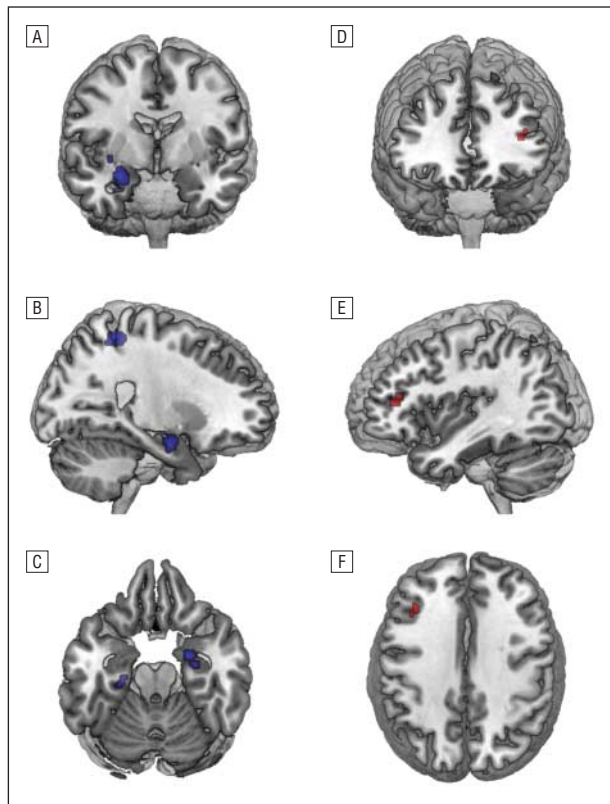
Abbreviations: ASD, autism spectrum disorder; BA, Brodmann area; SDM, Signed Differential Mapping.

<sup>a</sup> $P < .001$  for all.

The bilateral medial parietal cortex remained significant in all but 1 combination of data sets. The left middle-inferior frontal gyrus was somewhat less robust, failing to reach significance in 4 combinations of studies. The analyses of quartiles showed that at least 25% of

the studies had found a decrease of gray matter in the right amygdala-hippocampus complex and the bilateral precuneus but not the other 2 regions.

Because there was a partial sample overlap between 2 sets of studies (Rojas et al<sup>40</sup> with Wilson et al<sup>43</sup> and



**Figure 2.** Regions of gray matter volume difference between participants with autism spectrum disorder (ASD) and healthy control individuals. A-C, Gray matter volume reductions in ASD (3-dimensional view). A, Right amygdala (coronal and radiologic view); B, right amygdala, right precuneus (sagittal view); and C, bilateral amygdala-hippocampus complex (transversal and neurologic view). D-F, Gray matter volume increase in the left middle-inferior frontal gyrus in ASD (3-dimensional view). D, Coronal and radiologic view; E, sagittal view; and F, transversal and neurologic view.

McAlonan et al<sup>39</sup> with Toal et al<sup>42</sup>), we next repeated the analyses excluding the studies with the smallest samples.<sup>39,43</sup> The results remained unchanged when we excluded both of these studies.

Finally, we repeated the analyses excluding the 3 studies that did not use a criterion standard diagnostic tool, such as the Autism Diagnostic Interview-Revised.<sup>21,38,45</sup> The exclusion of these 3 studies did not modify the results.

#### EFFECTS OF ASD SUBTYPE AND AGE ON GLOBAL AND REGIONAL GRAY MATTER VOLUMES

Eleven data sets (in 10 studies)<sup>35-38,40,43,46,49,51,52</sup> reported global gray matter volumes and the proportion of participants with autistic disorder and those with Asperger disorder in their samples. These studies were included in the ANCOVA of global gray matter differences comparing diagnostic and age subgroups (n=303 healthy controls, 211 autistic disorder patients, and 67 Asperger disorder patients). The results revealed no statistically significant differences in global gray matter volumes between autistic disorder and Asperger disorder or between adult and adolescent ASD samples (Q=0.183, df=2, P=.91; autistic disorder vs Asperger disorder: d=0.009,

SD=0.29, z=0.03, P=.98; adults vs adolescents: d=-0.010, SD=0.22, z=-0.42, P=.67).

All but 2 studies<sup>47,53</sup> reported the proportion of participants with autistic disorder and those with Asperger disorder within their samples and could be included in the ANCOVA of regional gray matter differences (n=440 healthy controls, 293 patients with autistic disorder, and 169 patients with Asperger disorder). The Q map of regional gray matter differences (effects of diagnosis and age) found a significant difference in the right precuneus (peak [Talairach]: 22, -48, 54, SDM=1, P<.001). This was driven by a significantly greater decrease of gray matter volume in adults than in adolescents (peak [Talairach]: 22, -48, 54, SDM=-0.346, P<.001) (**Figure 3**). Crucially, no statistically significant differences were found in regional gray matter volumes between the autistic disorder and Asperger disorder groups (smallest P≥.001) (Figure 3). An additional analysis that included only diagnostically pure samples (ie, composed of only participants with autistic disorder or only those with Asperger disorder) resulted in a nonsignificant Q map (smallest P≥.001), indicating no statistically significant effects of diagnosis or age.

#### COMMENT

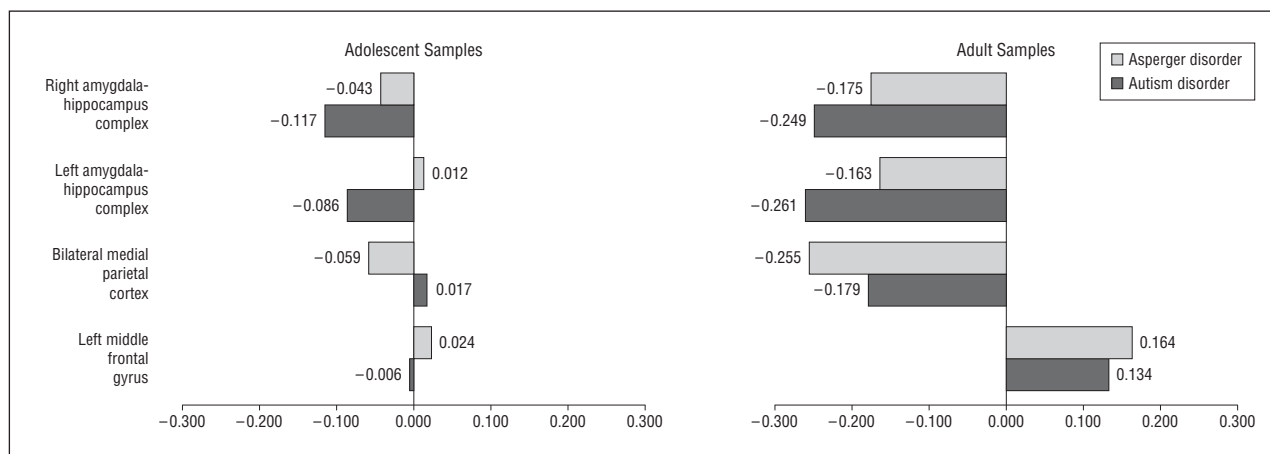
To our knowledge, ours is the first meta-analysis of voxel-based gray matter abnormalities in participants with ASD. It complements other existing meta-analyses of studies using hand-tracing methods.<sup>56</sup> The study is timely, given that findings from previous studies have been relatively inconsistent and that only recently have enough studies been accumulated to allow such meta-analysis. We took advantage of recent developments in meta-analytical methods to compare subtypes of ASD—a subject that is relevant to the current DSM-5 deliberations—and developed a publically available database, which we hope will facilitate replication and further analyses from researchers in the field. The database is readily accessible at <http://www.sdmproject.com/database/>.

#### SUMMARY OF THE MAIN FINDINGS

Twenty-four independent data sets comprising formal comparisons between participants with ASD and healthy controls met inclusion criteria. Although no significant differences in global gray matter volumes existed, participants with ASD showed robust reductions of gray matter volume in the amygdala-hippocampus complex (particularly on the right side) and medial parietal regions (precuneus, BA7). A small increase in gray matter volume was found in the left middle and inferior frontal gyri (BA46 and BA10). Overall, these findings were robust because they consistently emerged using multiple statistical approaches and various sensitivity and subgroup analyses. No significant differences in regional gray matter volume were found between participants with a diagnosis of autistic disorder vs Asperger disorder. Decreases of gray matter volume in the right precuneus were sta-

**Table 3. Jackknife Sensitivity and Quartiles Analyses**

Source	Decreased Gray Matter Volume			Increased Gray Matter Volume in Left Middle Frontal Gyrus
	Right Amygdala-Hippocampus Complex	Left Amygdala-Parahippocampus Complex	Bilateral Medial Parietal Cortex	
Jackknife sensitivity analysis, discarded study				
Abell et al, <sup>21</sup> 1999	Yes	Yes	Yes	Yes
Boddaert et al, <sup>44</sup> 2004	Yes	Yes	Yes	Yes
Bonilha et al, <sup>45</sup> 2008	Yes	Yes	Yes	Yes
Brieber et al, <sup>46</sup> 2007	Yes	No	Yes	Yes
Craig et al, <sup>35</sup> 2007	Yes	Yes	Yes	Yes
Ecker et al, <sup>36</sup> 2009	Yes	No	No	No
Freitag et al, <sup>47</sup> 2008	Yes	Yes	Yes	Yes
Hardan et al, <sup>48</sup> 2003 (Asperger disorder sample)	Yes	Yes	Yes	Yes
Hardan et al, <sup>48</sup> 2003 (Autistic disorder sample)	Yes	Yes	Yes	Yes
Hyde et al, <sup>37</sup> 2009	Yes	Yes	Yes	No
Ke et al, <sup>49</sup> 2008	Yes	Yes	Yes	Yes
Kosaka et al, <sup>38</sup> 2010	Yes	Yes	Yes	Yes
Kwon et al, <sup>50</sup> 2004 (Asperger disorder sample)	Yes	Yes	Yes	Yes
Kwon et al, <sup>50</sup> 2004 (Autistic disorder sample)	Yes	Yes	Yes	Yes
Langen et al, <sup>51</sup> 2009	Yes	Yes	Yes	Yes
McAlonan et al, <sup>39</sup> 2002	Yes	Yes	Yes	Yes
McAlonan et al, <sup>52</sup> 2008 (Asperger disorder sample)	Yes	Yes	Yes	Yes
McAlonan et al, <sup>52</sup> 2008 (Autistic disorder sample)	Yes	Yes	Yes	Yes
Rojas et al, <sup>40</sup> 2006	Yes	Yes	Yes	Yes
Schmitz et al, <sup>41</sup> 2006	Yes	Yes	Yes	No
Toal et al, <sup>42</sup> 2009 (Asperger disorder sample)	Yes	Yes	Yes	Yes
Toal et al, <sup>42</sup> 2009 (Autistic disorder sample)	Yes	Yes	Yes	Yes
Waiter et al, <sup>53</sup> 2004	Yes	Yes	Yes	No
Wilson et al, <sup>43</sup> 2009	Yes	Yes	Yes	Yes
<b>Total (24 data sets)</b>	<b>24</b>	<b>22</b>	<b>23</b>	<b>20</b>
Quartiles analysis				
First quartile (25%)	Yes	No	Yes	No
Second quartile (median)	No	No	No	No
Third quartile (75%)	No	No	No	No



**Figure 3.** Contribution of diagnostic group and age to the main results. Data shown are Signed Differential Mapping values, ranging from -1 to 1.

tistically higher in adults than in adolescents with ASD. Each of these findings is discussed in turn.

### Reduced Gray Matter Volume in Amygdala-Hippocampus Complex

The amygdala-hippocampus complex and adjacent cortical regions (eg, parahippocampal gyrus) have long been

hypothesized to be involved in ASD.<sup>57,58</sup> For example, lesions in the amygdala cause impairment in social cognition and alterations in salience coding, including processing of emotional information from faces,<sup>59-64</sup> features that had also been demonstrated to be altered in autism.<sup>65-69</sup>

Structural neuroimaging studies in ASD have reported volumetric abnormalities in the amygdala-hippocampus complex, although the direction of the changes has been

inconsistent.<sup>11,56</sup> Our results are in agreement with previous reports<sup>70-72</sup> of reduced gray matter volume in this region. Structural abnormalities in the amygdala are consistent with the results of a recent meta-analysis<sup>73</sup> that has shown hypoactivation of this structure in functional neuroimaging tasks related to social processes.

It is clear that the amygdala and its adjacent structures are implicated in social cognition.<sup>74</sup> Its impairment in ASD is largely supported by tasks involving theory-of-mind processes,<sup>75-80</sup> which require making inferences regarding the mental state of others.<sup>75,81</sup> Although the amygdala is one of the main areas active during these tasks, other brain regions, such as the precuneus and middle-inferior prefrontal areas, also found to be abnormal in this meta-analysis, are implicated too.<sup>78</sup> An alternative, yet not incompatible, interpretation of the findings is that the reported abnormalities in the amygdala-hippocampus may be associated with the extremely high prevalence of emotional disorders in ASD. Indeed, numerous studies<sup>82-84</sup> have shown that participants with ASD have a much higher prevalence of anxiety and mood disorders than would be expected in the general population. The amygdala-hippocampus complex is crucial to the current neurobiological models of anxiety and mood disorders.<sup>85-90</sup> Unfortunately, it is not possible from the current data to establish whether the observed abnormalities predispose individuals to developing anxiety or mood disorders, are the consequence of these comorbidities, or both.

#### **Reduced Gray Matter Volume in Medial Parietal Cortex (Precuneus)**

The precuneus is a posteromedial area in the parietal lobe that has been poorly studied in the past because of its broad connections with other brain regions and the rarity of specific lesions in this area. To our knowledge, there are no previous studies in ASD in which the parietal cortex has been selected as an ROI. However, in addition to the VBM studies included in this meta-analysis, at least 2 previous ASD studies<sup>91,92</sup> reported abnormal cortical thickness in this region using surface-based morphometry methods.

A recent functional neuroimaging study<sup>93</sup> provides interesting information regarding the role of the precuneus and its possible role in ASD. Specifically, the precuneus has been implicated in the processing of the self (ie, the representation and awareness of the self, integral to many aspects of social cognition), which has in turn been found to be impaired in autism.<sup>94,95</sup>

Supporting its role in social functions, the precuneus and medial prefrontal areas (including those reported in this meta-analysis) are implicated in the so-called mirror neuron system, which is involved in action-perception linkage and has been hypothesized to underlie empathy and social insight.<sup>96</sup> Dysfunction of the mirror neuron system in ASD (the broken mirror hypothesis) has been suggested and is currently a topic of considerable debate.<sup>97-103</sup>

The precuneus is also involved in visuospatial imagery, and several studies<sup>104</sup> have found unusual connectivity in participants with ASD when performing visuospa-

tial imagery tasks. Different visual abnormalities have been proposed to cause many of the behavioral signs and symptoms of ASD, some of them specifically affecting the development of social cognitive skills.<sup>105</sup> A third function in which the precuneus is implicated is episodic memory, which is known to be specifically impaired in ASD.<sup>106,107</sup>

#### **Increase in Gray Matter in the Left Middle-Inferior Frontal Cortex**

It is well known that lesions in prefrontal regions and their connections with other brain areas, such as the precuneus and the amygdala, cause marked impairment in social cognition.<sup>108-112</sup> Frontal brain areas have previously been proposed to be involved in ASD,<sup>76-79</sup> including the middle and inferior frontal gyri, although the precise regions obtained in our study (BA46 and BA10) have been less well studied in ASD. However, our findings in these regions were somewhat less robust because they failed to remain significant in some of the reliability analyses; thus, these findings need to be interpreted with caution.

#### **Absence of Gray Matter Volume Differences Between Autistic Disorder and Asperger Disorder**

An ongoing debate exists as to whether autistic disorder and Asperger disorder are 2 separate disorders or represent a single nosologic entity with varying degrees of severity.<sup>113,114</sup> We did not find statistically significant differences in gray matter volume between the autistic disorder and Asperger disorder groups. These findings would suggest that both disorders, as diagnosed in studies to date, have similar neural substrates and support the view of a single nosologic entity with differing degrees of severity. Thus, our results would be consistent with the proposal in the current draft of the *DSM-5* to subsume autistic disorder and Asperger disorder (as well as pervasive developmental disorder not otherwise specified) into a single, broader ASD category.<sup>17</sup> It is, of course, still possible that each of these disorders may prove to be etiologically heterogeneous.

#### **Differences Between Adult and Adolescent ASD Samples**

Generally, the findings were more pronounced in adult than adolescent samples, but the only statistically significant difference was a greater gray matter volume reduction in the precuneus in adult compared with adolescent samples. Whether these differences are the result of developmental maturational processes or reflect secondary effects of living with cognitive differences is unclear because little is known about the role of this brain region in ASD. One functional neuroimaging study<sup>115</sup> has recently reported age-related changes in the neural correlates of empathy (including decreases in activation in the right precuneus) in healthy participants.

Age-related changes in ASD may result from dynamic processes in brain structure and function across the lifespan.<sup>116</sup> It is known that children and adoles-

cents with ASD can show a surprising degree of age-related clinical improvement.<sup>117</sup> It is therefore possible that a selection bias exists, whereby older participants may have a more disabling form of the disorder and thus display more prominent gray matter abnormalities. Unfortunately, few magnetic resonance imaging studies have included young children, and it was difficult to fully explore age-related differences in brain structure in this meta-analysis. Longitudinal studies tracking individuals with a range of outcomes are clearly needed to examine this question.

In any case, these results need to be interpreted cautiously because additional analyses that include only diagnostically pure samples (ie, composed of only participants with autistic disorder or only those with Asperger disorder) revealed no statistically significant age effects. This finding could be indicative of insufficient statistical power to examine age-related effects.

### STRENGTHS AND LIMITATIONS

The main strengths of this study are the unbiased inclusion of published and unpublished studies, even if their results were negative (ie, when no significant differences between participants with ASD and controls were found) and the use of novel voxel-wise meta-analytic methods.<sup>27,28</sup> The online database containing all the data and methodologic details from every study included in this meta-analysis will be a useful resource. It is important to highlight several limitations of this study, some of which are inherent to all meta-analytical approaches. First, despite our attempts to include as many unpublished VBM studies as possible, the possibility of publication bias cannot be entirely ruled out. Second, voxel-based meta-analyses are based on summarized (ie, coordinates from published studies) rather than raw data, which may result in less accurate results.<sup>16</sup> However, obtaining the raw images from the original studies is logistically difficult. Third, although our method provides excellent control for false-positive results, it is more difficult to completely avoid false-negative results. Fourth, our comparison of results from groups with autistic disorder vs Asperger disorder may be limited by the method and accuracy of the specific diagnoses in the contributing studies; it can be extremely hard, for example, to obtain reliable developmental history (eg, age of first words and phrases) from parents of adults. Fifth, studies retrieved were generally homogeneous in terms of sex (predominantly male), IQ (mostly high functioning), and age (predominantly adults and adolescents), which may not represent the entire autistic spectrum. For example, in the general population, approximately 60% of all participants with ASD have an IQ below 70.<sup>2</sup> Therefore, the current results may not generalize to female participants, those with an IQ below 70, or younger patients with ASD.

In conclusion, our meta-analysis provides a quantitative summary of VBM studies in ASD and helps resolve some of the relatively inconsistent results in this literature. Abnormalities in bilateral amygdala-hippocampus, precuneus, and left prefrontal areas in ASD are all indicative of a dysfunctional network of social brain regions and consistent with the defining features of this sociocommu-

nicative disorder. In addition, our results suggest common structural abnormalities between high-functioning autistic disorder and Asperger disorder, which support the proposal of a single category of ASD in the DSM-5.

**Submitted for Publication:** July 27, 2010; final revision received November 2, 2010; accepted November 14, 2010.

**Correspondence:** David Mataix-Cols, PhD, PO Box 69, Department of Psychosis Studies, Institute of Psychiatry, King's College London, De Crespigny Park, London SE5 8AF, England (David.Mataix-Cols@kcl.ac.uk).

**Financial Disclosure:** None reported.

**Previous Presentation:** Part of this work was presented at the 16th Annual Meeting of the Organization for Human Brain Mapping; June 10, 2010; Barcelona, Spain.

**Additional Contributions:** We thank all the authors of the included studies, particularly Antonio Youssef Hardan, MD, and Christine Ecker, PhD, for sharing their unpublished data for inclusion in this meta-analysis.

### REFERENCES

1. American Psychiatric Association. *Diagnostic and Statistical Manual of Mental Disorders*. 4th ed, text revision. Washington, DC: American Psychiatric Association; 2000.
2. Baird G, Simonoff E, Pickles A, Chandler S, Loucas T, Meldrum D, Charman T. Prevalence of disorders of the autism spectrum in a population cohort of children in South Thames: the Special Needs and Autism Project (SNAP). *Lancet*. 2006;368(9531):210-215.
3. Folstein S, Rutter M. Infantile autism: a genetic study of 21 twin pairs. *J Child Psychol Psychiatry*. 1977;18(4):297-321.
4. Bailey A, Luthert P, Bolton P, Le Couteur A, Rutter M, Harding B. Autism and megalencephaly. *Lancet*. 1993;341(8854):1225-1226.
5. Piven J, Arndt S, Bailey J, Haverkamp S, Andreasen NC, Palmer P. An MRI study of brain size in autism. *Am J Psychiatry*. 1995;152(8):1145-1149.
6. Courchesne E, Pierce K, Schumann CM, Redcay E, Buckwalter JA, Kennedy DP, Morgan J. Mapping early brain development in autism. *Neuron*. 2007;56(2):399-413.
7. Verhoeven JS, De Cock P, Lagae L, Snaert S. Neuroimaging of autism. *Neuroradiology*. 2010;52(1):3-14.
8. Minshew NJ, Williams DL. The new neurobiology of autism: cortex, connectivity, and neuronal organization. *Arch Neurol*. 2007;64(7):945-950.
9. Brambilla P, Hardan A, di Nemi SU, Perez J, Soares JC, Barale F. Brain anatomy and development in autism: review of structural MRI studies. *Brain Res Bull*. 2003;61(6):557-569.
10. Palmen S, van Engeland H. Review on structural neuroimaging findings in autism. *J Neural Transm*. 2004;111(7):903-929.
11. Penn HE. Neurobiological correlates of autism: a review of recent research. *Child Neuropsychol*. 2006;12(1):57-79.
12. Levy SE, Mandell DS, Schultz RT. Autism. *Lancet*. 2009;374(9701):1627-1638.
13. Ashburner J, Friston KJ. Why voxel-based morphometry should be used. *Neuroimage*. 2001;14(6):1238-1243.
14. Ashburner J, Friston KJ. Voxel-based morphometry: the methods. *Neuroimage*. 2000;11(6, pt 1):805-821.
15. Costafreda SG. Pooling fMRI data: meta-analysis, mega-analysis and multi-center studies. *Front Neuroinformatics*. 2009;3:33.
16. Salimi-Khorshidi G, Smith SM, Keltner JR, Wager TD, Nichols TE. Meta-analysis of neuroimaging data: a comparison of image-based and coordinate-based pooling of studies. *Neuroimage*. 2009;45(3):810-823.
17. American Psychiatric Association. DSM-5 development. 2010. American Psychiatric Association Web site. <http://www.dsm5.org/Pages/Default.aspx>. Accessed October 11, 2010.
18. Witwer AN, Lecavalier L. Examining the validity of autism spectrum disorder subtypes. *J Autism Dev Disord*. 2008;38(9):1611-1624.
19. Ozonoff S, South M, Miller JN. DSM-IV-defined Asperger syndrome: cognitive, behavioral and early history differentiation from high-functioning autism. *Autism*. 2000;4(1):29-46.
20. Howlin P. Outcome in high-functioning adults with autism with and without early language delays: implications for the differentiation between autism and Asperger syndrome. *J Autism Dev Disord*. 2003;33(1):3-13.



21. Abell F, Krams M, Ashburner J, Passingham R, Friston K, Frackowiak R, Happé F, Frith C, Frith U. The neuroanatomy of autism: a voxel-based whole brain analysis of structural scans. *Neuroreport*. 1999;10(8):1647-1651.
22. Stroup DF, Berlin JA, Morton SC, Olkin I, Williamson GD, Rennie D, Moher D, Becker BJ, Sipe TA, Thacker SB; Meta-analysis Of Observational Studies in Epidemiology (MOOSE) Group. Meta-analysis of observational studies in epidemiology: a proposal for reporting. *JAMA*. 2000;283(15):2008-2012.
23. Radau J Signed differential mapping, 2009. SDM Project Web site. <http://www.sdmproject.com/>. Accessed October 11, 2010.
24. Viechtbauer W. Bias and efficiency of meta-analytic variance estimators in the random-effects model. *J Educ Behav Stat*. 2005;30(3):261-293.
25. Turkeltaub PE, Eden GF, Jones KM, Zeffiro TA. Meta-analysis of the functional neuroanatomy of single-word reading: method and validation. *Neuroimage*. 2002;16(3, pt 1):765-780.
26. Wager TD, Lindquist M, Kaplan L. Meta-analysis of functional neuroimaging data: current and future directions. *Soc Cogn Affect Neurosci*. 2007;2(2):150-158.
27. Radau J, Mataix-Cols D. Voxel-wise meta-analysis of grey matter changes in obsessive-compulsive disorder. *Br J Psychiatry*. 2009;195(5):393-402.
28. Radau J, van den Heuvel OA, Surguladze S, Mataix-Cols D. Meta-analytical comparison of voxel-based morphometry studies in obsessive-compulsive disorder vs other anxiety disorders. *Arch Gen Psychiatry*. 2010;67(7):701-711.
29. Yamasue H, Ishijima M, Abe O, Sasaki T, Yamada H, Suga M, Rogers M, Minowa I, Someya R, Kurita H, Aoki S, Kato N, Kasai K. Neuroanatomy in monozygotic twins with Asperger disorder discordant for comorbid depression. *Neurology*. 2005;65(3):491-492.
30. McAlonan GM, Cheung V, Cheung C, Suckling J, Lam GY, Tai KS, Yip L, Murphy DGM, Chua SE. Mapping the brain in autism: a voxel-based MRI study of volumetric differences and intercorrelations in autism. *Brain*. 2005;128(pt 2):268-276.
31. Salmund CH, Ashburner J, Connelly A, Friston KJ, Gadian DG, Vargha-Khadem F. The role of the medial temporal lobe in autistic spectrum disorders. *Eur J Neurosci*. 2005;22(3):764-772.
32. Salmund CH, Vargha-Khadem F, Gadian DG, de Haan M, Baldeweg T. Heterogeneity in the patterns of neural abnormality in autistic spectrum disorders: evidence from ERP and MRI. *Cortex*. 2007;43(6):686-699.
33. Salmund CH, de Haan M, Friston KJ, Gadian DG, Vargha-Khadem F. Investigating individual differences in brain abnormalities in autism. *Philos Trans R Soc Lond B Biol Sci*. 2003;358(1430):405-413.
34. Steinman K, Lotspeich L, Patnaik S, Hoefl F, Reiss A. Structural brain differences between autistic children and their typically-developing siblings: a voxel-based morphometry analysis [ANA Annual Meeting abstract poster CD34]. *Ann Neurol*. 2008;64(6):S155.
35. Craig MC, Zaman SH, Daly EM, Cutter WJ, Robertson DMW, Hallahan B, Toal F, Reed S, Ambikapathy A, Brammer M, Murphy CM, Murphy DGM. Women with autistic-spectrum disorder: magnetic resonance imaging study of brain anatomy. *Br J Psychiatry*. 2007;191:224-228.
36. Ecker C, Rocha-Rego V, Johnston P, Mourao-Miranda J, Marquand A, Daly EM, Brammer MJ, Murphy C, Murphy DG; MRC AIMS Consortium. Investigating the predictive value of whole-brain structural MR scans in autism: a pattern classification approach. *Neuroimage*. 2010;49(1):44-56.
37. Hyde KL, Samson F, Evans AC, Mottron L. Neuroanatomical differences in brain areas implicated in perceptual and other core features of autism revealed by cortical thickness analysis and voxel-based morphometry. *Hum Brain Mapp*. 2010;31(4):556-566.
38. Kosaka H, Omori M, Munesue T, Ishitobi M, Matsumura Y, Takahashi T, Narita K, Murata T, Saito DN, Uchiyama H, Morita T, Kikuchi M, Mizukami K, Okazawa H, Sadato N, Wada Y. Smaller insula and inferior frontal volumes in young adults with pervasive developmental disorders. *Neuroimage*. 2010;50(4):1357-1363.
39. McAlonan GM, Daly E, Kumari V, Critchley HD, van Amelsvoort T, Suckling J, Simmons A, Sigmundsson T, Greenwood K, Russell A, Schmitz N, Happe F, Howlin P, Murphy DGM. Brain anatomy and sensorimotor gating in Asperger's syndrome. *Brain*. 2002;125(pt 7):1594-1606.
40. Rojas DC, Peterson E, Winterrowd E, Reite ML, Rogers SJ, Tregellas JR. Regional gray matter volumetric changes in autism associated with social and repetitive behavior symptoms. *BMC Psychiatry*. 2006;6:56.
41. Schmitz N, Rubia K, Daly E, Smith A, Williams S, Murphy DGM. Neural correlates of executive function in autistic spectrum disorders. *Biol Psychiatry*. 2006;59(1):7-16.
42. Toal F, Daly EM, Page L, Deeley Q, Hallahan B, Bloemen O, Cutter WJ, Brammer MJ, Curran S, Robertson D, Murphy C, Murphy KC, Murphy DG. Clinical and anatomical heterogeneity in autistic spectrum disorder: a structural MRI study. *Psychol Med*. 2010;40(7):1171-1181.
43. Wilson LB, Tregellas JR, Hagerman RJ, Rogers SJ, Rojas DC. A voxel-based morphometry comparison of regional gray matter between fragile X syndrome and autism. *Psychiatry Res*. 2009;174(2):138-145.
44. Boddaert N, Chabane N, Gervais H, Good CD, Bourgeois M, Plumet M-H, Barthélémy C, Mouren MC, Artiges E, Samson Y, Brunelle F, Frackowiak R, Zilbovicius M. Superior temporal sulcus anatomical abnormalities in childhood autism: a voxel-based morphometry MRI study. *Neuroimage*. 2004;23(1):364-369.
45. Bonilha L, Cendes F, Rorden C, Eckert M, Dalgalarrondo P, Li LM, Steiner CE. Gray and white matter imbalance: typical structural abnormality underlying classic autism? *Brain Dev*. 2008;30(6):396-401.
46. Brieber S, Neufang S, Bruning N, Kamp-Becker I, Remschmidt H, Herpertz-Dahlmann B, Fink GR, Konrad K. Structural brain abnormalities in adolescents with autism spectrum disorder and patients with attention deficit/hyperactivity disorder. *J Child Psychol Psychiatry*. 2007;48(12):1251-1258.
47. Freitag CM, Konrad C, Häberlen M, Kleser C, von Gontard A, Reith W, Troje NF, Krick C. Perception of biological motion in autism spectrum disorders. *Neuropsychologia*. 2008;46(5):1480-1494.
48. Hardan AY, Yorbik O, Minshew NJ, Diwadkar VA, Keshavan MS. Voxel-based morphometry study of gray matter in Asperger's disorder [SOBP Annual Meeting, abstract 597]. *Biol Psychiatry*. 2003;53:211-212.
49. Ke X, Hong S, Tang T, Zou B, Li H, Hang Y, Zhou Z, Ruan Z, Lu Z, Tao G, Liu Y. Voxel-based morphometry study on brain structure in children with high-functioning autism. *Neuroreport*. 2008;19(9):921-925.
50. Kwon H, Ow AW, Pedatella KE, Lotspeich LJ, Reiss AL. Voxel-based morphometry elucidates structural neuroanatomy of high-functioning autism and Asperger syndrome. *Dev Med Child Neurol*. 2004;46(11):760-764.
51. Langen M, Schnack HG, Nederveen H, Bos D, Lahuis BE, de Jonge MV, van Engeland H, Durston S. Changes in the developmental trajectories of striatum in autism. *Biol Psychiatry*. 2009;66(4):327-333.
52. McAlonan GM, Suckling J, Wong N, Cheung V, Lienenkaemper N, Cheung C, Chua SE. Distinct patterns of grey matter abnormality in high-functioning autism and Asperger's syndrome. *J Child Psychol Psychiatry*. 2008;49(12):1287-1295.
53. Waiter GD, Williams JH, Murray AD, Gilchrist A, Perrett DI, Whiten A. A voxel-based investigation of brain structure in male adolescents with autistic spectrum disorder. *Neuroimage*. 2004;22(2):619-625.
54. Lord C, Rutter M, Le Couteur A. Autism Diagnostic Interview-Revised: a revised version of a diagnostic interview for caregivers of individuals with possible pervasive developmental disorders. *J Autism Dev Disord*. 1994;24(5):659-685.
55. Hedges LV, Olkin I, eds. *Statistical Methods for Meta-Analysis*. Orlando, FL: Academic Press; 1985.
56. Stanfield AC, McIntosh AM, Spencer MD, Philip R, Gaur S, Lawrie SM. Towards a neuroanatomy of autism: a systematic review and meta-analysis of structural magnetic resonance imaging studies. *Eur Psychiatry*. 2008;23(4):289-299.
57. Bauman M, Kemper TL. Histoanatomic observations of the brain in early infantile autism. *Neurology*. 1985;35(6):866-874.
58. Baron-Cohen S, Ring HA, Bullmore ET, Wheelwright S, Ashwin C, Williams SC. The amygdala theory of autism. *Neurosci Biobehav Rev*. 2000;24(3):355-364.
59. Kluver H, Bucy PC. Psychic blindness and other symptoms following bilateral temporal lobectomy in rhesus monkeys [Proceedings of the American Physiological Society, 49th annual meeting]. *Am J Physiol*. 1937;119:352-353.
60. Brothers L, Ring B, Kling A. Response of neurons in the macaque amygdala to complex social stimuli. *Behav Brain Res*. 1990;41(3):199-213.
61. Thompson CI, Towfighi JT. Social behavior of juvenile rhesus monkeys after amygdalotomy in infancy. *Physiol Behav*. 1976;17(5):831-836.
62. Emery NJ, Capitanio JP, Mason WA, Machado CJ, Mendoza SP, Amaral DG. The effects of bilateral lesions of the amygdala on dyadic social interactions in rhesus monkeys (*Macaca mulatta*). *Behav Neurosci*. 2001;115(3):515-544.
63. Bachevalier J, Mishkin M. Effects of selective neonatal temporal lobe lesions on visual recognition memory in rhesus monkeys. *J Neurosci*. 1994;14(4):2128-2139.
64. Adolphs R. What does the amygdala contribute to social cognition? *Ann N Y Acad Sci*. 2010;1191(1):42-61.
65. Bachevalier J. Brief report: medial temporal lobe and autism: a putative animal model in primates. *J Autism Dev Disord*. 1996;26(2):217-220.
66. Klin A, Sparrow SS, de Bildt A, Cicchetti DV, Cohen DJ, Volkmar FR. A normed study of face recognition in autism and related disorders. *J Autism Dev Disord*. 1999;29(6):499-508.
67. Amaral DG, Bauman MD, Schumann CM. The amygdala and autism: implications from non-human primate studies. *Genes Brain Behav*. 2003;2(5):295-302.
68. Boraston Z, Blakemore SJ. The application of eye-tracking technology in the study of autism. *J Physiol*. 2007;581(pt 3):893-898.
69. Sasson NJ. The development of face processing in autism. *J Autism Dev Disord*. 2006;36(3):381-394.
70. Saitoh O, Karns CM, Courchesne E. Development of the hippocampal forma-

- tion from 2 to 42 years: MRI evidence of smaller area dentata in autism. *Brain*. 2001;124(pt 7):1317-1324.
71. Aylward EH, Minshew NJ, Goldstein G, Honeycutt NA, Augustine AM, Yates KO, Barta PE, Pearson GD. MRI volumes of amygdala and hippocampus in nonmentally retarded autistic adolescents and adults. *Neurology*. 1999;53(9):2145-2150.
  72. Howard MA, Cowell PE, Boucher J, Broks P, Mayes A, Farrant A, Roberts N. Convergent neuroanatomical and behavioural evidence of an amygdala hypothesis of autism. *Neuroreport*. 2000;11(13):2931-2935.
  73. Di Martino A, Ross K, Uddin LQ, Sklar AB, Castellanos FX, Milham MP. Functional brain correlates of social and nonsocial processes in autism spectrum disorders: an ALE meta-analysis. *Biol Psychiatry*. 2009;65(1):63-74.
  74. Brothers L, et al. The social brain: a project for integrating primate behavior and neurophysiology in a new domain. In: Cacioppo JT eds. *Foundations in Social Neuroscience*. Cambridge, MA: The MIT Press; 2002:367-388.
  75. Baron-Cohen S, Leslie AM, Frith U. Does the autistic child have a "theory of mind"? *Cognition*. 1985;21(1):37-46.
  76. Happé F, Ehlers S, Fletcher P, Frith U, Johansson M, Gillberg C, Dolan R, Frackowiak R, Frith C. "Theory of mind" in the brain: evidence from a PET scan study of Asperger syndrome. *Neuroreport*. 1996;8(1):197-201.
  77. Happé F, Frith U. The neuropsychology of autism. *Brain*. 1996;119(pt 4):1377-1400.
  78. Baron-Cohen S, Ring HA, Wheelwright S, Bullmore ET, Brammer MJ, Simmons A, Williams SCR. Social intelligence in the normal and autistic brain: an fMRI study. *Eur J Neurosci*. 1999;11(6):1891-1898.
  79. Castelli F, Frith C, Happé F, Frith U. Autism, Asperger syndrome and brain mechanisms for the attribution of mental states to animated shapes. *Brain*. 2002;125(pt 8):1839-1849.
  80. Domes G, Kumbier E, Herpertz-Dahlmann B, Herpertz SC. Social cognition in autism: a survey of functional imaging studies [in German]. *Nervenarzt*. 2008;79(3):261-274.
  81. Siegal M, Varley R. Neural systems involved in "theory of mind." *Nat Rev Neurosci*. 2002;3(6):463-471.
  82. Hutton J, Goode S, Murphy M, Le Couteur A, Rutter M. New-onset psychiatric disorders in individuals with autism. *Autism*. 2008;12(4):373-390.
  83. MacNeil BM, Lopes VA, Minnes PM. Anxiety in children and adolescents with autism spectrum disorders. *Res Autism Spectr Disord*. 2009;3(1):1-21.
  84. Skokauskas N, Gallagher L. Psychosis, affective disorders and anxiety in autistic spectrum disorder: prevalence and nosological considerations. *Psychopathology*. 2010;43(1):8-16.
  85. Herman JP, Cullinan WE. Neurocircuitry of stress: central control of the hypothalamo-pituitary-adrenocortical axis. *Trends Neurosci*. 1997;20(2):78-84.
  86. McEwen BS. Mood disorders and allostatic load. *Biol Psychiatry*. 2003;54(3):200-207.
  87. Campbell S, Marriott M, Nahmias C, MacQueen GM. Lower hippocampal volume in patients suffering from depression: a meta-analysis. *Am J Psychiatry*. 2004;161(4):598-607.
  88. Diamond DM, Campbell A, Park CR, Vouimba R-M. Preclinical research on stress, memory, and the brain in the development of pharmacotherapy for depression. *Eur Neuropsychopharmacol*. 2004;14(suppl 5):S491-S495.
  89. Reagan LP, Grillo CA, Piroli GG. The As and Ds of stress: metabolic, morphological and behavioral consequences. *Eur J Pharmacol*. 2008;585(1):64-75.
  90. Castro JE, Varea E, Márquez C, Cordero MI, Poirier G, Sandi C. Role of the amygdala in antidepressant effects on hippocampal cell proliferation and survival and on depression-like behavior in the rat. *PLoS One*. 2010;5(1):e8618. doi:10.1371/journal.pone.0008618.
  91. Hardan AY, Muddasani S, Vemulapalli M, Keshavan MS, Minshew NJ. An MRI study of increased cortical thickness in autism. *Am J Psychiatry*. 2006;163(7):1290-1292.
  92. Jiao Y, Chen R, Ke X, Chu K, Lu Z, Herskovits EH. Predictive models of autism spectrum disorder based on brain regional cortical thickness. *Neuroimage*. 2010;50(2):589-599.
  93. Cavanna AE, Trimble MR. The precuneus: a review of its functional anatomy and behavioural correlates. *Brain*. 2006;129(pt 3):564-583.
  94. Lombardo MV, Barnes JL, Wheelwright SJ, Baron-Cohen S. Self-referential cognition and empathy in autism. *PLoS One*. 2007;2(9):e883. doi:10.1371/journal.pone.0000883.
  95. Lombardo MV, Baron-Cohen S. Unraveling the paradox of the autistic self. *Wiley Interdiscip Rev Cogn Sci*. 2010;1(3):393-403.
  96. Rizzolatti G, Fabbri-Destro M. Mirror neurons: from discovery to autism. *Exp Brain Res*. 2010;200(3-4):223-237.
  97. Ramachandran VS, Oberman LM. Broken mirrors: a theory of autism. *Sci Am*. 2006;295(5):62-69.
  98. Iacoboni M, Dapretto M. The mirror neuron system and the consequences of its dysfunction. *Nat Rev Neurosci*. 2006;7(12):942-951.
  99. Oberman LM, Ramachandran VS. The simulating social mind: the role of the mirror neuron system and simulation in the social and communicative deficits of autism spectrum disorders. *Psychol Bull*. 2007;133(2):310-327.
  100. Williams JH. Self-other relations in social development and autism: multiple roles for mirror neurons and other brain bases. *Autism Res*. 2008;1(2):73-90.
  101. Southgate V, Hamilton AF. Unbroken mirrors: challenging a theory of autism. *Trends Cogn Sci*. 2008;12(6):225-229.
  102. Hickok G. Eight problems for the mirror neuron theory of action understanding in monkeys and humans. *J Cogn Neurosci*. 2009;21(7):1229-1243.
  103. Dinstein I, Thomas C, Humphreys K, Minshew N, Behrmann M, Heeger DJ. Normal movement selectivity in autism. *Neuron*. 2010;66(3):461-469.
  104. Minshew NJ, Keller TA. The nature of brain dysfunction in autism: functional brain imaging studies. *Curr Opin Neurol*. 2010;23(2):124-130.
  105. Simmons DR, Robertson AE, McKay LS, Toal E, McAleer P, Pollick FE. Vision in autism spectrum disorders. *Vision Res*. 2009;49(22):2705-2739.
  106. Bowler DM, Gardiner JM, Berthollier N. Source memory in adolescents and adults with Asperger's syndrome. *J Autism Dev Disord*. 2004;34(5):533-542.
  107. Lind SE, Bowler DM. Recognition memory, self-other source memory, and theory-of-mind in children with autism spectrum disorder. *J Autism Dev Disord*. 2009;39(9):1231-1239.
  108. Shallice T, Burgess PW. Deficits in strategy application following frontal lobe damage in man. *Brain*. 1991;114(pt 2):727-741.
  109. Saver JL, Damasio AR. Preserved access and processing of social knowledge in a patient with acquired sociopathy due to ventromedial frontal damage. *Neuropsychologia*. 1991;29(12):1241-1249.
  110. Dimitrov M, Grafman J, Hollnagel C. The effects of frontal lobe damage on everyday problem solving. *Cortex*. 1996;32(2):357-366.
  111. Adolphs R. The social brain: neural basis of social knowledge. *Annu Rev Psychol*. 2009;60:693-716.
  112. Forbes CE, Grafman J. The role of the human prefrontal cortex in social cognition and moral judgment. *Annu Rev Neurosci*. 2010;33:299-324.
  113. Volkmar FR, State M, Klin A. Autism and autism spectrum disorders: diagnostic issues for the coming decade. *J Child Psychol Psychiatry*. 2009;50(1-2):108-115.
  114. Macintosh KE, Dissanayake C. Annotation: the similarities and differences between autistic disorder and Asperger's disorder: a review of the empirical evidence. *J Child Psychol Psychiatry*. 2004;45(3):421-434.
  115. Greimel E, Schulte-Rüther M, Fink GR, Piefke M, Herpertz-Dahlmann B, Konrad K. Development of neural correlates of empathy from childhood to early adulthood: an fMRI study in boys and adult men. *J Neural Transm*. 2010;117(6):781-791.
  116. Courchesne E, Campbell K, Solso S. Brain growth across the life span in autism: age-specific changes in anatomical pathology. *Brain Res*. 2011;1380:138-145.
  117. Helt M, Kelley E, Kinsbourne M, Pandey J, Boorstein H, Herbert M, Fein D. Can children with autism recover? if so, how? *Neuropsychol Rev*. 2008;18(4):339-366.