

Globally and Locally Reduced MRI Gray Matter Volumes in Neuroleptic-Naive Men With Schizotypal Personality Disorder

Association With Negative Symptoms

Takeshi Asami, MD, PhD; Thomas J. Whitford, PhD; Sylvain Bouix, PhD; Chandlee C. Dickey, MD; Margaret Niznikiewicz, PhD; Martha E. Shenton, PhD; Martina M. Voglmaier, PhD; Robert W. McCarley, MD

Importance: Some, but not all, previous magnetic resonance imaging studies have indicated smaller cortical and local gray matter volumes (GMVs) in men with schizotypal personality disorder (SPD) compared with healthy control (HC) subjects. Thus, there is need for a whole-brain comparison to resolve inconsistencies and provide hitherto generally absent data on the association between GMV and symptoms.

Objective: To use voxel-based morphometry to evaluate a large sample of neuroleptic-naive men with SPD compared with group-matched HC subjects on local and global GMV and to identify associations with symptoms, especially negative symptoms. Also, to determine whether age-related GMV reductions are greater in men with SPD than HC subjects, providing presumptive evidence on possible progression.

Design, Setting, and Participants: This naturalistic study involved 54 neuroleptic-naive men with SPD and 54 male HC subjects aged 18 to 55 years recruited from the community and scanned on the same 1.5-T GE magnetic resonance imaging scanner. Participants were group matched on age, socioeconomic status, handedness, and IQ.

Main Outcome Measures: Cross-sectional voxel-based morphometry, GMV in subjects with SPD and

HC participants, and the relationship to clinical symptoms.

Results: A voxelwise analysis showed participants with SPD had significantly smaller GMV in the left superior temporal gyrus and widespread frontal, frontolimbic, and parietal regions compared with HC subjects. Most of these regional volumes were strikingly and significantly correlated with negative symptoms: the more the volume reduction, the more negative symptoms. Global cortical GMV and most regional GMV showed significant negative relationships with age in both those with SPD and HC subjects, without any group by age interactions.

Conclusions and Relevance: Men with SPD showed global and widespread smaller regional GMV. The regional structural abnormalities were correlated with the severity of a participant's negative symptoms. While the pattern of GMV loss is similar to that in schizophrenia, the similar patterns of HC-SPD age-related GMV reduction suggest that SPD showed no progressive GMV loss, pointing to an important difference in the biological mechanisms of SPD and schizophrenia.

JAMA Psychiatry. 2013;70(4):361-372.

Published online February 6, 2013.

doi:10.1001/jamapsychiatry.2013.665

SCHIZOTYPAL PERSONALITY DISORDER (SPD) is a schizophrenia spectrum disorder with genetic, symptomatic, cognitive, and social characteristics similar to schizophrenia.¹⁻³ It is relatively common, with a lifetime prevalence estimated at 3.9%.⁴ Recent magnetic resonance imaging (MRI) studies have provided evidence of MRI brain similarities between SPD and schizophrenia (see articles on schizophrenia by McCarley et al⁵ and Shenton et al⁶). Schizotypal personality disorder MRI abnormalities compared with healthy control (HC) subjects include both global^{7,8} and regional volume reductions in

gray matter of the neocortex (**Table 1**). Reports of regional gray matter volume (GMV) reductions in SPD include (1) temporal lobe superior temporal gyrus (STG),^{9,17,21,26,30,31} Heschl gyrus within the STG,¹⁰ middle temporal gyrus,^{8,29} fusiform gyrus,²⁷ and hippocampus^{16,24}; (2) frontal lobe superior and inferior frontal gyri,^{8,21} insula,^{20,21} and cingulate gyrus^{29,30}; (3) parietal lobe^{8,28}; and (4) basal ganglia.^{11,15,18} However, relative to schizophrenia, the number of MRI volumetric studies of SPD is smaller. Moreover, many of the studies looked at small regions of interest (ROIs), had findings that were sometimes inconsistent, and generally had a small number of participants, with

Author Affiliations are listed at the end of this article.

Table 1. Previous Structural Imaging Studies of SPD

Source	No. of Subjects (Male/Female)	Clinical or Community Based	Medication	Method	Differences in Gray Matter Volumes in Subjects With SPD vs HC Subjects
Male SPD Study					
Dickey et al, ⁹ 1999	SPD: 15/0 HC: 14/0	Community	NN	ROI	Left STG↓, amygd, hipp, parahipp →
Dickey et al, ⁷ 2000	SPD: 16/0 HC: 14/0	Community	NN	ROI	Cortex↓ in trend
Dickey et al, ¹⁰ 2002	SPD: 21/0 HC: 22/0	Community	NN	ROI	Left Heschl gyrus↓
Levitt et al, ¹¹ 2002	SPD: 15/0 HC: 14/0	Community	NN	ROI	Bilateral caudate nucleus↓
Dickey et al, ¹² 2003	SPD: 21/0 HC: 19/0	Community	NN	ROI	Fusiform gyrus →
Dickey et al, ¹³ 2008	SPD: 13/0 HC: 13/0	Community	NN	ROI	Heschl gyrus →
Female SPD Study					
Dickey et al, ¹⁴ 2003	SPD: 0/21 HC: 0/29	Community	NN	ROI	STG →/left STG↓ in SPD with family history of major mental illness (n = 9)
Koo et al, ¹⁵ 2006	SPD: 0/32 HC: 0/29	Community	NN	ROI	Bilateral caudate nucleus↓
Koo et al, ⁸ 2006	SPD: 0/31 HC: 0/29	Community	NN	ROI VBM	Bilateral neocortex↓ Left STG, MTG, postcentral gyrus↓, right SFG↓, bilateral IPG↓
Dickey et al, ¹⁶ 2007	SPD: 0/20 HC: 0/29	Community	NN	ROI	Bilateral hipp↓
Male and Female SPD Combined Study					
Downhill Jr et al, ¹⁷ 2001	SPD: 12/1 HC: 23/8	Clinical (n = 11) Community (n = 2)	UM or NN	ROI	STG↓, temporal structures without STG↓
Shihabuddin et al, ¹⁸ 2001	SPD: 15/1 HC: 35/12	Both	NN (n = 10) UM at least 2 w (n = 6)	ROI	Putamen↓, caudate nucleus →
Takahashi et al, ¹⁹ 2002	SPD: 12/12 HC: 24/24	Clinical	NN (n = 2) NL (n = 22)	ROI	Anterior cingulate gyrus →
Yoneyama et al, ²⁰ 2003	SPD: 15/1 HC: 35/12	Clinical	UM at scan (n = 3) NL (n = 11)	VBM	Bilateral insula↓, left entorhinal region↓
Kawasaki et al, ²¹ 2004	SPD: 14/11 HC: 28/22	Clinical	NN (n = 2) Med (n = 23)	VBM	Left IFG, insula, STG, medial temporal region↓
Takahashi et al, ²² 2004	SPD: 14/12 HC: 30/31	Clinical	NN (n = 2) NL (n = 24)	ROI	Perigenual cingulate gyrus →
Haznedar et al, ²³ 2004	SPD: 12/1 HC: 25/7	NA	NA	ROI	Cingulate gyrus →
Suzuki et al, ²⁴ 2005	SPD: 15/10 HC: 35/24	Clinical	NN (n = 6) NL (n = 19)	ROI	Bilateral amygd, hipp↓, MFG↑, right straight gyrus↓
Takahashi et al, ²⁵ 2005	SPD: 24/13 HC: 35/34	Clinical	NN (n = 5) NL (n = 32)	ROI	Insula →
Takahashi et al, ²⁶ 2006	SPD: 24/15 HC: 38/34	Clinical	NN (n = 5) NL (n = 34)	ROI	Bilateral caudal STG↓, left PT↓
Takahashi et al, ²⁷ 2006	SPD: 24/15 HC: 38/34	Clinical	NN (n = 5) NL (n = 34)	ROI	Posterior fusiform gyrus↓
Zhou et al, ²⁸ 2007	SPD: 15/10 HC: 35/24	Clinical	NN (n = 6) NL (n = 29)	ROI	Left postcentral gyrus↓, bilateral SPG↓ in trend
Hazlett et al, ²⁹ 2008	SPD: 62/17 HC: 42/15	Clinical (10%), Community (90%)	NvM (n = 61) UM at least 2 w (n = 18)	Atlas	Cingulate gyrus↓, left MTG↓
Goldstein et al, ³⁰ 2009	SPD: 16/11 HC: 19/26	NA	UM at scan	Atlas ROI	STG (BA22) ↓, cingulate gyrus↓ in trend Amygd →
Longitudinal ROI Study					
Takahashi et al, ³¹ 2010	SPD: 9/4 HC: 11/9	Clinical	NL	ROI	Baseline: left caudal STG, PT↓, no longitudinal changes in STG

Abbreviations: Amygd, amygdala; Atlas, Atlas-based morphometry; BA, Brodmann area; HC, healthy control; Hipp, hippocampus; IFG, inferior frontal gyrus; IPG, inferior parietal gyrus; Med, medicated; MFG, middle frontal gyrus; MTG, middle temporal gyrus; NL, neuroleptic; NN, neuroleptic naive; NvM, never medicated; NA, not applicable; parahipp, parahippocampus; PT, planum temporale; ROI, region of interest; SFG, superior/middle/inferior frontal gyrus; SPD, schizotypal personality disorder; SPG, superior/inferior parietal gyrus; STG, superior temporal gyrus; UM, unmedicated; VBM, voxel-based morphometry; ↓, volume reduction; ↑, volume increase; →, no group difference.

variability in demographic factors that are known to influence brain volume such as age, sex, handedness, IQ, socioeconomic status (SES), and neuroleptic medication use.³²⁻⁴²

Neuroleptic medications are of particular concern in light of nonhuman primate evidence suggesting that these medications can influence brain structure in and of themselves.⁴³ Thus, a study of neuroleptic-naive subjects with

SPD may provide a clearer understanding of brain abnormalities in the schizophrenia spectrum.

Another important variable in SPD is sex because previous studies have demonstrated important sex differences in SPD, including a greater rate of lifetime prevalence of SPD in men (4.2%) compared with women (3.7%).⁴ In terms of symptom clusters, males with SPDs are most different from females with SPDs in interper-

Table 2. Demographic Characteristics of the 108 Study Participants

	Mean (SD)		<i>df</i> ^a	<i>T</i>	<i>P</i> Value
	Subjects With SPD (<i>n</i> = 54)	Control Subjects (<i>n</i> = 54)			
Age, y	39.0 (10.5)	36.8 (10.2)	106	1.14	.26
Education, y	15.1 (2.6)	15.8 (2.7)	104	1.32	.19
IQ	109.0 (14.4)	112.2 (15.3)	105	1.11	.27
Socioeconomic status ^b					
Participant	3.2 (1.1)	3.0 (1.4)	104	0.71	.48
Parental	3.1 (1.3)	3.1 (1.4)	104	0.16	.88
Handedness ^c	0.77 (0.23)	0.80 (0.18)	106	0.79	.43

Abbreviation: SPD, schizotypal personality disorder.

^aThe degrees of freedom differ among variables owing to unavailability of data in some participants.

^bHigher numbers represent higher socioeconomic status based on the Hollingshead Four Factor Index of Social Status.

^cHandedness was evaluated using the Edinburgh Handedness Inventory, where right handedness is positive.

sonal relationships, having significantly fewer close relationships and also more prevalent negative symptoms associated with social deficits.⁴⁴ Males with SPD also show a greater disturbance of verbal learning and abstraction than females with SPD.⁴⁵ Not surprisingly, structural MRI studies have also shown sex differences on regional brain volumes in subjects with SPD,^{9,14,19,22,42} as well as in schizophrenia⁴⁶⁻⁴⁸ and in HC subjects.^{32,34,35} These sex differences indicate that we must separately investigate structural brain abnormalities and their symptom associations in men and women with SPD to avoid a sex confound. In our previous study, a voxel-based morphometry (VBM) analysis demonstrated volumetric gray matter (GM) reductions in several brain regions, including the left STG in the neuroleptic-naïve women with SPD compared with matched HC subjects⁸ (Table 1).

In terms of men with SPD, our previous ROI analyses demonstrated GMV reductions in the cortex (6.9% reduction)⁷ and left STG (9.2% reduction)⁹ compared with matched HC subjects. Although limited, these findings suggest that cortical brain abnormalities in men with SPD are widespread but are more pronounced in some brain regions.

For the purpose of identifying local GMV abnormalities in SPD throughout the brain, a whole-brain VBM method is useful. However, there are only a few VBM studies of SPD.^{20,21} Furthermore, to our knowledge, there have been no VBM studies that have investigated GMV reductions in neuroleptic-naïve men with SPD and none providing clues as to reductions associated with negative symptoms, especially prominent in men.

The current whole-brain cross-sectional VBM analysis investigated volume differences in global and local GM in a large sample of 54 neuroleptic-naïve men with SPD compared with 54 male HC subjects. To avoid potential confounds that could affect brain structure, the SPD and HC groups were carefully matched for sex, age, handedness, IQ, and the subject's own SES and parental SES (Table 2). Based on the previous studies (Table 1), we speculated that men with SPD would show GMV reductions in multiple cortical regions—in similar regions but to a smaller extent than the reductions previously reported in patients with established schizophrenia. Once volume differences were confirmed, differences in the patterns of age-related GMV changes were evaluated be-

tween the groups to investigate whether these 2 groups would show similar patterns of age-related volume changes. Finally, correlation analyses were conducted between GMVs and clinical measures to investigate the biological implications of structural abnormalities in the men with SPD. Given the predominance of negative symptoms in males,⁴⁴ we hypothesized that negative symptoms would be closely associated with GMV reductions, particularly in frontal regions known to play a role in emotion regulation and regions associated with social cognition. We have found these to be reduced in schizophrenia and associated with negative symptoms.⁴⁹

METHODS

SUBJECTS

A total of 54 neuroleptic-naïve men diagnosed as having *DSM-III* or *DSM-IV* SPD and 54 male control subjects were recruited from the community through advertisements. Of those, 6 male subjects with SPD and 14 male control subjects were used in our previous ROI study.⁷ Subjects with SPD were recruited via the following advertisement:

Sixth sense/very shy: A study at Harvard Medical School seeks right-handed people who believe they have ESP, telepathy, or a "sixth sense"; often mistake noises for voices; sense the presence of others when alone; have extreme social anxiety (or discomfort) in social situations involving unfamiliar people; and have few friends.

The SPD advertisement tapped the *DSM-IV* diagnostic criteria for SPD, which include (1) ideas of reference, (2) odd beliefs and superstitions or sixth sense, (3) abnormal perceptual experiences, (4) odd thinking and speech, (5) suspiciousness, (6) constricted affect, (7) odd and peculiar appearance or behavior, (8) no close friends, and (9) extreme social anxiety.

Of the 3001 individuals who responded to the SPD advertisement, 1536 male participants underwent an extensive telephone screening process that used the following inclusion criteria: (1) age between 18 and 55 years; (2) right handedness⁵⁰; (3) English as the primary language; (4) no history of neurologic disorder or loss of consciousness longer than 5 minutes; (5) no history of electroconvulsive therapy, drug or alcohol dependence in the past 5 years, or abuse in the past year; and (6) no history of using neuroleptics at any time or psychotropic medications in the past year.

Table 3. Result of Voxel-Based Morphometry Analysis^a

Anatomic Location	MNI Coordinate			No. of Contiguous Voxels	T Value	P Value	
	x	y	z			Uncorrected	FDR Corrected
Temporal region							
L superior temporal gyrus	-46	-4	-6	32	3.38	<.001	.02 ^b
L middle temporal gyrus	-60	-28	-10	34	3.62	<.001	.02 ^b
L fusiform gyrus expanding to inferior temporal gyrus	-36	-26	-26	182	4.39	<.001	.02 ^b
R superior temporal gyrus expanding to middle temporal gyrus	52	-34	10	266	4.21	<.001	.02 ^b
R fusiform gyrus	38	-12	-30	36	3.57	<.001	.02 ^b
Frontal region							
L superior frontal gyrus expanding to L and R posterior cingulate gyrus and R superior frontal gyrus	-10	-16	38	571	4.56	<.001	.02 ^b
L superior frontal gyrus	-8	68	14	339	4.04	<.001	.02 ^b
L middle frontal gyrus	-24	2	60	32	3.64	<.001	.02 ^b
L insula	-24	20	-8	162	4.04	<.001	.02 ^b
R superior frontal gyrus expanding to L superior frontal gyrus, L and R orbitofrontal cortex, and anterior cingulate gyrus (subgenual and affective)	12	50	0	955	4.69	<.001	.02 ^b
	10	34	-14		4.51	<.001	.02 ^b
R superior frontal gyrus	10	68	6	102	3.81	<.001	.02 ^b
R orbitofrontal cortex	6	68	-4		3.75	<.001	.02 ^b
R superior frontal gyrus	2	26	46	213	3.78	<.001	.02 ^b
R superior frontal gyrus	12	60	26	167	3.78	<.001	.02 ^b
R middle frontal gyrus	22	46	30		3.96	<.001	.02 ^b
R posterior cingulate gyrus	4	-42	40	351	4.48	<.001	.02 ^b
R insula	36	0	6	42	3.64	<.001	.02 ^b
R precentral gyrus	52	-6	42	80	3.42	<.001	.02 ^b
R postcentral gyrus	56	-2	32		3.43	<.001	.02 ^b
Parieto-occipital region							
L postcentral gyrus	-50	-14	16	110	3.91	<.001	.02 ^b
R supramarginal gyrus	64	-26	34	58	4.02	<.001	.02 ^b
R precuneus	6	-74	44	199	5.08	<.001	.02 ^b
R inferior occipital gyrus	46	-78	-12	75	4.3	<.001	.02 ^b

Abbreviations: FDR, false discovery rate; L, left; MNI; Montreal Neurological Institute; R, right.

^aAnalysis showed gray matter volume reduction in the 54 neuroleptic-naive men with schizotypal personality disorder compared with the matched 54 male healthy control subjects.

^bFDR-corrected $P < .05$.

Of the 1536 subjects, 242 met the telephone inclusion criteria, including positive responses to at least 3 of the previously mentioned SPD criteria on screening questions. The Structured Clinical Interview for DSM-IV–Patient Edition (SCID)⁵¹ and its personality disorder version (SCID-II)⁵² were then used to make DSM-IV diagnoses, exclude Axis I psychotic and bipolar disorders from both groups, and exclude Axis I and Axis II diagnoses from control subjects. A total of 118 male subjects were diagnosed as having SPD and 65 men with SPD underwent MRI. The fact that fewer subjects had MRIs than were eligible was primarily owing to unavailability of the scanner—subject diagnostic characteristics did not play a role in selection. Finally, 54 men with SPD were chosen for this study, matched on demographic data with male HC participants.

We have previously described in detail the clinical and demographic characteristics of the subjects with SPD.^{8,44} Interviews were conducted by either a licensed psychiatrist (C.C.D. or R.W.M) or a licensed psychologist (M.M.V. or M.E.S.). Interrater reliability for the diagnosis of SPD was high ($\kappa = 0.89$; $n = 25$).⁹

Interviewers were trained to detect nuances of behavior and history and to ask follow-up questions to establish the correct diagnosis. In the rare instances in which the first interviewer was uncertain about the diagnosis, a second licensed psychia-

trist or psychologist interviewed the subject, and a consensus was obtained. All 54 subjects with SPD who underwent MRI and other parts of the protocol met the full DSM-IV SPD diagnostic criteria (having ≥ 5 of the 9 characteristics). Subjects with SPD had a mean of 1.5 additional DSM-IV personality diagnoses, with the most common being paranoid ($n = 19$), avoidant ($n = 16$), obsessive-compulsive ($n = 12$), borderline ($n = 10$), and schizoid ($n = 9$) personality disorders. Fifteen men with SPD also met the criteria for Axis I disorders, including depression ($n = 1$); dysthymia ($n = 9$); generalized anxiety disorder ($n = 4$); and body dysmorphic disorder ($n = 1$).

Male control subjects were recruited from the community through a different advertisement and similarly underwent the SCID and SCID-II. Control participants had the additional inclusion requirement of no family history of psychotic or bipolar illness and no personal history of an Axis I or personality disorder diagnosis. Control subjects were group matched with subjects with SPD for demographic variables including age, Wechsler Adult Intelligence Scale–III IQ based on Vocabulary and Block Design subscales, handedness, and both the subject's own and parental SES.⁵³ The project was approved by the institutional review boards at Harvard Medical School and Boston Veterans Affairs Healthcare System; after a full description

of the study was provided to the participants, written informed consent was obtained.

CLINICAL MEASURES

Clinical symptoms were measured using the Structured Interview for Schizotypy (SIS).^{54,55} Use of the SIS began in the middle of subject recruitment; therefore, only 21 of the 54 men with SPD completed the SIS. Based on our previous results from SPD on the most prominent positive and negative SIS items in our population and the Kendler criteria, we calculated the positive symptom score by summing scores of (1) ideas of reference, (2) magical thinking, (3) illusions, and (4) psychoticlike symptoms, while the negative symptom score summed scores of (1) social isolation, (2) introversion, (3) restricted emotion, and (4) sensitivity.^{15,55} There were no significant demographic differences between the male subjects with SPD with and without SIS scores (eFigure, <http://www.jamapsych.com>).

MRI PROCESSING

The MRI protocol used 2 pulse sequences on a 1.5-T MRI system (GE Medical Systems), as described.⁸ A 3-dimensional Fourier transformed spoiled-gradient-recalled acquisition sequence yielded a coronal series of contiguous 1.5-mm images (echo time, 5 milliseconds; repetition time, 35 milliseconds; repetition, 1; nutation angle, 45°; field of view, 24 cm; acquisition matrix, 256 × 256 × 124; voxel dimension, 0.9375 × 0.9375 × 1.5 mm).

IMAGE PREPROCESSING

The theory and algorithms of VBM using Statistical Parametric Mapping version 5 (SPM5) software (Wellcome Department of Cognitive Neurology) are well documented.^{56,57} In the present cross-sectional study, VBM was performed using the Diffeomorphic Anatomical Registration Through Exponentiated Lie (DARTEL) algebra tool in SPM5.⁵⁸ After realigning the T1-weighted images so that the anterior commissure–posterior commissure line was horizontal and the midsagittal plane was vertical, the images were segmented by the unified segmentation approach in SPM5⁵⁷ into probability maps of gray and white matter and cerebrospinal fluid. These gray and white probability maps were then rigid-body aligned (3 rotations and 3 translations) according to the Montreal Neurological Institute (MNI) template and resampled into 1.5-mm isotropic voxels. These aligned images were still in their native space (www.fil.ion.ucl.ac.uk/spm/doc/manual.pdf). Next, a population GM was created by nonlinear registration of the resampled gray and white matter probability maps using DARTEL, which provided a higher dimensional (thus more accurate) warping procedure than that typically used in standard VBM.⁵⁸ The white matter maps were used to achieve this improved registration, but they were not incorporated into the statistical analysis. The GM maps of each subject were then spatially nonlinearly normalized to the population template, and Jacobian modulated. To bring the final analysis into standard MNI space, the population GM template was registered to the MNI space. All the individual GM maps residing in the population template space were then coregistered to MNI using the same affine transformation. Finally, these images were smoothed with an 8-mm full-width at half maximum Gaussian kernel.

STATISTICAL ANALYSIS

To estimate group difference in global cortical GMV, individual cortical GMVs were calculated as per the procedure of

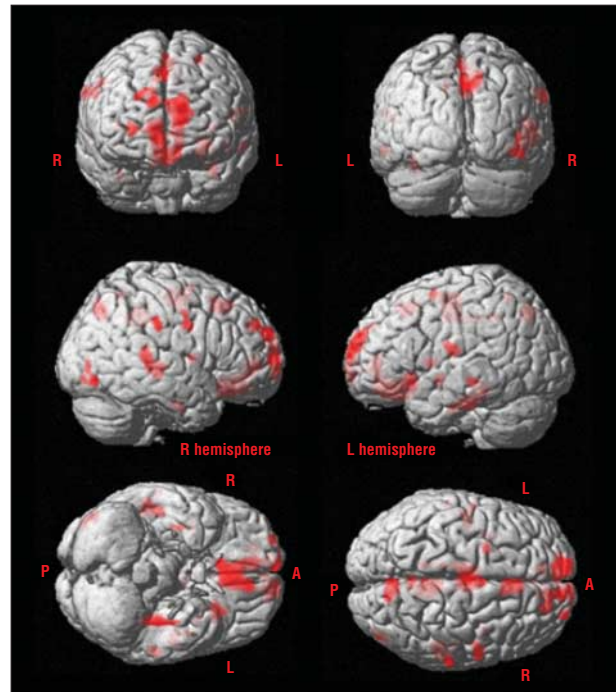


Figure 1. Regions of reduced gray matter volume in the 54 men with schizotypal personality disorder compared with the 54 male healthy control subjects. The gray matter volume reductions (red) in the schizotypal personality disorder compared with healthy control subjects are shown using the brain template in SPM software. These regions include widespread gray matter volume reductions in the bilateral frontal, temporal, and parietal regions (see Table 3 for specific coordinates). An uncorrected threshold of $P < .001$ with an extent threshold of 30 voxels was used for graphical reporting. All the regions shown with volume reductions also satisfied the false discovery rate criterion with a corrected $P < .05$ (Table 3). A indicates anterior; L, left; P, posterior; R, right.

Asami et al⁴⁹ and Whitford et al.⁵⁹ Consistent with our previous ROI study for male SPD,⁷ cortical GM was defined as all the cerebral GM, excluding the basal ganglia and thalamus. First, a binary image of cortical GM was created using the Wake Forest University PickAtlas toolkit.⁶⁰ This binary image was then convolved with all subjects' preprocessed GM images, and the volumes of cortical GM were calculated by summing the constituent smoothed modulated values. Finally, relative volumes were calculated using intracranial content (ICC) volumes measured by 3-dimensional slicer (www.slicer.org).

To investigate group differences in regional GMVs, the framework of the general linear model⁶¹ was implemented using an analysis of covariance model. A 2-sample t test was applied, with ICC volume as a confounding covariate to correct for global anatomical variations.⁶² The resulting set of voxel values for each contrast constituted a statistical parametric map of the t statistic, $SPM(t)$. The $SPM(t)$ values were displayed at an uncorrected threshold of $P < .001$, with an extent threshold of 30 voxels for graphical reporting. The purpose of the current whole-brain VBM analysis was to identify local regions contributing to the global (cortical) GMV reduction in the male subjects with SPD observed in our previous study.⁷ Therefore, consistent with previous VBM analyses,⁶³⁻⁶⁵ false discovery rate–corrected $P < .05^{66}$ was applied to maintain a balance between appropriate correction for multiple comparisons, while also minimizing the potential for type 2 errors. In the text and tables, we discuss only those results surviving correction at this level.

Table 4. Results of Correlation Analyses between Relative Volumes of the Global and ROI-defined Gray Matter Regions and Age

Anatomic Location	Males With SPD (n = 54)		Male HC Subjects (n = 54)		Age by Group Interaction	
	rho	P Value	rho	P Value	F ₁₀₆	P Value
Cortex	-.70	<.001 ^a	-.70	<.001 ^a	.74	.77
L superior temporal gyrus	-.43	.001 ^b	-.48	<.001 ^a	.65	.86
L middle temporal gyrus	-.39	.004 ^b	-.36	.007 ^b	.95	.54
L inferior temporal gyrus	-.41	.002 ^b	-.50	<.001 ^a	.57	.92
L fusiform gyrus	-.36	.009 ^b	-.46	.001 ^b	.43	.98
R superior temporal gyrus	-.39	.004 ^b	-.24	.08	1.12	.36
R middle temporal gyrus	-.43	.001 ^b	-.21	.09	1.14	.34
R fusiform gyrus	-.30	.03	-.37	.005 ^b	.76	.75
L superior frontal gyrus	-.44	.001 ^b	-.48	<.001 ^a	.77	.74
L middle frontal gyrus	-.48	<.001 ^a	-.57	<.001 ^a	.69	.83
L orbitofrontal cortex	-.49	<.001 ^a	-.48	<.001 ^a	.97	.51
L insula	-.51	<.001 ^a	-.65	<.001 ^a	.64	.87
L anterior cingulate gyrus	-.49	<.001 ^a	-.47	<.001 ^a	.81	.69
L posterior cingulate gyrus	-.52	<.001 ^a	-.48	<.001 ^a	.84	.66
R superior frontal gyrus	-.49	<.001 ^a	-.62	<.001 ^a	.54	.94
R middle frontal gyrus	-.41	.002 ^b	-.38	.004 ^b	.86	.64
R precentral gyrus	-.43	.001 ^b	-.38	.005 ^b	.63	.87
R orbitofrontal cortex	-.50	<.001 ^a	-.51	<.001 ^a	1.10	.38
R insula	-.42	.002 ^b	-.52	<.001 ^a	.94	.55
R anterior cingulate gyrus	-.47	<.001 ^a	-.47	<.001 ^a	.92	.56
R posterior cingulate gyrus	-.55	<.001 ^a	-.46	<.001 ^a	1.11	.37
L postcentral gyrus	-.39	.004 ^b	-.36	.007 ^b	.95	.54
L precuneus	-.47	<.001 ^a	-.43	.001 ^b	1.33	.20
R postcentral gyrus	-.47	<.001 ^a	-.44	.001 ^b	.84	.67
R precuneus	-.51	<.001 ^a	-.24	.084	1.11	.37
R supramarginal gyrus	-.45	.001 ^b	-.45	.001 ^b	.96	.52
R inferior occipital gyrus	-.41	.002 ^b	-.42	.002 ^b	.76	.75

Abbreviations: HC, healthy control; L, left; R, right; ROI, region of interest; SPD, schizotypal personality disorder.

^a P < .001.

^b P < .01.

CORRELATIONS BETWEEN VOLUMES AND AGE AND SYMPTOMS

As was done with the global cortical GMVs, the regional volumes were calculated as per the procedure of Asami et al⁴⁹ and Whitford et al.⁵⁹ First, the regions for which the VBM analysis showed significant GMV differences between the 2 groups were extracted as a gray-scale image using the save option on the SPM5 graphic user interface. Then the gray-scale image was transformed into a binary image, and this binary image was parcellated into gyri using the Wake Forest University PickAtlas toolkit⁶⁰ and SPM image calculator. These binary images were then convolved with all subjects' preprocessed GM images, and the volumes of each ROI-defined region were calculated by summing the constituent modulated values. Finally, relative volumes of each region were calculated using ICC volumes.

To assess relationships between age and relative volumes of cortical and each ROI-defined GM in the SPD and HC groups, Spearman correlations were conducted, with P < .05 as significant (2 tailed). In addition, age by group interaction analyses were conducted for the cortical and each ROI-defined GM regions using analysis of variance, with cutoff P values of .05, to investigate whether the SPD and HC groups had similar patterns of age-related GMV reductions.

To evaluate contributions of structural changes to behavioral abnormalities in SPD, we evaluated associations between the positive and negative symptom scores derived from SIS and each ROI-defined GMV with significant reductions in those with SPD vs HC subjects. Based on our previous work, we hypoth-

esized correlations with negative symptom scales. Results are reported as P < .05 (2 tailed).

RESULTS

There were no significant group differences in age, handedness, subject and parental SES, or IQ (Table 2).

GLOBAL CORTICAL GMV COMPARISON

There was a significant group difference in the global GMV; namely, the 54 neuroleptic-naive men with SPD showed smaller relative volume of the cortical GM compared with 54 matched male HC subjects (mean [SD], SPD: 42.0 [3.9], HC: 43.5 [3.1] [units are percentage of total ICC]; $t_{106} = 2.23$; P = .03).

VBM AND REGIONAL VOLUMES

Reflecting the result of group difference in the global GMV, the voxelwise whole-brain analysis showed significant widespread GMV reductions in the 54 men with SPD compared with the 54 HC subjects (false discovery rate-corrected P < .05). These regions included (1) temporal regions of the bilateral superior and middle temporal gyri, fusiform gyrus, and left inferior temporal gyrus; (2) frontal regions of the bilateral superior and middle fron-

tal gyri, orbitofrontal cortex, insula, cingulate gyrus (both anterior [subgenual and affective subregions] and posterior), and right precentral gyrus; and (3) parieto-occipital regions of bilateral postcentral gyrus, right supramarginal gyrus, precuneus, and inferior occipital gyrus. Although significant reductions were observed in the multiple cerebral regions, each reduction was small (typically <300 voxels), as shown in **Table 3**, **Figure 1**, and the eFigure. We found no region where the men with SPD had significantly larger volumes compared with the HC subjects.

There were no differences in regional GMVs between men with SPD with and without comorbid Axis I or Axis II disorders. Among the 11 subjects with SPD who also had first-degree relatives with psychosis, there was no significant GMV difference when compared with the participants with SPD without a family history of psychosis (eFigure).

CORRELATION ANALYSIS

Relationships Between Age and Global and Regional GMVs

The results are summarized in **Table 4** and **Figure 2**. The Spearman correlation analyses showed statistically significant negative relationships between age and relative volumes of the cortical GM, as well as most of the ROI-defined GM regions, in both those with SPD and HC participants. However, analysis of variance showed no age by group interactions.

Relationships Between Positive and Negative Symptom Scores and Regional GMVs

There were no significant correlations between patients' positive symptom scores and their GMV in any of the 26 ROIs. In contrast, as hypothesized, significant negative correlations were observed between the negative symptoms and the volume of 22 of the 26 ROIs in patients with SPD (**Table 5**, **Figure 3**, and the eFigure). This was unlikely to be a chance finding, given that the probability of obtaining 22 of 26 significant correlations with an alpha level of 0.05 was $P < 10^{-11}$ by the binomial theorem. Consequently, we then investigated the relationship between each of the 4 items on the SIS negative symptom scale and the regional volume of the 26 ROIs. As detailed in Table 5 and summarized here, significant negative correlations were observed between social isolation and 18 GM regions, restricted emotions and 11 regions, introversion and 13 regions, and sensitivity and 19 GM regions. The binomial distribution probability of 11 or more successes out of 26 trials with a probability of success of 0.05 was $P < 10^{-7}$, which remains significant for the 4 items after Bonferroni correction (eFigure).

COMMENT

This study demonstrated statistically significant GMV reductions in global and widespread brain regions in the 54 neuroleptic-naïve men with SPD compared with the

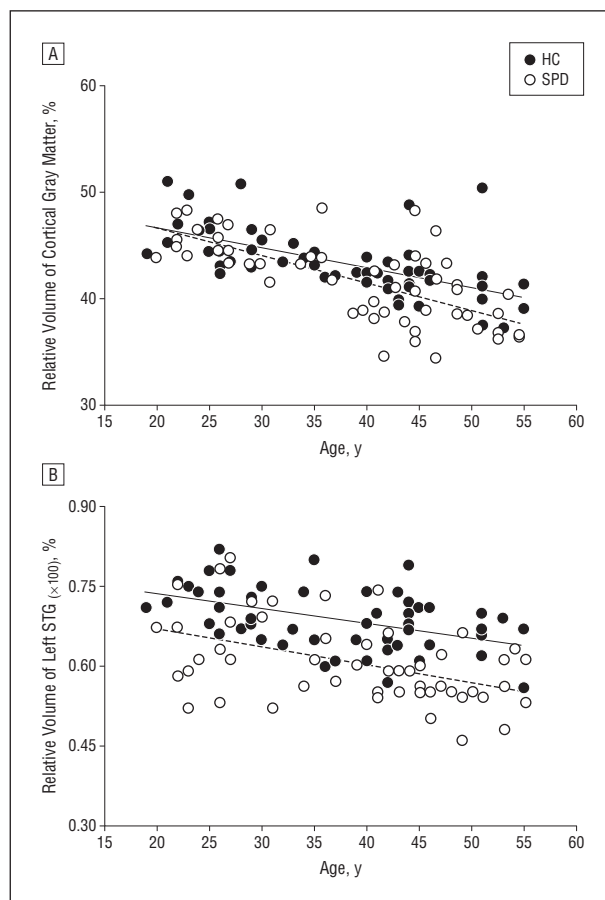


Figure 2. Relationships between the relative volumes of gray matter in the cortex (A) and left superior temporal gyrus (STG) (B) and age. The 54 men with schizotypal personality disorder (SPD) and 54 male healthy control (HC) subjects showed significant age-related gray matter volume reductions in the cortex (SPD: $\rho = -0.70$, $P < .001$; HC: $\rho = -0.70$, $P < .001$) and left STG (SPD: $\rho = -0.43$, $P = .001$; HC: $\rho = -0.48$, $P < .001$). However, there were no age by group interactions for these regions (cortex: $F_{106} = 0.74$, $P = .77$; left STG: $F_{106} = 0.65$, $P = .86$) (Table 4).

54 matched male HC subjects. To our knowledge, this is the first study to demonstrate such widespread GMV reductions in what is, we believe, the largest sample of neuroleptic-naïve men with SPD compared with HC subjects. Our extensive results, not observed in other VBM studies,^{20,21} may be owing to the improved sensitivity of the DARTEL method⁶⁷ and the careful group matching by age, sex, handedness, IQ, and the subject's own and parental SES. The global analysis finding of a significant GMV reduction in the cortex in the men with SPD was in line with our previous result, arrived at using a ROI method.⁷ In the voxelwise analysis, significant widespread GMV reductions were discovered in multiple cortical regions in the men with SPD compared with HC subjects. The size of each reduced region was comparatively small, in contrast to previous studies that have identified widespread volumetric GM reductions in patients with schizophrenia.^{49,68} Relative to women with SPD, the men with SPD showed GMV reductions in widespread local brain regions.

In the frontal lobe, volume reductions were confirmed in several frontal surface gyri: bilateral superior (mainly the medial region), middle, orbitofrontal, and

Table 5. Results of Correlation Analyses between Relative Volumes of the ROI-defined Gray Matter Regions and SIS Negative Symptom Scores in the Male Subjects With SPD

Anatomic Location	Negative Symptom (n = 21)		Social Isolation (n = 21)		Restricted Emotions (n = 21)		Introversion (n = 21)		Sensitivity (n = 21)	
	Rho	P Value	Rho	P Value	Rho	P Value	Rho	P Value	Rho	P Value
L superior temporal gyrus	-.68	.001 ^a	-.56	.003 ^a	-.49	.026 ^b	-.53	.01 ^b	-.72	<.001 ^a
L middle temporal gyrus	-.48	.03 ^b							-.53	.01 ^b
L inferior temporal gyrus	-.39	.08								
L fusiform gyrus	-.31	.17								
R superior temporal gyrus	-.43	.05								
R middle temporal gyrus	-.42	.06								
R fusiform gyrus	-.63	.002 ^a	-.53	.01 ^b			-.56	.008 ^a	-.68	.001 ^a
L superior frontal gyrus	-.67	.001 ^a	-.62	.003 ^a	-.47	.03 ^b	-.44	.05 ^b	-.62	.003 ^a
L middle frontal gyrus	-.56	.008 ^a	-.57	.007 ^a			-.43	.05 ^b		
L orbitofrontal cortex	-.71	<.001 ^a	-.70	<.001 ^a	-.44	.05 ^b	-.58	.006 ^a	-.63	.002 ^a
L insula	-.45	.04 ^b							-.61	.004 ^a
L anterior cingulate gyrus	-.58	.006 ^a	-.57	.008 ^a					-.60	.004 ^a
L posterior cingulate gyrus	-.53	.01 ^b			-.49	.02 ^b			-.63	.002 ^a
R superior frontal gyrus	-.63	.002 ^a	-.60	.004 ^a	-.45	.04 ^b			-.59	.005 ^a
R middle frontal gyrus	-.63	.002 ^a	-.65	.002 ^a			-.45	.04 ^b	-.50	.02 ^b
R precentral gyrus	-.66	.001 ^a	-.59	.005 ^a	-.51	.02 ^b	-.54	.01 ^b	-.61	.003 ^a
R orbitofrontal cortex	-.74	<.001 ^a	-.73	<.001 ^a	-.44	.05 ^b	-.61	.003 ^a	-.61	.003 ^a
R insula	-.47	.03 ^b							-.61	.004 ^b
R anterior cingulate gyrus	-.72	<.001 ^a	-.68	.001 ^a			-.65	.002 ^a	-.76	<.001 ^a
R posterior cingulate gyrus	-.64	.002 ^a	-.61	.004 ^a			-.47	.03 ^b	-.54	.01 ^b
L postcentral gyrus	-.61	.004 ^a	-.60	.008 ^a			-.51	.02 ^b	-.65	.001 ^a
L precuneus	-.55	.01 ^b	-.57	.007 ^a	-.47	.03 ^b				
R postcentral gyrus	-.61	.003 ^a	-.57	.007 ^a	-.56	.008 ^a	-.47	.03 ^b	-.58	.006 ^a
R precuneus	-.51	.02 ^b	-.52	.02 ^b	-.45	.04 ^b				
R supramarginal gyrus	-.60	.004 ^a	-.54	.01 ^b	-.53	.01 ^b	-.47	.03 ^b	-.46	.04 ^b
R inferior occipital gyrus	-.50	.02 ^b	-.53	.01 ^b					-.55	.01 ^b

Abbreviations: L, left; R, right; ROI, region of interest; SIS, Structured Interview for Schizotypy; SPD, schizotypal personality disorder.

^a $P < .01$.

^b $P < .05$.

right precentral. Previous studies have suggested that the volume of frontal regions, particularly Brodmann area 10, may be preserved in subjects with SPD.^{1,29} However, we found that men with SPD had GMV reductions at least in small regions in the medial frontal regions that were associated with the default mode network. Within frontolimbic regions, SPD evinced smaller GMVs in the bilateral insula, affective and subgenual subregions of the anterior cingulate gyrus, and posterior cingulate gyrus, similar to previous studies.^{8,20,21,29}

In the temporal lobe, the subjects with SPD showed volume reductions in the bilateral superior and middle temporal gyri, fusiform gyrus, and left inferior temporal gyrus compared with the HC subjects. The volume reduction in the STG is the most consistent finding in both the ROI^{9,26,31} and VBM^{8,21} analyses in SPD; volume reductions in the other temporal regions have also been reported previously.^{17,27} The fusiform gyrus is thought to be important in facial recognition,^{69,70} and our previous MRI-evoked-potential studies have demonstrated these structural-cognitive relationships in schizophrenia.^{71,72} Subjects with SPD are also thought to have deficits of facial recognition^{73,74}; the finding of fusiform gyrus volume reductions might be an anatomical substrate of poor facial recognition in SPD. Although our previous ROI did not demonstrate a difference in fusiform GMV,¹² the voxel by voxel approach, as well as larger subject sample, could detect small abnormalities in fusi-

form gyrus in SPD. In parietal and occipital lobes, this study provided new evidence that men with SPD showed GMV reductions in the bilateral postcentral gyrus, precuneus, right supramarginal gyrus, and inferior occipital gyrus compared with HC subjects. Lateral parietal regions are also believed to be related to the default mode network,⁷⁵ while the inferior occipital gyrus and fusiform gyrus are believed to be involved in the ventral stream of visual processing. Thus, it is feasible that abnormalities in this region might also be related with poor facial recognition in individuals with SPD.

While the neurobiological mechanism underlying the smaller GMVs in SPD is unknown, it is consistent with the finding of GMV reductions observed in schizophrenia, but without the postonset progression. Neuropathologic investigations indicate the basis of GMV reductions in schizophrenia is neuropil reduction.^{76,77} We have speculated that, in schizophrenia, there is a cortical circuit abnormality of deficient gamma-aminobutyric acidergic recurrent inhibition that may result in excitotoxic GMV loss. While this mechanism could promote progressive GMV reductions in schizophrenia, we speculate that SPD has a less severe alteration in circuitry, therefore shows no progressive GMV changes.

The absence of progression in SPD is supported by a recent longitudinal MRI study showing no progressive GMV changes in the STG after a 2.9-year interval in the patients with SPD compared with HC subjects.³¹ In our

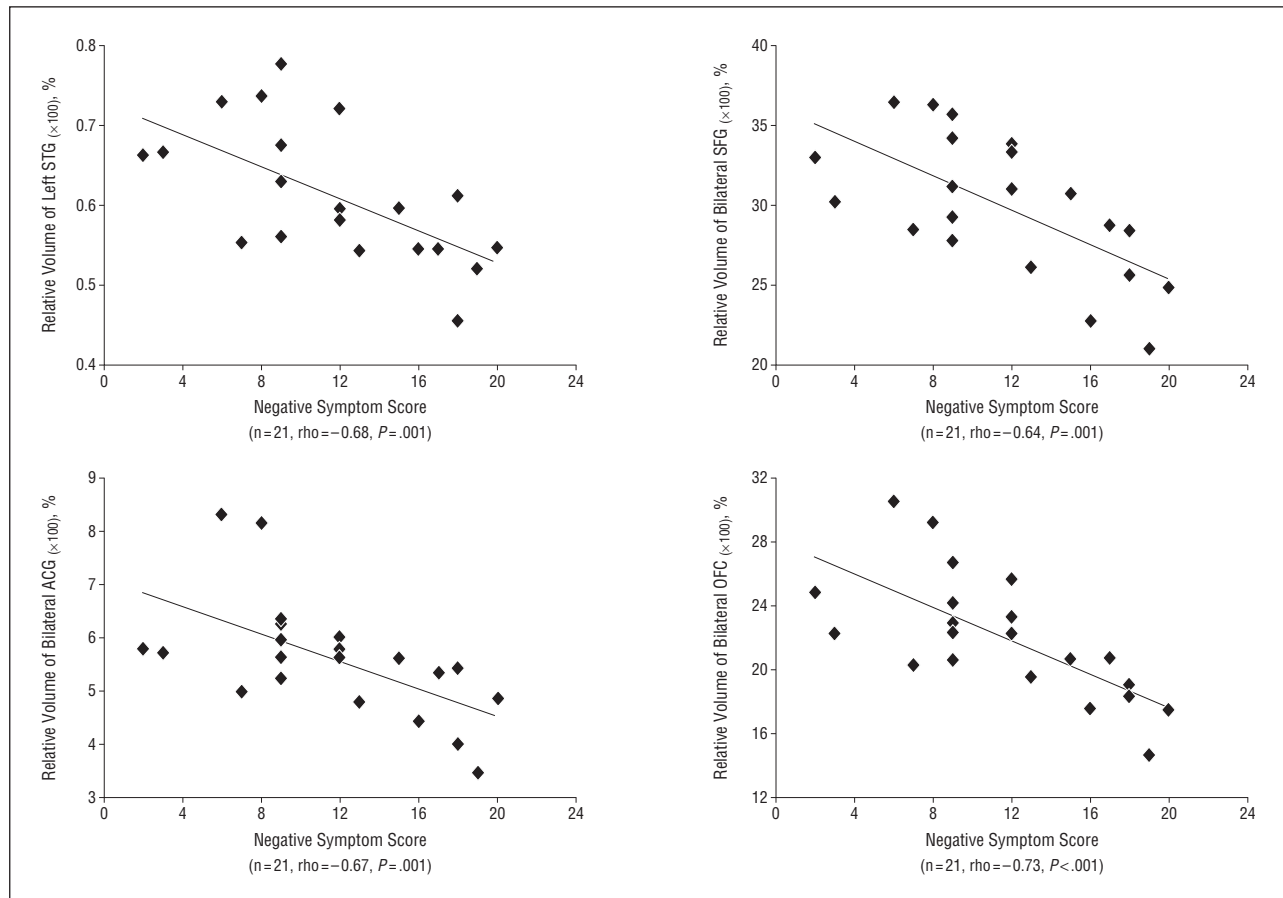


Figure 3. Correlation between regional gray matter volumes and Structured Interview for Schizotypy negative symptom scores (Table 5). ACG indicates anterior cingulate gyrus; OFC, orbitofrontal cortex; SFG, superior frontal gyrus; STG, superior temporal gyrus. The eFigure graphs this relationship for 21 additional regions.

data, the similar patterns of the age-related volume decline between the 2 groups may provide provisional evidence that, in contrast to patients with schizophrenia, male subjects with SPD do not show progressive loss on neocortical and almost all regional volumes,^{36,78,79} although it is necessary to confirm our findings in a longitudinal analysis. This caveat notwithstanding, our results point to an intriguing difference between schizophrenia and the spectrum disorder of SPD, a difference that invites further neurobiological study.

Finally, the correlation analyses, although tentative because of the number of correlations performed, demonstrated relationships between the local GMV reductions and behavioral abnormalities in the men with SPD. This confirmed our prediction of the association between negative symptoms and GMVs, a prediction generated because severe negative symptoms and fewer close friends are the most salient and prominent features of male SPD,⁴⁴ thus most likely to be associated with volumetric reductions. The association of reduced STG and fusiform gyrus volumes with negative symptoms is of interest in suggesting that deficits in early sensory processing may be related to negative symptoms. We noted also that previous studies have reported that negative symptoms are among the risk factors for social dysfunction, lower quality of life, and suicide in subjects with schizophrenia spectrum disorders.⁸⁰⁻⁸² Because studies have shown that individuals with SPD have worse social function and higher

frequency of attempted suicide,^{83,84} this association of negative symptoms and volumetric reduction provides insight into the pathophysiology of SPD.

To our knowledge, there are no previous MRI studies reporting widespread structure-negative symptom relationships in men with SPD. In previous studies—which either included only female subjects or combined male and female subjects with SPD—only a small number of regions have been demonstrated to have a relationship with negative symptoms. Examples of these regions include Brodmann area 22 (STG), showing the negative association with the interpersonal impairment score (which involved no close friends²⁹) and the caudate, showing the relationship with restricted emotions.¹⁵ In contrast, our current study revealed that the widespread GM regions—not limited local regions—were associated with the negative symptoms. These GM regions included frontal (mainly medial regions), frontolimbic, temporal, and parietal regions. These regions have been reported to have associations with negative symptoms in schizophrenia.⁸⁵⁻⁸⁸ We note the negative symptom—GM association did not definitively indicate that the GMV changes caused the negative symptoms because various extraneous factors (eg, social factors) could be causative of, or could potentiate, GMV changes. Finally, with respect to the GMV changes, because this never-medicated subject population excluded medication as a confound, we believe the observed GMV-

negative symptom association is important in providing information on the pathophysiology of schizophrenia spectrum disorders.

Of particular interest to the negative-symptom profile is its relationship to the default network and the location of SPD GM deficits. Recent functional MRI studies and fractionation analyses⁷⁵ suggest the core of the default network is the posterior cingulate and anterior medial prefrontal cortex, regions prominently represented in GM deficits in SPD. The fractionation analysis also identified default network components related to self in the present; the SPD regions with GMV deficits had a strong overlap with this aspect of the self, including the dorsomedial (anterior cingulate) prefrontal cortex, temporoparietal junction regions, and lateral temporal cortex, although the temporal pole did not show a deficit in SPD. These SPD regions also showed correlations with negative symptoms. Interestingly, functional MRI studies point to abnormalities in the resting-state default network in schizophrenia and, of particular note, in first-degree relatives of persons with schizophrenia.^{89,90} While there are many ways of conceptualizing the default network activity, one prominent theory is that it is related to social cognition because the brain regions in the default network and those active in social cognition overlap.⁹¹ Thus, we hypothesized that the prominent social deficits/negative symptoms shown in SPD may be, at least in part, related to GM abnormalities in the default network, regions that showed association with negative symptoms.

The present data indicate that contributions to negative symptoms likely also stem from a defective anatomic substrate in other, widespread brain regions in addition to the default network. Abnormalities in GMV in auditory, somatosensory, and fusiform regions were associated with negative symptoms, regions involved in sensory and language processing, and possibly interfering with social interaction through defective processing of social cues. Moreover, as reviewed by us in our article on orbitofrontal cortex in schizophrenia,⁹² abnormalities in this region have consistently been associated with social deficits, as we found in the SPD population.

The correlation analyses between negative symptoms and regional volumes, although hypothesis driven, should be considered exploratory owing to the number of correlations, therefore needing confirmation in future studies. A longitudinal study would offer stronger evidence that men with SPD do not (or do) have progressive GMV loss.

This study revealed volumetric GM reductions and symptom correlations in a large and neuroleptic-naive sample of single-sex (male) subjects with SPD. A correlation analysis indicated that the widespread GMV reductions were strongly associated with negative symptoms in men with SPD. These reductions also overlapped with the default network and the regions active in social cognition and perception of social cues, suggesting a possible anatomical substrate of negative symptoms. The absence of an age-related difference in GM change between those with SPD and HC subjects suggested that, unlike schizophrenia, there is no progressive volume reduction in SPD. Future longitudinal studies would be useful in confirming this important point of difference between the 2 disorders.

Submitted for Publication: June 6, 2012; final revision received June 6, 2012; accepted August 21, 2012.

Published Online: February 6, 2013. doi:10.1001/jamapsychiatry.2013.665

Author Affiliations: Laboratory of Neuroscience, Clinical Neuroscience Division, Department of Psychiatry, Boston Veterans Affairs Healthcare System, Brockton Division, Brockton (Drs Asami, Bouix, Dickey, Niznikiewicz, Shenton, Voglmaier, and McCarley); Psychiatry Neuroimaging Laboratory, Department of Psychiatry, Brigham and Women's Hospital, Boston (Drs Asami, Whitford, Bouix, Dickey, Niznikiewicz, and Shenton), Harvard Medical School, Massachusetts; and School of Psychology, University of New South Wales, Sydney, New South Wales, Australia (Dr Whitford).

Correspondence: Robert W. McCarley, MD, Department of Psychiatry, 116A, Boston Veterans Affairs Healthcare System, Brockton Division, Harvard Medical School, 940 Belmont St, Brockton, MA 02301 (robert_mccarley@hms.harvard.edu).

Conflict of Interest Disclosures: None reported.

Funding/Support: This study was supported by Merit Awards from the Department of Veterans Affairs (Drs Shenton and McCarley); a Research Enhancement Award (Drs Shenton and McCarley); a Middleton Award (Dr McCarley); a Veterans Affairs Advanced Career Development Award (Dr Dickey); and grants K05MH070047 and R01MH50740 (Dr Shenton) and R01 MH 40799 and R01 MH 052807 (Dr McCarley) from the National Institute of Mental Health. Dr Whitford's work is supported by an Overseas-Based Biomedical Training Fellowship from the National Health and Medical Research Council of Australia (NHMRC 520627), administered through the Melbourne Neuropsychiatry Centre at the University of Melbourne, Australia.

Online-Only Material: The eFigure is available at <http://www.jamapsych.com>.

Additional Contributions: We acknowledge Marie Fairbanks for her administrative support on this study.

REFERENCES

1. Siever LJ, Davis KL. The pathophysiology of schizophrenia disorders: perspectives from the spectrum. *Am J Psychiatry*. 2004;161(3):398-413.
2. Seeber K, Cadenhead KS. How does studying schizotypal personality disorder inform us about the prodrome of schizophrenia? *Curr Psychiatry Rep*. 2005; 7(1):41-50.
3. Raine A. Schizotypal personality: neurodevelopmental and psychosocial trajectories. *Annu Rev Clin Psychol*. 2006;2:291-326.
4. Pulay AJ, Stinson FS, Dawson DA, Goldstein RB, Chou SP, Huang B, Saha TD, Smith SM, Pickering RP, Ruan WJ, Hasin DS, Grant BF. Prevalence, correlates, disability, and comorbidity of DSM-IV schizotypal personality disorder: results from the wave 2 National Epidemiologic Survey on Alcohol and Related Conditions. *Prim Care Companion J Clin Psychiatry*. 2009;11(2):53-67.
5. McCarley RW, Wible CG, Frumin M, Hirayasu Y, Levitt JJ, Fischer IA, Shenton ME. MRI anatomy of schizophrenia. *Biol Psychiatry*. 1999;45(9):1099-1119.
6. Shenton ME, Dickey CC, Frumin M, McCarley RW. A review of MRI findings in schizophrenia. *Schizophr Res*. 2001;49(1-2):1-52.
7. Dickey CC, Shenton ME, Hirayasu Y, Fischer I, Voglmaier MM, Niznikiewicz MA, Seidman LJ, Fraone S, McCarley RW. Large CSF volume not attributable to ventricular volume in schizotypal personality disorder. *Am J Psychiatry*. 2000; 157(1):48-54.
8. Koo MS, Dickey CC, Park HJ, Kubicki M, Ji NY, Bouix S, Pohl KM, Levitt JJ, Nakamura M, Shenton ME, McCarley RW. Smaller neocortical gray matter and larger sulcal cerebrospinal fluid volumes in neuroleptic-naive women with schizotypal personality disorder. *Arch Gen Psychiatry*. 2006;63(10):1090-1100.

9. Dickey CC, McCarley RW, Voglmaier MM, Niznikiewicz MA, Seidman LJ, Hirayasu Y, Fischer I, Teh EK, Van Rhoads R, Jakab M, Kikinis R, Jolesz FA, Shenton ME. Schizotypal personality disorder and MRI abnormalities of temporal lobe gray matter. *Biol Psychiatry*. 1999;45(11):1393-1402.
10. Dickey CC, McCarley RW, Voglmaier MM, Frumin M, Niznikiewicz MA, Hirayasu Y, Fraone S, Seidman LJ, Shenton ME. Smaller left Heschl's gyrus volume in patients with schizotypal personality disorder. *Am J Psychiatry*. 2002;159(9):1521-1527.
11. Levitt JJ, McCarley RW, Dickey CC, Voglmaier MM, Niznikiewicz MA, Seidman LJ, Hirayasu Y, Ciszewski AA, Kikinis R, Jolesz FA, Shenton ME. MRI study of caudate nucleus volume and its cognitive correlates in neuroleptic-naïve patients with schizotypal personality disorder. *Am J Psychiatry*. 2002;159(7):1190-1197.
12. Dickey CC, McCarley RW, Voglmaier MM, Niznikiewicz MA, Seidman LJ, Frumin M, Toner S, Demeo S, Shenton ME. A MRI study of fusiform gyrus in schizotypal personality disorder. *Schizophr Res*. 2003;64(1):35-39.
13. Dickey CC, Morocz IA, Niznikiewicz MA, Voglmaier M, Toner S, Khan U, Dreu-sicke M, Yoo SS, Shenton ME, McCarley RW. Auditory processing abnormalities in schizotypal personality disorder: an fMRI experiment using tones of deviant pitch and duration. *Schizophr Res*. 2008;103(1-3):26-39.
14. Dickey CC, McCarley RW, Voglmaier MM, Niznikiewicz MA, Seidman LJ, Demeo S, Frumin M, Shenton ME. An MRI study of superior temporal gyrus volume in women with schizotypal personality disorder. *Am J Psychiatry*. 2003;160(12):2198-2201.
15. Koo MS, Levitt JJ, McCarley RW, Seidman LJ, Dickey CC, Niznikiewicz MA, Voglmaier MM, Zamani P, Long KR, Kim SS, Shenton ME. Reduction of caudate nucleus volumes in neuroleptic-naïve female subjects with schizotypal personality disorder. *Biol Psychiatry*. 2006;60(1):40-48.
16. Dickey CC, McCarley RW, Xu ML, Seidman LJ, Voglmaier MM, Niznikiewicz MA, Connor E, Shenton ME. MRI abnormalities of the hippocampus and cavum septi pellucidum in females with schizotypal personality disorder. *Schizophr Res*. 2007;89(1-3):49-58.
17. Downhill JE Jr, Buchsbaum MS, Hazlett EA, Barth S, Lees Roitman S, Nunn M, Lekarev O, Wei T, Shihabuddin L, Mitropoulou V, Silverman J, Siever LJ. Temporal lobe volume determined by magnetic resonance imaging in schizotypal personality disorder and schizophrenia. *Schizophr Res*. 2001;48(2-3):187-199.
18. Shihabuddin L, Buchsbaum MS, Hazlett EA, Silverman J, New A, Brickman AM, Mitropoulou V, Nunn M, Fleischman MB, Tang C, Siever LJ. Striatal size and relative glucose metabolic rate in schizotypal personality disorder and schizophrenia. *Arch Gen Psychiatry*. 2001;58(9):877-884.
19. Takahashi T, Suzuki M, Kawasaki Y, Kurokawa K, Hagino H, Yamashita I, Zhou SY, Nohara S, Nakamura K, Seto H, Kurachi M. Volumetric magnetic resonance imaging study of the anterior cingulate gyrus in schizotypal disorder. *Eur Arch Psychiatry Clin Neurosci*. 2002;252(6):268-277.
20. Yoneyama E, Matsui M, Kawasaki Y, Nohara S, Takahashi T, Hagino H, Suzuki M, Seto H, Kurachi M. Gray matter features of schizotypal disorder patients exhibiting the schizophrenia-related code types of the Minnesota Multiphasic Personality Inventory. *Acta Psychiatr Scand*. 2003;108(5):333-340.
21. Kawasaki Y, Suzuki M, Nohara S, Hagino H, Takahashi T, Matsui M, Yamashita I, Chitnis XA, McGuire PK, Seto H, Kurachi M. Structural brain differences in patients with schizophrenia and schizotypal disorder demonstrated by voxel-based morphometry. *Eur Arch Psychiatry Clin Neurosci*. 2004;254(6):406-414.
22. Takahashi T, Suzuki M, Zhou SY, Hagino H, Kawasaki Y, Yamashita I, Nohara S, Nakamura K, Seto H, Kurachi M. Lack of normal gender differences of the perigenual cingulate gyrus in schizophrenia spectrum disorders: a magnetic resonance imaging study. *Eur Arch Psychiatry Clin Neurosci*. 2004;254(5):273-280.
23. Haznedar MM, Buchsbaum MS, Hazlett EA, Shihabuddin L, New A, Siever LJ. Cingulate gyrus volume and metabolism in the schizophrenia spectrum. *Schizophr Res*. 2004;71(2-3):249-262.
24. Suzuki M, Zhou SY, Takahashi T, Hagino H, Kawasaki Y, Niu L, Matsui M, Seto H, Kurachi M. Differential contributions of prefrontal and temporolimbic pathology to mechanisms of psychosis. *Brain*. 2005;128(pt 9):2109-2122.
25. Takahashi T, Suzuki M, Zhou SY, Hagino H, Tanino R, Kawasaki Y, Nohara S, Yamashita I, Seto H, Kurachi M. Volumetric MRI study of the short and long insular cortices in schizophrenia spectrum disorders. *Psychiatry Res*. 2005;138(3):209-220.
26. Takahashi T, Suzuki M, Zhou SY, Tanino R, Hagino H, Kawasaki Y, Matsui M, Seto H, Kurachi M. Morphologic alterations of the parcellated superior temporal gyrus in schizophrenia spectrum. *Schizophr Res*. 2006;83(2-3):131-143.
27. Takahashi T, Suzuki M, Zhou SY, Tanino R, Hagino H, Niu L, Kawasaki Y, Seto H, Kurachi M. Temporal lobe gray matter in schizophrenia spectrum: a volumetric MRI study of the fusiform gyrus, parahippocampal gyrus, and middle and inferior temporal gyri. *Schizophr Res*. 2006;87(1-3):116-126.
28. Zhou SY, Suzuki M, Takahashi T, Hagino H, Kawasaki Y, Matsui M, Seto H, Kurachi M. Parietal lobe volume deficits in schizophrenia spectrum disorders. *Schizophr Res*. 2007;89(1-3):35-48.
29. Hazlett EA, Buchsbaum MS, Haznedar MM, Newmark R, Goldstein KE, Zelmanova Y, Glanton CF, Torosjan Y, New AS, Lo JN, Mitropoulou V, Siever LJ. Cortical gray and white matter volume in unmedicated schizotypal and schizophrenia patients. *Schizophr Res*. 2008;101(1-3):111-123.
30. Goldstein KE, Hazlett EA, New AS, Haznedar MM, Newmark RE, Zelmanova Y, Passarelli V, Weinstein SR, Canfield EL, Meyerson DA, Tang CY, Buchsbaum MS, Siever LJ. Smaller superior temporal gyrus volume specificity in schizotypal personality disorder. *Schizophr Res*. 2009;112(1-3):14-23.
31. Takahashi T, Suzuki M, Zhou SY, Tanino R, Nakamura K, Kawasaki Y, Seto H, Kurachi M. A follow-up MRI study of the superior temporal subregions in schizotypal disorder and first-episode schizophrenia. *Schizophr Res*. 2010;119(1-3):65-74.
32. Coffey CE, Lucke JF, Saxton JA, Ratcliff G, Unitas LJ, Billig B, Bryan RN. Sex differences in brain aging: a quantitative magnetic resonance imaging study. *Arch Neurol*. 1998;55(2):169-179.
33. Gur RE, Cowell P, Turetsky BI, Gallacher F, Cannon T, Bilker W, Gur RC. A follow-up magnetic resonance imaging study of schizophrenia: relationship of neuroanatomical changes to clinical and neurobehavioral measures. *Arch Gen Psychiatry*. 1998;55(2):145-152.
34. Wisniewski AB. Sexually-dimorphic patterns of cortical asymmetry, and the role for sex steroid hormones in determining cortical patterns of lateralization. *Psychoneuroendocrinology*. 1998;23(5):519-547.
35. Good CD, Johnsrude I, Ashburner J, Henson RN, Friston KJ, Frackowiak RS. Cerebral asymmetry and the effects of sex and handedness on brain structure: a voxel-based morphometric analysis of 465 normal adult human brains. *Neuroimage*. 2001;14(3):685-700.
36. Good CD, Johnsrude IS, Ashburner J, Henson RN, Friston KJ, Frackowiak RS. A voxel-based morphometric study of ageing in 465 normal adult human brains. *Neuroimage*. 2001;14(1, pt 1):21-36.
37. Frangou S, Chitnis X, Williams SC. Mapping IQ and gray matter density in healthy young people. *Neuroimage*. 2004;23(3):800-805.
38. Ivanovic DM, Leiva BP, Pérez HT, Olivares MG, Díaz NS, Urrutia MS, Almagià AF, Toro TD, Miller PT, Bosch EO, Larrain CG. Head size and intelligence, learning, nutritional status and brain development: head, IQ, learning, nutrition and brain. *Neuropsychologia*. 2004;42(8):1118-1131.
39. Lieberman JA, Tollefson GD, Charles C, Zipursky R, Sharma T, Kahn RS, Keefe RS, Green AI, Gur RE, McEvoy J, Perkins D, Hamer RM, Gu H, Tohen M; HGDH Study Group. Antipsychotic drug effects on brain morphology in first-episode psychosis. *Arch Gen Psychiatry*. 2005;62(4):361-370.
40. Nakamura M, Salisbury DF, Hirayasu Y, Bouix S, Pohl KM, Yoshida T, Koo MS, Shenton ME, McCarley RW. Neocortical gray matter volume in first-episode schizophrenia and first-episode affective psychosis: a cross-sectional and longitudinal MRI study. *Biol Psychiatry*. 2007;62(7):773-783.
41. Narr KL, Woods RP, Thompson PM, Szeszo P, Robinson D, Dimtcheva T, Gurbani M, Toga AW, Bilder RM. Relationships between IQ and regional cortical gray matter thickness in healthy adults. *Cereb Cortex*. 2007;17(9):2163-2171.
42. Dickey CC, McCarley RW, Shenton ME. The brain in schizotypal personality disorder: a review of structural MRI and CT findings. *Harv Rev Psychiatry*. 2002;10(1):1-15.
43. Konopaske GT, Dorph-Petersen KA, Pierri JN, Wu Q, Sampson AR, Lewis DA. Effect of chronic exposure to antipsychotic medication on cell numbers in the parietal cortex of macaque monkeys. *Neuropsychopharmacology*. 2007;32(6):1216-1223.
44. Dickey CC, McCarley RW, Niznikiewicz MA, Voglmaier MM, Seidman LJ, Kim S, Shenton ME. Clinical, cognitive, and social characteristics of a sample of neuroleptic-naïve persons with schizotypal personality disorder. *Schizophr Res*. 2005;78(2-3):297-308.
45. Voglmaier MM, Seidman LJ, Niznikiewicz MA, Dickey CC, Shenton ME, McCarley RW. A comparative profile analysis of neuropsychological function in men and women with schizotypal personality disorder. *Schizophr Res*. 2005;74(1):43-49.
46. Yücel M, Stuart GW, Maruff P, Velakoulis D, Crowe SF, Savage G, Pantelis C. Hemispheric and gender-related differences in the gross morphology of the anterior cingulate/paracingulate cortex in normal volunteers: an MRI morphometric study. *Cereb Cortex*. 2001;11(1):17-25.
47. Goldstein JM, Seidman LJ, O'Brien LM, Horton NJ, Kennedy DN, Makris N, Caviness VS Jr, Faraone SV, Tsuang MT. Impact of normal sexual dimorphisms on sex differences in structural brain abnormalities in schizophrenia assessed by magnetic resonance imaging. *Arch Gen Psychiatry*. 2002;59(2):154-164.
48. Gur RE, Kohler C, Turetsky BI, Siegel SJ, Kanes SJ, Bilker WB, Brennan AR, Gur RC. A sexually dimorphic ratio of orbitofrontal to amygdala volume is altered in schizophrenia. *Biol Psychiatry*. 2004;55(5):512-517.

49. Asami T, Bouix S, Whitford TJ, Shenton ME, Salisbury DF, McCarley RW. Longitudinal loss of gray matter volume in patients with first-episode schizophrenia: DARTEL automated analysis and ROI validation. *Neuroimage*. 2011;59(2):986-996.
50. Oldfield RC. The assessment and analysis of handedness: the Edinburgh Inventory. *Neuropsychologia*. 1971;9(1):97-113.
51. First MB, Spitzer RL, Gibbon M, Williams J. *Structured Clinical Interview for DSM-IV Axis I Disorders: Patient Edition (SCID-I/P), Version 2.0*. New York, NY: New York State Psychiatric Institute, Biomedical Research Dept; 1995.
52. First MB, Gibbon M, Spitzer RL, Williams J, Benjamin L. *Structured Clinical Interview for DSM-IV Personality Disorders (SCID-II): Interview and Questionnaire*. Washington, DC: American Psychiatric Press; 1997.
53. Hollingshead AB. *Four-Factor Index of Social Status*. New Haven, CT: Yale University, Department of Sociology; 1975.
54. Kendler KS, Lieberman JA, Walsh D. The Structured Interview for Schizotypy (SIS): a preliminary report. *Schizophr Bull*. 1989;15(4):559-571.
55. Kendler KS, Ochs AL, Gorman AM, Hewitt JK, Ross DE, Mirsky AF. The structure of schizotypy: a pilot multitrait twin study. *Psychiatry Res*. 1991;36(1):19-36.
56. Ashburner J, Friston KJ. Voxel-based morphometry: the methods. *Neuroimage*. 2000;11(6, pt 1):805-821.
57. Ashburner J, Friston KJ. Unified segmentation. *Neuroimage*. 2005;26(3):839-851.
58. Ashburner J. A fast diffeomorphic image registration algorithm. *Neuroimage*. 2007;38(1):95-113.
59. Whitford TJ, Farrow TF, Gomes L, Brennan J, Harris AW, Williams LM. Grey matter deficits and symptom profile in first episode schizophrenia. *Psychiatry Res*. 2005;139(3):229-238.
60. Maldjian JA, Laurienti PJ, Kraft RA, Burdette JH. An automated method for neuroanatomic and cytoarchitectonic atlas-based interrogation of fMRI data sets. *Neuroimage*. 2003;19(3):1233-1239.
61. Friston KJ, Holmes AP, Worsley KJ, Poline JP, Frith CD, Frackowiak RSJ. Statistical Parametric Maps in functional imaging: a general linear approach. *Hum Brain Mapp*. 1994;2(4):189-210. doi:10.1002/hbm.460020402.
62. Yamasue H, Kasai K, Iwanami A, Ohtani T, Yamada H, Abe O, Kuroki N, Fukuda R, Tochigi M, Furukawa S, Sadamatsu M, Sasaki T, Aoki S, Ohtomo K, Asukai N, Kato N. Voxel-based analysis of MRI reveals anterior cingulate gray-matter volume reduction in posttraumatic stress disorder due to terrorism. *Proc Natl Acad Sci U S A*. 2003;100(15):9039-9043.
63. Gurling HM, Critchley H, Datta SR, McQuillin A, Blaveri E, Thirumalai S, Pimm J, Krasucki R, Kalsi G, Quesed D, Lawrence J, Bass N, Choudhury K, Puri V, O'Daly O, Curtis D, Blackwood D, Muir W, Malhotra AK, Buchanan RW, Good CD, Frackowiak RS, Dolan RJ. Genetic association and brain morphology studies and the chromosome 8p22 pericentriolar material 1 (PCMT1) gene in susceptibility to schizophrenia. *Arch Gen Psychiatry*. 2006;63(8):844-854.
64. Zarei M, Mataix-Cols D, Heyman I, Hough M, Doherty J, Burge L, Winmill L, Nijhawan S, Matthews PM, James A. Changes in gray matter volume and white matter microstructure in adolescents with obsessive-compulsive disorder. *Biol Psychiatry*. 2011;70(11):1083-1090.
65. Grothe M, Heinsen H, Teipel SJ. Atrophy of the cholinergic basal forebrain over the adult age range and in early stages of Alzheimer's disease. *Biol Psychiatry*. 2011;71(9):805-813.
66. Genovese CR, Lazar NA, Nichols T. Thresholding of statistical maps in functional neuroimaging using the false discovery rate. *Neuroimage*. 2002;15(4):870-878.
67. Tahmasebi AM, Abolmaesumi P, Zheng ZZ, Munhall KG, Johnsrude IS. Reducing inter-subject anatomical variation: effect of normalization method on sensitivity of functional magnetic resonance imaging data analysis in auditory cortex and the superior temporal region. *Neuroimage*. 2009;47(4):1522-1531.
68. Whitford TJ, Grieve SM, Farrow TF, Gomes L, Brennan J, Harris AW, Gordon E, Williams LM. Progressive grey matter atrophy over the first 2-3 years of illness in first-episode schizophrenia: a tensor-based morphometry study. *Neuroimage*. 2006;32(2):511-519.
69. George N, Dolan RJ, Fink GR, Baylis GC, Russell C, Driver J. Contrast polarity and face recognition in the human fusiform gyrus. *Nat Neurosci*. 1999;2(6):574-580.
70. Grill-Spector K, Knouf N, Kanwisher N. The fusiform face area subserves face perception, not generic within-category identification. *Nat Neurosci*. 2004;7(5):555-562.
71. Onitsuka T, Shenton ME, Kasai K, Nestor PG, Toner SK, Kikinis R, Jolesz FA, McCarley RW. Fusiform gyrus volume reduction and facial recognition in chronic schizophrenia. *Arch Gen Psychiatry*. 2003;60(4):349-355.
72. Onitsuka T, Niznikiewicz MA, Spencer KM, Frumin M, Kuroki N, Lucia LC, Shenton ME, McCarley RW. Functional and structural deficits in brain regions subserving face perception in schizophrenia. *Am J Psychiatry*. 2006;163(3):455-462.
73. Poreh AM, Whitman RD, Weber M, Ross T. Facial recognition in hypothetically schizotypic college students: the role of generalized poor performance. *J Nerv Ment Dis*. 1994;182(9):503-507.
74. Mikhailova ES, Vladimirova TV, Iznak AF, Tsulukovskaya EJ, Sushko NV. Abnormal recognition of facial expression of emotions in depressed patients with major depression disorder and schizotypal personality disorder. *Biol Psychiatry*. 1996;40(8):697-705.
75. Andrews-Hanna JR, Reidler JS, Sepulcre J, Poulin R, Buckner RL. Functional-anatomic fractionation of the brain's default network. *Neuron*. 2010;65(4):550-562.
76. Seimon LD, Goldman-Rakic PS. The reduced neuropil hypothesis: a circuit based model of schizophrenia. *Biol Psychiatry*. 1999;45(1):17-25.
77. Sweet RA, Pierri JN, Auh S, Sampson AR, Lewis DA. Reduced pyramidal cell somal volume in auditory association cortex of subjects with schizophrenia. *Neuropsychopharmacology*. 2003;28(3):599-609.
78. Hulshoff Pol HE, Schnack HG, Bertens MG, van Haren NE, van der Tweel I, Staal WG, Baaré WF, Kahn RS. Volume changes in gray matter in patients with schizophrenia. *Am J Psychiatry*. 2002;159(2):244-250.
79. Bose SK, Mackinnon T, Mehta MA, Turkheimer FE, Howes OD, Selvaraj S, Kempston MJ, Grasby PM. The effect of ageing on grey and white matter reductions in schizophrenia. *Schizophr Res*. 2009;112(1-3):7-13.
80. Fenton WS, McGlashan TH, Victor BJ, Blyler CR. Symptoms, subtype, and suicidality in patients with schizophrenia spectrum disorders. *Am J Psychiatry*. 1997;154(2):199-204.
81. Pompili M, Amador XF, Girardi P, Harkavy-Friedman J, Harrow M, Kaplan K, Krausz M, Lester D, Meltzer HY, Modestin J, Montross LP, Mortensen PB, Munk-Jørgensen P, Nielsen J, Nordentoft M, Saarnen PI, Zisook S, Wilson ST, Tarelli R. Suicide risk in schizophrenia: learning from the past to change the future. *Ann Gen Psychiatry*. 2007;6:10.
82. Cohen AS, Davis TE III. Quality of life across the schizotypy spectrum: findings from a large nonclinical adult sample. *Compr Psychiatry*. 2009;50(5):408-414.
83. Bornstein RF, Klein DN, Mallon JC, Slater JF. Schizotypal personality disorder in an outpatient population: incidence and clinical characteristics. *J Clin Psychol*. 1988;44(3):322-325.
84. Cramer V, Torgersen S, Kringlen E. Socio-demographic conditions, subjective somatic health, Axis I disorders and personality disorders in the common population: the relationship to quality of life. *J Pers Disord*. 2007;21(5):552-567.
85. Mathalon DH, Sullivan EV, Lim KO, Pfefferbaum A. Progressive brain volume changes and the clinical course of schizophrenia in men: a longitudinal magnetic resonance imaging study. *Arch Gen Psychiatry*. 2001;58(2):148-157.
86. Wible CG, Anderson J, Shenton ME, Kricun A, Hirayasu Y, Tanaka S, Levitt JJ, O'Donnell BF, Kikinis R, Jolesz FA, McCarley RW. Prefrontal cortex, negative symptoms, and schizophrenia: an MRI study. *Psychiatry Res*. 2001;108(2):65-78.
87. Koo MS, Levitt JJ, Salisbury DF, Nakamura M, Shenton ME, McCarley RW. A cross-sectional and longitudinal magnetic resonance imaging study of cingulate gyrus gray matter volume abnormalities in first-episode schizophrenia and first-episode affective psychosis. *Arch Gen Psychiatry*. 2008;65(7):746-760.
88. Takahashi T, Wood SJ, Soulsby B, McGorry PD, Tanino R, Suzuki M, Velakoulis D, Pantelis C. Follow-up MRI study of the insular cortex in first-episode psychosis and chronic schizophrenia. *Schizophr Res*. 2009;108(1-3):49-56.
89. Garrity AG, Pearlson GD, McKiernan K, Lloyd D, Kiehl KA, Calhoun VD. Aberrant "default mode" functional connectivity in schizophrenia. *Am J Psychiatry*. 2007;164(3):450-457.
90. Whitfield-Gabrieli S, Thermenos HW, Milanovic S, Tsuang MT, Faraone SV, McCarley RW, Shenton ME, Green AI, Nieto-Castanon A, LaViolette P, Wojcik J, Gabrieli JD, Seidman LJ. Hyperactivity and hyperconnectivity of the default network in schizophrenia and in first-degree relatives of persons with schizophrenia. *Proc Natl Acad Sci U S A*. 2009;106(4):1279-1284.
91. Schilbach L, Eickhoff SB, Rotarska-Jagiela A, Fink GR, Vogeley K. Minds at rest? social cognition as the default mode of cognizing and its putative relationship to the "default system" of the brain. *Conscious Cogn*. 2008;17(2):457-467.
92. Nakamura M, Nestor PG, Levitt JJ, Cohen AS, Kawashima T, Shenton ME, McCarley RW. Orbitofrontal volume deficit in schizophrenia and thought disorder. *Brain*. 2008;131(pt 1):180-195.