

Volumetric Measure of the Frontal and Temporal Lobe Regions in Schizophrenia

Relationship to Negative Symptoms

Michael Sanfilipo, MS; Todd Lafargue, MD; Henry Rusinek, PhD; Luigi Arena, MD, PhD; Celia Loneragan, MA; Andrew Lautin, MD; Deborah Feiner, BA; John Rotrosen, MD; Adam Wolkin, MD

Background: Previous research has provided evidence for brain abnormalities in schizophrenia, but their relationship to specific clinical symptoms and syndromes remains unclear.

Methods: With an all-male demographically similar sample of 53 schizophrenic patients and 29 normal control subjects, cerebral gray and white matter volumes (adjusted for intracranial volume and age) were determined for regions in the prefrontal lobe and in the superficial and mesial temporal lobe using T1-weighted magnetic resonance imaging with 2.8-mm coronal slices.

Results: As a group, schizophrenic patients had widespread bilateral decrements in gray matter in the prefrontal (7.4%) and temporal lobe regions (8.9%), but not in white matter in these regions. In the temporal lobe, gray matter reductions were found bilaterally in the su-

perior temporal gyrus (6.0%), but not in the hippocampus and parahippocampus. While there were no overall group differences in white matter volumes, widespread decrements in prefrontal white matter in schizophrenic patients ($n = 53$) were related to higher levels of negative symptoms (partial $r[49] = -0.42, P = .002$), as measured by the Scale for the Assessment of Negative Symptoms. A post hoc analysis revealed that schizophrenic patients with high negative symptoms had generalized prefrontal white matter reductions (11.4%) that were most severe in the orbitofrontal subregion (15.1%).

Conclusions: These results suggest that gray matter deficits may be a fairly common structural abnormality of schizophrenia, whereas reductions in prefrontal white matter may be associated with schizophrenic negative symptoms.

Arch Gen Psychiatry. 2000;57:471-480

From the Psychiatry Service (Mr Sanfilipo, Ms Loneragan, and Drs Lautin, Rotrosen, and Wolkin) and the Radiology Service and Magnetic Resonance Imaging Section (Dr Arena), New York Veterans Affairs Medical Center, Departments of Psychiatry (Mr Sanfilipo, Dr Lafargue, Mss Loneragan and Feiner, and Drs Lautin, Rotrosen, and Wolkin) and Radiology (Drs Rusinek and Arena), New York University School of Medicine and the Departments of Psychiatry (Dr Lafargue) and Radiology (Dr Arena), Bellevue Hospital Center, New York, NY.

MAGNETIC resonance (MR) imaging research has shown that schizophrenia is associated with slight decreases in total brain volume,¹ modest reductions in brain volume during the course of the illness,^{2,3} and fairly widespread⁴⁻⁷ or regional (viz, frontal and temporal) decrements in cerebral gray matter volume,⁸⁻¹⁰ even in first-episode schizophrenic patients.^{11,12} However, MR imaging findings for cerebral white matter volume in schizophrenia have been mixed. Most studies⁴⁻⁸ have found no differences in white matter volume between schizophrenic patients and normal control subjects, but some have reported white matter reductions in schizophrenia.¹³⁻¹⁵ Yet, there is additional intriguing evidence of white matter abnormalities in schizophrenia, such as disruption of cerebral white matter connections,^{16,17} smaller corpus callosum size,^{18,19} inward displacement of white matter within cerebral laminar architecture,²⁰⁻²² and patchy reductions in white matter tracts.²³

While the evidence for structural abnormalities in schizophrenia is incontrovertible, these abnormalities are not pathognomonic markers of the disorder (considerable overlap exists in various brain measures between schizophrenic patients and normal controls). The exact meaning of these abnormalities also remains uncertain for etiologic origins, pathophysiological mechanisms, and the expression of clinical symptoms. In addition, attempts to relate regional measures to clinical symptoms of the illness or to schizophrenic subtypes have provided inconsistent and widely varying results. While there is some MR imaging evidence for an association between positive symptoms and structural gray matter measures in the temporal lobe,⁸⁻¹⁰ it has not been supported in all studies. Moreover, very few structural relationships have been reported for negative symptoms,²⁴ especially in studies that segment gray and white matter.

In our study, we used high-resolution whole-brain MR imaging scans to analyze gray and white matter volumes in the

SUBJECTS AND METHODS

SUBJECTS

Fifty-three male schizophrenic patients and 29 male normal controls, all recruited from the New York Veterans Affairs Medical Center, New York, gave informed consent to participate in the study. The study procedures and consent forms used received approval from the Institutional Review Boards at the New York Veterans Affairs Medical Center and New York University Medical Center. Data from this sample have been included in part elsewhere in our reports on the cerebral ventricular system²⁷ and whole-brain image averaging.²³

Schizophrenic patients were recruited from inpatient and outpatient hospital facilities, and all met *DSM-III-R* criteria for schizophrenia as diagnosed by 2 psychiatrists (T.L. and A.W.) and assessment using the *Structured Clinical Interview for DSM-III-R Patient Edition*.²⁸ Schizophrenic patients with current substance abuse (ie, last use ≤ 3 months) or any history of substance dependence (past or present, excluding caffeine and nicotine) were excluded from the study. Eighteen schizophrenic patients with a history of substance abuse (ie, last drug abuse > 3 months) were included in the study (**Table 1**).

Normal control candidates, responding to a posted hospital announcement, received an initial telephone screening²⁹ and then an evaluation interview, which included the *Structured Clinical Interview for DSM-III-R Non-Patient Edition*.³⁰ Normal controls were excluded from the study if they had a first-degree familial history of psychiatric illness, an educational level higher than 16 years, or any current or past *DSM-III-R* psychiatric or substance abuse diagnoses (excluding caffeine dependence, nicotine dependence, and prior isolated episodes of depression).

Additional exclusion criteria for all subjects included mental retardation, aged older than 50 years, any contraindications for MR imaging, any current medical illness, or any history of head trauma, loss of consciousness, seizures, neurologic disease, or central nervous system infections. Finally, 3 subjects (2 controls and 1 patient) were excluded from the study because their MR imaging scan uncovered clear evidence of a pathologic brain condition as assessed by a clinical radiologist (L.A.).

All schizophrenic patients were receiving neuroleptic medication (Table 1) at the time of the MR imaging scan for treatment of either acute or chronic decompensation of schizophrenia. Psychiatric ratings (Table 1), including the Clinical Global Impressions Scale,³¹ Brief Psychiatric Rating Scale,³²

the Scale for the Assessment of Negative Symptoms (SANS),³³ the Simpson-Angus Scale (for extrapyramidal symptoms),³⁴ and the Abnormal Involuntary Movement Scale,³⁵ were obtained when patients were clinically judged to have had an optimal response to medication, which ranged from the day of to 12 weeks after the MR imaging scan. The purpose of obtaining clinical ratings at the time of optimal medication response was to provide a more uniform comparison of psychopathology across patients who initially were seen at different stages of symptom severity.

MR IMAGING SCANS

Magnetic resonance imaging scans were obtained with a 1.5-T scanner (Vista HPQ; Pickar, Cleveland, Ohio). Coronal T1-weighted images of the whole brain (perpendicular to the sylvian fissure) were acquired with a high-resolution, 3-dimensional, radiofrequency-spoiled gradient echo technique (repetition time = 33 milliseconds, echo time = 11 milliseconds, flip angle = 35°, 256 × 256-pixel acquisition matrix, 85 slices, slice thickness = 2.8 mm, no slice gap, field of view = 24 cm, and 1 signal average), which provided an excellent contrast between gray and white tissue with a short acquisition time. To determine the degree of whole-brain alignment uniformity across cases, coronal images were reformatted in the sagittal plane and, on the midsagittal slice, the angle between the horizontal and the line through the anterior and posterior commissures was measured. The mean (\pm SD) angle was 17.9° \pm 5.3° (average error = 4.1°, reference range, 5.0°-32.0°) and was not different for the schizophrenic patients (18.5° \pm 5.5°) or the normal controls (17.4° \pm 5.1°).

For estimation of intracranial volume (ICV) and clinical screening of brain pathology, T2-weighted and proton density-weighted axial images of the whole brain were acquired with a 2 echo spin-echo pulse sequence (repetition time = 2400 milliseconds, echo time = 20 and 80 milliseconds, flip angle = 90°, 165 × 256-pixel acquisition matrix, 20 slices, slice thickness = 5 mm, slice gap = 1 mm, field of view = 22 cm, and 1 signal average). One individual (T.L.) performed ICV estimations for all cases by demarcating the outer boundary of the brain for each slice using automated edge-detection contour tracing. Estimations of ICV were limited to slices that ranged from the vertex to the red nuclei, as slices below could not be reliably measured.

MR IMAGING SCAN ANALYSIS

Magnetic resonance imaging scans were loaded on a personal computer system workstation (Sun, Mountain View,

prefrontal and temporal lobe regions in a large sample of schizophrenic patients and normal controls to investigate the relationship between brain structure and schizophrenic symptoms. We were especially interested in the possible relationship of structural abnormalities with negative symptoms, given our previous functional imaging work showing that negative symptom severity is related to resting frontal metabolism²⁵ and to changes in cerebral metabolism associated with haloperidol treatment.²⁶ In the current study, we replicate prior research revealing fairly widespread deficits in gray, but not white, matter volumes in schizophrenic patients; however, we

also report that negative symptoms are related to white matter reductions in the prefrontal region.

RESULTS

DEMOGRAPHIC VARIABLE ANALYSES

In this all-male sample, there were no differences in age, race, and handedness⁴¹ between the schizophrenic and normal control groups (Table 1). These 2 groups, however, had significantly different educational levels, even though the average difference was only 1.1 years. While

Calif), and MIDAS³⁶ (locally developed, New York, NY) was used for segmentation of tissue compartments and acquisition of regions. Images were displayed in $\times 3$ magnification to improve region-of-interest sampling technique. To avoid bias, all cases were blind-coded for diagnosis and hemisphere (half of the cases were mirror-reversed).

Tissue segmentation and acquisition of regions was performed on the coronal T1-weighted images and included the following steps: (1) signal intensity values for "pure" cerebrospinal fluid, gray matter, and white matter were sampled casewise by 1 person (T.L.) from unambiguous anatomical regions in rostral, central, and posterior portions of the brain, in areas where partial volume effects were minimal; (2) predicted signal intensity values for gray and white matter for each slice of each case were calculated using separate linear regression equations (based on pure tissue samplings and slice position), to correct for anteroposterior drift in signal intensity values due to magnetic field inhomogeneities, head coil artifact, and subject-induced distortions; (3) the windowing threshold value for the gray vs white tissue compartments was defined as the midpoint between inhomogeneity-corrected signal intensity values for gray and white matter for each slice; (4) 1 individual (A.W.) identified the neuroanatomical landmarks used to define the anterior and posterior extent of regions; (5) to obtain regions-of-interest, rough and overinclusive outlines encircling regions were manually drawn by separate single raters for the prefrontal (T.L.) and temporal (C.L.) lobe regions, and the resulting tracings were intersected with the inhomogeneity-corrected signal intensity threshold value for gray or white matter for that slice; and (6) planar regions-of-interest measurements were summed across the anteroposterior extent of each region to yield final volumetric regions. Our method has the advantages of minimized partial volume effects,³⁷ accurate white-gray segmentation volumes,^{37,38} excellent interscan reliability,³⁸ and controlling for signal inhomogeneity artifact.³⁷

The neuroanatomical landmarks used in our study to delineate the amygdala, hippocampus, parahippocampus, and superior temporal gyrus were identical to those used in the study by Shenton et al.³⁹ In addition, volumes were acquired for "whole" temporal gray and white matter regions, which subsumed temporal lobe tissue between the anterior and posterior boundaries for the above regions.

Subdivision of the prefrontal region was based on a geometric "pie-sector" approach rather than an anatomical one, given the difficulty in identifying specific gyri, the non-trivial differences in intersubject cerebral shape, and the anatomical variability in the correspondence between location and function. After identifying the slice anterior to the genu

of the corpus callosum, prefrontal regions-of-interest were defined for that slice plus the 7 anterior adjacent slices (total thickness of 2.2 cm) for all study participants. For each of the 8 prefrontal slices, MR imaging software was used to demarcate the cortical hemispheric perimeter, calculate the geometric centers of the left and right hemispheres, and create 6 contiguous and nonoverlapping 60°-pie sectors for each hemisphere that are positioned relative to the horizontal ray extending medially from the hemispheric center (thus creating superior and inferior sets of medial, central, and lateral sectors; **Figure**, inset). These individual sectors, combined across all 8 prefrontal slices, result in 6 three-dimensional, wedge-shaped prefrontal subregions for each hemisphere extending in the anteroposterior plane. These subregions are consistent in geometric location within and between subjects and have very high reliability.

Based on the method described earlier, the intrarater reliability for each region was determined using the same rater on repeated identical cases ($n = 5$). Due to poor intraclass correlations for the amygdala region, the results for the amygdala were deemed unreliable and were excluded from this study. For the remaining regions, the average intraclass correlation coefficients were greater than 0.99 for the prefrontal subregions (all $\text{ricc}[4]$, >0.99 , $P < .000$) and 0.92 for the temporal regions (all $\text{ricc}[4]$, >0.86 , $P < .01$).

STATISTICAL ANALYSES

All statistical analyses had a 2-tailed α level of .05 for significance, unless otherwise stated. For the brain regions, the analyses were performed on absolute regional white and gray matter volumes after adjustment for ICV and age. Even though the schizophrenic and normal control groups were demographically similar for age, regional white and gray matter volumes were, nevertheless, adjusted for age to reduce variance in the analyses, given evidence here (see "Results" section) and elsewhere⁴⁰ of a decrease in gray matter volume with normal aging.

An overall 3-factor group \times hemisphere \times region repeated measures analysis of covariance (ANCOVA) design adjusting for ICV and age was used as an omnibus statistic in separate analyses for the prefrontal gray, prefrontal white, and temporal gray matter regions. The omnibus ANCOVA models were followed up with group \times hemisphere ANCOVA designs for each of the individual regions (adjusting for ICV and age). In addition, separate group \times hemisphere ANCOVA models (adjusting for ICV and age) were used to analyze the whole temporal gray and white matter regions.

head circumference also was not different for these 2 groups, schizophrenic patients had a smaller ICV than normal controls.^{1,42} Moreover, schizophrenic patients with and without a history of any substance abuse did not significantly differ for any of the prefrontal and temporal regional volumes (data not shown).

Partial correlations ($r_p[df]$) for the entire sample (adjusted for ICV) revealed that age was inversely related to total gray matter volume in the prefrontal ($r_p[79] = -0.41$, $P < .001$) and temporal regions ($r_p[79] = -0.34$, $P = .002$), but was unrelated to total white matter volume in the prefrontal ($r_p[79] = 0.10$, $P = .39$) and temporal lobe re-

gions ($r_p[79] = 0.13$, $P = .25$). For the schizophrenic group, total gray and white matter volume in the prefrontal and temporal regions (after adjusting for ICV) was not significantly related to the number of years ill, age of illness onset, and number of hospitalizations (data not shown).

GROUP-REGIONAL VOLUME ANALYSES

In the omnibus group \times hemisphere \times region ANCOVA models (**Table 2**), the main effect of group was statistically significant for prefrontal gray matter volume ($P = .003$), but was not significant for temporal gray

Table 1. Demographic and Clinical Characteristics of the 53 Schizophrenic Patients and the 29 Normal Controls*

Variable	Schizophrenic Patients	Normal Controls	Statistic	P
Age, y	38.7 ± 5.5	35.8 ± 8.7	$U_{(1,N=82)} = 640.5$.21
No. of years of education†	13.1 ± 1.8	14.2 ± 1.8	$t_{(78)} = 2.48$.02
Race, No. of subjects				
White	13	15	$\chi^2_{(4,N=82)} = 7.27$.12
Black	24	10		
Hispanic	13	4		
Asian	1	0		
Other	2	0		
Handedness‡				
Right	46	27	$\chi^2_{(1,N=82)} = 0.76$.38
Left or mixed	7	2		
Head circumference, cm	58.7 ± 2.2	58.6 ± 1.8	$t_{(76)} = 0.20$.84
Intracranial volume, cc§	861.9 ± 91.6	905.3 ± 71.5	$t_{(80)} = 2.21$.03
Patient status, No. of subjects				
Inpatients	26	
Outpatients	27	
Schizophrenia subtype, No. of subjects				
Undifferentiated	21	
Paranoid	32	
No. of years ill	14.4 ± 6.8	
Age of illness onset, y	24.3 ± 4.1	
No. of hospitalizations	12.1 ± 13.8	
No. of patients receiving neuroleptic (dose range)				
Chlorpromazine (400-1200 mg/d)	6	
Clozapine (600 mg/d)	1	
Fluphenazine (15-45 mg/d)	4	
Fluphenazine decanoate (12.5-62.5 mg/2 wk)	9	
Haloperidol (1-35 mg/d)	12	
Haloperidol decanoate (50-300 mg/2 wk)	4	
Mesoridazine (150-300 mg/d)	2	
Olanzapine (20 mg/d)	1	
Perphenazine (16-80 mg/d)	7	
Risperidone (6 mg/d)	1	
Thioridazine (75-500 mg/d)	4	
Trifluoperazine (5-20 mg/d)	2	
Substance abuse, No. of subjects				
Any	18	
Alcohol	15	
Stimulant	7	
Psychiatric rating scales, mean ± SD, score¶				
CGI (1, low; 7, high)	4.0 ± 0.7	
BPRS (0, low; 6, high)				
Total score	24.3 ± 9.8	
Schizophrenia factor#	6.0 ± 3.4	
Depression item	1.2 ± 1.1	
SANS (Global scores)				
Affective Flattening/Blunting	2.6 ± 1.0	
Alogia	2.2 ± 0.9	
Avolition-Apathy	2.8 ± 0.8	
Anhedonia-Asociality	2.7 ± 1.0	
Attention	1.5 ± 0.7	
Sum of Global SANS	11.8 ± 3.4	
Simpson-Angus (for EPS) total	2.3 ± 2.9	
AIMS total	0.7 ± 1.4	

*Values expressed as mean ± SD, unless otherwise indicated. Probability values of significance are based on 2-tailed α level.

†Compares the educational level of parents of schizophrenic patients with the educational level of normal controls.

‡Handedness was assessed with a shortened version of the Edinburgh Inventory.⁴¹

§Intracranial volumes were measured from T2-weighted axial slices ranging from the red nuclei to the vertex.

||Listed once are 2 patients receiving intramuscular and oral neuroleptic (same type) and 1 patient receiving 2 different neuroleptic drugs.

¶CGI indicates Clinical Global Impressions Scale; BPRS, Brief Psychiatric Rating Scale; SANS, Schedule for the Assessment of Negative Symptoms; EPS, extrapyramidal symptoms; and AIMS, Abnormal Involuntary Movement Scale.

#The BPRS schizophrenia factor (0, low; 6, high) measures positive symptoms and is the sum of the BPRS "conceptual disorganization," "hallucinatory behavior," and "unusual thought content" items.

matter volume ($P = .06$) and prefrontal white matter volume ($P = .41$). However, for the whole temporal lobe measures, the overall group \times hemisphere ANCOVA models (Table 2) revealed significant main effects for group ($P = .001$) and hemisphere ($P = .03$) in gray matter but not in white matter ($P = .47$ and $P = .36$, respectively). All other main and interaction effects were nonsignificant, excluding the variables used as covariates. This overall pattern of results indicates that schizophrenic patients, as a group, have nonspecific reductions in prefrontal and temporal gray matter relative to normal controls, but there was no evidence for a corresponding group difference in prefrontal and temporal white matter.

The follow-up regional ANCOVA analyses (see Table 2 for group means, ANCOVA results, percentage differences, and effect sizes⁴³) revealed that schizophrenic patients had smaller prefrontal gray matter volumes bilaterally as compared with normal controls (with the exception of only a right hemispheric reduction in inferior central prefrontal gray matter). However, there were no group differences in white matter volume for any of the 6 prefrontal subregions. Similarly, the schizophrenic group had significant reductions in gray matter volume in the superior temporal gyrus and whole temporal cortex, but not in white matter volume in these 2 regions. In addition, laterality in regional volumes was observed in prefrontal superior lateral white matter (left > right) and in whole temporal cortex gray matter (right > left). Overall, schizophrenic patients generally had fairly large and widespread reductions in gray matter in the prefrontal (bilateral decrease of 4.89 cc [7.4%], $d = 0.72$) and whole temporal cortex (bilateral decrease of 4.73 cc [8.9%], $d = 0.80$) and decrements in the superior temporal cortex (bilateral decrease of 1.05 cc [6.0%], $d = 0.80$); however, they were not different from normal controls for white matter volumes in any of the prefrontal and temporal regions.

CLINICAL SYMPTOM-REGIONAL VOLUME ANALYSES

Partial correlations adjusting for ICV and age were computed between bilateral regional brain volumes and the clinical ratings performed on the schizophrenic group (Table 3). After adjusting for the number of tests (2-tailed α error level set to $P < .01$), total prefrontal white matter was found to relate inversely to negative symptoms ($r_{p[49]} = -0.42$, $P = .002$, $n = 53$), as measured by the sum of the 5 global subscales of the SANS (Figure). This relationship was a global rather than focal effect (Figure, inset), as corresponding partial correlations for the 6 individual prefrontal subregions for each hemisphere were generally robust (reference range, $r_{p[49]} = -0.44$, $P = .001$ to $-.25$, $P = .08$). In terms of specific negative symptoms, total prefrontal white matter was related inversely to the SANS Anhedonia-Asociality and Alogia Global subscales (Table 3). No other correlations were significant.

POST HOC ANALYSES

In a post hoc analysis, differences in prefrontal white matter volume were examined among normal controls and patients with low- and high-negative symptom scores

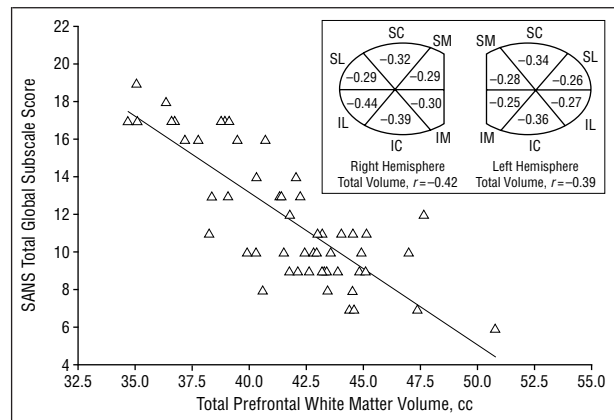


Figure. Plot of Scale for the Assessment of Negative Symptoms (SANS) score (sum of global scores for each of the 5 subscales) vs total prefrontal white matter volume for schizophrenic patients ($n = 53$) after adjusting for intracranial volume and age ($r_{p[49]} = -0.42$, $P = .002$). Inset, Schematic shows corresponding partial correlation coefficients for individual prefrontal subregions depicted in coronal plane. S indicates superior; I, inferior; L, lateral; C, central; and M, medial.

(Table 4), where the high- and low-negative symptom dichotomy was based on the top quartile of the SANS (sum of global subscale scores ≥ 16). The main effect for group was significant in the omnibus analysis of the individual prefrontal subregions, in the analysis of total prefrontal volume, and for 1 individual subregion, inferior central prefrontal white matter. Follow-up t tests for these regions revealed that the high-negative symptom group had significantly smaller inferior central and total prefrontal white matter volumes than patients with low-negative symptoms and normal controls, which were not different from each other. This effect represented a bilateral reduction of 1.27 cc (15.1%, $d = 0.86$) in inferior central white matter volume and 4.94 cc (11.4%, $d = 0.75$) in total prefrontal white matter volume relative to the low-negative symptom schizophrenic group. (The high- and low-negative symptom schizophrenic groups were not different for any of the demographic variables listed in Table 1 [data not shown].)

COMMENT

In this study, we used high-resolution, 3-dimensional MR imaging to examine gray and white matter volumes in prefrontal and temporal lobe regions in an all-male, demographically similar sample of 53 schizophrenic patients and 29 normal controls. The schizophrenic group had widespread bilateral decrements in gray matter in the prefrontal and whole temporal cortex, but not in white matter in these regions. In the temporal lobe, gray matter reductions were found in superficial cortex (ie, superior temporal gyrus), but not in mesial areas (ie, hippocampus and parahippocampus). In addition, prefrontal and temporal gray matter regional volumes were unrelated to various clinical symptoms.

While there were no overall differences in white matter volumes between the schizophrenic and normal control groups, total prefrontal white matter among schizophrenic patients was inversely related to negative symptoms. For schizophrenic patients who have

Table 2. Regional White and Gray Matter Volumes for the 53 Schizophrenic Patients and the 29 Normal Controls After Correction for Intracranial Volume and Age^a

Brain Region	Schizophrenic Patients		Normal Controls		Percentage of Reduction ^b and Effect Size		ANCOVA $F_{(1,78)}$ Values and Results			
	LH	RH	LH	RH	LH	RH	Main Effects		Interaction	Post Hoc Results
							Group	Hemisphere	Group × Hemisphere	
Superior Medial Prefrontal Gray ^c	4.59 ± 0.57	4.86 ± 0.54	4.94 ± 0.58	5.35 ± 0.66	7.0 (0.60)	9.1 (0.82)	10.73 ^d	0.32	0.97	SZ<NC
Superior Central Prefrontal Gray ^c	5.78 ± 0.73	6.08 ± 0.82	6.27 ± 0.74	6.63 ± 0.83	7.9 (0.67)	8.2 (0.66)	8.63 ^d	0.09	0.23	SZ<NC
Superior Lateral Prefrontal Gray ^c	4.42 ± 0.60	4.82 ± 0.63	4.75 ± 0.61	5.31 ± 0.64	6.9 (0.55)	9.3 (0.79)	11.26 ^d	1.31	1.12	SZ<NC
Inferior Medial Prefrontal Gray ^c	4.37 ± 0.53	4.81 ± 0.57	4.76 ± 0.54	5.21 ± 0.57	8.1 (0.72)	7.7 (0.70)	10.66 ^d	0.62	0.02	SZ<NC
Inferior Central Prefrontal Gray ^c	5.26 ± 0.81	5.27 ± 0.84	5.43 ± 0.82	5.69 ± 0.85	3.1 (0.21)	7.5 (0.50)	2.49	0.13	5.20 ^e	RH _{SZ} <RH _{NC}
Inferior Lateral Prefrontal Gray ^c	5.54 ± 0.73	5.66 ± 0.73	5.91 ± 0.74	6.11 ± 0.74	6.3 (0.51)	7.4 (0.62)	6.42 ^e	0.83	0.41	SZ<NC
Hemispheric Prefrontal Gray	29.96 ± 3.38	31.49 ± 3.61	32.05 ± 3.42	34.29 ± 3.65	6.5 (0.62)	8.2 (0.77)	9.33 ^d	0.03	2.68	SZ<NC
Total Prefrontal Gray Matter	61.45 ± 6.75		66.34 ± 6.84		7.4 (0.72)	
Superior Medial Prefrontal White ^f	2.61 ± 0.77	2.19 ± 0.72	2.75 ± 0.78	2.35 ± 0.73	5.1 (0.18)	6.9 (0.23)	1.36	0.10	0.01	...
Superior Central Prefrontal White ^f	4.61 ± 0.89	4.49 ± 0.78	4.64 ± 0.90	4.57 ± 0.79	0.6 (0.03)	1.8 (0.10)	0.08	1.58	0.17	...
Superior Lateral Prefrontal White ^f	2.63 ± 0.60	2.61 ± 0.67	2.82 ± 0.61	2.73 ± 0.67	6.7 (0.31)	4.3 (0.18)	1.63	4.04 ^e	0.15	LH>RH
Inferior Medial Prefrontal White ^f	3.24 ± 0.70	3.61 ± 0.68	3.31 ± 0.71	3.67 ± 0.69	2.2 (0.11)	1.8 (0.10)	0.24	0.99	0.00	...
Inferior Central Prefrontal White ^f	4.38 ± 0.85	3.68 ± 0.77	4.59 ± 0.86	3.91 ± 0.78	4.5 (0.24)	5.8 (0.29)	1.39	0.21	0.03	...
Inferior Lateral Prefrontal White ^f	4.00 ± 0.79	3.89 ± 0.77	4.05 ± 0.80	3.89 ± 0.78	1.3 (0.07)	0.1 (0.00)	0.03	1.49	0.18	...
Hemispheric Prefrontal White	21.47 ± 3.64	20.47 ± 3.51	22.16 ± 3.69	21.12 ± 3.55	3.1 (0.19)	3.1 (0.19)	0.69	2.46	0.00	...
Total Prefrontal White Matter	41.93 ± 6.81		43.28 ± 6.90		3.1 (0.20)	
Hippocampus ^g	3.23 ± 0.47	3.20 ± 0.58	3.42 ± 0.48	3.35 ± 0.59	5.6 (0.40)	4.6 (0.27)	2.23	0.70	0.13	...
Parahippocampus ^g	2.61 ± 0.48	2.52 ± 0.45	2.62 ± 0.49	2.56 ± 0.45	0.0 (0.00)	1.5 (0.08)	0.04	0.60	0.15	...
Superior Temporal Gyrus										
Gray ^g	7.79 ± 1.19	8.57 ± 1.19	8.23 ± 1.21	9.18 ± 1.21	5.4 (0.37)	6.6 (0.51)	4.21 ^e	1.39	0.48	SZ<NC
White	5.28 ± 1.12	5.63 ± 1.30	5.51 ± 1.13	5.62 ± 1.31	4.1 (0.20)	-0.1 (-0.01)	0.16	2.60	1.20	...
Hemispheric Whole Temporal Gray	23.44 ± 3.08	24.71 ± 3.04	25.46 ± 3.12	27.43 ± 3.08	7.9 (0.65)	9.9 (0.89)	11.40 ^h	5.07 ^e	3.21	SZ<NC, RH>LH
Total Whole Temporal Gray	48.15 ± 5.90		52.88 ± 5.97		8.9 (0.80)	
Hemispheric Whole Temporal White	17.94 ± 3.54	18.73 ± 3.60	18.92 ± 3.58	18.93 ± 3.65	5.1 (0.27)	1.1 (0.06)	0.52	0.86	2.48	...
Total Whole Temporal White	36.67 ± 6.83		37.85 ± 6.92		3.1 (0.17)	

^aGray and white matter volumes were measured in cubic centimeters. Table values are the mean ± SD of absolute regional brain matter volumes after adjusting for intracranial volume (ICV) and age. $F_{(1,78)}$ values for each region are from a group × hemisphere (2×2) analysis of covariance (ANCOVA) design using ICV and age as covariates. LH indicates left hemisphere; RH, right hemisphere; SZ, patients with schizophrenia; NC, normal controls; and ellipses, not applicable.

^bPercentage reduction in regional volumes is relative to normal controls. Effect sizes (in parentheses) are group mean differences divided by the pooled SD.

^cFor frontal gray matter regions, the overall group × hemisphere × region ($2 \times 2 \times 6$) ANCOVA using ICV and age as covariates had the following F values: ICV, $F_{(1,78)} = 24.58$, $P < .001$; age, $F_{(1,78)} = 13.15$, $P < .001$; group, $F_{(1,78)} = 9.33$, $P = .003$; hemisphere, $F_{(1,78)} = 0.03$, $P = .86$; region, $F_{(5,74)} = 1.41$, $P = .23$; group × hemisphere, $F_{(1,78)} = 2.68$, $P = .11$; group × region, $F_{(5,74)} = 1.29$, $P = .28$; hemisphere × region, $F_{(5,74)} = 0.65$, $P = .67$; group × hemisphere × region, $F_{(5,74)} = 0.79$, $P = .56$.

^d $P < .01$.

^e $P < .05$.

^fFor frontal white matter regions, the overall group × hemisphere × region ($2 \times 2 \times 6$) ANCOVA using ICV and age as covariates had the following F values: ICV, $F_{(1,78)} = 7.16$, $P = .009$; age, $F_{(1,78)} = 0.99$, $P = .32$; group, $F_{(1,78)} = 0.69$, $P = .41$; hemisphere, $F_{(1,78)} = 2.46$, $P = .12$; region, $F_{(5,74)} = 1.51$, $P = .20$; group × hemisphere, $F_{(1,78)} = 0.00$, $P = .95$; group × region, $F_{(5,74)} = 1.85$, $P = .11$; hemisphere × region, $F_{(5,74)} = 0.64$, $P = .67$; group × hemisphere × region, $F_{(5,74)} = 0.29$, $P = .91$.

^gFor temporal lobe gray matter regions, the overall group × hemisphere × region ($2 \times 2 \times 3$) ANCOVA using ICV and age as covariates had the following F values: ICV, $F_{(1,78)} = 7.63$, $P < .001$; age, $F_{(1,78)} = 8.82$, $P = .004$; group, $F_{(1,78)} = 3.90$, $P = .06$; hemisphere, $F_{(1,78)} = 0.86$, $P = .36$; region, $F_{(2,77)} = 2.28$, $P = .11$; group × hemisphere, $F_{(1,78)} = 0.32$, $P = .57$; group × region, $F_{(2,77)} = 2.43$, $P = .09$; hemisphere × region, $F_{(2,77)} = 1.49$, $P = .23$; group × hemisphere × region, $F_{(2,77)} = 0.41$, $P = .67$. The amygdala region was not included in the analysis due to poor reliability.

^h $P < .005$.

Table 3. Partial Correlations Between Bilateral Regional Volumes and Clinical Rating Scales for the 53 Schizophrenic Patients After Adjusting for Intracranial Volume and Age*

Clinical Rating Scale	White Matter Regions			Gray Matter Regions				
	Total Prefrontal White Matter	Whole Temporal White Matter	Superior Temporal Gyrus White Matter	Total Prefrontal Gray Matter	Whole Temporal Gray Matter	Superior Temporal Gray Matter	Hippocampus	Parahippocampus
CGI	-0.25	-0.13	-0.12	0.22	0.17	0.25	0.06	0.16
BPRS								
Total score	-0.07	-0.11	0.01	0.07	-0.05	0.10	0.05	-0.08
Schizophrenia factor score	-0.04	-0.19	-0.06	0.12	-0.04	0.13	-0.01	-0.04
Depression item score	-0.07	-0.17	-0.12	-0.20	-0.21	-0.10	0.05	-0.22
SANS (Global scores)								
Total Global score†	-0.42‡	-0.24	-0.15	0.14	0.18	0.34	0.22	0.04
Affective Flattening/Blunting	-0.33	-0.15	-0.06	0.06	0.14	0.21	0.27	0.11
Alogia	-0.37§	-0.18	-0.16	0.05	0.13	0.20	0.03	-0.04
Avolition-Apathy	-0.28	-0.10	-0.02	0.15	0.14	0.34	0.22	-0.05
Anhedonia-Asociality	-0.45	-0.35	-0.21	0.17	0.07	0.31	0.28	0.16
Attention	-0.21	-0.14	-0.11	0.15	0.26	0.32	0.03	-0.05
Simpson-Angus Scale total	-0.13	0.08	0.14	0.06	0.14	0.16	0.26	0.05
AIMS total	-0.04	0.05	0.10	0.01	0.00	0.01	0.05	-0.03

*Table values are partial correlations (all $df = 49$) that express relationships after adjusting for the effects of intracranial volume (ICV) and age. Significant partial correlations were defined as having a 2-tailed probability of significance $< .01$ to adjust for the number of tests (ie, 2-tailed α level was set at $P < .01$). In a follow-up analysis, all significant relationships in the table also were significant at the above-cited probability values using partial correlations that adjusted for ICV, age, BPRS depression item score, and BPRS schizophrenia factor score (all $df = 47$). Regional gray and white matter volumes are the sum of left and right hemispheric volumes. The amygdala region was not included in the analysis due to poor reliability. See the ¶ footnote to Table 1 for explanation of abbreviations.

†Total Global SANS scores are the sum of the global scores for each SANS subscale (affective flattening/blunting, alogia, avolition-apathy, anhedonia-asociality, and attention).

‡ $P < .005$.

§ $P < .01$.

|| $P < .001$.

high-negative symptoms, reductions in total prefrontal white matter were robust relative to both schizophrenic patients who have low-negative symptoms and normal controls. This prefrontal white matter reduction was most severe in the orbitofrontal subregion. White matter volumes were not significantly correlated with age, the number of years ill, age of illness onset, and number of hospitalizations. Together, these results may indicate that gray matter deficits may be a fairly common (though not necessarily ubiquitous) structural abnormality of schizophrenia, whereas decrements in prefrontal white matter may be specifically associated with the expression of schizophrenic negative symptoms.

The results presented here are generally consistent with the extensive structural MRI imaging literature demonstrating gray matter reductions in schizophrenia in the prefrontal region, temporal lobe, and superior temporal gyrus.^{8-10,44} However, other studies,^{8,45} unlike our results here, have also found bilateral reductions in the hippocampus and parahippocampus. These discrepant results may be explained in part by the possibility that thin slices (thinner than 2.8 mm) are needed for detecting significant differences.⁴⁶ The overall validity of our technique is evidenced by ratios of gray and white volumes similar to those reported in other recent studies^{12,14,15,24} and by the negative relationship between age and gray matter volumes, but not white matter volumes.⁴⁰

Of significant interest was the strong inverse relationship between schizophrenic negative symptoms and prefrontal white matter volume found in our study. Wible et al²⁴ also reported such an association for white matter

volume in the left prefrontal region, but did not find overall group differences in either white or gray matter. Some studies also have found that schizophrenic negative symptoms are inversely related to corpus callosum size.^{19,47} While most studies, like the present one, have reported no overall reductions in white matter volume in schizophrenia,⁴⁻⁸ some have offered evidence for reductions in total white matter,^{13,14} absolute posterior white matter,¹⁵ corpus callosum,^{18,19} or total reductions only in non-deficit schizophrenic patients.⁴⁸

Additional support for white matter abnormalities in schizophrenia comes from other imaging methods, as well as from autopsy studies. Magnetic resonance spectroscopy has indicated that neuronal connections in white matter may be disrupted in schizophrenia without concomitant volumetric reductions.¹⁶ Widespread¹⁷ and prefrontal⁴⁹ decreases in white matter tensor diffusion anisotropy also have been reported in schizophrenia, without evidence of volumetric white matter deficits.¹⁷ From post-mortem data, there is cytoarchitectural evidence for an inward maldistribution of neurons in prefrontal^{20,21} and temporal lobe²² white matter regions in schizophrenia.

Autopsy evidence^{50,51} indicates that schizophrenia is associated with increased neuronal density in the prefrontal and other regions,^{52,53} which are likely to be a result of smaller neuronal cell size and overall modest cranial deficits rather than cell loss or gliosis.^{50,54,55} Selemon and Goldman-Rakic⁵¹ have proposed that these brain regions in schizophrenia, particularly the prefrontal cortex, may have functional impairments in the neuropil that retard synaptic interactions and cellular support activi-

Table 4. Results of the Post Hoc Analyses on Prefrontal White Matter Volumes for the High Negative Symptom, Low Negative Symptom, and Normal Control Groups After Correction for Intracranial Volume and Age*

Brain Region	Schizophrenic Patients						ANCOVA $F_{(1,78)}$ Values and Results			
	With HN Symptom† (n = 13)		With LN Symptom† (n = 40)		Normal Controls (n = 29)		Main Effects		Interaction	Post Hoc Results
	LH	RH	LH	RH	LH	RH	Group	Hemisphere	Group × Hemisphere	
Superior Medial Prefrontal White‡	2.29 ± 0.75	2.03 ± 0.71	2.72 ± 0.76	2.24 ± 0.72	2.75 ± 0.77	2.35 ± 0.73	2.50	0.08	0.22	...
Superior Central Prefrontal White‡	4.21 ± 0.86	4.08 ± 0.75	4.74 ± 0.87	4.62 ± 0.76	4.64 ± 0.88	4.57 ± 0.77	2.49	1.54	0.08	...
Superior Lateral Prefrontal White‡	2.51 ± 0.60	2.30 ± 0.64	2.67 ± 0.60	2.72 ± 0.65	2.82 ± 0.61	2.73 ± 0.66	2.58	3.94	0.66	...
Inferior Medial Prefrontal White‡	3.08 ± 0.69	3.40 ± 0.67	3.29 ± 0.70	3.68 ± 0.68	3.31 ± 0.71	3.68 ± 0.69	0.98	0.97	0.04	...
Inferior Central Prefrontal White‡§	3.91 ± 0.81	3.20 ± 0.73	4.53 ± 0.82	3.84 ± 0.73	4.59 ± 0.84	3.91 ± 0.75	4.45	0.20	0.02	HN < LN = NC
Inferior Lateral Prefrontal White‡	3.74 ± 0.77	3.48 ± 0.74	4.08 ± 0.78	4.02 ± 0.74	4.05 ± 0.79	3.89 ± 0.76	1.91	1.42	0.93	...
Hemispheric Prefrontal White¶	19.73 ± 3.52	18.48 ± 3.36	22.03 ± 3.55	21.12 ± 3.38	22.16 ± 3.61	21.12 ± 3.44	3.19	2.39	0.12	HN < LN = NC
Total Prefrontal White Matter¶	38.21 ± 6.54		43.15 ± 6.59		43.28 ± 6.70	

*Table values are the mean ±SD of absolute regional brain matter volumes (in cubic centimeters) after adjusting for intracranial volume (ICV) and age. F values for each region are from a group × hemisphere (3 × 2) analysis of covariance (ANCOVA) design using ICV and age as covariates. In this design, the main effects of hemisphere, ICV, and age have df = 1,77, and the main effect of group and the interaction effect of group × hemisphere have df = 2,77. Probability values of significance are based on 2-tailed α levels. HN indicates schizophrenic patients with high negative symptoms; LN, schizophrenic patients with low negative symptoms; LH, left hemisphere; RH, right hemisphere; NC, normal controls, and ellipses, not applicable.

†The high and low negative symptom schizophrenic groups were defined as patients who had total global subscale scores above and below the top quartile (≥ 16), respectively, on the Scale for the Assessment of Negative Symptoms (SANS). These 2 schizophrenic groups were not different for any of the demographic variables listed in Table 1 (data not shown).

‡For frontal white matter regions, the overall group × hemisphere × region (3 × 2 × 6) ANCOVA using ICV and age as covariates had the following F values: ICV, $F_{(1,77)} = 7.60$, $P = .007$; age, $F_{(1,77)} = 1.05$, $P = .31$; group, $F_{(2,77)} = 3.19$, $P = .05$; hemisphere, $F_{(1,77)} = 2.39$, $P = .13$; region, $F_{(5,73)} = 1.58$, $P = .18$; group × hemisphere, $F_{(2,77)} = 0.12$, $P = .89$; group × region, $F_{(10,146)} = 1.05$, $P = .15$; hemisphere × region, $F_{(5,73)} = 0.63$, $P = .68$; group × hemisphere × region, $F_{(10,146)} = 1.19$, $P = .30$.

§For the inferior central prefrontal white matter region, the high negative symptom schizophrenic group had a bilateral reduction of 1.27 cc (15.1%, $d = .86$) relative to the low negative symptom schizophrenic group.

|| $P < .05$.

¶For total prefrontal white matter volume, the high negative symptom schizophrenic group had a bilateral reduction of 4.94 cc (11.4%, $d = .75$) relative to the low negative symptom schizophrenic group.

ties among neuronal cells. The net result of neuropil dysfunction is impaired neural transmission, which may be worsened by possible structural abnormalities in neural pathways as a result of faulty neurodevelopment.^{56,57}

Given the extensive evidence for structural abnormalities in schizophrenia, especially in frontal and temporal cortical regions, support for relationships between regional brain volumes and clinical symptoms for the most part has been inconsistent, even with putative associations of positive symptoms with temporal lobe gray matter pathology.⁸⁻¹⁰ Instead of regional volumes (corresponding to localization of function), core components of schizophrenic psychopathology, such as cognitive deficits and hypofrontality, have been related to disruption in neural tracts that connect and integrate various cortical regions.⁵⁶⁻⁵⁸ In a similar fashion, “dysconnection”^{56,59-61} of brain regions involving cortico-cortical and/or cortical-subcortical white matter tracks, such as those pertaining to the heteromodal association cortex,⁶² may disrupt increasingly complex human behaviors (eg, integration of volition and motivation in purposeful behavior, proper perception and expression of emotion in social interactions) and underlie the behavioral domains comprising schizophrenic negative symptoms. For example, compromised cortical-subcortical con-

nectivity may underlie the apparent similarity between certain aspects of negative syndromes and subcortical dementia,⁶³⁻⁶⁶ both of which entail cognitive slowness, apathy, loss of motivation, and neurologic abnormalities. In addition, the disruption of corticolimbic (viz, amygdala) and other cortical-subcortical connections,⁶⁷ as revealed by reports of volumetric deficits in the orbitofrontal region here and elsewhere,⁶⁸ may contribute to negative symptom phenomenology.

In this study, the high-negative symptom group, while clinically stable, was defined using the top quartile of scores from the SANS, a cross-sectional phenomenological rating scale. Clearly, this clinical scale does not distinguish among various negative symptom syndromes, such as the deficit syndrome⁶⁹ and secondary negative symptoms. However, in this study we used this straightforward assessment method because it has been associated with robust group differences in our previous functional imaging studies. For example, we have previously found a strong relationship between negative symptom severity and metabolic hypofrontality in prefrontal cortex,²⁵ a finding that is possibly related to the structural results reported here.

This convergence of functional and structural results suggests that certain prefrontal abnormalities in

schizophrenic patients may be associated with a common pathway for the expression of and/or vulnerability to various types of negative symptom syndromes, rather than an etiologically homogeneous negative syndrome. This pathway or vulnerability may result in, for instance, the mediation of secondary negative symptoms under certain conditions of neurotransmitter imbalance (ie, parkinsonism), or underlie the evolution of primary negative symptoms and the deficit syndrome during the course of schizophrenic illness.

The limitations of our study include the thickness of our MR slices (and possible type II error for certain limbic regions), correction for magnetic field inhomogeneity in only one dimension, the use of an all-male sample, the lack of prospective matching with respect to our groups, and elucidation of the negative symptom findings using exploratory post hoc analyses. Our results need to be replicated in future studies using samples of male and female patients with varying degrees and types of negative symptoms. Additional investigations with first-onset schizophrenic patients may provide clues about the time point at which prefrontal white matter deficits emerge over the course of the illness.

In summary, schizophrenic patients had widespread bilateral reductions in gray matter volume in the prefrontal and whole temporal regions, circumscribed gray matter deficits in the superior temporal gyrus, but no significant decrease in prefrontal and temporal white matter volume. However, decrements in prefrontal white matter volume were strongly associated with greater negative symptoms in schizophrenic patients.

Accepted for publication January 19, 2000.

This study was supported by the Department of Veterans Affairs, Washington, DC.

We also thank Douglas Harris, Julius Perry, and John Asarian for their assistance with acquiring the magnetic resonance imaging scans.

Corresponding author: Adam Wolkin, MD, Mental Health Service (11M), Room 17017W, Veterans Administration New York Harbor Health Care System, 423 E 23rd St, New York, NY 10010-5050 (e-mail: adam.wolkin@med.va.gov).

REFERENCES

1. Ward KE, Friedman L, Wise A, Schulz SC. Meta-analysis of brain and cranial size in schizophrenia. *Schizophr Res*. 1996;22:197-213.
2. DeLisi LE, Sakuma M, Tew W, Knshner M, Hoff AL, Grimson R. Schizophrenia as a chronic active brain process: a study of progressive brain structural change subsequent to the onset of schizophrenia. *Psychiatry Res*. 1997;74:129-140.
3. Gut RE, Cowell P, Turetsky BI, Gallacher F, Cannon T, Bilker W, Gut RC. A follow-up magnetic resonance imaging study of schizophrenia: relationship of neuroanatomical changes to clinical and neurobehavioral measures. *Arch Gen Psychiatry*. 1998;55:145-152.
4. Zipursky RB, Lim KO, Sullivan EV, Brown BW, Pfefferbaum A. Widespread cerebral gray matter volume deficits in schizophrenia. *Arch Gen Psychiatry*. 1992;49:195-205.
5. Lim KO, Sullivan EV, Zipursky RB, Pfefferbaum A. Cortical gray matter volume deficits in schizophrenia: a replication. *Schizophr Res*. 1996;20:157-164.
6. Lauriello J, Hoff A, Wieneke MH, Blankfeld H, Faustman WO, Rosenbloom M, DeMent S, Sullivan EV, Lim KO, Pfefferbaum A. Similar extem of brain dysmorphology in severely ill women and men with schizophrenia. *Am J Psychiatry*. 1997;154:819-825.
7. Sullivan EV, Lim KO, Mathalon D, Marsh L, Beal DM, Harris D, Hoff AL, Faustman WO, Pfefferbaum A. A profile of cortical gray matter volume deficits characteristic of schizophrenia. *Cereb Cortex*. 1998;8:117-124.
8. Lawrie SM, Abukmeil SS. Brain abnormality in schizophrenia: a systematic and quantitative review of magnetic resonance imaging studies. *Br J Psychiatry*. 1998;172:110-120.
9. McCarley RW, Wible CG, Fmmin M, Hirayasu Y, Levitt JJ, Fisher IA, Shemon ME. MRI anatomy of schizophrenia. *Biol Psychiatry*. 1999;45:1099-1119.
10. Pearlson GD, Marsh L. Structural brain imaging in schizophrenia: a selective review. *Biol Psychiatry*. 1999;46:627-649.
11. Lim KO, Tew W, Kushner M, Chow K, Matsumoto B, DeLisi LE. Cortical gray matter volume deficit in patients with first-episode schizophrenia. *Am J Psychiatry*. 1996;153:1548-1553.
12. Zipursky RB, Lambe EK, Kaput S, Mikulis DJ. Cerebral gray matter volume deficits in first episode psychosis. *Arch Gen Psychiatry*. 1998;55:540-546.
13. Breier A, Buchanan RW, Elksahaf A, Munson RC, Kirkpatrick B, Gellad F. Brain morphology and schizophrenia: a magnetic resonance imaging study of limbic, prefrontal cortex, and caudate structures. *Arch Gen Psychiatry*. 1992;49:921-926.
14. Buchanan RW, Vladar K, Barta PE, Pearlson GD. Structural evaluation of the prefrontal cortex in schizophrenia. *Am J Psychiatry*. 1998;155:1049-1055.
15. Cannon TI, van Erp TGM, Huttunen M, Lonnqvist J, Salonen O, Valanne L, Poutanen VP, Standertskjold-Nordenstam CG, Gut RC, Yan M. Regional gray matter, white matter, and cerebrospinal fluid distributions in schizophrenics patients, their siblings, and controls. *Arch Gen Psychiatry*. 1998;55:1084-1091.
16. Lim KO, Adalsteinsson E, Spielman D, Sullivan EV, Rosenbloom MJ, Pfefferbaum A. Proton magnetic resonance spectroscopic imaging of cortical gray and white matter in schizophrenia. *Arch Gen Psychiatry*. 1998;55:346-352.
17. Lim KO, Hedehus M, Moseley M, de Crespigny A, Sullivan EV, Pfefferbaum A. Compromised white matter tract integrity in schizophrenia inferred from diffusion tensor imaging. *Arch Gen Psychiatry*. 1999;56:367-374.
18. Woodruff PW, McManus IC, David AS. Meta-analysis of corpus callosum size in schizophrenia. *J Neurol Neurosurg Psychiatry*. 1995;58:457-461.
19. Tibbo P, Nopoulos P, Arndt S, Andreasen NC. Corpus callosum shape and size in male patients with schizophrenia. *Biol Psychiatry*. 1999;44:405-412.
20. Akbarian S, Kim JJ, Potkin SG, Hetrick WP, Bunney WE, Jones EG. Maldistribution of interstitial neurons in prefrontal white matter of the brains of schizophrenic patients. *Arch Gen Psychiatry*. 1996;53:425-436.
21. Akbarian S, Bunney WE, Jr, Potkin SG, Wigal SB, Haglan JO, Sandman CA, Jones EG. Altered distribution of nicotinamide-adenine dinucleotide phosphate-diaphorase cells in frontal lobe of schizophrenic implies disturbances of cortical development. *Arch Gen Psychiatry*. 1993;50:169-177.
22. Akbarian S, Vinuela A, Kim JJ, Potldn SG, Bunney WEJ, Jones EG. Distorted distribution of nicotinamide-adenine dinucleotide phosphate-diaphorase neurons in temporal lobe of schizophrenics implies anomalous cortical development. *Arch Gen Psychiatry*. 1993;50:178-187.
23. Wolkin A, Rusinek H, Vaid G, Arena L, Lafargue T, Sanfilippo M, Loneragan C, Lantin A, Rotrosen J. Structural magnetic resonance image averaging in schizophrenia. *Am J Psychiatry*. 1998;155:1064-1073.
24. Wible CG, Shenton ME, Hokama H, Kikinis R, Jolesz FA, Metcalf D, McCarley RW. Prefrontal cortex and schizophrenia: a quantitative magnetic resonance imaging study. *Arch Gen Psychiatry*. 1995;52:279-288.
25. Wolkin A, Sanfilippo M, Wolf AP, Angrist B, Brodie ID, Rotrosen J. Negative symptoms and hypofrontality in chronic schizophrenia. *Arch Gen Psychiatry*. 1992;49:959-965.
26. Wolkin A, Sanfilippo M, Duncan E, Angrist B, Wolf AP, Cooper TB, Brodie ID, Laska E, Rotrosen JP. Blunted change in cerebral glucose utilization after haloperidol treatment in schizophrenic patients with prominent negative symptoms. *Am J Psychiatry*. 1996;153:346-354.
27. Sanfilippo M, Lafargue T, Arena L, Rusinek H, Kushner K, Lantin A, Loneragan C, Vaid G, Rotrosen J, Wolkin A. Fine volumetric analysis of the cerebral ventricular system in schizophrenia: further evidence for multifocal, mild-to-moderate enlargement. *Schizophr Bull*. 2000;26:201-216.
28. Spitzer RL, Williams JBW, Gibbon M, First MB. *Structured Clinical Interview for DSM-III-R Patient Edition* (SCID-P, version 1.0). Washington, DC: American Psychiatric Association; 1990.
29. Shtasel DL, Gur RE, Mozley D, Richards J, Taleff MM, Heimberg C, Gallacher F, Gur RC. Volunteers for biomedical research. *Arch Gen Psychiatry*. 1991;48:1022-1025.
30. Spitzer RL, Williams JBW, Gibbon M, First MB. *Structured Clinical Interview for DSM-III-R Non-Patient Edition* (SCID-NP, version 1.0). Washington, DC: American Psychiatric Association; 1990.
31. Guy W. *ECDEU Assessment Manual for Psychopharmacology-Revised*. Rockville, Md: National Institute of Mental Health; 1976. DHEW Publication ADM 76-338.

32. Overall JE, Gorham DR. The brief psychiatric rating scale. *Psychol Rep.* 1962; 10:799-812.
33. Andreasen NC. Negative symptoms in schizophrenia: definition and reliability. *Arch Gen Psychiatry.* 1982;39:784-788.
34. Simpson GM, Angus JWS. A rating scale for extrapyramidal side effects. *Acta Psychiatr Scand Scand Suppl.* 1970;212:11-19.
35. Guy W. ECDEU Assessment Manual for Psychopharmacology. Washington, DC: US Dept of Health, Education, and Welfare; 1976. Publication ADM 534-535 ed.
36. Tsui WH. MIDAS User's Manual (Version 0.6). Unpublished Manual from the Information Processing Laboratory, New York University Medical Center, New York, NY.
37. Rusinek H, Chandra R. Brain tissue volume measurement from magnetic resonance imaging: a phantom study. *Invest Radiol.* 1993;28:890-895.
38. Rusinek H, DeLeon MJ, George AE, Stylopoulos LA, Chandra R, Smith G, Rand T, Mourino M, Kowalski H. Alzheimer disease: measuring loss of cerebral gray matter with MR imaging. *Radiology.* 1991;178:109-114.
39. Shenton ME, Kikinis R, Jolesz FA, Pollak SD, LeMay M, Wible CG, Hokama H, Martin J, Metcalf D, Coleman M, McCarter RW. Abnormalities of the left temporal lobe and thought disorder in schizophrenia: a quantitative magnetic resonance imaging study. *N Engl J Med.* 1992;327:604-612.
40. Pfefferbaum A, Mathalon DH, Sullivan EV, Rawles JM, Zipursky RB, Lira KO. A quantitative magnetic resonance imaging study of changes in brain morphology from infancy to late adulthood. *Arch Neurol.* 1994;51:874-887.
41. Oldfield RC. The assessment and analysis of handedness: the Edinburgh Inventory. *Neuropsychologia.* 1971;9:97-113.
42. Flaum M, Swayze VW, O'Leary DS, Yuh WT, Ehrhardt JC, Amdt SV, Andreasen NC. Effects of diagnosis, laterality, and gender on brain morphology in schizophrenia. *Am J Psychiatry.* 1995;152:704-714.
43. Cohen J. *Statistical Power Analysis for the Behavioral Sciences.* 2nd ed. Hillsdale, NJ: Lawrence Erlbaum Associates; 1988:92-92.
44. Pearlson GD. Superior temporal gyrus and planum temporale in schizophrenia: a selective review. *Prog Neuropsychopharmacol Biol Psychiatry.* 1997;21:1203-1229.
45. Nelson MD, Saykin AJ, Flashinan LA, Riordan HJ. Hippocampal volume reduction in schizophrenia as assessed by magnetic resonance imaging: a meta-analytic study. *Arch Gen Psychiatry.* 1998;55:433-440.
46. Velakoulis D, Pantelis C, McGorry PD, Dudgeon P, Brewer W, Cook M, Desmond P, Bridle N, Tierney P, Murrin V, Singh B, Copolov D. Hippocampal volume in first-episode psychoses and chronic schizophrenia. *Arch Gen Psychiatry.* 1999;56:133-140.
47. Woodruff PW, Phillips ML, Rushe T, Wright IC, Murray RM, David AS. Corpus callosum size and inter-hemispheric function in schizophrenia. *Schizophr Res.* 1999;23:189-196.
48. Buchanan RW, Breier A, Kirkpatrick B, Elkashef A, Munson RC, Gellad F, Carpenter WT Jr. Structural abnormalities in deficit and nondeficit schizophrenia. *Am J Psychiatry.* 1993;150:59-65.
49. Buchsbaum MS, Tang CY, Peled S, Gudbjartsson H, Lu D, Hazlett EA, Downhill J, Haznedar M, Fallon JH, Atlas SW. MRI white matter diffusion anisotropy and PET metabolic rate in schizophrenia. *Neuroreport.* 1998;9:425-430.
50. Harrison PJ. The neuropathology of schizophrenia: a critical review of the data and their interpretation. *Brain.* 1999;122:593-624.
51. Selemon LD, Goldman-Rakic PS. The reduced neuropil hypothesis: a circuit-based model of schizophrenia. *Biol Psychiatry.* 1999;45:17-25.
52. Selemon LD, Rajkowska G, Goldman-Rakic PS. Abnormally high neuronal density in the schizophrenic cortex: a morphometric analysis of prefrontal area 9 and occipital area 17. *Arch Gen Psychiatry.* 1995;52:805-818.
53. Selemon LD, Rajkowska G, Goldman-Rakic PS. Elevated neuronal density in prefrontal area 46 in brain from schizophrenic patients: application of a three-dimensional, stereologic counting method. *J Comp Neurol.* 1998;392:402-412.
54. Pakkenberg B. Total nerve cell number in neocortex in chronic schizophrenics and controls estimated using optical detectors. *Biol Psychiatry.* 1993;34:768-772.
55. Rajkowska G, Selemon LD, Goldman-Rakic PS. Neuronal and glial somal size in the prefrontal cortex: a postmortem morphometric study of schizophrenia and Huntington disease. *Arch Gen Psychiatry.* 1998;55:215-224.
56. Weinberger DR, Lipska BK. Cortical maldevelopment, anti-psychotic drugs, and schizophrenia: a search for common ground. *Schizophr Res.* 1995;16:87-110.
57. Weinberger DR. On the plausibility of "the neurodevelopmental hypothesis" of schizophrenia. *Neuropsychopharmacology.* 1996;14(suppl):1S-11S.
58. Berman KF, Weinberger DR. The prefrontal cortex in schizophrenia and other neuropsychiatric diseases: in vivo physiological correlates of cognitive deficits. *Prog Brain Res.* 1990;85:521-537.
59. Friston KJ, Frith CD. Schizophrenia: a disconnection syndrome? *Clin Neurosci.* 1995;3:89-95.
60. Friston KJ. The disconnection hypothesis. *Schizophr Res.* 1998;30:115-125.
61. McGuire PK, Frith CD. Disordered functional connectivity in schizophrenia. *Psychol Med.* 1996;26:663-668.
62. Pearlson GD, Petty RG, Ross CA, Tien AY. Schizophrenia: a disease of heteromodal association cortex? *Neuropsychopharmacology.* 1996;14:1-17.
63. Pantelis C, Barnes TRE, Nelson HE. Is the concept of frontal-subcortical dementia relevant to schizophrenia? *Br J Psychiatry.* 1992;160:442-460.
64. Albert ML, Feldman RG, Willis AL. The "subcortical dementia" of progressive supranuclear palsy. *J Neurol Neurosurg Psychiatry.* 1974;37:121-130.
65. Cummings JL. Subcortical dementia: Neuropsychology, neuropsychiatry, and pathophysiology. *Br J Psychiatry.* 1986;149:682-697.
66. Fenton WS, Wyatt RJ, McGlashan TH. Risk factors for spontaneous dyskinesia in schizophrenia. *Arch Gen Psychiatry.* 1994;51:643-650.
67. Fuster JM. *The Prefrontal Cortex: Anatomy, Physiology, and Neuropsychology of the Frontal Lobe.* 3rd ed. Philadelphia, Pa: Lippincott-Raven Publishers; 1997.
68. Baare WF, Hulshoff Pol HE, Hijman R, Mali WP, Viergever MA, Kahn RS. Volumetric analysis of frontal lobe regions in schizophrenia: relation to cognitive function and symptomatology. *Biol Psychiatry.* 1999;45:1597-1605.
69. Carpenter WT, Heinrichs DW, Wagman AMI. Deficit and nondeficit forms of schizophrenia: the concept. *Am J Psychiatry.* 1988;145:578-583.