

# Depression-Related Variation in Brain Morphology Over 3 Years

## *Effects of Stress?*

Thomas S. Frodl, MD; Nikolaos Koutsouleris, MD; Ronald Bottlender, MD; Christine Born, MD; Markus Jäger, MD; Isabel Scupin; Maximilian Reiser, MD; Hans-Jürgen Möller, MD; Eva M. Meisenzahl, MD

**Context:** Results of experimental studies suggest that neuroplastic changes may occur during depressive episodes. These effects have not been confirmed in patients with depression, to our knowledge.

**Objective:** To examine changes in the brains of patients with major depression vs those of healthy control subjects.

**Design:** Prospective longitudinal 3-year study.

**Setting:** Inpatients with major depression were recruited from the Department of Psychiatry and Psychotherapy, Ludwig Maximilians University of Munich, Munich, Germany, and controls were recruited from the local community.

**Participants:** The study included 38 patients with major depression and 30 healthy controls.

**Main Outcome Measures:** High-resolution magnetic resonance imaging was performed at baseline and

3 years later. Voxel-based morphometric measurements were estimated from magnetic resonance images, and psychopathologic findings were assessed at baseline, weekly during the inpatient phase, and then after 1, 2, and 3 years.

**Results:** Compared with controls, patients showed significantly more decline in gray matter density of the hippocampus, anterior cingulum, left amygdala, and right dorsomedial prefrontal cortex. Patients who remitted during the 3-year period had less volume decline than non-remitted patients in the left hippocampus, left anterior cingulum, left dorsomedial prefrontal cortex, and bilaterally in the dorsolateral prefrontal cortex.

**Conclusion:** This study supports findings from animal studies of neuroplastic stress-related processes that occur in the hippocampus, amygdala, dorsomedial prefrontal cortex, dorsolateral prefrontal cortex, and anterior cingulum during depressive episodes.

*Arch Gen Psychiatry.* 2008;65(10):1156-1165

### Author Affiliations:

Departments of Psychiatry and Psychotherapy (Drs Frodl, Koutsouleris, Bottlender, Jäger, Möller, and Meisenzahl and Ms Scupin) and Radiology (Drs Born and Reiser), Ludwig Maximilians University of Munich, Munich, Germany. Dr Frodl is now with the Department of Psychiatry, School of Medicine, Trinity College Dublin, Trinity Centre for Health Sciences, St James Hospital and Adelaide and Meath Hospital incorporating the National Children's Hospital (AMiNCH), Dublin, Ireland.

**D**YSFUNCTION OF NEURONAL plasticity or remodeling may contribute to the pathogenesis of mood disorders.<sup>1</sup> This hypothesis is supported by preclinical studies<sup>2,3</sup> demonstrating that stress and depression lead to changes in hippocampal morphologic structure. Experimental animal studies showed that prolonged stress decreases the numbers of apical dendritic branch points and the length of apical dendrites, particularly in the laminar CA3 region of the hippocampus.<sup>2,3</sup> This effect is glucocorticoid dependent and can emerge after 3 weeks of experimental corticosteroid treatment.<sup>2,3</sup> In animal models, antidepressants suppress the toxic effects of

stress on the hippocampus and increase hippocampal neurogenesis.<sup>4</sup>

Many *in vivo* neuroimaging investigations have detected reduced hippocampal volumes in older and younger patients with major depression. The results for other brain regions are inconsistent. For example, enlarged amygdala volumes and reduced volumes of the anterior cingulum and the prefrontal cortex have been reported in some investigations using region of interest (ROI) analysis in structural magnetic resonance (MR) imaging, suggesting alterations in the frontolimbic network.<sup>5</sup> The basal ganglia are reduced in patients with major depression, but this is more likely to occur in late-onset depression.<sup>6,7</sup>

**Table 1. Demographic and Clinical Data of Patients With an Episode of Major Depression vs Healthy Control Subjects<sup>a</sup>**

Variable	Patient Group (n = 38)	Control Group (n = 30)	t Test P Value	Remitted Patients (n = 21)	Nonremitted Patients (n = 17)	t Test P Value
Age, mean (SD), y	46.1 (11.3)	43.6 (11.3)	.40	44.0 (11.2)	48.7 (11.3)	.20
Female to male sex ratio <sup>b</sup>	<b>25:13</b>	19:11	.83	14:7	11:6	.90
Right-handedness–left-handedness ratio <sup>b</sup>	<b>34:4</b>	28:2	.44	19:2	15:2	.98
Height, mean (SD), cm	169.7 (7.7)	170.9 (9.6)	.54	171.0 (7.1)	168.1 (8.4)	.26
Weight, mean (SD), kg	66.9 (13.9)	69.8 (10.5)	.34	66.2 (14.2)	67.6 (14.0)	.76
Alcohol consumption, mean (SD), g/d	5.8 (10.9)	5.2 (6.2)	.80	5.1 (9.9)	4.5 (14.4)	.87
Age at onset, mean (SD), y	40.0 (12.1)	...	...	38.2 (11.8)	42.2 (12.5)	.59
Cumulative illness duration, mean (SD), mo	24.9 (21.0)	...	...	26.5 (23.3)	22.8 (18.5)	.33
Hamilton Depression Rating Scale score, mean (SD)						
Baseline	24.9 (6.8)	...	...	23.9 (6.8)	26.2 (6.7)	.30
After 3 y	6.5 (8.6)	...	...	2.0 (2.2)	12.1 (10.2)	<.001

Abbreviation: Ellipsis, not applicable.

<sup>a</sup>No significant differences were found between patients and control subjects or between remitted and nonremitted patients by *t* test or by  $\chi^2$  test.

<sup>b</sup>*P* < .05 by  $\chi^2$  test. Boldfaced values are the totals of remitted and nonremitted patients.

The first indication of a relationship between structural alterations and the course of the depression was obtained from cross-sectional investigations. Significant associations were reported between chronic depression and reduced left hippocampal gray matter density (GMD) measured by voxel-based analysis.<sup>8</sup> Moreover, using statistical parametric mapping, a recent study<sup>9</sup> found that the right hippocampus is reduced in older patients with depression, particularly in patients with a longer course of illness. Moreover, a relationship between hippocampal volume decline and longer cumulative illness duration has been described.<sup>10</sup>

Voxel-based morphometry (VBM) has become an established research method in recent years.<sup>11</sup> It enables the global assessment of brain structures without a priori identification of the ROI and is useful because it allows analysis of brain regions in which boundaries are difficult to define. Using VBM, smaller volumes of the medial part of the bilateral frontal lobes have been detected in patients with subthreshold depression,<sup>12</sup> and smaller volumes of the right hippocampus and the bilateral middle frontal gyrus have been found in patients with major depression.<sup>9</sup>

According to the hypothesis regarding the toxic effects of stress, hippocampal volumes may be expected to diminish during a depressive episode.<sup>13</sup> To our knowledge, no follow-up investigations about the whole brain have been published. There is not only a lack of studies examining these changes in patients with different stages of depression (eg, remitted depressed states) but also few studies with a longitudinal prospective design. A longitudinal study<sup>14</sup> demonstrated no significant change during 1 year in 30 patients with major depression and showed that a small hippocampal volume at the beginning of the study was related to a poor clinical outcome. Limitations of this first prospective study were that regions other than the hippocampus were not investigated, the interval (1 year) was short, and cofactors such as medication could not be accounted for because of the small number of patients participating. Furthermore, a longitudinal study<sup>15</sup> on white matter (WM) and subcortical gray matter (GM) lesions in 164 depressed subjects and 126 healthy subjects older than 60 years found

that lesion volume progression was associated not only with aging but also with the pathologic condition of late-life depression.

The aim of this prospective longitudinal VBM study was to compare baseline and 3-year follow-up GMD findings in patients with major depression vs those in healthy control subjects to examine whether depression results in a further diminution of GMD. We hypothesized that, compared with healthy controls, patients with depression would show reduced GMD in the hippocampus, amygdala, anterior gyrus cinguli, and dorsolateral prefrontal cortex (DLPFC) and dorsomedial prefrontal cortex (DMPFC), that GMD would further diminish in patients with chronic depression and relapses, and that GMD reduction would cease in patients with remission during the 3-year period.

## METHODS

### PARTICIPANTS

Thirty-eight inpatients with major depression (mean [SD] age, 46.1 [11.3] years) were recruited from the Department of Psychiatry and psychotherapy, Ludwig Maximilians University of Munich, Munich, Germany (**Table 1**). Psychiatric diagnoses were made on the basis of DSM-IV criteria and the Structured Clinical Interview for DSM-IV and were determined by a consensus of at least 2 psychiatrists (T.F. and M.J.). Clinical variables were documented using the 21-item Hamilton Depression Rating Scale<sup>16</sup> at baseline and then after 1, 2, and 3 years.

At the time of MR imaging, patients were taking the following medications: serotonin reuptake inhibitors (citalopram hydrobromide by 4 patients, sertraline hydrochloride by 2 patients, and paroxetine hydrochloride by 2 patients), tricyclic antidepressants (amitriptyline hydrochloride by 5 patients, doxepin hydrochloride by 5 patients, and amitriptylinolide by 2 patients), other new antidepressants (mirtazapine by 6 patients, venlafaxine hydrochloride by 4 patients, and reboxetine mesylate by 3 patients), maprotiline by 3 patients, lithium carbonate by 1 patient, and no antidepressant by 1 patient. Patients were also treated with supporting psychotherapy during their hospital stay.

For comparison, 30 healthy controls were matched for age (mean [SD] age, 43.6 [11.3] years), sex, and handedness (Table 1). Neither the controls nor their first-degree relatives had a history of neurologic or mental illness.

A structured interview was used to assess medical history, trauma, and other exclusion criteria for all subjects. Exclusion criteria for patients and controls were neurologic diseases, age older than 65 years, previous alcohol or other drug abuse, cortisol medication in the medical history, and previous head injury with loss of consciousness. Patients having comorbidity with other mental illnesses (eg, bipolar disorders) or personality disorders were also excluded. No subject had received electroconvulsive therapy before the investigation. Handedness was determined using the Edinburgh Inventory.<sup>17</sup>

Full remission during the 3-year period was defined as a score of at least 7 on the 17-item Hamilton Depression Rating Scale, calculated from the 21-item Hamilton Depression Rating Scale. Of 21 patients who fully remitted, 11 continued to take their medication during the 3 years, and, of 17 nonremitted patients, 12 continued to take their medication.

The study was described in detail to the patients and the controls, and written informed consent was obtained. The study design was approved by the local ethics committee and was prepared in accord with the ethical standards of the Declaration of Helsinki.

## MR IMAGING PROCEDURES

### Data Acquisition

At baseline and 3 years later, MR images were obtained (Magnetom Vision; Siemens, Erlangen, Germany) at 1.5 T. All subjects were imaged on the same scanner at baseline and at follow-up using a T1-weighted 3-dimensional MPRAGE (magnetization prepared rapid gradient echo) sequence (repetition time, 11.6 milliseconds; echo time, 4.9 milliseconds; total acquisition time, 9 minutes; number of acquisitions, 1; field of view, 230 mm; matrix, 512 × 512 pixels; and section thickness, 1.5 mm, yielding 126 contiguous axial sections with a defined voxel size of 0.45 × 0.45 × 1.5 mm). After manually reorienting and centering the images on the anterior commissure, data preprocessing was performed based on the VBM approach by Good et al<sup>18</sup> and implemented in the VBM2 toolbox (<http://dbm.neuro.uni-jena.de>), a software extension (SPM2; Wellcome Department of Cognitive Neurology, London, United Kingdom), using commercially available statistical software (MATLAB 6.5; The MathWorks, Natick, Massachusetts). The VBM2 toolbox provides state-of-the-art longitudinal VBM preprocessing algorithms.

### VBM Preprocessing

All data were blinded so that the staff could not distinguish between diagnosis or follow-up. Optimized longitudinal VBM was implemented as a 2-step procedure, starting with the construction of a study-specific whole-brain template and GM, WM, and cerebrospinal fluid (CSF) priors.

For the first step, the MR images were segmented into GM, WM, and CSF partitions and were reprocessed using a hidden Markov random field (HMRF) model.<sup>19</sup> The images were then registered to the space of the Montreal Neurological Institute whole-brain template by matching the GM partitions to the Montreal Neurological Institute GM template using affine and nonlinear normalization parameters.<sup>11</sup> The normalized T1-weighted images and the GM, WM, and CSF partitions were averaged and smoothed using an 8-mm full width at half maximum (FWHM) gaussian kernel. There-

fore, a study-specific whole-brain template and tissue priors were created that accounted for the magnetic field properties of the scanner and the anatomical properties of our study cohorts.

In the second step, the custom T1-weighted template and tissue priors were used. An initial bias field correction of the baseline and follow-up images was performed. Because of differing intrasubject distributions of intensity nonuniformities caused by the time lag between baseline and follow-up MR images, an additional bias correction was performed to minimize these differences. For this purpose, an intrasubject difference bias field was approximated with the intracranial parts of the difference image smoothed using a gaussian kernel with a large FWHM of 30 mm.

The follow-up MR images were registered to the corresponding baseline images to correct for position but not size. All baseline and follow-up images were segmented in native space and were filtered by means of the HMRF algorithm. This algorithm provides spatial constraints based on neighboring voxel intensity information within a 3 × 3 × 3-voxel cube. The procedure improves the signal to noise ratio by removing isolated voxels of a certain tissue class that are unlikely to be a member of that class and closes holes in a cluster of connected voxels of that class.

After HMRF filtering, the segmented baseline data were normalized to the customized whole-brain template by affine and nonlinear normalization of GM partitions to the customized GM template. The normalization estimates derived from this procedure were applied on the corresponding follow-up images. Therefore, spatial normalization removed interindividual anatomical differences, while preserving intraindividual longitudinal changes. All normalized whole-brain volumes were resegmented, which further removed nonbrain voxels from the brain tissue. This segmentation step was finished by reapplying the HMRF model to the GMD maps (GMD refers to the probability of finding GM in a certain voxel, not to absolute GM volume). Before statistical analysis, normalized GMD maps of baseline and follow-up images were smoothed using a 10-mm FWHM gaussian kernel.

## STATISTICAL ANALYSIS

The framework of the general linear model was used for the longitudinal VBM analysis of patients and controls. Group and time interactions for GMD changes during the follow-up period were tested using a longitudinal repeated-measures analysis of variance. After parameter estimation, contrasts were defined for GMD increases and decreases over time within and between groups. Longitudinal GMD reductions occurring in both groups were assessed at  $P < .05$  (corrected for familywise error) after exclusion of GMD changes in the control group from the statistical maps of interest at a height threshold of uncorrected  $P < .05$  (mask height threshold).

To test our hypothesis of different longitudinal GMD changes in patients and controls at  $P < .001$ , small-volume-corrected VBM analyses were performed for the following 5 ROIs: the hippocampus, amygdala, anterior cingulum, DMPFC, and DLPFC. The chosen threshold of  $P < .001$  was difficult to achieve because Bonferroni correction would have required  $P < .01$ .

The small-volume-corrected patient subgroup analyses were performed for the 5 ROIs. We tested the longitudinal GMD differences in stable remitted patients vs nonremitted patients. With Bonferroni correction, the statistical threshold was reduced from  $P < .05$  to  $P < .01$ . Coordinates of peak significant voxels were assigned to anatomic regions by means of automated anatomic labeling.<sup>20</sup>

## DEMOGRAPHIC DATA

Age, sex, height, weight, handedness, and alcohol consumption were similar in patients and controls. These variables, as well as age at onset, cumulative illness duration, and Hamilton Depression Rating Scale score at baseline, were also similar in stable remitted patients and nonremitted patients after 3 years (Table 1). Patients with stable remission did not discontinue their antidepressants more often than nonremitted patients ( $t_{38}=1.3$ ,  $P=.25$ ).

## LONGITUDINAL GMD

## Whole-Brain Analysis

The most significant longitudinal GMD reductions were found within the DMPFC, anterior cingulum, hippocampus, DLPFC, and orbitofrontal cortex, as well as in some other areas of the frontal, temporal, parietal, and occipital cortices and the cerebellum; these reductions were found in patients with major depression but not in controls (Figure 1 and Table 2). Within the frontal cortex, significant volume decline was detected in the superior and medial frontal cortices and in the superior and medial orbitofrontal cortices in patients with major depression but not in controls. The temporal cortices showed GMD reductions with right-pronounced localizations in the temporal pole and superotemporal lobe and with left-pronounced localizations in the fusiform gyrus and in the left hippocampus and parahippocampal gyrus. The cerebellum also showed GMD decline (which was more pronounced on the left side) in patients with major depression but not in controls. Additional bilateral structural alterations were found within the cuneus, lingual gyrus, and left precuneus. Bilaterally, the superior and middle occipital cortex showed reductions in GMD at the 3-year follow-up in patients but not in controls. No significant GMD losses were observed in the head and body of the basal ganglia and the thalamus.

No significant GMD increases were found at the 3-year follow-up in patients compared with controls. Some regions showed GMD decline from baseline to follow-up in the controls that was not seen in the patients. This decline was found bilaterally within the superior and inferior orbitofrontal cortices, the gyrus rectus, and some regions of the cerebellum.

## ROIs Analysis

In patients compared with controls, small-volume corrections for our ROIs revealed significantly greater GMD decline in the hippocampus (bilaterally left pronounced), as well as in the anterior cingulum and the left amygdala. The right DMPFC also diminished during the 3-year follow-up to a greater extent in patients than in controls. The DLPFC, right amygdala, and left DMPFC did not show more volume decline in patients than in controls at the follow-up (Figure 2).

## Effects of Clinical Outcome

The investigation of whether patients with stable remission during the 3-year follow-up period differ from the nonremitted patients revealed significant GMD decline in the left hippocampus, left anterior cingulum, left DMPFC, and bilaterally in the DLPFC in nonremitted patients (Figure 3). Compared with controls, nonremitted and stable remitted patients had greater GMD decline in these regions.

## COMMENT

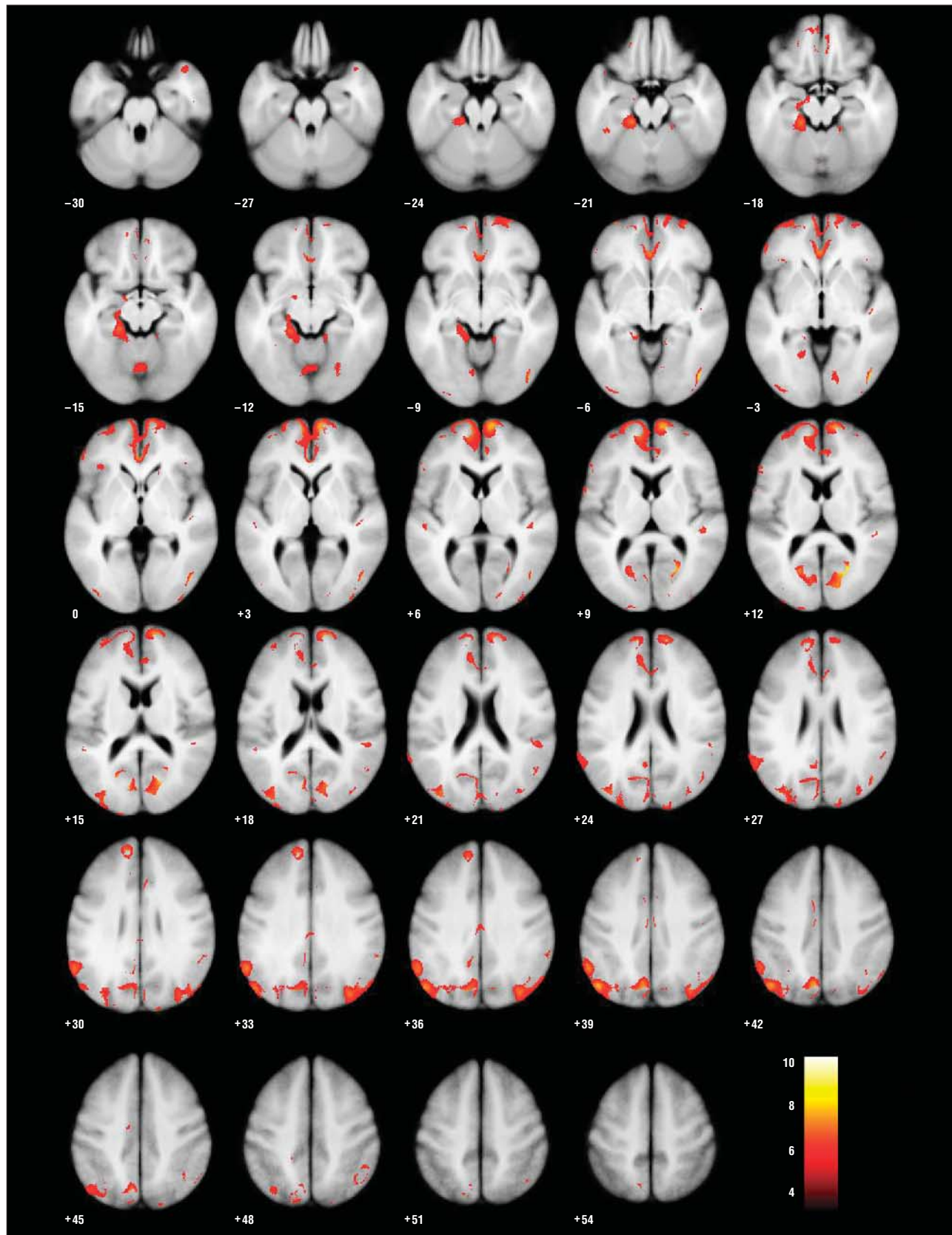
To our knowledge, this study demonstrates for the first time the progression of changes in GMD during 3 years in individuals with major depression compared with healthy controls. In this first longitudinal study, patients showed higher volume decline in the anterior cingulum, left amygdala, and right DMPFC and bilaterally in the hippocampus, compared with controls. The GMD of the superior and medial frontal cortices and the superior and medial orbitofrontal cortices and cerebellum also diminished significantly.

A growing amount of scientific data suggests that the cerebellum and its relevant neural connections to prefrontal areas should be integrated in models of depression. Because the vermis has the highest density of glucocorticoid receptors during development, exceeding that of the hippocampus,<sup>21</sup> it may be particularly vulnerable to the effects of stress hormones. An early MR imaging study showed reduced cerebellar vermis size in patients with unipolar depression, compared with healthy controls,<sup>22,23</sup> whereas a more recent quantitative MR imaging study<sup>24</sup> failed to demonstrate any statistically significant differences.

Most of our patients remitted after the inpatient treatment phase, but about 17 patients (45%) relapsed during the follow-up period. These were patients with the worst outcomes. The remaining 21 patients (55%) were stable over 3 years. Patients with incomplete remission and relapses to depression during the 3-year follow-up had a larger volume decline in the hippocampus, anterior cingulum, DLPFC, and DMPFC compared with stable remitted patients. The GMD decline in the amygdala did not differ between stable remitted patients and nonremitted patients. Therefore, GMD decline in the hippocampus, anterior cingulum, and prefrontal cortices seems to depend on depression-related factors such as stress, whereas GMD decline in the amygdala seems to be independent of the depressive state. In line with this, a cross-sectional study<sup>10</sup> reported an association between days of untreated depressive episodes and hippocampal volume reduction.

These results support changes in the structural integrity of neuronal cells in these specific important brain regions constituting a fronto-limbic-cerebellar network during depressive episodes and in particular during the course of depression. These data suggest that neuroplastic changes occur as a result of stress- and depression-related factors. Therefore, our results support transla-





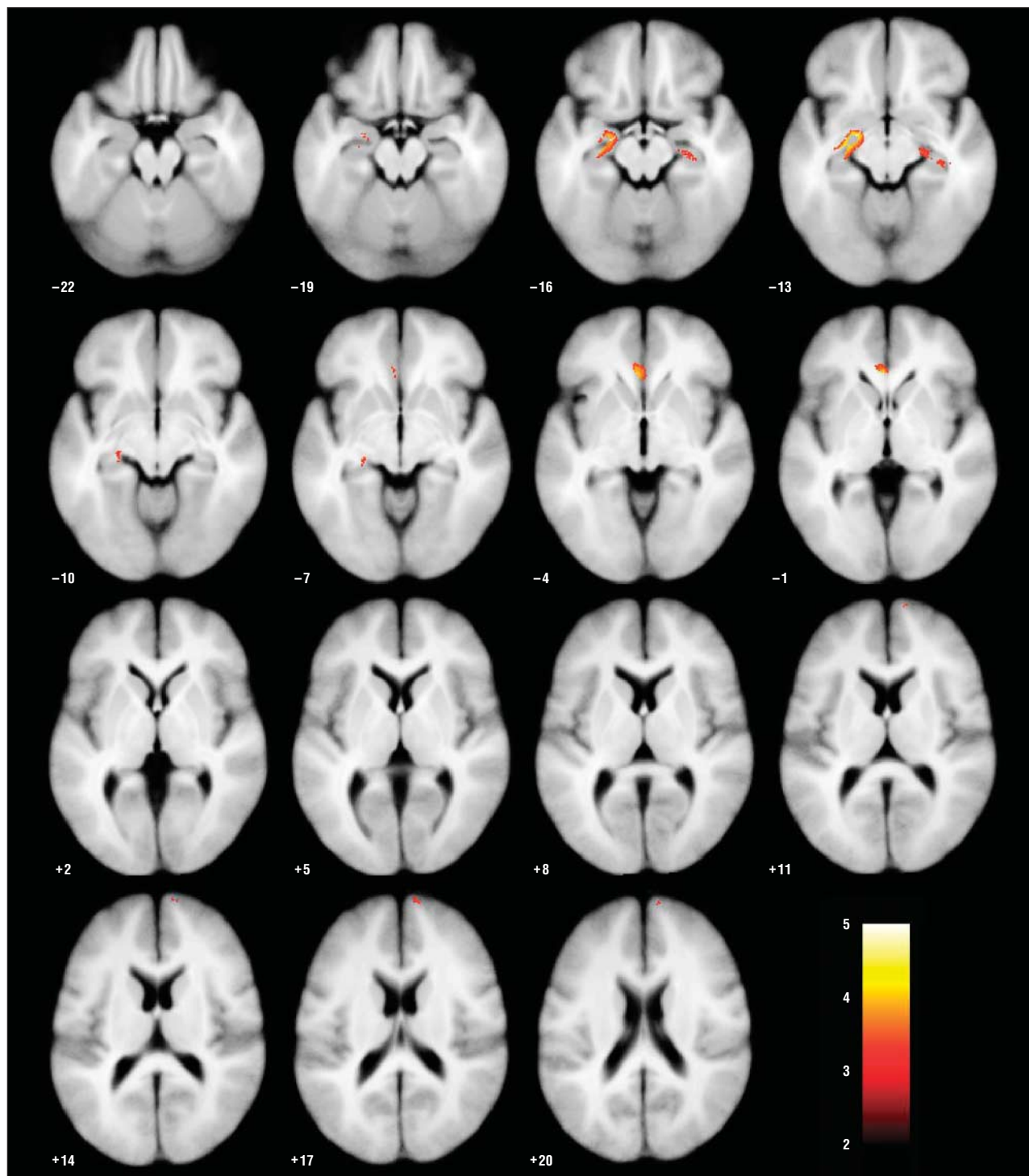
**Figure 1.** Overall brain gray matter density decline during 3 years in patients with major depression. Shown are regions in which gray matter density significantly diminishes from baseline to the follow-up investigations in patients with major depression, masked for the decline in healthy control subjects to determine a major depression-specific pattern. Numbers below sections represent the vertical distance in millimeters to the anterior commissure. Significant longitudinal gray matter density reductions within the dorsomedial prefrontal cortex, anterior cingulum, hippocampus, dorsolateral prefrontal cortex, and orbitofrontal, temporal, parietal, and occipital cortices are shown for patients with major depression compared with controls. Color of bar scales indicate the amount of significance. A difference between patients and controls is shown.

**Table 2. Progression of Gray Matter Density Decline in Whole-Brain Baseline and Follow-up Magnetic Resonance Images of Patients With Major Depression, Compared and Masked for the Decline in Healthy Control Subjects to Determine a Major Depression-Specific Pattern**

Variable	Left								Right							
	k	k %	FEW P Value <sup>a</sup>	T Value	MNI Coordinates			k	k %	FEW P Value <sup>a</sup>	T Value	MNI Coordinates				
					x	y	z					x	y	z		
<b>Frontal</b>																
Frontal superior	1535	5.3	<.001	6.89	-13	54	31	1008	3.1	<.001	7.23	15	66	10		
Frontal superior orbital	207	2.6	<.001	6.69	-14	61	-9	627	7.8	.001	6.39	13	65	-2		
Frontal mid	440	1.1	.01	5.71	-33	53	17	19	0.0	.01	5.68	19	57	25		
Frontal mid orbital	21	0.3	.007	5.89	-39	60	-4	...	...	...	...	...	...	...		
Frontal inferior operculum	54	0.6	.01	5.71	-61	7	9	...	...	...	...	...	...	...		
Frontal inferior triangular	331	1.6	.001	6.36	-53	38	-2	8	0.0	.03	5.42	42	31	-3		
Frontal inferior orbital	34	0.2	.003	6.08	-52	40	-4	...	...	...	...	...	...	...		
Frontal superior medial	3204	13.3	<.001	7.05	-8	59	7	2695	15.7	0	7.63	11	66	7		
Frontal medial orbital	518	9.0	<.001	6.84	-7	64	-2	551	8.0	.001	6.48	1	33	-10		
<b>Limbic</b>																
Cingulum anterior	1741	15.5	<.001	7.04	-3	37	-3	855	8.1	<.001	6.75	-1	34	-5		
Cingulum mid	257	1.6	.001	6.43	-11	-48	36	116	0.6	.003	6.1	1	-19	34		
Cingulum posterior	48	1.3	.003	6.12	-5	-55	28	...	...	...	...	...	...	...		
Hippocampus	286	3.8	.003	6.1	-20	-23	-15	...	...	...	...	...	...	...		
Parahippocampus	860	10.9	<.001	6.77	-18	-31	-21	...	...	...	...	...	...	...		
<b>Occipital</b>																
Calcarine	887	4.9	<.001	7.24	-20	-66	14	1223	8.2	<.001	8.86	24	-65	12		
Cuneus	985	8.0	<.001	6.85	-12	-74	38	416	3.6	<.001	7.17	17	-74	17		
Lingual	373	2.2	.004	6.01	-15	-38	-9	219	1.1	.004	6.02	13	-77	-2		
Occipital superior	419	3.83	.001	6.59	-12	-73	37	207	1.8	.002	6.29	34	-73	39		
Occipital mid	2322	8.8	<.001	7.25	-48	-72	37	2033	12.1	<.001	7.62	45	-75	-1		
Occipital inferior	30	0.4	.005	5.99	-34	-91	-6	218	2.7	<.001	9.42	45	-76	-5		
<b>Temporal</b>																
Fusiform	499	2.7	<.001	6.76	-19	-32	-18	153	0.7	.003	6.13	30	4	-42		
Temporal superior	110	0.6	.01	5.74	-51	-25	5	498	1.9	<.001	6.84	47	-31	10		
Temporal pole superior	...	...	...	...	...	...	...	183	1.7	<.001	6.65	41	17	-33		
Temporal mid	...	...	...	...	...	...	...	206	0.5	<.001	8.03	46	-73	-2		
Temporal pole mid	...	...	...	...	...	...	...	299	3.1	<.001	6.95	40	17	-34		
Temporal inferior	...	...	...	...	...	...	...	194	0.6	<.001	9	45	-75	-7		
<b>Parietal</b>																
Parietal superior	264	1.6	<.001	6.69	-12	-74	39	...	...	...	...	...	...	...		
Parietal inferior	965	4.9	<.001	7.03	-56	-55	39	184	1.7	.006	5.91	50	-49	48		
Supramarginal	751	7.47	<.001	6.94	-58	-53	33	199	1.2	.005	5.94	57	-46	29		
Angular	1756	18.7	<.001	7.63	-47	-71	41	1117	7.9	<.001	6.75	46	-70	30		
Precuneus	1662	5.8	<.001	7.34	-6	-69	41	...	...	...	...	...	...	...		
Rectus	140	2.0	.002	6.3	-8	54	-19	115	1.9	.008	5.84	5	32	-17		
<b>Cerebellum</b>																
Cerebellum_crus1_L	34	0.1	.01	5.75	-41	-49	-42	...	...	...	...	...	...	...		
Cerebellum_3_L	26	2.3	.001	6.49	-15	-30	-22	...	...	...	...	...	...	...		
Cerebellum_4_5_L	547	6.0	<.001	6.8	-16	-32	-21	...	...	...	...	...	...	...		
Cerebellum_4_5_R	141	2.0	.01	5.67	13	-42	-11	...	...	...	...	...	...	...		
Cerebellum_6_L	158	1.1	.01	5.75	-4	-68	-14	...	...	...	...	...	...	...		
Cerebellum_7b_L	37	0.7	.009	5.8	-39	-49	-43	...	...	...	...	...	...	...		
Cerebellum_8_L	205	1.3	.002	6.29	-24	-40	-45	...	...	...	...	...	...	...		
Cerebellum_8_R	215	1.1	.001	6.41	30	-42	-45	...	...	...	...	...	...	...		
Cerebellum_9_L	225	3.24	<.001	6.69	-22	-40	-46	...	...	...	...	...	...	...		
Cerebellum_9_R	33	0.5	.008	5.82	20	-40	-46	...	...	...	...	...	...	...		
Cerebellum_10_L	145	12.5	<.001	7.26	-22	-37	-45	...	...	...	...	...	...	...		
Cerebellum_10_R	82	6.4	<.001	6.65	25	-40	-43	...	...	...	...	...	...	...		
Vermis_6	402	13.5	.006	5.91	1	-68	-15	...	...	...	...	...	...	...		

Abbreviations: FEW, familywise error; k, number of significant voxels; k %, percentage of significant voxels in the anatomical region; L, left; MNI, Montreal Neurological Institute; R, right; ellipsis, not applicable.

<sup>a</sup>Corrected for multiple comparisons.

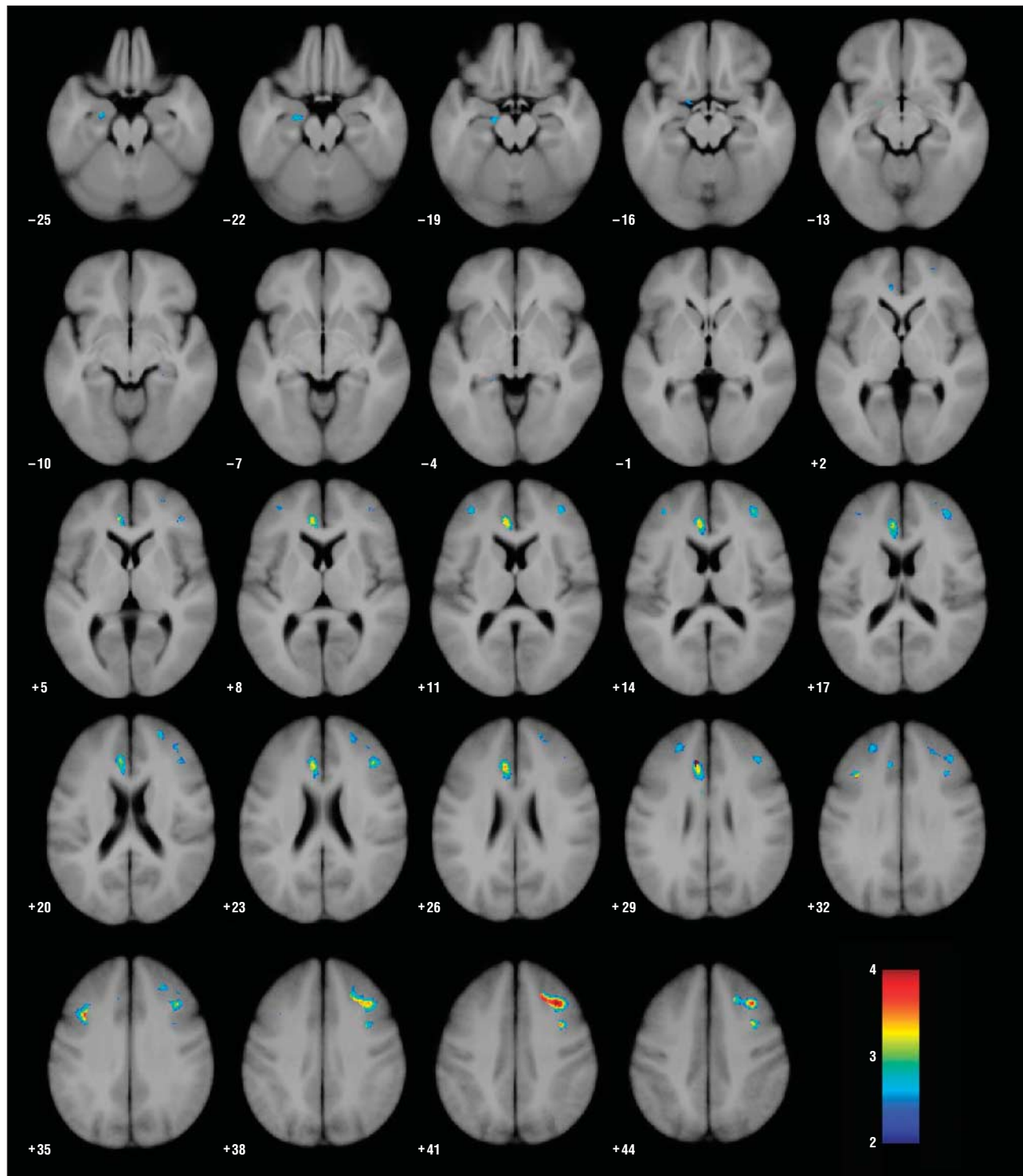


**Figure 2.** Small-volume-corrected gray matter density decline in regions of interest in patients vs control subjects. Shown are regions in which gray matter density declines more from baseline to the 3-year follow-up in patients with major depression than in healthy controls, with small-volume correction for the anterior cingulum, hippocampus, amygdala, dorsolateral prefrontal cortex, and dorsomedial prefrontal cortex. Statistical parametric maps were thresholded at  $t > 3.17$  (uncorrected  $P < .001$ ). The figure shows significantly greater gray matter density decline in patients compared with controls bilaterally in the hippocampus, bilaterally in the anterior cingulum, in the left amygdala, and in the right dorsomedial prefrontal cortex. Color of bar scales indicate the amount of significance.

tion of the hypothesis regarding toxic effects of stress in depression<sup>13</sup> to humans and are in agreement with cross-sectional findings on the relationship between illness duration and hippocampal volumes.<sup>10</sup>

A recent study<sup>14</sup> found no significant volume decline in the hippocampus during 1 or 3 years using

manual tracing methods (ROI). We have analyzed the data using VBM and found different results from those of the ROIs analysis. The strength of VBM is that altered parts of anatomical regions can be detected and the whole brain can be analyzed. However, a limitation of VBM is that the normalization procedure



**Figure 3.** Small-volume-corrected gray matter density decline in regions of interest in nonremitted patients vs remitted patients. Shown are regions in which gray matter density declines more from baseline to the 3-year follow-up in nonremitted patients with major depression than in stable remitted patients, with small-volume correction for the anterior cingulum, hippocampus, amygdala, dorsolateral prefrontal cortex, and dorsomedial prefrontal cortex. Statistical parametric maps were thresholded at  $t > 3.17$  ( $P < .01$  with Bonferroni correction). Shown is the significant gray matter density decline in the left hippocampus, left anterior cingulum, left dorsomedial prefrontal cortex, and bilaterally in the dorsolateral prefrontal cortex in nonremitted patients. Color of bar scales indicate the amount of significance.

reduces the power to identify alterations in anatomically complex regions.

Mayberg<sup>25</sup> suggests a model of depression in which a dorsal compartment (including the DLPFC, DMPFC, and anterior cingulum) that is involved in the cognitive symp-

tom of depression is hypoactive and in which a ventral compartment (consisting of the hippocampus, amygdala, subgenual cingulum, insula, brainstem, and hypothalamus) is hyperactive. Our results indicate GMD decline in the DLPFC, DMPFC, and anterior cingulum,



particularly in patients with ongoing depression; the hypoactivity in these regions during depressive episodes may be related in part to GMD decline. However, the hippocampus, which is supposed to be hyperactive in Mayberg's model, also shows GMD decline, which may be in line with experimental findings on the toxic effects of stress.<sup>13</sup>

Because GMD diminishes during the course of the disease, probably due to effects of depression, and because this decline has consequences for the clinical course, therapy with antidepressants or psychotherapy should be started as early as possible. Therefore, early diagnosis of depression is just as important as early diagnosis of dementia and schizophrenia.

The findings of the study are new and deserve discussion, particularly with respect to some limitations. Patients were taking medication at baseline and at follow-up. We did not detect any differences between patients taking their medication over the 3-year period vs those who stopped taking medication because they remitted. In 20 patients with posttraumatic stress disorder, the mean hippocampal volume was increased by about 4.6% after a 36- to 48-week antidepressant trial with paroxetine.<sup>26</sup> However, in patients with major depression, no significant change in the hippocampal volume was found after a mean (SD) of 7 (3) months of successful treatment with serotonin reuptake inhibitors (in particular, fluoxetine) compared with the pretreatment investigation.<sup>27</sup> A preliminary investigation in 10 pediatric patients with obsessive-compulsive disorder showed enlarged thalamic volumes before treatment and a decrease of thalamic volumes after 12 weeks of treatment with paroxetine, but it is unclear whether this effect was due to the medication or to symptom changes during treatment.<sup>28</sup> It may be that morphologic changes are more likely to be seen after a longer period, as in our study, than after a few months of treatment.

Patients who during the entire 3-year period were remitted had less volume decline in the left hippocampus, left anterior cingulum, and left DMPFC and bilaterally in the DLPFC compared with nonremitted patients. We are aware of no evidence that antidepressants act unilaterally on neurogenesis or neuroplastic processes, so we have to regard this finding with caution. The lack of changes in the right hippocampus and anterior cingulum could be a result of too small sample size and power.

The sample was insufficient to allow the clinical outcome to be assessed for all relevant treatment factors (eg, different pharmacotherapy or psychotherapy), so only the overall clinical outcome can be considered for VBM analysis. Studies in larger samples are necessary to investigate this question.

Our patients were treated according to current clinical practice in German hospitals for moderate to severe major depression after outpatient treatment has failed or when an episode is too severe. Therefore, the disease in this population may be more severe than that in an outpatient sample, which should be considered when comparing our results with those future studies.

Patients in our study have a somewhat older age at onset than the mean age at onset in the general population. The reason for this is unclear but may be because

our sample had more treatment resistance than an outpatient sample.

In summary, our findings indicate that during depressive episodes GMD diminishes in limbic and frontal cortical brain regions, indicating neuroplastic changes due to the effect of depression. More severe neuromorphologic abnormalities in the hippocampus, DLPFC, and anterior cingulum, particularly during the course of depression, seem to be clinically associated with a more severe outcome of depression. It is likely that an early start of treatment with antidepressants and psychotherapy may prevent neuroplastic changes that, in turn, worsen the clinical course. Moreover, much more effort is needed to explore the nature of these changes (eg, by translational research approaches), and further studies are necessary to address these aims.

**Submitted for Publication:** December 1, 2007; final revision received March 5, 2008; accepted May 5, 2008.

**Correspondence:** Thomas S. Frodl, MD, Department of Psychiatry, School of Medicine, Trinity College Dublin, Trinity Centre for Health Sciences, St James Hospital and Adelaide and Meath Hospital incorporating the National Children's Hospital (AMiNCH), Dublin 2, Ireland.

**Financial Disclosure:** None reported.

**Funding/Support:** This study was supported by the German Federal Research Ministry within the promotion "German Research Networks in Medicine" as part of the project "German Research Network on Depression."

**Additional Information:** Ms Scupin completed her doctoral thesis within this study.

**Additional Contributions:** Jaquie Klesing provided native English-language editing.

## REFERENCES

1. Duman RS. Pathophysiology of depression: the concept of synaptic plasticity. *Eur Psychiatry*. 2002;17(suppl 3):306-310.
2. Reagan LP, McEwen BS. Controversies surrounding glucocorticoid-mediated cell death in the hippocampus. *J Chem Neuroanat*. 1997;13(3):149-167.
3. Woolley CS, Gould E, McEwen BS. Exposure to excess glucocorticoids alters dendritic morphology of adult hippocampal pyramidal neurons. *Brain Res*. 1990; 531(1-2):225-231.
4. Santarelli L, Saxe M, Gross C, Surget A, Battaglia F, Dulawa S, Weisstaub N, Lee J, Duman R, Arancio O, Belzung C, Hen R. Requirement of hippocampal neurogenesis for the behavioral effects of antidepressants. *Science*. 2003;301(5634): 805-809.
5. Campbell S, Marriott M, Nahmias C, MacQueen GM. Lower hippocampal volume in patients suffering from depression: a meta-analysis. *Am J Psychiatry*. 2004;161(4):598-607.
6. Husain MM, McDonald WM, Doraiswamy PM, Figiel GS, Na C, Escalona PR, Boyko OB, Nemeroff CB, Krishnan KR. A magnetic resonance imaging study of putamen nuclei in major depression. *Psychiatry Res*. 1991;40(2):95-99.
7. Krishnan KR, McDonald WM, Escalona PR, Doraiswamy PM, Na C, Husain MM, Figiel GS, Boyko OB, Ellinwood EH, Nemeroff CB. Magnetic resonance imaging of the caudate nuclei in depression: preliminary observations. *Arch Gen Psychiatry*. 1992;49(7):553-557.
8. Shah PJ, Ebmeier KP, Glabus MF, Goodwin GM. Cortical grey matter reductions associated with treatment-resistant chronic unipolar depression: controlled magnetic resonance imaging study. *Br J Psychiatry*. 1998;172:527-532.
9. Bell-McGinty S, Butters MA, Meltzer CC, Greer PJ, Reynolds CF III, Becker JT. Brain morphometric abnormalities in geriatric depression: long-term neurobiological effects of illness duration. *Am J Psychiatry*. 2002;159(8):1424-1427.
10. Sheline YI, Gado MH, Kraemer HC. Untreated depression and hippocampal volume loss. *Am J Psychiatry*. 2003;160(8):1516-1518.
11. Ashburner J, Friston KJ. Voxel-based morphometry: the methods. *Neuroimage*. 2000;11(6, pt 1):805-821.

12. Taki Y, Kinomura S, Awata S, Inoue K, Sato K, Ito H, Goto R, Uchida S, Tsuji I, Arai H, Kawashima R, Fukuda H. Male elderly subthreshold depression patients have smaller volume of medial part of prefrontal cortex and precentral gyrus compared with age-matched normal subjects: a voxel-based morphometry. *J Affect Disord.* 2005;88(3):313-320.
13. Sapolsky RM. Glucocorticoids and hippocampal atrophy in neuropsychiatric disorders. *Arch Gen Psychiatry.* 2000;57(10):925-935.
14. Frodl T, Meisenzahl EM, Zetzsche T, Höhne T, Banac S, Schorr C, Jäger M, Leinsinger G, Bottlender R, Reiser M, Möller HJ. Hippocampal and amygdala changes in patients with major depressive disorder and healthy controls during a 1-year follow-up. *J Clin Psychiatry.* 2004;65(4):492-499.
15. Chen PS, McQuoid DR, Payne ME, Steffens DC. White matter and subcortical gray matter lesion volume changes and late-life depression outcome: a 4-year magnetic resonance imaging study. *Int Psychogeriatr.* 2006;18(3):445-456.
16. Hamilton M. A rating scale for depression. *J Neurol Neurosurg Psychiatry.* 1960;23:56-62.
17. Oldfield RC. The assessment and analysis of handedness: the Edinburgh Inventory. *Neuropsychologia.* 1971;9(1):97-113.
18. Good CD, Johnsrude IS, Ashburner J, Henson RN, Friston KJ, Frackowiak RS. A voxel-based morphometric study of ageing in 465 normal adult human brains. *Neuroimage.* 2001;14(1, pt 1):21-36.
19. Cuadra MB, Cammoun L, Butz T, Cuisenaire O, Thiran JP. Comparison and validation of tissue modelization and statistical classification methods in T1-weighted MR brain images [published correction appears in *IEEE Trans Med Imaging.* 2006;25(2):241]. *IEEE Trans Med Imaging.* 2005;24(12):1548-1565.
20. Tzourio-Mazoyer N, Landeau B, Papathanassiou D, Papathanassiou D, Crivello F, Etard O, Delcroix N, Mazoyer B, Joliot M. Automated anatomical labeling of activations in SPM using a macroscopic anatomical parcellation of the MNI MRI single-subject brain. *Neuroimage.* 2002;15(1):273-289.
21. Pavlík A, Buresová M. The neonatal cerebellum: the highest level of glucocorticoid receptors in the brain. *Brain Res.* 1984;314(1):13-20.
22. Shah SA, Doraiswamy PM, Husain MM, Escalona PR, Na C, Figiel GS, Patterson LJ, Ellinwood EH Jr, McDonald WM, Boyko OB. Posterior fossa abnormalities in major depression: a controlled magnetic resonance imaging study. *Acta Psychiatr Scand.* 1992;85(6):474-479.
23. Escalona PR, Early B, McDonald WM, Doraiswamy PM, Shah SA, Husain MM, Boyko OB, Figiel GS, Ellinwood EH, Nemeroff CB, Krishnan KRR. Reduction of cerebellar volume in major depression: a controlled MRI study. *Depression.* 1993;1:156-158.
24. Pillay SS, Yurgelun-Todd DA, Bonello CM, Lafer B, Fava M, Renshaw PF. A quantitative magnetic resonance imaging study of cerebral and cerebellar gray matter volume in primary unipolar major depression: relationship to treatment response and clinical severity. *Biol Psychiatry.* 1997;42(2):79-84.
25. Mayberg HS. Limbic-cortical dysregulation: a proposed model of depression. *J Neuropsychiatry Clin Neurosci.* 1997;9(3):471-481.
26. Vermetten E, Vythilingam M, Southwick SM, Charney DS, Bremner JD. Long-term treatment with paroxetine increases verbal declarative memory and hippocampal volume in posttraumatic stress disorder. *Biol Psychiatry.* 2003;54(7):693-702.
27. Vythilingam M, Vermetten E, Anderson GM, Luckenbaugh D, Anderson ER, Snow J, Staib LH, Charney DS, Bremner JD. Hippocampal volume, memory, and cortisol status in major depressive disorder: effects of treatment. *Biol Psychiatry.* 2004;56(2):101-112.
28. Gilbert AR, Moore GJ, Keshavan MS, Paulson LA, Narula V, Mac Master FP, Stewart CM, Rosenberg DR. Decrease in thalamic volumes of pediatric patients with obsessive-compulsive disorder who are taking paroxetine. *Arch Gen Psychiatry.* 2000;57(5):449-456.